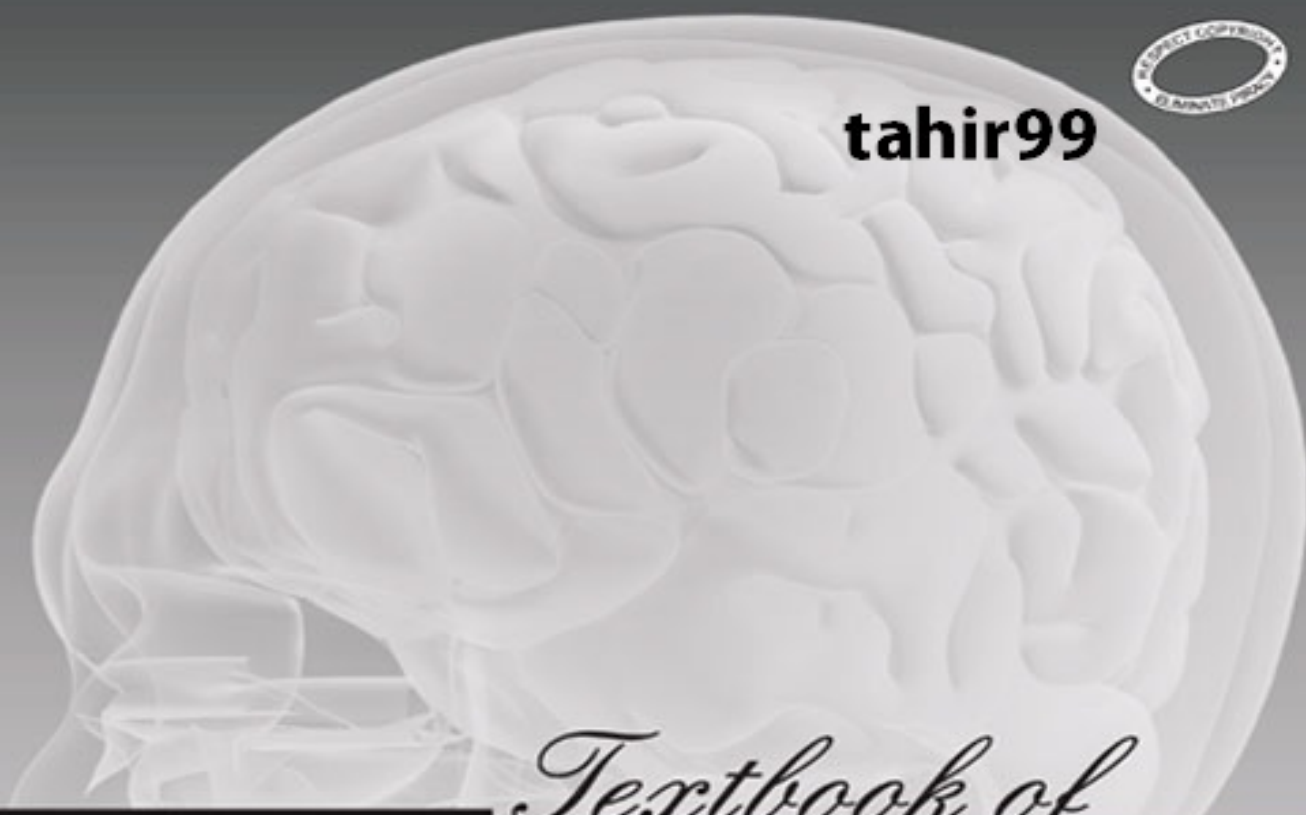




tahir99



Textbook of

CLINICAL NEUROANATOMY


SECOND EDITION

<https://kat.cr/user/Blink99/>

Vishram Singh



tahir99



Textbook of

CLINICAL NEUROANATOMY

SECOND EDITION

<https://kat.cr/user/Blink99/>

Vishram Singh

Textbook of clinical neuroanatomy

SECOND EDITION

Vishram Singh, MS

Professor & Head, Department of Anatomy, Professor-in-charge, Medical Education Unit, Additional Senior Superintendent of Examination, Santosh Medical College, Santosh University, Ghaziabad, NCR, Delhi



Table of Contents

Cover image

Title page

Copyright

Dedication

Preface to the second edition

Preface to the first edition

Acknowledgements

Chapter 1: Development of the nervous system

Formation of Neural Tube (FIG. 1.1)

Formation of Neural Crest Cells

Formation of Ectodermal Placodes

Development of Spinal Cord

Development of Brain

Hindbrain (Rhombencephalon)

Midbrain (Mesencephalon)

Forebrain (Prosencephalon)

Chapter 2: Organization and functions of the nervous system

Divisions of Nervous System

Cellular Organization of the Nervous System

Chapter 3: Peripheral nerves and ganglia

Nerve Fibres

Classification of Peripheral Nerve Fibres

Peripheral Nerves

Ganglia (Swelling or Knot)

Chapter 4: Receptors and effectors

Receptors

Effector Nerve Endings

Chapter 5: Dermatomes and muscular activity

Segmental Innervation of Skin

Segmental Innervation of Muscles

Muscle Tone

Movement and Posture

Posture (= physical disposition of the body)

Chapter 6: Central nervous system: an overview

Brain

Superficial Attachments of the Cranial Nerves

Spinal Cord

Ventricular System and CSF in CNS

Meninges and CSF

Chapter 7: Spinal cord

Positional Changes Of The Cord

Spinal Meninges

External Features of the Spinal Cord

Internal Structure of the Spinal Cord

Tracts of the Spinal Cord (Fig. 7.15)

Intrinsic Spinal Mechanisms

Blood Supply of The Spinal Cord Arterial Supply

Chapter 8: Brainstem

Medulla Oblongata

Pons

Midbrain

Chapter 9: Nuclei

Morphological Classification of Cranial Nerves

Functional Columns and Nuclei of Cranial Nerves

Nuclei, Functional Components and Distribution of Individual Cranial Nerves

Cortical Control of Cranial Nerves

Reflexes Mediated by Cranial Nerves

Chapter 10: Cerebellum and fourth ventricle

Cerebellum

Intrinsic Neuronal Circuitry in The Cerebellum

Fourth Ventricle

Chapter 11: Diencephalon and third ventricle

Diencephalon

Third Ventricle

Chapter 12: Cerebrum

External Features of the Cerebral Hemisphere

Types of Cerebral Cortex

Structure of Cerebral Cortex

Further Consideration of Motor and Sensory Areas

Cerebral Hemispheric Dominance

Chapter 13: Basal nuclei (Basal Ganglia)

Corpus Striatum

Clastrum

Amygdaloid Body

Substantia Nigra

Subthalamus (Subthalamic Nucleus)

Functions of Basal Nuclei

Chapter 14: White matter of the cerebrum and lateral ventricles 14

White Matter Of The Cerebrum

Lateral Ventricles

Chapter 15: Blood supply of the brain

Arteries of The Brain

Venous Drainage of The Brain

Blood-Brain Barrier (BBB)

Blood-Csf Barrier

Chapter 16: Meninges and cerebrospinal fluid

Meninges

Cerebrospinal Fluid

Chapter 17: Somatic motor and sensory pathways

Somatic Motor Pathways

General Somatic Sensory Pathways

Chapter 18: Special senses and their neural pathways

Olfactory System

Visual System

Auditory System

Steps Involved In Hearing

Vestibular System

Taste

Chapter 19: Reticular formation and limbic system

Reticular Formation

Limbic System

Chapter 20: Autonomic nervous system

Divisions of the Autonomic Nervous System

Autonomic plexuses

Autonomic ganglia

Neurotransmitters involved in autonomic nerve impulse transmission

Afferent nerve fibres of autonomic nervous system (visceral afferents)

Higher control of the autonomic nervous system

Enteric nervous system

Important autonomic innervations

Index

Copyright

Textbook of Clinical Neuroanatomy, 2/e

Vishram Singh

Elsevier

A division of

Reed Elsevier India Private Limited

Mosby, Saunders, Churchill Livingstone, Butterworth Heinemann and Hanley & Belfus are the Health Science imprints of Elsevier.

© 2010 Elsevier

First published 2004

Reprinted 2005 (twice), 2006, 2007,
2008 (thrice), 2009 (thrice)

Second Edition 2010

All rights are reserved.

No part of this publication may be reproduced, stored in a retrieval system, or transmitted in any form or by any means, electronic, mechanical, photocopying, recording or otherwise, without the prior permission of the publisher.

ISBN: 978-81-312-2307-9

Medical knowledge is constantly changing. As new information becomes available, changes in treatment, procedures, equipment and the use of drugs become necessary. The authors, editors, contributors and the publishers have, as far as it is possible, taken care to ensure that the information given in this text is accurate and up-to-date. However, readers are strongly advised to confirm that the information, especially with regard to drug dose/usage, complies with current legislation and standards of practice.

Published by Elsevier, a division of Reed Elsevier India Private Limited

Registered Office: Gate No. 3, Shed A-1, 2 Industrial Area, Kalkaji, New Delhi-110 019. Sales and

Publishing Office: 14th Floor, Building No. 10B, DLF Cyber City, Phase-II, Gurgaon 122002, Haryana, India.

Head, Medical Education: Jalees Farhan

Managing Editor: Binny Mathur

Copy Editor: Goldy Bhatnagar

Manager – Publishing Operations: Sunil Kumar

Manager – Production: NC Pant

Typeset by Olympus Infotech Pvt. Ltd., Chennai, India.

Printed and bound at Ajanta Offset, New Delhi.

Dedication

Dedicated to *My Parents*

Preface to the second edition

It is with great pleasure that I express my gratitude to all the students and teachers of the Indian subcontinent who have whole heartedly appreciated and recommended this book. It is because of their support that this book was reprinted more than 10 times since its first publication in 2004.

The success of this book reflects the appeal of its unique problem-solving approach and its utility in highlighting the anatomical and embryological basis of clinical problems in neurology and neurosurgery. This approach has been retained in this edition.

Based on the large number of suggestions by the teachers of anatomy (my young colleagues and senior Professors) and students, the text has been thoroughly updated and a number of new illustrations, tables and flowcharts have been added for easy comprehension and assimilation of the complicated information. The topics on cranial nerves, blood supply of the brain and sensory and motor pathways have been described in detail due to high incidence of cranial nerve lesions, cerebrovascular accidents and sensory and motor disorders in recent times.

There was a growing demand from PG students, neurologists and neurosurgeons to provide actual photographs, CT scans and MR images to appreciate the value of current diagnostic imaging techniques in diagnosing neurological lesions. They have been especially commissioned for this edition from Gray's Anatomy for Students, Integrated Anatomy, Davidson's Principles and Practice of Medicine (with kind permission of the publisher).

While the text is primarily written to help the undergraduate medical students to clear their concepts of neuroanatomy and confidently answer the questions in examinations, I am sure PG students, neurologists and neurosurgeons will also find it of value in updating and refreshing their knowledge.

I am really overwhelmed with the unexpected success of this book and for this I thank from the bottom of my heart (cortical) all students and academics. The inspiration and encouragement provided by them helped me to complete this revision. I sincerely hope that they will find this edition even more interesting and useful than the previous one. I would highly appreciate their comments and suggestions for further improvement of this book.

'Inspiring students to success is teacher's success'

Vishram Singh

Preface to the first edition

During my long teaching experience, I found that undergraduate medical students generally feel that neuroanatomy is not only a difficult subject to understand but also that it is not of much help in general practice. Contrary to this view, I feel that the subject of neuroanatomy is based on sound scientific foundation, which if properly understood, is of great clinical importance even for general practice in addition to neurological specializations.

To ensure that students develop an interest in neuroanatomy, this book is written in simple language with rational ideas and correlation of theoretical knowledge to clinical problems. Further the text is profusely illustrated which makes it easier for students to understand the subject and correlate their knowledge rather than merely memorizing the information.

As a teacher of Anatomy, I am emphatic that nothing stimulates the students more than discussing clinical applications of neuroanatomy. Therefore theoretical details, not of much clinical relevance have been skipped; on the other hand emphasis is given on problem-based learning (PBL). Clinical comments (screened in light pink) are inserted in the running text itself to emphasize the clinical significance of every segment of the text. Patient-oriented problems and their anatomical basis are presented at the end of each chapter.

I hope that this textbook will be useful and exciting to read and that it will stimulate enthusiasm for the subject.

It is my pleasure to sincerely thank all my colleagues in the department, Dr. Poonam Kharb, Dr. Nisha Kaul, Dr. LK Padhy and Dr. Rajvir Singh for their help during the preparation of this book. I am highly grateful to my teacher Prof A Halim who inspired me to develop a keen interest in neuroanatomy.

I express my gratitude to Professors/Doctors Ashok Sahai, Ajai Srivastava, PK Sharma and Mehdi Hasan (Lucknow); Hasan Zaidi, Virendra Kumar, Vinod Kumar and RK Srivastava (Kanpur); NC Goel and Manju Goel (Allahabad); Usha Dhall and SK Srivastava (Rohtak); Rani Kumar, Gayatri Rath, ZM Kaul, RK Suri, ML Ajmani, Ram Prakash and Veena Bharihoke (New Delhi); SJ Haider and Nafis Ahmad Faruqi (Aligarh); Ramesh Babu (Meerut); Versha Katira (Ghaziabad), Krishna Garg and Brijendra Singh (Murad Nagar); Madhur Gupta and Balbir Singh (Chandigarh); SL Jethani and Sohail A Pervez (Jolly Grant, Dehradun); A Agarwal (Agra) for their support.

I am deeply indebted to Mr. MM Mehra of BI Publications for providing me books for reference during the preparation of this text. My thanks are due to Mr. Atul Bhushan for typesetting and page designing. I highly appreciate the perseverance and keen interest shown by Mr. Aslam Pervez in redrawing the illustrations on the computer.

I wish to express my thanks to Mr. YR Chadha, Publishing Consultant, BI Publications, and to the staff of Elsevier, particularly Mr. Rajiv Banerji, Publishing Manager, Mr. Anand K Jha, Editor, and Mr. NC Pant, Senior Production Executive for taking keen interest in production of this book. The efforts of Mr. Jha have been invaluable for completion of this project.

Finally, I wish to express my deep gratitude to Dr. P Mahalingam, Chairman, Santosh World Medical Academy for his continuous support, encouragement and appreciation of my work.

Acknowledgements

I am highly grateful to Dr. P Mahalingam, Chancellor, Santosh University, Ghaziabad, NCR, Delhi for developing a congenial academic atmosphere in the university, and inspiring and encouraging me to complete this book.

I also express my deep gratitude to Dr. VK Arora, Vice Chancellor and Dr. Ayyaduri, Chief Executive Officer, Santosh University, Dr. DK Srivastava, Dean, Santosh Medical College, and Dr. Manoj Goel, Dean, Santosh Dental College for their help and guidance.

I thank my colleagues in the Department, Professor Nisha Kaul, Professor Avinash Sharma, and Dr. LK Padhy for their cooperation. I especially thank Dr. Ruchira Sethi for her support and help.

I am pleased to thank Professor Poonam Kharb, Sharda Medical College, Greater NOIDA, Dr. Hitendra Lohiya, Vardhman Mahavir Medical College & Safdarjung Hospital, New Delhi, Dr. Pradeep Bokariya, Mahatma Gandhi Institute of Medical Sciences, Sevagram, Wardha, Dr. Vishal Mudgil, Bankey Bihari Dental College and Research Centre, Ghaziabad, and Dr. Manoj Kumar, Krishna Dental College, Ghaziabad for sincerely going through the proofs.

I gratefully acknowledge the feedback and support of fellow colleagues in anatomy, particularly,

- Professors Mahdi Hasan, Ashok Sahai, MS Siddiqui, Ajay Kumar Srivastava (Head of the Department), PK Sharma and Dr. Punita Manik, King George Medical College, Lucknow.
- Professors Versha Katira, Krishna Garg and Dr. Deepa Singh, my ex-colleagues of the Department.
- Professor RK Srivastava (Head of the Department), Rama Medical and Dental Colleges, Kanpur, Uttar Pradesh.
- Professors Gayatri Rath (Head of the Department) and RK Suri, Vardhman Mahavir Medical College & Safdarjung Hospital, New Delhi.
- Professors Rani Kumar (Dean), Shashi Wadhwa, Raj Mehra, P Dhar and Dr. Ritu Sehgal, AIIMS, New Delhi.
- Professors Veena Bharihoke (Head of the Department), Ram Prakash and Dr. Rajeev Bhardwaj, UCMS, Shahdara, Delhi.
- Professors Shipra Paul (Head of the Department) and Shashi Raheja, Lady Hardinge Medical College, New Delhi.
- Professor JM Kaul (Head of the Department) and Dr. Dinesh, Maulana Azad Medical College, New Delhi.
- Professors SL Jethani (Head of the Department), Sohail Ahmed Pervez, RK Rohtagi, and Dr. Namita Mehrotra, Himalayan Institute of Medical Sciences, Jolly Grant, Dehradun.
- Professors Keshav Kumar (Head of the Department) and NC Goel, MLN Medical College, Allahabad.
- Professor SD Joshi (Head of the Department), Rural Medical College, Loni, Maharashtra.
- Professor Balbir Singh (Head of the Department), Government Medical College, Chandigarh.
- Professor Vinod Kumar (Head of the Department), GSVM Medical College, Kanpur, Uttar Pradesh.
- Professor Ramji Lal (Head of the Department), BRD Medical College, Gorakhpur, Uttar Pradesh.
- Professor CS Ramesh Babu (Head of the Department), LLRM Medical College, Meerut, Uttar Pradesh.

- Professors AK Asthana (Dean) and Satyam Khare (Head of the Department) Subharti Medical and Dental Colleges, Meerut, Uttar Pradesh.

I gratefully acknowledge the help and cooperation received from the staff of Elsevier, a division of Reed Elsevier India Pvt. Ltd., especially Mr. Vidhu Goel (Director, Clinical Education and Reference Division), Dr. Jalees Farhan (Head, Medical Education) and Dr. Binny Mathur (Managing Editor), Ms Goldy Bhatnagar, and Mr. Milind Majgaonkar (Graphic Designer). I highly appreciate the sincerity and dedication of Dr. Binny Mathur.

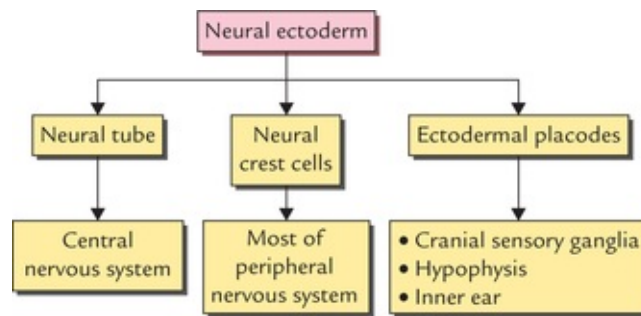
Vishram Singh

Development of the Nervous System

A study of development of the nervous system helps to understand its complex organization and the occurrence of various congenital anomalies.

The whole of the nervous system is derived from ectoderm except its blood vessels and some neuroglial elements.

The specific cell population of the early ectoderm, which gives rise to entire nervous system and special sense organs is termed **neural ectoderm**. The neural ectoderm later differentiates into three structures: neural tube, neural crest cells, and ectodermal placodes. The neural tube gives rise to the central nervous system (CNS), the neural crest cells form nearly all the peripheral nervous system and ectodermal placodes contribute to the cranial sensory ganglia, hypophysis and inner ear ([Flowchart 1.1](#)).



FLOWCHART 1.1 Genesis of nervous system and special sense organs.

Formation of Neural Tube (FIG. 1.1)

In the early embryonic disc, at about 16th day of embryonic life, the ectoderm overlying the newly formed notochord thickens in the midline forming the **neural plate**. As somatic mesoderm develops on either side of notochord, the margins of neural plate are elevated as **neural folds**, as a result the centre of the plate sinks, creating the **neural groove**. The neural folds gradually move together towards the mid-line and finally fuse to form a cylindrical neural tube that loses its connection with the surface ectoderm. The process of neural tube formation is termed **neurulation**.

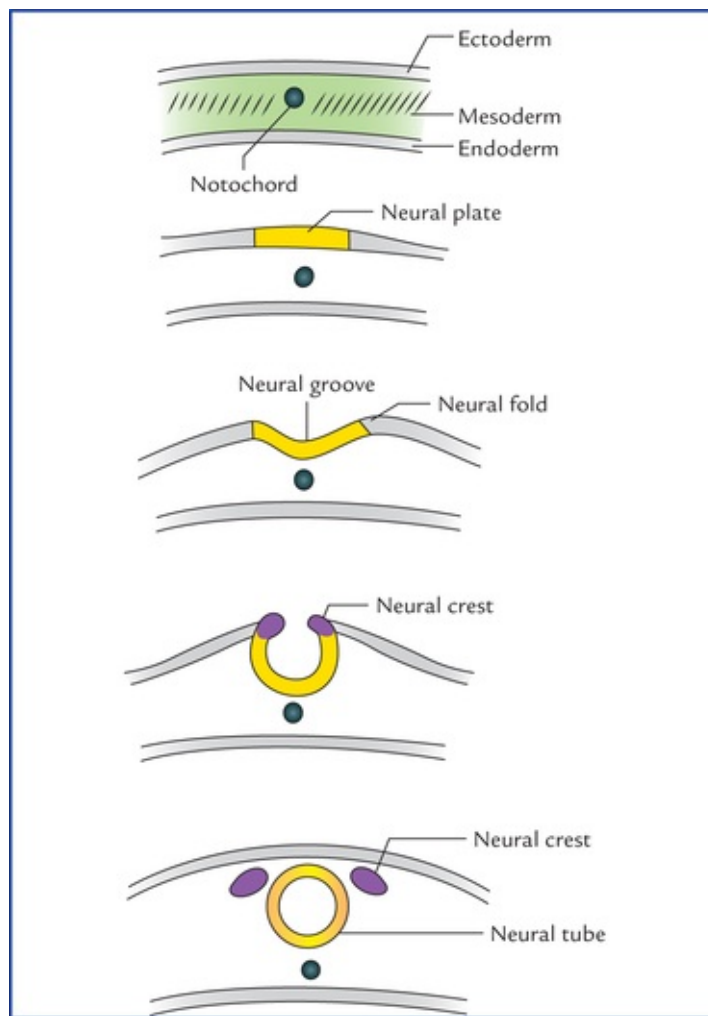


FIG. 1.1 Formation of neural tube and neural crest.

The fusion of neural folds begins in the middle (region of fourth somite on 20th day of embryonic development) and it simultaneously proceeds in the cephalic and caudal directions. The fusion at the cranial and caudal ends of neural tube are somewhat delayed, forming small openings called **anterior** and **posterior neuropores**. The neural tube and surrounding amniotic cavity, therefore, remain temporarily in open communication with each other through these pores. The anterior neuropore closes in the middle of the 4th week at 18–20 somite stage (i.e. on 25th day) and posterior neuropore closes at the end of 4th week at about 25 somite stage. By the time the neural tube is completely closed, it is divisible into an enlarged cranial part and an elongated caudal part which later on gives rise to brain and spinal cord, respectively.

Formation of Neural Crest Cells

As the neural folds come together and fuse, the cells at the tips of neural folds break away from the neuroectoderm to form neural crest cells. The surface ectoderm of one side becomes continuous with the surface ectoderm of the opposite side over the neural tube.

Thus the cells at the tips of neural folds (**neural crest cells**) do not participate in neural tube formation. The neural crest cells at first remain in the midline between the dorsal surface of the neural tube and the surface ectoderm, and then forms two-cell clusters dorsolaterally, one on either side of the neural tube.

The neural crest cells differentiate to form the cells of dorsal root ganglia, sensory ganglia of cranial nerves, autonomic ganglia, adrenal medulla, chromaffin tissue, melanocytes and Schwann cells (Fig. 1.2).

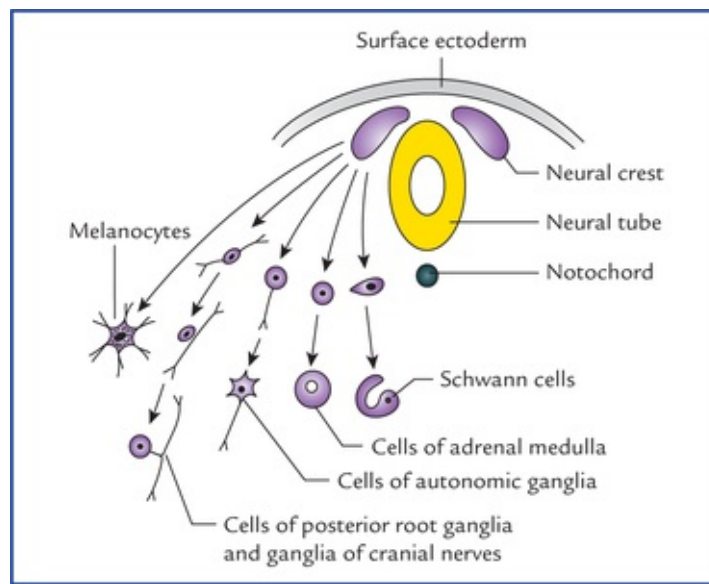


FIG. 1.2 Structures derived from neural crest cells (differentiation of neural crest cells).

Formation of Ectodermal Placodes

Prior to the neural tube closure, the neural fold contains two types of cell populations: neural crest cells and neuroepithelial cells. During *neurulation*, the neural crest cells are detached and neuroepithelial cells become incorporated into the surface ectoderm. These areas of neuroepithelium within the surface ectoderm are termed **ectodermal placodes**. (For details read textbooks on Embryology.)

Clinical Correlation

- **Anencephaly (craniorachischisis)** A failure of the cephalic part of the neural tube to close and associated defective development of the vault of the skull produces a congenital anomaly called **anencephaly**.

Characteristic features

- The vault of skull is absent.
- The brain is represented by a mass of degenerated tissue exposed to the surface.
- The cord is open in the cervical region.
- The appearance of child is characteristic with:
 - prominent eyes bulging forwards, and the chin continuous with the chest due to the absence of neck.
- **Rachischisis (a severe form of spina bifida)** An incomplete closure of caudal neuropore and defective development of the associated vertebral arches causes a congenital anomaly called **rachischisis**.

Characteristic features

- A failure of dorsal portions of the vertebral arches to fuse with each other.
- Usually localized in the lumbosacral region.
- The neural tissue is widely exposed to the surface.
- Occasionally the neural tissue shows considerable overgrowth, usually however the excess

tissue becomes necrotic shortly before or after the birth.

N.B. Anencephaly and rachischisis are the common and severe forms of congenital anomalies of CNS due to defective development of the neural tube.

Development of Spinal Cord

The spinal cord develops from the caudal elongated part of the neural tube. The neural tube increases in thickness due to repeated mitosis of its epithelial lining. By the middle of 5th week of embryonic development, the transverse section of the recently closed neural tube (**according to classical theory**) reveals three distinct layers or zones. From within outwards these are: (a) matrix (ependymal) zone, (b) mantle zone, and (c) marginal zone (**Fig. 1.3**).

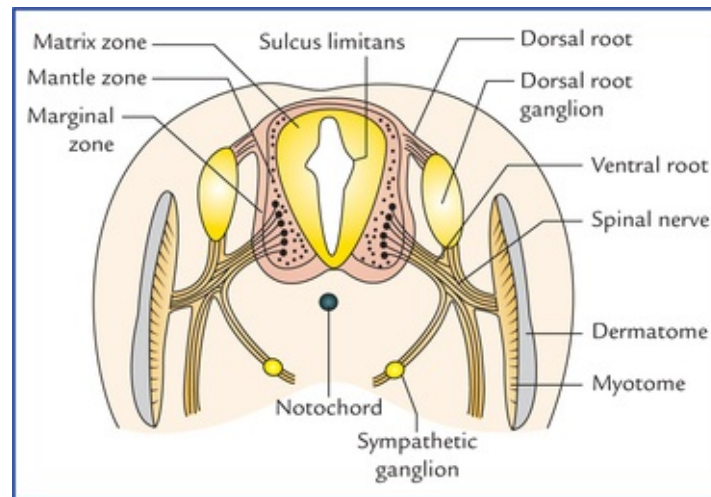


FIG. 1.3 The differentiation of the neural tube into three distinct layers and zones and associated structures.

Matrix (ependymal) zone is thick and lines the enclosed cavity (neurocele). Its numerous cells undergoing mitosis produce neuroblasts and spongioblasts; the former develop into neurons and the latter into neuroglial cells.

The neuroblasts migrate to the adjacent **mantle zone**, the future spinal grey matter; their axons enter the external **marginal zone**, the future white matter.

Some central processes of the dorsal root ganglia ascend in the marginal zone while others synapse with neurons in the mantle zone.

Once the histogenesis is complete, the remaining matrix cells differentiate into ependymal cells lining the central canal.

Recently, on the basis of microspectrophotometric, radioautographic and electron microscopic observation the concept of classical theory is changed.

Now according to current theory the wall of recently closed neural tube consists of only one cell type, the *pluripotent neuroepithelial cells*. These cells extend over the entire thickness of the wall and form thick pseudostratified neuroepithelium. The zonal appearance merely reflects the different phases of their proliferative cycle, the sequence being termed *interkinetic migration*.

As the development proceeds, these neuroepithelial cells give rise to another cell type having round nuclei with dark staining nucleoli, called nerve cells or *neuroblasts*. The neuroblasts form a zone which surrounds the neuroepithelial layer. It is known as mantle zone. Mantle zone later forms the grey matter of the spinal cord. The outermost layer of spinal cord contains the fibres emerging from the neuroblasts in the mantle layer and is known as marginal layer. Myelination of nerve fibre gives this layer a white appearance and is referred to as the white matter of the spinal cord.

The dorsal and ventral walls of the neural tube remain thin and called roof and floor plates respectively. On each side the wall of neural tube is demarcated into dorsal and ventral regions by an inner longitudinal sulcus called **sulcus limitans**.

The cells of dorsal region or **alar lamina** are functionally afferent/sensory while those of **basal lamina** are efferent/ motor. The axons of cells of basal lamina leaving the cord as ventral roots join with the peripheral processes of dorsal root ganglia, to form the spinal nerves (Fig. 1.4).

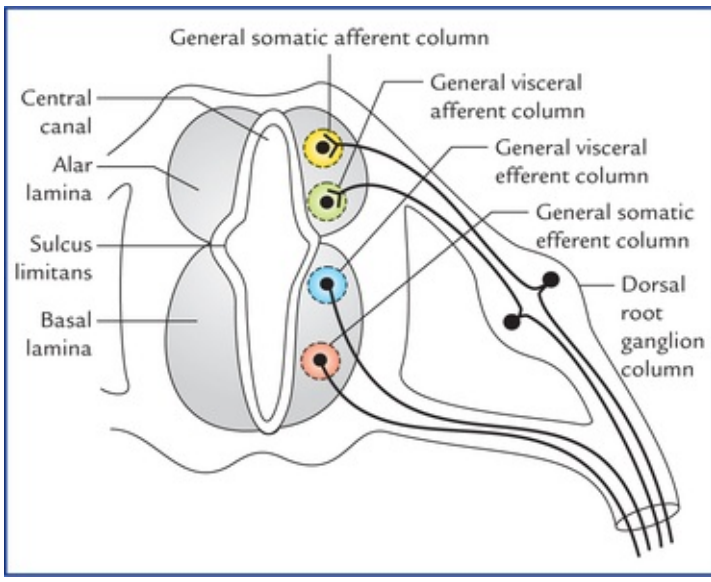


FIG. 1.4 Transverse section of the developing spinal cord showing four longitudinal cell columns.

The cells of alar and basal laminae are arranged into longitudinal columns. Each lamina reveals two columns.

The **two afferent columns of alar lamina** receive axons from dorsal root ganglia. These are:

1. **General somatic afferent column:** It extends throughout the spinal cord and receives impulses from superficial (cutaneous) and deep (proprioceptive) receptors.
2. **General visceral afferent column:** It is confined to thoracolumbar and sacral regions only and receives impulses from viscera and blood vessels

The **two efferent columns of basal lamina** give rise to motor fibres.

These are:

1. **General visceral efferent column:** It is confined to thoracolumbar and sacral regions only and provides preganglionic fibres (synapsing in ganglia) to viscera, glands and blood vessels.
2. **General somatic efferent column:** It extends throughout the spinal cord and provides fibres which innervate the skeletal muscles.

N.B. The four cell columns in the spinal cord are termed 'general' because three additional 'special' columns exist in the brainstem.

Development of Brain

The brain develops from the enlarged cranial part of the neural tube. At about the end of 4th week, the enlarged cephalic part shows three distinct dilatations called **primary brain vesicles** (Fig. 1.5). Craniocaudally, these are: (a) prosencephalon (forebrain), (b) mesencephalon (mid-brain), and (c) rhombencephalon (hindbrain). Their cavities form the ventricular system of the adult brain. During the 5th week both prosencephalon and rhombencephalon subdivide into two vesicles thus producing five **secondary brain vesicles**.

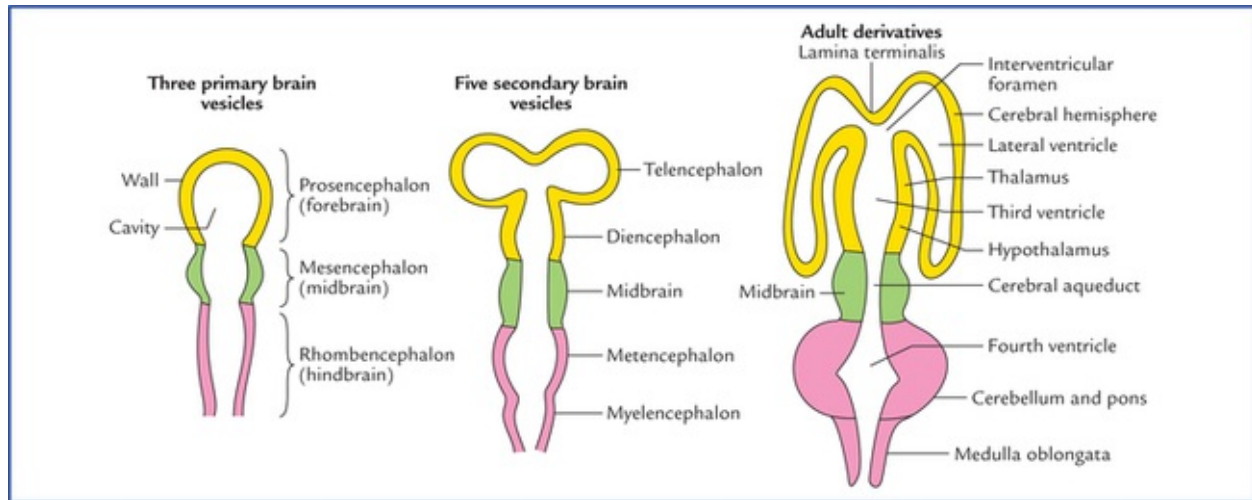


FIG. 1.5 Stages in the differentiation of brain vesicles and the ventricular system.

The **prosencephalon** gives a rostral telencephalon and caudal diencephalon (interbrain). The *telencephalon* develops lateral diverticula by evagination which enlarge, overgrow and cover the caudal diencephalon to form the cerebral hemispheres. The *diencephalon* thus becomes hidden in the lower parts of the cerebral hemispheres and forms thalamus, hypothalamus, epithalamus, etc.

The **mesencephalon** gives rise to midbrain. It does not show much change in the early part of development except that its cavity gets progressively narrowed to form the *cerebral aqueduct*.

The **rhombencephalon** divides into rostral *metencephalon* which eventually develops into pons and cerebellum and caudal *myelencephalon* which gives rise to medulla oblongata.

The adult derivatives of brain vesicles are summarized in [Table 1.1](#).

Table 1.1

Adult derivatives of brain vesicles

Primary brain vesicles (3 in number)	Secondary brain vesicles (5 in number)	Parts of adult brain	Parts of ventricular system
Prosencephalon (forebrain)	<ul style="list-style-type: none"> • Telencephalon • Diencephalon 	Cerebral hemispheres – Thalamus – Metathalamus – Hypothalamus – Subthalamus – Epithalamus	Lateral ventricles Third ventricle
Mesencephalon (midbrain)	Mesencephalon	Midbrain	Cerebral aqueduct
Rhombencephalon (hindbrain)	<ul style="list-style-type: none"> • Metencephalon • Myelencephalon 	– Pons – Cerebellum – Medulla oblongata	Fourth ventricle

Flexures of the Brain

The primitive brain presents three flexures:

1. *Pontine flexure*, at the middle of rhombencephalon.
2. *Cervical flexure*, at the junction of rhombencephalon and spinal cord.
3. *Cephalic (mesencephalic) flexure*, in the region of midbrain.

The cephalic and cervical flexures are concave ventrally, whereas the pontine flexure exhibits a ventral convexity (Fig. 1.6).

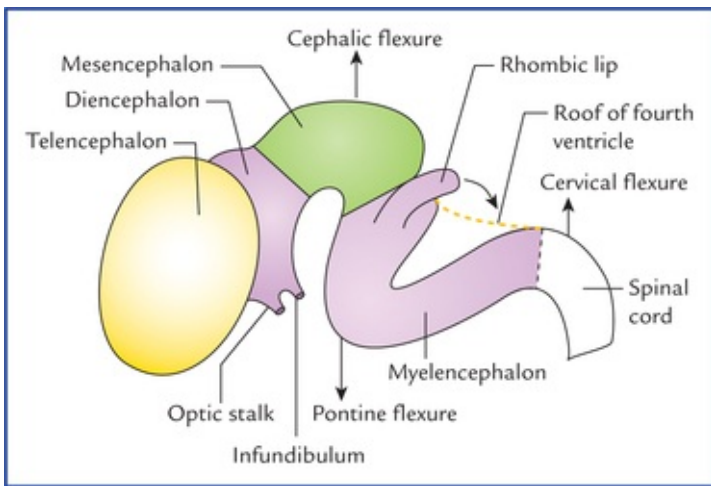


FIG. 1.6 Three flexures of the developing brain. The arrow from the rhombic lip indicates the direction of growth of the cerebellum.

The cervical flexure makes a 90° bend between hind-brain and spinal cord causing the brain to be oriented almost at 90° to the spinal cord.

The brain assumes its configuration as a result of differential growth of its vesicles and of flexures.

Pontine flexure

The hindbrain is folded at its middle so that it forms an acute angle ventrally. This changes the shape of the tube dramatically. The cavity becomes a diamond-shaped space, called **fourth ventricle**, which is widest at the line of folding (junction of the two parts of the hindbrain-the pons and the medulla

oblongata) and tapers superiorly to the narrow canal of the midbrain, the aqueduct of Sylvius and inferiorly to the central canal in the lower part of the medulla oblongata (Fig. 1.7). The thin roof is pulled out to cover the space posteriorly, and at the line of folding extends far laterally as the roof of the lateral recesses of the fourth ventricle. At the tips of these recesses and at the inferior angle of the ventricle, the thin roof breaks down forming the apertures (lateral foramina of Luschka and median foramen of Magendie) through which the cavity of neural tube communicates with the surrounding subarachnoid space.

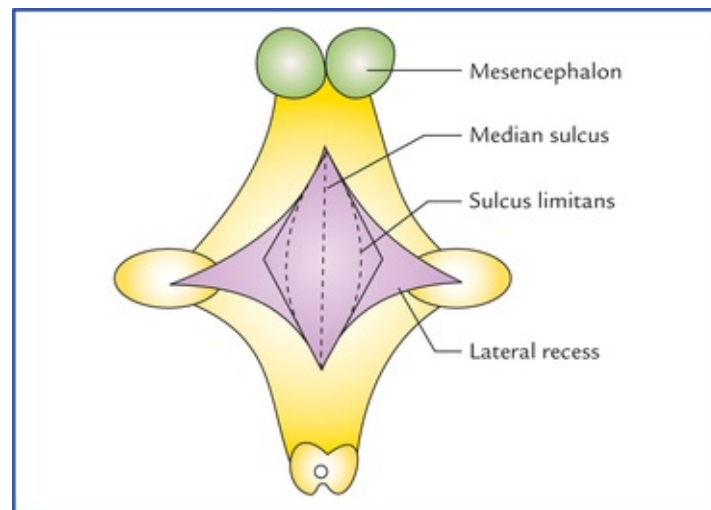


FIG. 1.7 Posterior view of developing rhombencephalon showing the role of pontine flexure in the formation of fourth ventricle. Note, opposite to the line of pontine flexure the neural tube is flattened out, as a result the slit-like cavity of rhomben-cephalon becomes diamond-shaped.

The flattening of the hindbrain which results from folding, displaces the alar laminae so that they lie lateral to the basal laminae (buckling effect). Thus the sensory nuclei which arise from the alar laminae are lateral to the motor nuclei which arise from the basal laminae. *For this reason sensory cranial nerves are attached laterally and motor cranial nerves medially to the brainstem.*

The part of hindbrain caudal to the pontine flexure is called *myelencephalon* (the future medulla oblongata) and rostral part from which pons and cerebellum develop is called *metencephalon*.

Cervical flexure

Cervical flexure is convex dorsally and appears at the junction of hindbrain and spinal cord, making a right angled bend between them.

Cephalic flexure

Cephalic flexure is convex dorsally and appears at the mid-brain level.

N.B. The closed rostral end of the neural tube persists as a thin lamina terminalis.

Development of Ventricular System

The cavities of brain vesicles form the ventricular system of adult brain:

- The hindbrain cavity becomes the *fourth ventricle*.
- The narrowed mesencephalic cavity becomes the *cerebral aqueduct (aqueduct of Sylvius)*.

- The diencephalic cavity becomes the *third ventricle*.
- The twin telencephalic cavities become *lateral ventricles*.

Further development of hindbrain, midbrain, and fore-brain is discussed below in brief.

Hindbrain (Rhombencephalon)

The caudal part of the myelencephalon has a central canal and forms the **closed part of the medulla oblongata**. Rostrally the central canal expands as the cavity of the fourth ventricle, and thus the rostral part of myelencephalon forms the open part of the medulla oblongata.

The floor of fourth ventricle is derived from myelencephalon (medulla) and metencephalon (pons). On either side of midline the floor consists of basal and alar laminae, which are separated from each other by a longitudinal sulcus called **sulcus limitans**. The basal and alar laminae similar to that of spinal cord, contains motor, and sensory nuclei respectively. These nuclei are arranged into longitudinal columns. In spinal cord as discussed earlier, each lamina contains two columns, somatic and visceral but in the brainstem to supply the derivatives of the branchial arches which develop around this region, an extra branchial column, appears between the somatic and visceral columns of each lamina. In addition, a special column is added in the most lateral part of the alar lamina to receive impulses of special sensations of hearing and balance. Thus in brainstem the basal lamina contains three columns and alar lamina four columns (for details see [page 91](#)).

The stretched roof plate of rhombencephalic vesicle forms the roof of fourth ventricle. The roof consists of a single layer of ependymal cells covered by a vascular mesenchyme, the pia mater. The single layer of ependymal cells with covering pia mater is known as **tela choroidea**. Owing to the active proliferation of the vascular mesenchyme, the tuft of capillaries of blood vessels invaginates into the ventricular cavity. These sac-like invaginations consisting of tela choroidea and tuft of capillaries form the **choroid plexus** ([Fig. 1.8](#)).

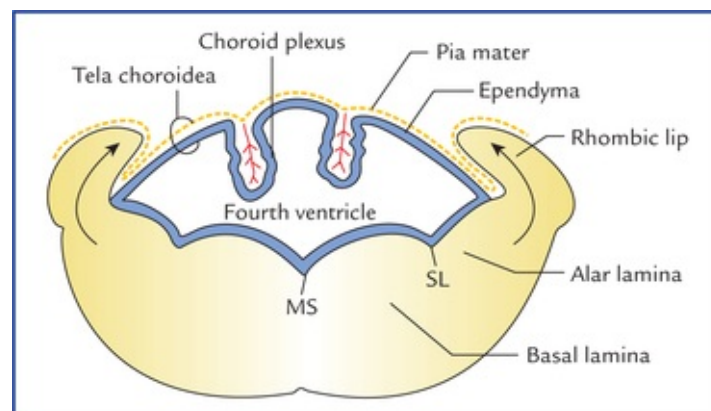


FIG. 1.8 Developing fourth ventricle and cerebellum. Note: (a) Vascular pia mater invaginates ependyma to form choroid plexus, (b) alar lamina lies lateral to basal lamina, and (c) rhombic lips derived from alar laminae grow together to form cerebellum dorsal to the roof of fourth ventricle. (MS = median sulcus, SL = sulcus limitans.)

The dorsolateral parts of the alar laminae of metencephalon extend medially and dorsally to form the **rhombic lips**. These meet and fuse over the roof of the fourth ventricle and then grow dorsally to form the **cerebellum**.

The marginal layer of the basal plates of metencephalon expands considerably to serve as a bridge for nerve fibres connecting the cerebral cortex and the cerebellar cortex (corticoponto-cerebellar pathways).

Since this portion of metencephalon serves as a bridge it is known as **pons** (pons = bridge).

Midbrain (Mesencephalon)

Morphologically the midbrain is the most primitive of the brain vesicles. It generally retains a cylindrical form and its narrowed cavity forms the cerebral aqueduct which is continuous below with the fourth ventricle and above with the third ventricle.

- Anterior to the cerebral aqueduct, the basal laminae give rise to the **tegmentum** and **substantia nigra**. The marginal layer of each basal lamina enlarges and forms the **crus cerebri**. These crura serve as pathway for the nerve fibres descending from the cerebral cortex to the lower centres in the pons, medulla, and spinal cord.
- The cells of alar laminae invade the roof plate, to form the bilateral longitudinal elevations separated by a shallow midline groove. With further development, each elevation is subdivided by a transverse groove into upper and lower parts called **superior and inferior colliculi** respectively. Thus, four colliculi (also called corpora quadrigemina) develop into the roof plate dorsal to the aqueduct of Sylvius and form the **tectum**.

Forebrain (Prosencephalon)

- The **diencephalon** develops from the median portion of the pros-encephalon. Its cavity is called **third ventricle**. The primitive dien-cephalon consists of two thick lateral walls, a thin roof and floor plates. Each lateral wall presents a sulcus, the **hypothalamic sulcus** which appears to be the rostral continuation of the **sulcus limitans**. The hypothalamic sulcus divides the lateral wall into dorsal and ventral regions. The dorsal region develops into the **thalamus**. The ventral region encroaches on the floor plate and form the **hypothalamus**.

A downgrowth from the floor of anterior hypothalamus, the *neurohypophysis* joins an upgrowth from the stomodeum the *adenohypophysis* to form the **hypophysis cerebri (pituitary gland)**.

The **epithalamus** comprising *pineal gland* and *habenular nuclei* develops posteriorly in the roof plate. The **pineal gland** grows posteriorly from the roof plate at its junction with the midbrain, and lies on the dorsal surface of midbrain between the two superior colliculi.

- The **telencephalon** consists of a median part and two lateral diverticula or cerebral vesicles. The median part forms a small anterior part of the third ventricle, and the lamina terminalis which limits the ventricle rostrally.

The lamina terminalis represents the cephalic end of the primitive neural tube and corresponds with the site of closure of the anterior neuropore.

The lateral diverticula or cerebral vesicles represent the rudiments of cerebral hemispheres. The cavities of the hemispheres, the **lateral ventricles**, communicate with the cavity of diencephalon, the third ventricle through the interventricular foramina.

The developing cerebral hemisphere enlarges forwards upwards and backwards in that order. As the vesicle grows backwards it overlaps successively diencephalon, mesencephalon and cerebellar rudiments. The lowest parts of the medial walls of hemispheres in the region where they are attached to the roof of diencephalon remain very thin due to disproportionate growth of the various parts of the hemispheres.

Through this thin wall, the choroid plexus of third ventricle protrudes laterally into the lateral ventricle along a line known as the **choroid fissure**.

Immediately above the choroid fissure, the medial wall of the hemisphere thickens to form the **hippocampus**. With subsequent massive expansion of the cerebral hemispheres (neocortex), the hippocampus is displaced posteroinferiorly into the lateral ventricle; the **fornix** is drawn out as an efferent tract on its medial aspect. The choroid fissure also becomes curved, interposed between the fornix and diencephalon.

The **corpus striatum** develops bilaterally in the floor of tel-encephalon adjacent to the thalami. Primitively these areas of grey matter (corpus striatum) are **sensory-motor control centres**. Subsequent to the massive development of neocortex, a major pathway must develop for descending fibres from the cerebral cortex, and ascending fibres from the thalamus to the cerebral cortex, the only possible route is through this region. Hence, these fibres which form the **internal capsule** on each side, divide the corpus striatum into two parts: (a) a dorsomedial portion, the **caudate nucleus**, and (b) a ventrolateral portion, the **lentiform nucleus** (Fig. 1.9A, B).

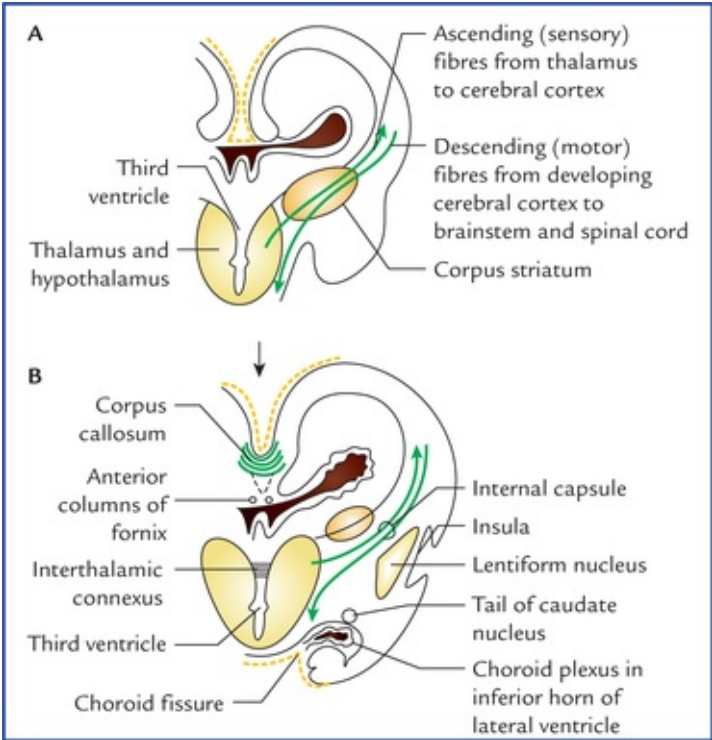


FIG. 1.9 Coronal sections through the developing forebrain—showing development of internal capsule and establishment of corpus striatum. Note the ascending and descending fibres traversing through corpus striatum (A), and the division of corpus striatum into caudate and lentiform nuclei and formation of internal capsule (B).

***N.B.** The cerebral hemisphere starts growing/expanding in the region of interventricular foramen. It grows rapidly forwards (forming frontal lobe), dorsally (forming parietal lobe), posteriorly (forming occipital lobe), and then anteroinferiorly (forming the temporal lobe). This curved pattern of expansion of cerebral hemisphere from the interventricular foramen around the diencephalon causes structures related to it (viz. lateral ventricle, corpus callosum, fornix, choroid fissure, caudate nucleus) to acquire the C-shaped forms.*

The **three meninges/membranes** (i.e. *pia mater*, *arachnoid mater*, and *dura mater*) surrounding the brain and spinal cord are derived from mesenchyme surrounding the neural tube. However, according to some workers the *pia mater* and the *arachnoid mater* (*leptomeninges*) are derived from neural crest and

not from mesenchyme.

Clinical Correlation

The mitotic activity within the neural tissue is completed during prenatal development. Thus, a person is born with all the neurons he was destined to have. However the nervous tissue continues to grow and specialize even after birth, particularly in the initial several years of postnatal life.

Clinical Problems

1. A newborn baby has no cranial vault, and its brain substance is exposed to the surface as an irregular degenerated mass. Name the congenital anomaly and mention whether a physician can detect it antenatally (i.e. before birth).
2. Why is anencephalic fetus associated with **hydramnios**?
3. What do you understand by **meningocele**, **meningoencephalocele** and **meningohydroencephalocele**? Mention their embryological basis.
4. What do you understand of a clinical condition called **spina bifida** and its several forms? Mention their embryological basis.

Clinical Problem Solving

1. This is a typical case of **anencephaly**, where brain tissue and associated vault of skull fail to develop due to failure of closure of anterior neuropore. A physician can detect this anomaly: (a) by ultrasonography in the later part of the pregnancy or (b) by detecting the alpha-fetoprotein (AFP) level of the amniotic fluid after transabdominal amniocentesis.

N.B. The level of alpha-fetoprotein is raised in anencephaly.

2. The amniotic cavity is normally filled with clear watery fluid derived mainly from maternal blood and partly from amniotic cells and amounts to about 300–1000 ml at 37th week of gestation.
From the beginning of the 5th month the fetus swallows about 400 ml of fluid every day. The swallowed fluid is absorbed through the gut and passes into the maternal blood. In anencephalic baby the swallowing reflex does not develop due to defective development of the brain leading to excessive accumulation of amniotic fluid (1500–2000 ml). It is termed **hydramnios**.
3. These are the congenital malformations of the nervous system which occur due to defective ossification of the skull bones, particularly the squamous part of the occipital bone.
A gap in the skull caused by defective ossification makes the meninges surrounding the

brain to bulge out of cranial cavity producing meningocele. If the defect is large, a part of brain tissue may also herniate producing **meningoencephalocele**. If the herniated part of the brain contains a part of ventricular cavity it is termed **meningohydroencephalocele**.

4. The **spina bifida** is a congenital malformation produced due to failure of the fusion of vertebral arches. Consequently the vertebral canal (also called spinal canal) remains defective posteriorly. Depending upon the herniation of structures present within the spinal canal through the defect, it is classified into following forms:
- **Spina bifida occulta:** No herniation of structures of spinal canal through the gap. A tuft of hair is often present over the skin at the site of defect.
 - **Meningocele:** Meninges surrounding the spinal cord bulge out through the defect in the vertebral arches, forming a cystic swelling beneath the skin containing cerebrospinal fluid.
 - **Meningomyelocele:** Spinal cord and spinal nerve roots also herniate along with the meninges if the defect is large.
 - **Rachischisis:** The neural tissue is exposed to the surface. It is in fact due to failure of fusion of caudal neuropore (*see page 2*).

Organization and Functions of the Nervous System

Neuroanatomy is the study of the nervous system. The nervous system is the most complex, widely investigated and least understood system in the body. It along with endocrine system regulates the functions of all other systems of the body. Hence nervous system is also called **master system of the body**.

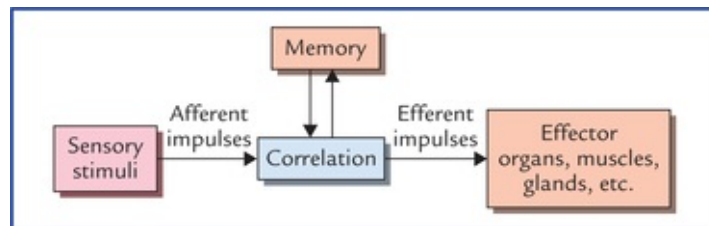
The functions of the nervous system include:

- Reception of sensory stimuli from internal and external environments.
- Integration of sensory information.
- Coordination and control of voluntary and involuntary activities of the body.
- Assimilation of experiences, a requisite to memory, learning and intelligence.
- Storage of experiences to establish pattern of responses in future, based on prior experience.
- Programming of basic instincts.*

N.B. The brain, “the divinest part of the body” is involved in much more than these functions such as thoughts and aspirations. The thought processes of brain have devised technology for making computer, launching rockets into space, etc.

The nervous system consists of three basic functional types of neurons: sensory, motor and interneurons. The sensory neurons detect stimuli and motor neurons send commands to the effector organs. The interneurons confer on the nervous system its prodigious capacity to analyse, integrate and store information.

The mechanism of functioning of the nervous system is as follows: The sensory stimuli (afferent impulses) received from inside or outside the body are correlated within the nervous system and then coordinated motor response (motor impulses) is sent to the effector organs (muscles, glands, etc.) so that they work harmoniously for the well-being of the individual ([Flowchart 2.1](#)).



FLOWCHART 2.1 Mechanism of working of the nervous system.

Divisions of Nervous System

Anatomical

Anatomically the nervous system is divided into two parts, the central nervous system and the peripheral nervous system (Fig. 2.1).

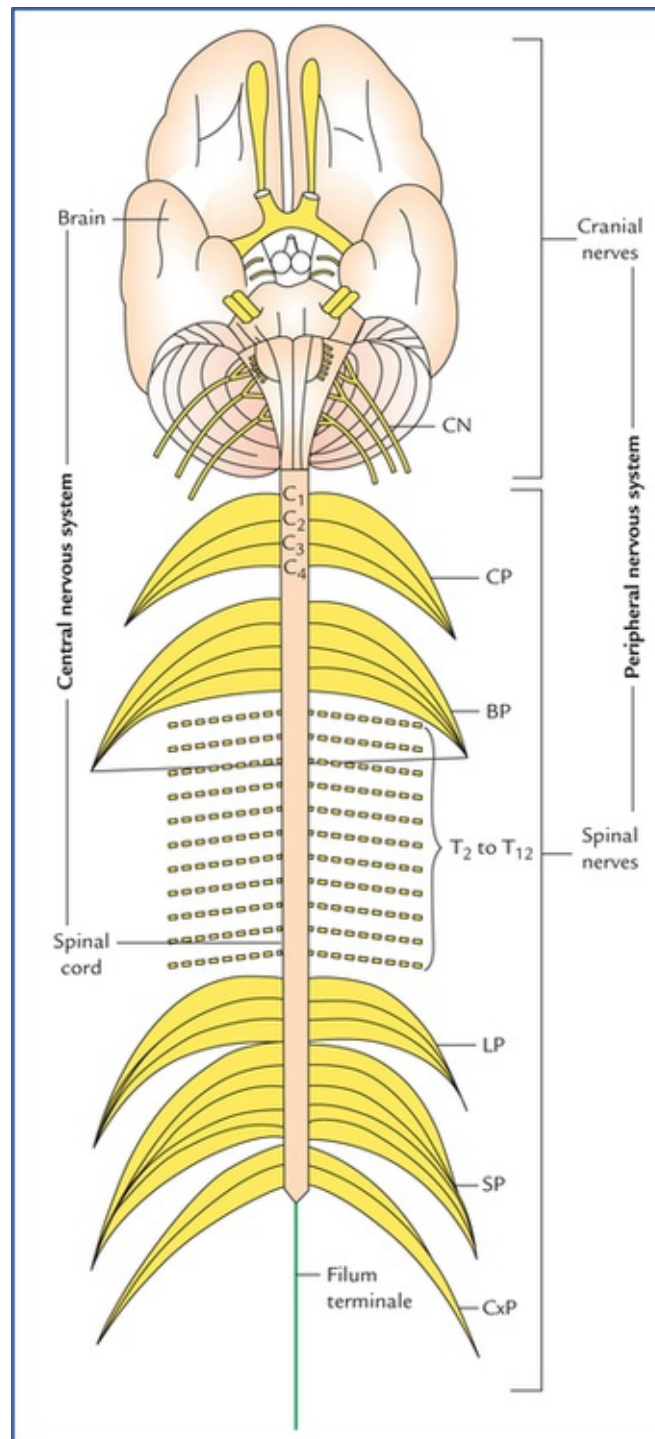


FIG 2.1 Anatomical divisions of the nervous system. The central nervous system consists of brain and spinal cord. The peripheral nervous system consists of cranial nerves which arise from the brain, and spinal nerves which arise from the spinal cord. (CP = cervical plexus, BP = brachial plexus, LP = lumbar plexus, SP = sacral plexus, CxP = coccygeal plexus, CN = cranial nerves.)

- The **central nervous system** (CNS) consists of brain and spinal cord. The brain is located within the cranial cavity and the spinal cord within the vertebral canal. The CNS is responsible for integrating, processing, and coordinating sensory data, and giving appropriate motor commands. It is also the seat

of higher functions such as intelligence, memory, learning, and emotions.

- The **peripheral nervous system** (PNS) includes all the neural tissues outside the CNS, such as 12 pairs of cranial nerves, 31 pairs of spinal nerves, and ganglia associated with cranial and spinal nerves. The PNS provides sensory information to the CNS and carries its motor commands to the peripheral tissues and systems.

Functional

Functionally also the nervous system is divided into two parts, the afferent division and the efferent division (Fig. 2.2).

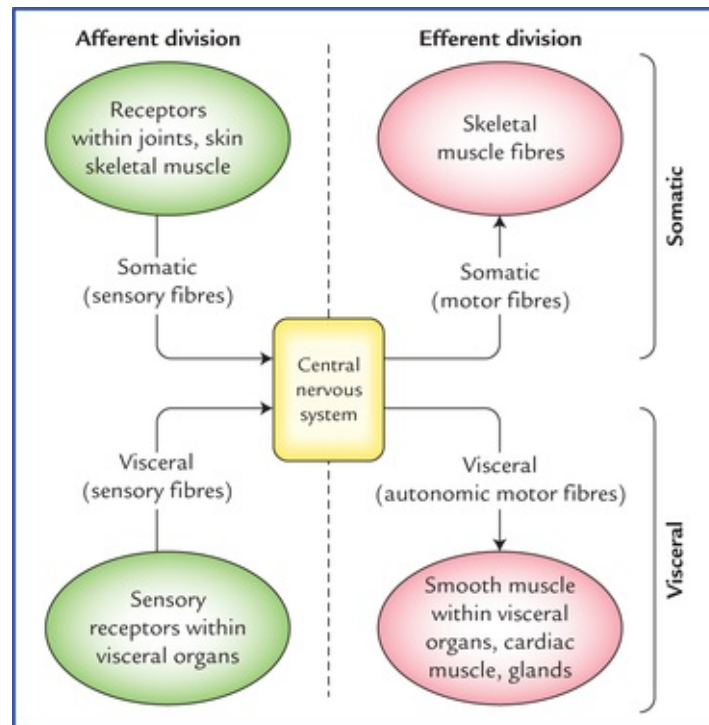


FIG. 2.2 Functional subdivisions of the nervous system.

- The **afferent division** brings sensory information to the CNS.
- The **efferent division** carries motor commands to the muscles and glands.

The efferent division has somatic and visceral components constituting somatic and autonomic nervous systems, respectively.

- *The somatic nervous system* (SNS) provides the voluntary control over the skeletal muscle contraction.
- *The autonomic nervous system* (ANS) innervates involuntary structures, such as heart, smooth muscle and glands and thus provides an involuntary regulation of smooth muscle, cardiac muscle, and glandular activity.

N.B. *The afferent division brings sensory information to the CNS. The CNS interprets the sensory information and sends commands through the efferent division to produce a response.*

Cellular Organization of the Nervous System

The highly specialized and complex nervous system consists of only two principal categories of cells, (a) neurons, and (b) neuroglia.

- **Neurons** form the basic structural and functional units of the nervous system. They are excitable cells which are specialized for reception of stimuli and the conduction of nerve impulses.
- **Neuroglia** or **glial cells** are supportive cells that support the neurons both structurally and functionally. The neuroglia are five times more abundant than the neurons and account for more than half of the weight of the brain.

Neurons (Neuro, Nerve)

The neurons are the structural and functional units of the nervous system. They are specialized for reception, integration, interpretation and onward transmission of information. They conduct nerve impulses over long distances at great speeds. The nervous system consists of vast number (about 10^{12}) of neurons.

Each neuron consists of a cell body (also called *soma* or *perikaryon* or *nerve cell body*) and its processes called **neurites**.

The typical neuron has a single long process called **axon** and many short processes called **dendrites** (Fig. 2.3).

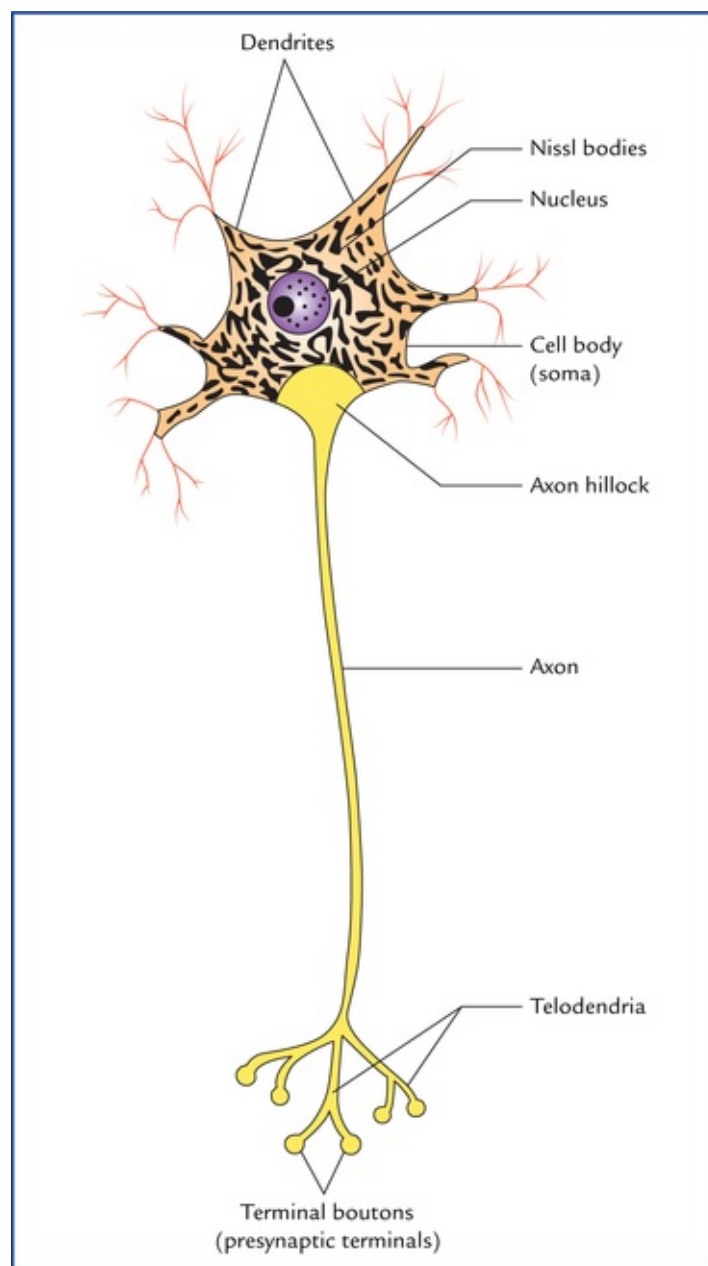


FIG. 2.3 A neuron. Note that Nissl substance is distributed throughout the cytoplasm of the cell body except in the region close to axon called axon hillock. It extends into the dendrites but is lacking in the axon.

The axon does not branch freely except at its termination; although it does give off side branches as collaterals by which it establishes interconnections with the other neurons. The axon conducts impulses away from the cell body.

The dendrites receive stimuli and conduct nerve impulses to the nerve cell body. The dendrites often branch profusely and form a major part of the receptive area of the neuron.

***N.B.** The collections of nerve cell bodies within the CNS are called **nuclei**, and outside the CNS **ganglia**. The axons are generally referred to as **nerve fibres**.*

Classification of neurons (types of neurons)

The neurons exhibit considerable diversity in form and function. Therefore, they are classified structurally as well as functionally.

Anatomical (morphological) classification

According to polarity (Fig. 2.4)

- **Pseudounipolar neurons.** These neurons possess oval or rounded cell body. A single process emerges from the cell body and after a short convoluted course bifurcates at a T-junction into peripheral and central processes. They are called *pseudounipolar neurons* because it is thought that the two processes of the bipolar neurons, during the process of differentiation, are approximated and finally fused near the cell body to form a single process. Thus, it appears that the neurons possess a single process bifurcating in a T-shaped manner, a short distance from the cell body. Such neurons are found in dorsal root ganglia of spinal nerves and sensory ganglia of some cranial nerves.

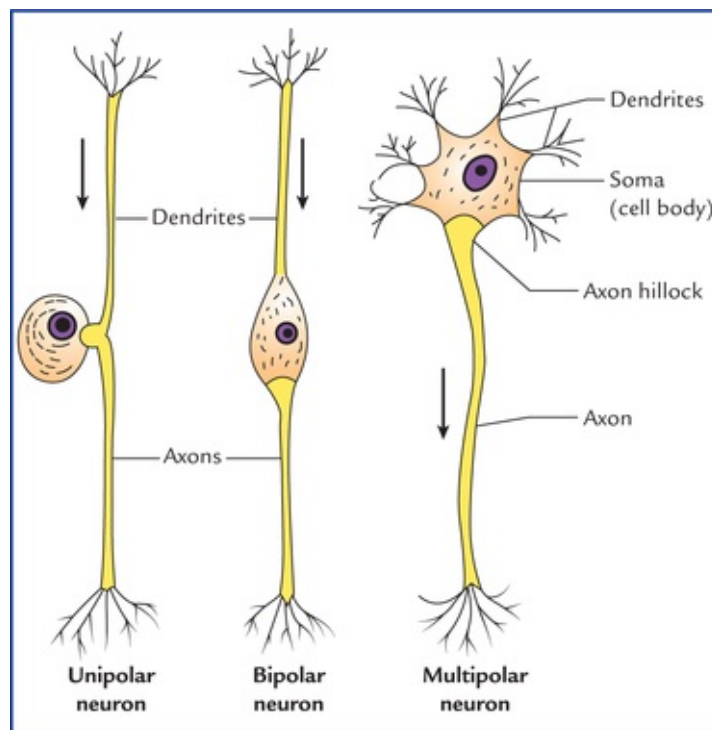


FIG. 2.4 Three basic morphological types of neurons. The arrows indicate the usual direction of impulse transmission.

- **Bipolar neurons.** They possess spindle-shaped cell body, from each end of which a single neurite (process) emerges. Thus, bipolar neurons have two processes, one dendrite and one axon, with the soma between them. Such neurons are found in olfactory epithelium of nasal cavity, retina of eyeball and sensory ganglia of cochlear and vestibular nerves.
- **Multipolar neurons.** Have multipolar cell body from which emerges several dendrites and a single axon. Most of the neurons in the body especially those in CNS belong to this category. For example, all the motor neurons that control skeletal muscles are multipolar neurons.

In fact multipolar neurons make up almost entire neuronal population of the CNS. Due to presence of several dendrites and their elaborate primary and secondary dendritic branches, these neurons enormously increase their synaptic surfaces.

N.B. In addition to three main morphological types of neurons (vide supra), there are **unipolar neurons**, which are found only in the mesencephalic nucleus of the Vth cranial nerve.

According to relative lengths of axons and dendrites

- **Golgi type I neurons.** These neurons have long axons that may be one metre long in extreme cases and connect different parts of the nervous system. The axons of these neurons form the long fibre tracts of

the brain and spinal cord, and the nerve fibres of the peripheral nerves. The pyramidal cells of the cerebral cortex, Purkinje cells of the cerebellum and motor anterior horn cells of spinal cord are Golgi type I neurons. Their dendrites are short and numerous.

- **Golgi type II neurons (microneurons).** Axons of these neurons are morphologically similar to that of dendrites. This gives these cells a star-shaped appearance. They establish synaptic contacts with large number of neurons in their neighbourhood.

They are found in large numbers in cerebral cortex, cerebellar cortex and in the retina.

[Table 2.1](#) summarizes the morphological (anatomical) classification of neurons.

Table 2.1

Morphological classification of neurons

Morphology	Location and example
According to polarity	
• Unipolar/pseudounipolar	Posterior root ganglia of spinal nerves, sensory ganglia of cranial nerves
• Bipolar	Olfactory epithelium, retina, sensory ganglia of cochlear and vestibular nerves
• Multipolar	Central nervous system (motor cells forming fibre tracts of brain and spinal cord and peripheral nerves), autonomic ganglia
According to size of nerve fibre	
• Golgi type I	Pyramidal cells of cerebral cortex, Purkinje cells of cerebellum, anterior horn cells of spinal cord
• Golgi type II	Cerebral cortex, cerebellar cortex (stellate cells forming synaptic contacts with other neighbouring neurons)

Functional classification

- **Sensory neurons**

They carry impulses from the receptor organs to the CNS.

Types of sensory neurons

In relation to the general sensory pathways, they are classified into three types:

1. **Primary sensory neurons:** The cell bodies of these neurons lie outside the CNS except those of mesencephalic nucleus of fifth cranial nerve which lie within the CNS.
2. **Secondary sensory neurons:** The cell bodies of these neurons lie in the CNS.
3. **Tertiary sensory neurons:** The cell bodies of these neurons lie in the thalamus. For details see [Chapter 17](#).

- **Motor neurons**

They transmit impulses from the CNS to the muscles and glands. The cell bodies of these neurons lie within the CNS except those of postganglionic neurons of autonomic nervous system.

Types of motor neurons

In the **somatic nervous system** they are divided into two types:

1. **Upper motor neurons** have their cell bodies located in the cerebral hemisphere, viz. motor area of the cerebral cortex. They form the descending pathways of the brain and synapse with the motor neurons of the cranial nerve nuclei in the brainstem and motor neurons of the spinal nerves in the anterior horns of the spinal cord. The upper motor neurons are involved in the voluntary control of muscular activity.

2. **Lower motor neurons** have their cell bodies located in the brainstem and spinal cord.

The skeletal muscles are supplied by the motor neurons of the anterior horns in the spinal cord and in the motor nuclei of cranial nerves. These neurons form the final common pathway (*Sherrington*) for determining the muscle action and are collectively known as **lower motor neurons**.

In the **autonomic nervous system** also the motor neurons are divided into two types:

1. **Preganglionic neurons:** The cell bodies of these neurons lie in the brain and spinal cord.

2. **Postganglionic neurons:** The cell bodies of these neurons lie outside the CNS in lateral, collateral and terminal autonomic ganglia.

The common anatomical terms used for describing the nervous system are mentioned in [Table 2.2](#).

Table 2.2

Terms commonly used for describing nervous system

Terms	Definition
Nerve fibre	Axon
Nerve	Bundle of nerve fibres outside the CNS
Tract	Bundle of nerve fibres inside the CNS
Ganglion	Collection of nerve cell bodies outside the CNS
Nucleus	Collection of nerve cell bodies inside the CNS
Sensory neuron	Neuron that transmits impulses from a sensory receptor to the CNS
Motor neuron	Neuron that transmits impulses from the CNS to the effector organ, e.g. muscle
Somatic motor nerve	Nerve that stimulates contraction of skeletal muscles
Autonomic motor nerve	Nerve that stimulates contraction/inhibition of smooth and cardiac muscles; and that stimulates secretion of glands
Nerve plexus	Network of intercalated nerves

CNS = central nervous system.

Fine structure of a typical neuron (Fig. 2.5)

A typical neuron consists of three principal components: (a) a cell body, (b) dendrites, and (c) an axon.

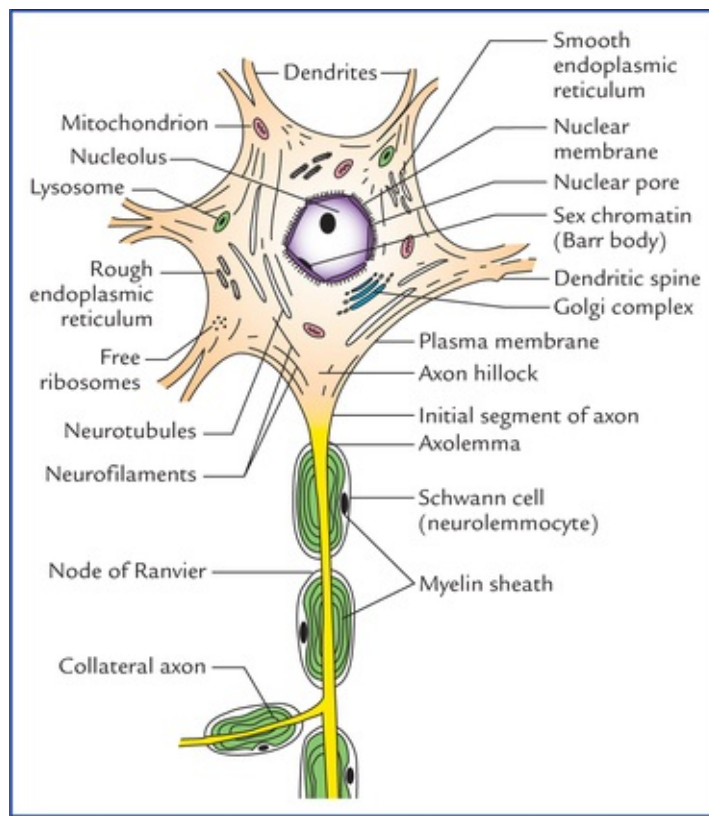


FIG. 2.5 Fine structure of a neuron. Note that the cytoplasm of the body is rich in rough and smooth endoplasmic reticulum and contains following organelles and inclusions: (a) Nissl substance, (b) Golgi apparatus, (c) mitochondria, (d) neurotubules, (e) neurofilaments, (f) lysosome, (g) centrioles, and (h) lipo-fuchsin, and melanin, glycogen and lipid.

- The **cell body** is an enlarged portion of the neuron. It consists of a mass of cytoplasm, surrounded by a plasma membrane. The cytoplasm contains a single relatively large and centrally located nucleus with prominent nucleolus.

The two main characteristic features of the cytoplasm of a neuron are: (a) the presence of **Nissl substance** (also called **Nissl bodies or granules**), and (b) **neurofibrils**.

The *Nissl substance* is composed of large aggregations of rough endoplasmic reticulum. The high concentration of rough endoplasmic reticulum is thought to be necessary for the production of enzymes involved in neurotransmitter synthesis. The Nissl substance extends into the dendrites but are absent in axon hillock and axon.

The *neurofibrils* represent the microfilaments and microtubules of the other cells of the body.

The electron microscopy reveals the presence of **neuro-tubules** and **neurofilaments** in the cytoplasm of a neuron. The neurotubules are made up of protein tubulin and course through the cell body into the neurites. These are concerned with the transport of large molecules along the neurites in either direction.

***N.B.** The centrosomes (centrioles) usually a feature of dividing cells has been observed in mature neurons incapable of division. They are possibly associated with the formation or maintenance of neurotubules.*

- The **dendrites** are highly branched short tapering processes which either end in the specialized sensory receptors as in primary sensory neurons, or form synapses with neighbouring neurons from which they receive stimuli. In some neurons the smaller processes of dendrites bear numerous minute projections called **dendritic spines** or **gemmules**. The dendrites conduct the nerve impulse towards the cell body—the **law of forward conduction** or the **law of dynamic polarity**.
- The **axon** arises from a cone-shaped portion of the cell body called **axon hillock**. The axon extends as

a cylindrical process of uniform diameter of variable length terminating on other neurons or effector organs by a variable number of small branches the **telodendria** which end in small swellings called **terminal boutons** or **presynaptic terminals** (Fig. 2.3).

The plasma membrane (plasmalemma) forms the continuous external boundary of the cell body and its processes.

In the neuron it is the site for the initiation and conduction of the nerve impulse.

The plasmalemma bounding the axon is called **axo-lemma**. The cytoplasm of the axon is called **axoplasm**.

N.B. The initial segment of axon (50-100 μm) after it leaves the axon hillock is the most excitable part of the axon and is the site at which an action potential originates.

Axon transport

The axon transports substances in both the directions in its axoplasm, i.e. away from the cell body, called **orthograde transport (anterograde flow)**, and towards the cell body, called **retrograde transport (retrograde flow)**. Thus, substances produced in the nerve cell body having many of the characteristics of a secretory cell can be passed along the axon to the area or tissue which it innervates, for example dopamine produced in the substantia nigra of midbrain is transported to the corpus striatum by nigrostriate fibres. Similarly, the materials absorbed from extracellular fluid by the axon terminals (by pinocytosis) can be transported to the cell body. This explains how the cell bodies of neurons respond to changes in the distal ends of the axons—a mechanism which may control the activity of nerve cell in relation to that of tissue which it innervates.

N.B. It is an amazing feat of biological engineering that different substances can move in different directions and at different rates through a very-very narrow tube—the axon.

Neuroglia

The neuroglia are the interstitial or supporting cells of the nervous system. They do not contribute to the propagation of impulses or the processing of the perceived information but support the neurons both structurally and functionally.

Neuroglia in the central nervous system

There are four main types of neuroglia (glial cells) in the CNS: (a) astrocytes, (b) ependymal cells, (c) oligodendrocytes, and (d) microglia (Fig. 2.6A).

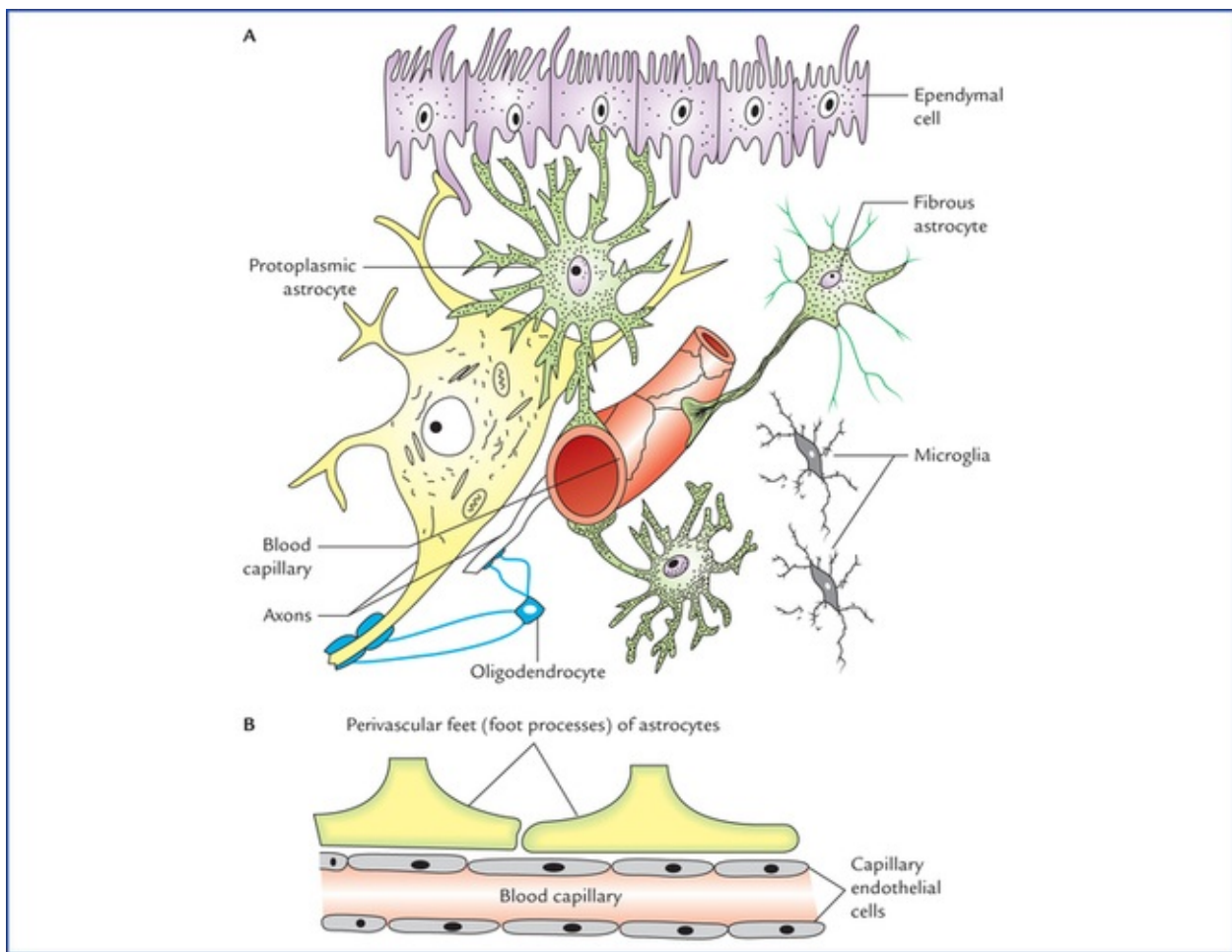


FIG. 2.6 (A) Four types of neuroglia found in the central nervous system. (B) The perivascular feet of astrocytes forming a sleeve around a capillary.

- **Astrocytes** are the largest and most numerous, and form the main supporting tissue of the nervous system. They are star-shaped as the name implies and possess many fine dendrite-like processes. At the ends of processes there are small swellings called *foot-processes*. Astrocytes are of two types: protoplasmic astrocytes and fibrous astrocytes.
 - The **protoplasmic astrocytes** are found in the grey matter. Their processes are thicker and more branched than fibrous astrocytes.
 - The **fibrous astrocytes** are found mainly in the white matter. Their processes are long, slender, smooth and less branched. Further, they contain more filaments in their cytoplasm as compared to the processes of protoplasmic astrocytes.

The astrocytes fill up most of the extracellular spaces among the neurons and their processes contact the surfaces of neurons and capillaries of the CNS. They are involved in the exchange of metabolites between the neurons and capillaries. The astrocytes are thought to be primary glycogen storehouse in the brain.

Astrocytes are found in large numbers adjacent to the blood capillaries with their foot processes, **perivascular feet** forming a sleeve around them (Fig. 2.6B). Thus, blood is separated from neurons by the capillary wall (endothelial cells) and a layer of astrocytic foot processes, which together constitute the **blood-brain barrier (BBB)** (for details see page 183).

Because of blood-brain barrier, only certain substances can pass from blood into the neurons, hence protecting them from toxic substances in the blood.

The astrocytes thus help regulate the passage of molecules from the blood to the capillaries.

- **Ependymal cells** line the ventricles of the brain and central canal of the spinal cord. Ependymal cells

are of three types: (a) ependymocytes, (b) choroid epithelial cells, and (c) tanocytes. The ependymocytes are cuboidal or columnar in shape with tuft of cilia on their luminal surfaces and constitute the majority of the ependymal cells. The specialized ependymal cells in choroid plexuses (choroidal epithelial cells) secrete cerebrospinal fluid. The cilia of ependymal cells assist in moving cerebrospinal fluid through the cavities of the brain.

The ependymal cells lining the floor of the fourth ventricle have long basal processes are termed 'tanocytes'.

- **Oligodendrocytes** are smaller than astrocytes and as the name implies have fewer processes. They are found (a) in clusters around the neurons of grey matter, and (b) adjacent to and along the length of myelinated nerve fibres in the white matter.

Oligodendrocytes form myelin sheath around axons in the CNS, having same function as Schwann cells in peripheral nervous system. A Schwann cell forms myelin sheath around a portion of one axon only whereas an oligodendrocyte, through its processes myelinates portions of several axons.

- **Microglia** are the smallest of the glial cells, and are capable of migrating through the surrounding neural tissue. Microglia do not develop in the neural tissue. They are derived from phagocytic white blood cells (fetal monocytes) that migrate from the blood into the nervous system before birth.

The microglia enlarges and become phagocytic in areas of inflammation and cell destruction. They remove cell debris, wastes and pathogens that invade the CNS by phagocytosis.

N.B. All the neuroglia (glial cells) are derived from ectoderm except microglia, which are derived from mesoderm.

Clinical Correlation

- Following death of the neurons the astrocytes proliferate and fill the spaces previously occupied by the neurons. This process is called **replacement gliosis**.
- The '**glioblastoma multiforme**', the most fatal tumour of brain with life expectancy of only 2 or 3 months, arises from astrocytes.
- Numerous microglia migrate to the areas of CNS that are damaged by infection, trauma or stroke to phagocytose the necrotic tissue. A pathologist therefore can identify these damaged areas of CNS during an autopsy, as large number of microglia is found in them.

Neuroglia in the peripheral nervous system

There are two types of glial cells in the PNS: satellite cells, and Schwann cells.

- **Satellite cells** or **amphicytes**, surround the nerve cell bodies in peripheral ganglia and provide support and nutrition to them.
- **Schwann cells** or **neurolemmocytes** form myelin sheath around axons in the peripheral nervous system. It is important to note that Schwann cells form neurilemma around all axons in PNS whether they are unmyelinated or myelinated.

N.B. Both neurilemma and myelin sheath are components of Schwann cells.

The types and functions of glial cells are summarized in [Table 2.3](#).

Table 2.3

Glial cells in the central nervous system and peripheral nervous system

Cell type	Functions
Central nervous system	
• Astrocytes	– Maintain blood-brain barrier, regulate ion, nutrient, and dissolved gas concentrations – Form scar tissue after injury
• Oligodendrocytes	Form myelin around CNS axons
• Microglia	Remove cellular debris, and pathogens in CNS by phagocytosis
• Ependymal cells	Line ventricles of the brain and central canal of the spinal cord. Assist in production, circulation and monitoring of cerebrospinal fluid
Peripheral nervous system	
• Satellite cells	Surround nerve cell bodies in peripheral ganglia
• Schwann cells	– Surround all axons in PNS – Responsible for myelination of axons in PNS – Participate in repair process after injury

Synaptic Transmission

In the nervous system, information moves from one location to another in the form of action potentials. An action potential travelling along an axon is called **nerve impulse**.

The nerve impulse is akin to a tiny electrical charge and forms the physiological unit of the nervous system.

Synapse

There is always more than one neuron involved in the transmission of a nerve impulse from its origin to its destination, whether it is sensory or motor. The neurons form long chains along which the impulses are conducted.

***N.B.** All the neuroglia are derived from ectoderm like neurons except microglia which are derived from mesoderm.*

The point at which the nerve impulse passes from one neuron to another is called synapse.

It is important to know that at synapse, the contact between the neurons is by contiguity and not by continuity (**neuron theory of Waldeyer, 1891**), and the impulse is transmitted across a synapse by a specific neurotransmitter.

The synaptic communication is the process by which neurons communicate among themselves and with the muscles and glands.

Classification of synapses

Depending upon the parts of two neurons forming a synapse, the synapses are of the following types:

1. **Axodendritic:** synapse between an axon and a dendrite.
2. **Axosomatic:** synapse between an axon and a soma.
3. **Axoaxonal:** synapse between two axons.
4. **Somatodendritic:** synapse between a soma and a dendrite.
5. **Somatosomal:** synapse between two somas and soma.
6. **Dendrodendritic:** synapse between two dendrites.

N.B. The most common synapse is between an axon of one neuron and the soma or dendrite of another neuron (i.e. axosomatic or axodendritic). The axodendritic synapse is generally termed typical synapse.

Structure of a synapse

Figure 2.7 presents the structure of an axodendritic synapse.

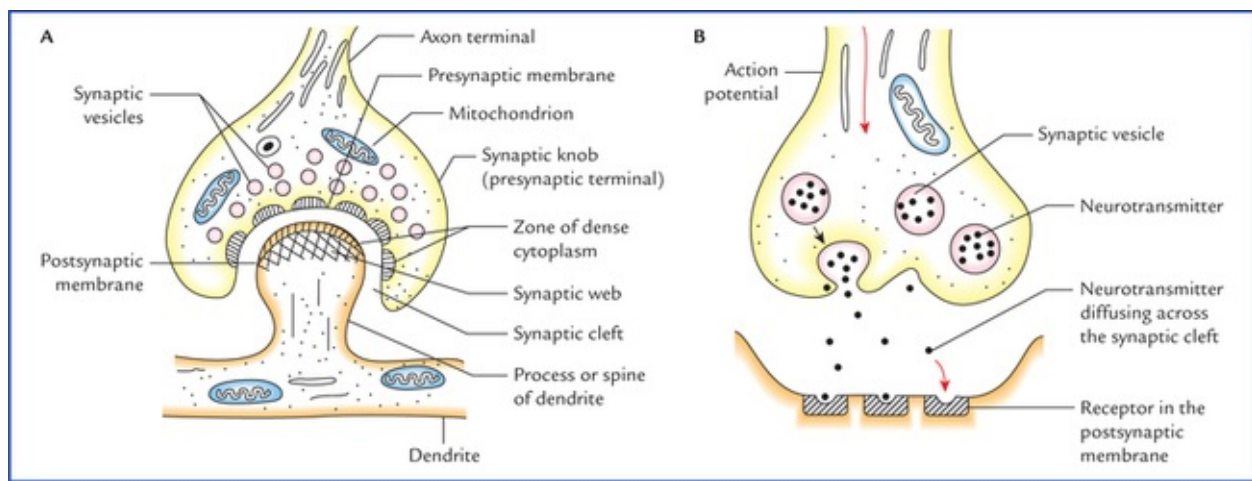


FIG. 2.7 (A) The structure of a typical synapse as seen under electron microscope. (B) The synaptic transmission. The neurotransmitter diffuses from the presynaptic terminal across the synaptic cleft to the receptors on the postsynaptic membrane.

At its free end the axon breaks up into minute branches which terminate in small swellings called **presynaptic knobs** or **boutons**. They lie in close proximity to the dendrites of the other neurons. The region of dendrite receiving the axon terminal is called **postsynaptic process**. The membrane opposed to the presynaptic knob is called **postsynaptic membrane**. The space between presynaptic knob and postsynaptic membrane is termed **synaptic cleft**, which is about 20 nm wide.

Thus, the essential anatomical components of a synapse are: the presynaptic knob, the synaptic cleft, and the post-synaptic membrane (Fig. 2.7A).

The granular material or delicate fibres may be seen within the synaptic cleft. On either side of the cleft there is a region of dense cytoplasm. On the presynaptic side the dense cytoplasm is broken up into several bits, whereas on the postsynaptic side the dense cytoplasm is continuous and is associated with a meshwork of filaments called **synaptic web**.

The thickened areas on the pre- and postsynaptic membranes constitute the active zone/zones of synapse for neurotransmission.

When the synaptic web is thick, the synapse is called *asymmetrical*, and when it is thin, the synapse is called *symmetrical*.

In most locations the inhibitory synapses are symmetrical and the excitatory synapses are asymmetrical.

Within the presynaptic knob are synaptic vesicles containing chemical transmitter called **neurotransmitter** which carry nerve impulses across the synaptic cleft. The neurotransmitter is secreted by nerve cells, actively transported along axon and stored in synaptic vesicles. Synaptic knob in addition to vesicles, contains endoplasmic reticulum and mitochondria.

The postsynaptic membrane contains the receptors for the neurotransmitter.

Mechanism of transmission of nerve impulse

Arrival of nerve impulse at terminal knob causes release of neurotransmitter into the synaptic cleft, which binds with receptors on the postsynaptic membrane. This binding produces response in the postsynaptic membrane, in the form of depolarization or hyperpolarization. The excitatory nerve impulse causes depolarization of postsynaptic membrane while an inhibitory impulse causes its hyperpolarization. If depolarization reaches threshold, an action potential is produced in the synaptic neuron. In this way, action potentials are transferred from one neuron to another neuron.

Neurotransmitters

Mostly the synaptic transmission is carried out by a chemical substance called **neurotransmitters**. The neurotransmitters produce either depolarization or hyperpolarization of post-synaptic membrane and their effects are termed excitatory or inhibitory respectively.

There are a number of neurotransmitters (Table 2.4) but **acetylcholine (ACh)** and **noradrenaline (epinephrine)** are the main ones.

Table 2.4

Neurotransmitters and their effects

Neurotransmitter	Typical effects
Acetylcholine	Excitatory
Amines	
• Noradrenaline	Excitatory
• Adrenaline	Excitatory
• Serotonin	Inhibitory
• Dopamine (DOPA)	Inhibitory
• Histamine	Inhibitory
Amino acids	
• Gamma-aminobutyric acid (GABA)	Inhibitory
• Glycine	Inhibitory
• Glutamate	Excitatory
• Aspartate	Excitatory
Neuropeptides	
• Substance P	Excitatory
• Endorphins	Inhibitory
• Enkephalins	Inhibitory

The synapses releasing the acetylcholine are known as the **cholinergic synapses** and those releasing the

noradrenaline, the **adrenergic synapses**.

The sequence of events at a typical cholinergic synapse is as follows:

- An arriving action potential depolarizes the presynaptic membrane.
- The calcium (Ca^{2+}) ion channels open and the calcium ions enter the cytoplasm of synaptic knob.
- The calcium ions cause synaptic vesicles to fuse with the presynaptic membrane and release their content (ACh) into synaptic cleft through exocytosis.
- ACh diffuses across the synaptic cleft and binds to receptors on the postsynaptic membrane.
- The sodium (Na^+) ion channels on the postsynaptic membrane open and sodium ions enter the cytoplasm of postsynaptic cell causing its depolarization.
- ACh release ceases because calcium ions are removed from the cytoplasm of synaptic knob.
- The depolarization ends as ACh is broken down into acetate and choline by an enzyme, acetylcholine esterase (AChE).
- The synaptic knob reabsorbs choline from the synaptic cleft and uses it to resynthesize ACh.

N.B. Adrenaline usually has an excitatory depolarizing effect on postsynaptic membrane, but the mechanism is quite distinct from that of ACh. For details consult textbooks on neurophysiology.

Properties of synapse

- The nerve impulse passes only in one direction, i.e. passage of impulse is unidirectional
- The passage of nerve impulse is slightly delayed at the synapse.
- The synapse is susceptible to fatigue.
- Certain substances released in the CNS can inhibit or facilitate the release of neurotransmitter by presynaptic inhibition or facilitation.
- The mechanism of transmission of nerve impulse at synapse is susceptible to certain drugs/chemical agents.

N.B. Knowledge of the actions of different neurotransmitters is important because drugs are available which may neutralize or prolong their effects.

Clinical Problems

1. A histopathologist while examining a nervous tissue under microscope can determine the sex of an individual.
2. The time of occurrence of rabies following a bite by an animal is less if the person is bitten in the body part nearer to the central nervous system, viz. in the face.
3. The people involved in skilled activities are very fond of taking tea or coffee.
4. The aged heart has decreased ability to pump faster and harder during exercise.
5. The tumour of neurons in the central nervous system is rare in adult individuals.

Clinical Problem Solving

1. The neurons of female individuals are characterized by the presence of a small stainable body of chromatin (**Barr body**) on the inner surface of the nuclear membrane.

It represents one of the two X-chromosomes present in the female. It is not seen in neurons of male as they contain only one X-chromosome. Thus, the presence or absence of the Barr body enables the histopathologists to determine the sex of an individual from whom the tissue has been taken.

N.B. The presence of Barr body was first noticed by Barr and Bertram in 1949.

2. The rabies is a fatal viral disease of the central nervous system. The virus is transmitted by the bite of an infected wild or domestic animal like dog. The virus is present in the saliva of the infected animal and following a bite, it travels to the CNS by way of axonal transport in nerves. The incubation period (i.e. period between the time of bite and appearance of symptoms) is related to the length of the peripheral nerves. The longer the nerve, the longer is the duration of the incubation period.

N.B. The virus causing poliomyelitis also travel from the gastrointestinal tract to the anterior horn cells of the spinal cord by an axonal transport.

3. The synaptic transmission is affected by various drugs. The caffeine present in the coffee and tea increases the rate of transmission at synapse with subsequent stimulatory effect on the central nervous system.
4. The number of Ca^{2+} ion channels in the presynaptic knobs of the nerve fibres that stimulate the heart decreases with age. As a result, less number of Ca^{2+} ions enter into the presynaptic knobs, causing a decreased release of neurotransmitter, which causes less stimulation of the heart, hence in old age the heart is not able to pump faster and harder during an exercise.
5. A tumour is an expanding lesion (swelling) due to uncontrolled proliferation of the cells. Since neurons are incapable of division in the postnatal life the tumours cannot arise from neurons in the adults (the mitotic activity of the nerve cells is completed during prenatal development).

*The basic instincts in humans are survival, eating, drinking, voiding, and sex (following puberty).

Peripheral Nerves and Ganglia

The peripheral nerve lesions are common in clinical practice and can be caused by a wide variety of diseases like trauma, neoplasms, infection, metabolic diseases (diabetes) and chemical toxins such as lead.

Therefore, it is of paramount importance for a physician to know the basic structure of peripheral nerves. Further, he also needs to know the structure and function of nerve fibres, and the process of their myelination, so that he could understand the mode of conduction of nerve impulses, and appreciate the process of nerve degeneration and regeneration.

Nerve Fibres

An axon of a nerve cell is termed **nerve fibre**. The bundles of nerve fibres found in the central nervous system (CNS) are referred to as **nerve tracts** while the bundles of nerve fibres found in the peripheral nervous system are called **peripheral nerves**. Two types of nerve fibres are present in the nervous system, viz. myelinated and non-myelinated.

Myelinated and Non-myelinated Nerve Fibres

In the peripheral nervous system, all axons (nerve fibres) are enveloped by the specialised Schwann cells which provide both structural and metabolic support to them.

In general, small diameter axons, for example those of the autonomic nervous system (ANS) and small pain fibres, are simply enveloped by the cytoplasm of Schwann cells; these nerve fibres are said to be **non-myelinated**. The large diameter fibres are wrapped by a variable number of concentric layers of Schwann cell plasma membrane forming the so-called **myelin sheath**, and such nerve fibres are said to be myelinated. Within the CNS, the myelination is similar to that in the peripheral nervous system except that the myelin sheath is formed by cells called oligodendrocytes.

Myelination (formation of myelin)

The myelination is the process by which nerve fibres acquire myelin sheaths which enhance the conduction of nerve impulses.

The process of myelination begins before birth in the late fetal period but is not complete until a year or more later after the birth.

Myelination of the peripheral nerve fibres (Fig. 3.1)

The myelination begins near the origin of the axon and ends just before its terminal branches.

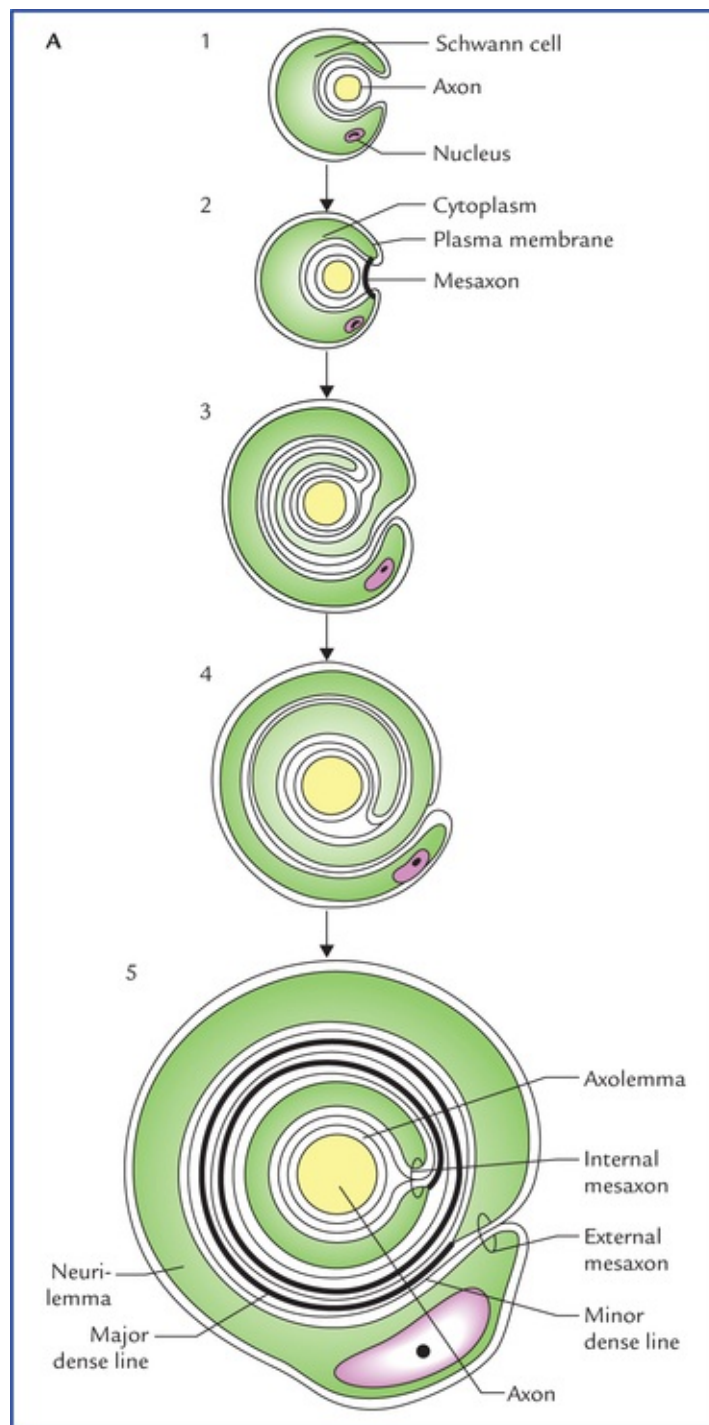


FIG. 3.1 Myelination. (A) Stages in the formation of myelin sheath. The axon invaginates the cytoplasm of the Schwann cell and becomes suspended by a mesaxon (1 and 2). The mesaxon elongates and bound around the axon spirally (3, 4 and 5).

The axon invaginates the side of a Schwann cell, as a result the plasma membrane of Schwann cell forms a **mesaxon**, which suspends the axon within the Schwann cell. The layer of plasma membrane immediately around the axon is continuous with the remainder of the plasma membrane through a double layered mesaxon (Fig. 3.1A).

The Schwann cell now rotates around the axon so that mesaxon becomes wrapped repeatedly around the axon forming spirals around it. As the process continues, the cytoplasm is extruded from the spirals into the Schwann cell body. On maturity, the inner layers of plasma membrane fuse with each other so that axon becomes surrounded by several layers of modified membrane which together constitute the myelin sheath. Thus, **myelin sheath** consists of many regular layers of plasma membrane material, which is predominantly white lipid protein, giving the myelinated axons a whitish appearance. It insulates the axon

from extracellular environment thus preventing ion fluxes across the plasma membrane of the nerve fibre/axon.

The thickness of myelin sheath depends on the number of spirals of Schwann cell membrane. In electron micrographs of cross-sections of myelinated nerve fibres, the myelin is seen to be laminated consisting of major and minor dense lines. The darker major dense line (about 2.5 nm thick) consists of two inner protein layers of the plasma membrane that are fused together. The lighter minor dense line (about 10 nm thick) is formed by the approximation of the outer surfaces of adjacent plasma membranes and is made up of lipid.

Each Schwann cell extends for a short distance along the nerve fibre and at its termination its role is supplemented by another Schwann cell with which it interdigitates closely.

In the CNS, oligodendrocytes responsible for the process of myelination, follows the similar pattern as of Schwann cell in the PNS; a single oligodendrocyte, however, forms the myelin sheath around several axons.

A myelinated nerve fibre, therefore, consists of an axon, a myelin sheath and a neurilemmal/Schwann sheath. The myelin sheath is segmented, the segments being separated at regular intervals by **nodes of Ranvier**. The areas between the nodes are called **internodes**.

Functions of the myelin sheath

- Provides support to the nerve fibres.
- Aids in conduction of the nerve impulses.
- Insulates an axon from the extracellular environment.
- Responsible for the colour of the white matter of the brain and spinal cord.

The **non-myelinated fibres** are also surrounded by Schwann cells (Fig. 3.2). Several axons become longitudinally invaginated into the cytoplasm of a Schwann cell so that each fibre is embedded in a groove in the Schwann cell cytoplasm. The Schwann cell plasma membrane fuses along the opening of the groove, thus effectively sealing the nerve fibre within an extracellular compartment. As many as 15 or more axons may share a single Schwann cell.

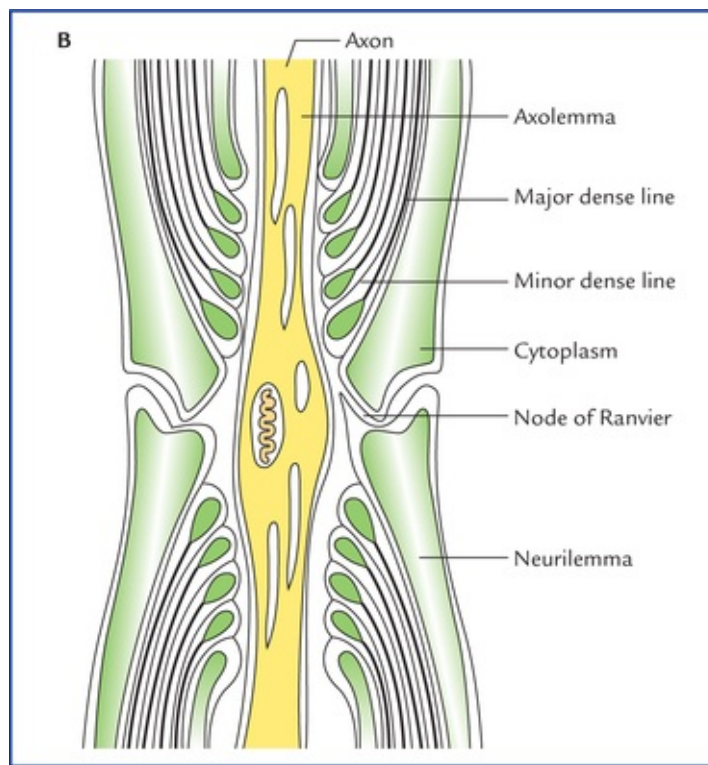


FIG. 3.1 (B) The longitudinal section of the myelinated nerve showing fine structure of the node of Ranvier.

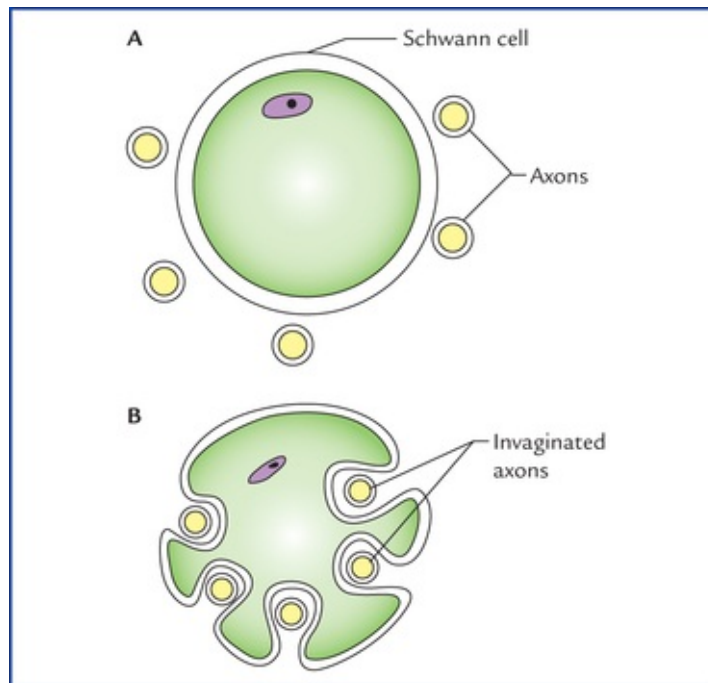


FIG. 3.2 Relationship of several non-myelinated axons to a Schwann cell. (A) Axons lying near the plasma membrane of a Schwann cell. (B) The axons are longitudinally invaginated into the cytoplasm of Schwann cell.

Each axon is surrounded by a single layer of plasma membrane of schwann cell, hence it is unmyelinated. There are no nodes of Ranvier. Consequently the action potential travels along the whole length of axolemma without the accelerating factor of node-to-node (saltatory) conduction. This accounts for slow rate of conduction of nerve impulse in the unmyelinated fibres.

Conduction of Action Potential along an Axon

Like all the cells, the resting (unstimulated) neuron maintains an ionic gradient across its plasma membrane, thereby creating an electrical potential called **resting membrane potential**. Thus, in resting neuron its plasma membrane remains polarized. The excitability (a fundamental property of neurons) involves a change in membrane permeability in response to appropriate stimuli so that the ionic gradient across the plasma membrane is reversed and the plasma membrane becomes depolarized. A wave of depolarization known as **action potential** then spreads along the plasma membrane. This is followed by the process of repolarization in which membrane rapidly re-establishes its **resting potential**.

The speed of conduction of the action potential, along an axon depends on the myelination of the axon (Fig. 3.3). The action potentials are conducted more rapidly in myelinated than in non-myelinated axons. In non-myelinated fibres, the action potential passes continuously along the axolemma, progressively exciting neighbouring areas of membrane. In myelinated fibres, the myelin sheath serves as an insulator. Consequently a myelinated nerve fibre can be stimulated only at the nodes of Ranvier, where the axon is naked and the ions can pass freely through the plasma membrane between the extracellular fluid and the axo-plasm. Therefore, in these fibres the action potential jumps from one node to the next. The action potential at one node sets up a current in the surrounding tissue fluid, which quickly produces depolarization at the next node. The action potential conduction in a myelinated fibre is like a *grasshopper jumping*, whereas action potential conduction in a non-myelinated fibre is like a *grasshopper walking*. The action potential will naturally move more rapidly by jumping.

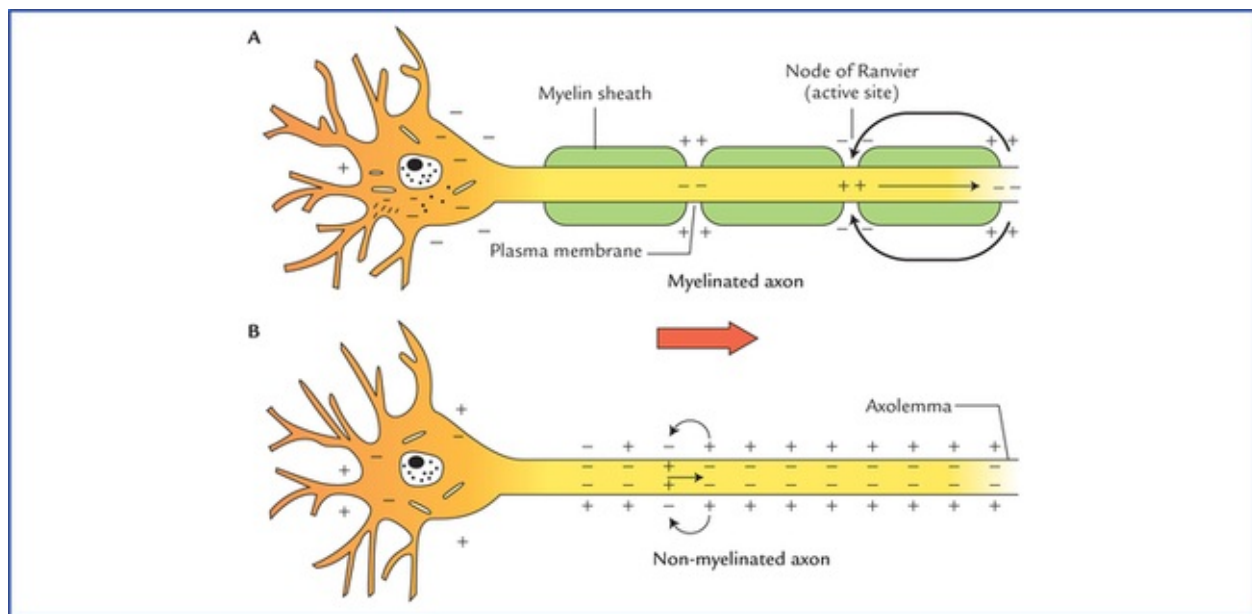


FIG. 3.3 The conduction of action potential along an axon. (A) In myelinated axon the action potential is conducted from one node of Ranvier to another (*saltatory conduction*). (B) In non-myelinated axon the action potential is conducted along the entire length of the axon.

This leaping of the action potential from one node of Ranvier to another in the myelinated nerve fibres is called **saltatory conduction** (L. *saltare* = to leap).

In addition to myelination, the diameter of axons affects the speed of conduction of action potential. The conduction of action potential is faster along large diameter axons than small diameter axons because large diameter axons provide less resistance to action potential propagation. In the large motor fibres (alpha fibres), the rate of conduction may be as high as 70-120 meters per second.

The smaller sensory fibres have slower conduction rate (Table 3.1).

Tabel 3.1

Classification of peripheral nerve fibres

Type of fibres	Fibre diameter (µm)	Speed of conduction (metres per second)
Group 'A' fibres		
• Afferent fibres		
– Group I: from 'annulospiral' endings of muscle spindles, (Ia) and Golgi tendon organs (Ib)	20	120
– Group II: from 'flower-spray' endings in muscle spindles, touch and pressure receptors	15	90
– Group III: from pain and temperature receptors	7	30
• Efferent fibres		
– α Fibres: supply extrafusal muscle fibres	17	120
– β Fibres: few in number, supply extrafusal muscle and muscle spindles	12	70
– γ Fibres: supply intrafusal muscle fibres (of muscle spindles)	8	30
Group 'B' fibres: preganglionic autonomic	3	15
Group 'C' fibres: postganglionic autonomic, also visceral and somatic afferents for pain and temperature sensations	1.5	2

Clinical Correlation

The process of myelination begins before birth (late in the fetal development), and continues rapidly until the end of first year after birth and continues more slowly thereafter. Thus, the development of myelin sheath is associated with the infant's continuing development of rapid and better coordinated responses. For example, the fibres of corticospinal tract which control the reflex emptying of urinary bladder get myelinated and begin to function at 3-6 years of age. Therefore reflex emptying of bladder and **enuresis** (bed-wetting) is normal in infants.

Classification of Peripheral Nerve Fibres

According to the axonal diameter (including myelin sheath if present) and speed of conduction, the peripheral nerve fibres are classified into three main groups: A, B and C.

- **Type A fibres** are large diameter, myelinated axons and therefore conduct action potentials at a great speed (15 – 120 m/sec). Motor neurons supplying skeletal muscles and most sensory neurons have type A fibres. Consequently, rapid response to external stimuli is possible as there is rapid input of sensory information to CNS on one hand and rapid output of action potential to skeletal muscle on the other hand.

N.B. All types of fibres in group A and B are myelinated whereas group C fibres are non-myelinated.

- **Type B fibres** are medium-diameter, myelinated axons and conduct action potentials at a slow speed (3-15 m/sec).
- **Type C fibres** are small-diameter non-myelinated axons that conduct action potentials at a very slow speed (2 m/sec or less).

The type B and C fibres are primarily found in the ANS, which supplies internal organs such as stomach, intestine. The responses necessary to maintain internal homeostasis such as digestion need not be as rapid as to external environment.

The group A fibres are further classified into somatic sensory (I, II, III) and motor (a, (3, 7) subgroups. [Table 3.1](#) shows the types of nerve fibres and their maximum diameters and conduction rates.

Peripheral Nerves

The peripheral nerves comprise 12 pairs of cranial and 31 pairs of spinal nerves.

Most of these nerves are composed of both motor and sensory fibres, and therefore called **mixed nerves**. Some of the cranial nerves, however are composed of either sensory nerve fibres only (**sensory nerves**) or motor nerve fibres only (**motor nerves**).

The impulses enter or leave the CNS via the cranial and spinal nerves.

According to the area of innervation the nerve fibres within the spinal nerves may be classified into the following types ([Fig. 3.4](#)):

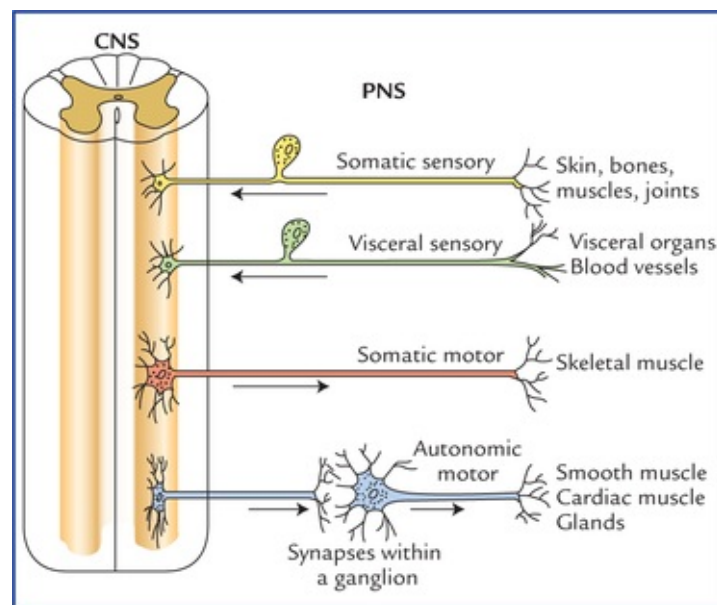


FIG. 3.4 Classification of the nerve fibres according to the area of innervation. Note the relationship of the sensory and motor fibres of the peripheral nervous system (PNS) with the central nervous system (CNS).

1. **Somatic sensory fibres:** convey nerve impulses from skin, bones, muscles and joints to the CNS.
2. **Somatic motor fibres:** carry nerve impulses from CNS to the skeletal muscles.
3. **Visceral sensory fibres:** convey nerve impulses from visceral organs and blood vessels to the CNS.
4. **Visceral motor fibres** (also called *autonomic motor fibres*): carry impulses from CNS to the cardiac muscle, glands, and smooth muscles within the visceral organs.

The types of nerve fibres present within the cranial nerves are described in [Chapter 9](#).

Cranial nerves

There are 12 pairs of cranial nerves which arise from brain and leave the cranial cavity by passing through the foramina in the skull. Three of these nerves (olfactory I, optic II, and vestibulocochlear VIII) are composed entirely of sensory (afferent) nerve fibres bringing sensations to the brain; five of them (oculomotor III, trochlear IV, abducent VI, accessory XI, and hypoglossal XII) are composed entirely of motor (efferent) fibres, while the remainder (trigeminal V, facial VII, glossopharyngeal IX, and vagus X) possess both sensory (afferent) and motor (efferent) fibres (for details, see [Chapter 9](#)).

Spinal nerves

There are 31 pairs of spinal nerves which arise from the spinal cord and pass through intervertebral foramina in the vertebral column. The spinal nerves are named according to the regions of the vertebral column with which they are associated. There are 8 cervical, 12 thoracic, 5 lumbar, 5 sacral, and 1 coccygeal nerves.

Typical spinal nerve

A typical spinal nerve arises from spinal cord by two roots: an anterior root and a posterior root ([Fig. 3.5](#)). The *anterior root* consists of bundles of nerve fibres which carry nerve impulses away from the spinal cord; these fibres are called **motor (efferent) fibres**. Their cells of origin lie in the anterior horn of the spinal cord.

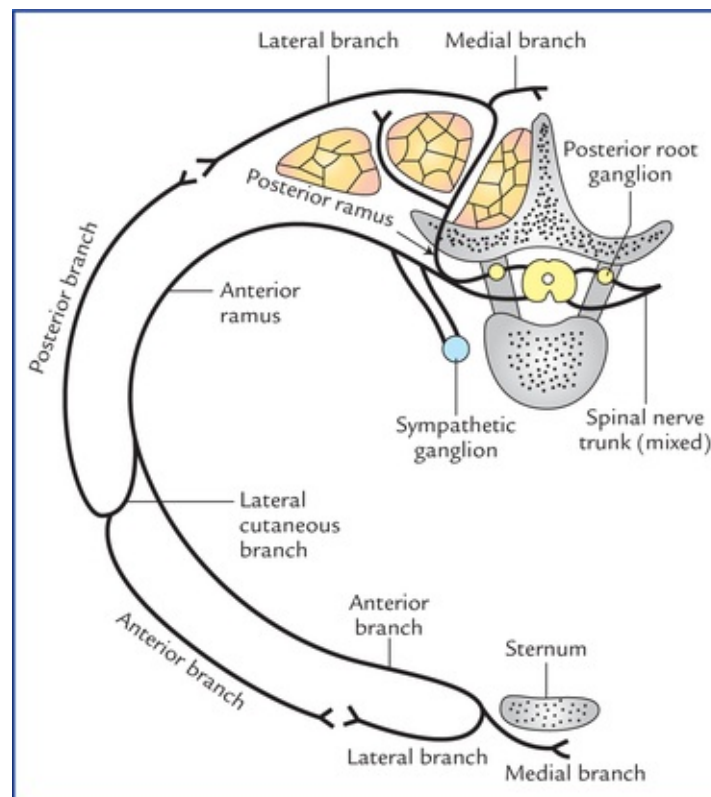


FIG. 3.5 A typical spinal (segmental) nerve.

The *posterior root* consists of bundles of nerve fibres which carry impulses to the spinal cord, these

are called **sensory (afferent) fibres**. The cell bodies of these nerve fibres are located outside the spinal cord in a swelling on the posterior root called *posterior root ganglion*. The posterior root ganglion is located in the intervertebral foramen.

The spinal nerve roots pass from the spinal cord to the intervertebral foramen, where they unite to form a spinal nerve. Thus, the spinal nerve is made up of both motor and sensory fibres.

After emerging from the intervertebral foramen, each spinal nerve first gives a *recurrent meningeal branch* which re-enters the vertebral canal to innervate the meninges, then it divides into a large anterior ramus and a smaller posterior ramus, each containing both motor and sensory fibres. The posterior ramus passes posteriorly around the vertebral column to supply the muscles and skin of the back. The anterior ramus runs anteriorly to supply the muscles and skin over the anterolateral part of the body wall.

The anterior ramus in its initial part is connected to the sympathetic ganglion by grey and white rami communicantes.

Plexus formation

Except for thoracic nerves from T3 to T11, the anterior primary rami of all the spinal nerves join together and/or branch to form a network of nerves known as **nerve plexus**. There are three major plexuses:

- **Cervical plexus** (Fig. 3.6), made up of C1 through C4 spinal nerves, innervates the muscles of neck and diaphragm.

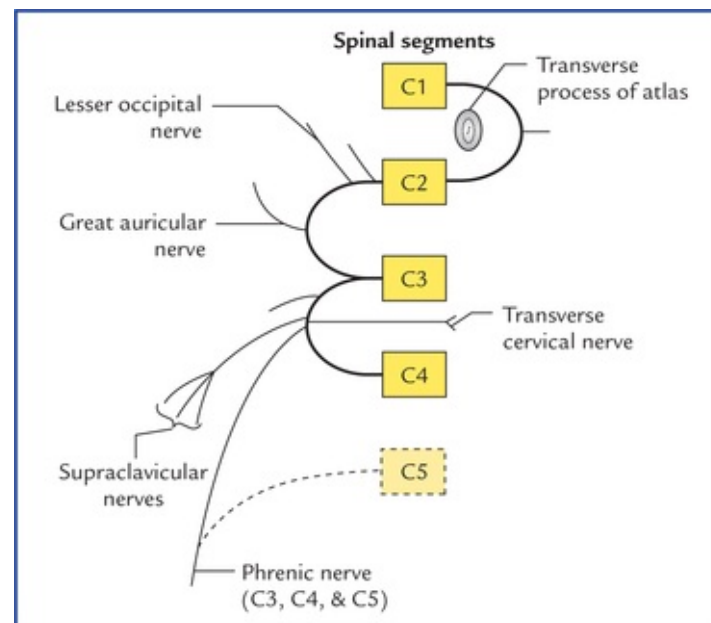


FIG. 3.6 Cervical plexus.

- **Brachial plexus** (Fig. 3.7), made up of C5 through T1 spinal nerves, innervates muscles of the upper limb.

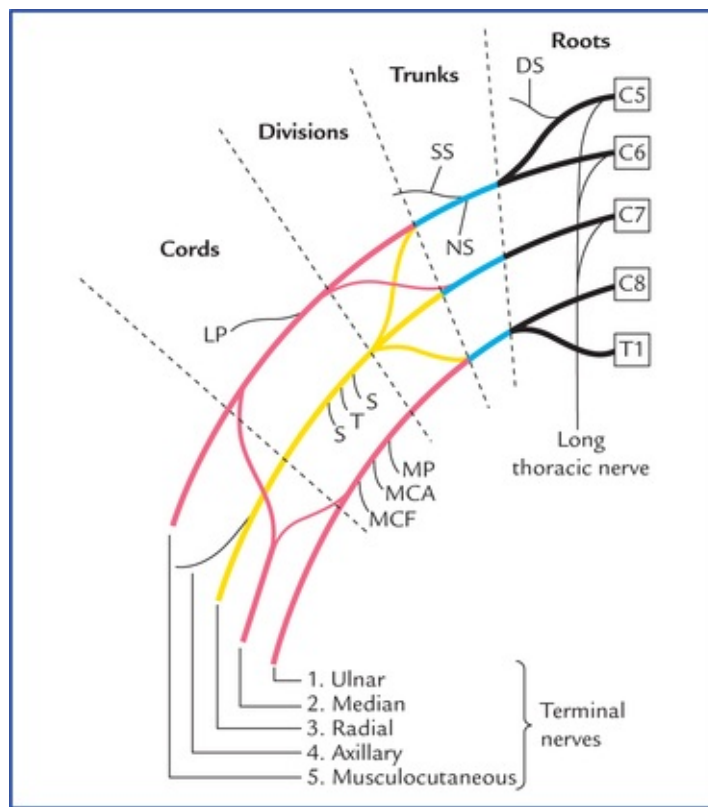


FIG. 3.7 Brachial plexus. (DS = dorsal scapular, SS = suprascapular, NS = nerve to subclavius, LP = lateral pectoral nerve, S = subscapular nerve, T = thoracodorsal nerve, MP = medial pectoral nerve, MCA = medial cutaneous nerve of arm, MCF = medial cutaneous nerve of forearm.)

- **Lumbosacral plexus** (Fig. 3.8), made up of L1 through S5 spinal nerves, innervates muscles of the lower limb. It is divided into two portions:

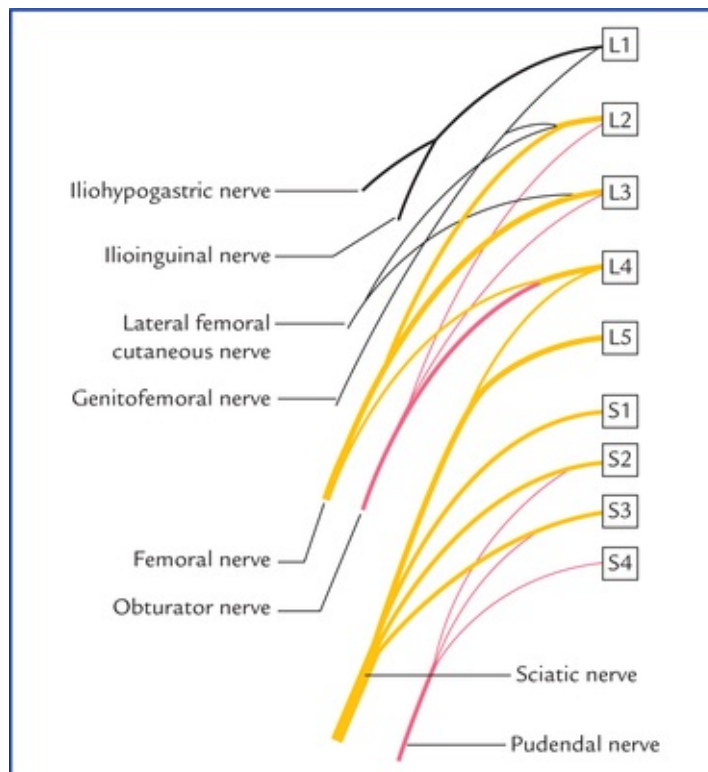


FIG. 3.8 The lumbosacral plexus.

- *Lumbar portion* (lumbar plexus) L1 through L4, supplies mostly muscles of the thigh.
- *Sacral portion* (sacral plexus) L5 through S5, supplies mostly muscles of leg and foot.

The branches arising from plexuses are also termed peripheral nerves.

The formation of nerve plexus allows individual nerve fibres to pass from one peripheral nerve to another. A nerve plexus thus permits a redistribution of nerve fibres within the different peripheral nerves.

The detailed description of these plexuses and peripheral nerves derived from them is beyond the scope of this book.

Structure of the Peripheral Nerve (Fig. 3.9)

Each peripheral nerve trunk consists of a number of nerve fibre bundles or fasciculi.

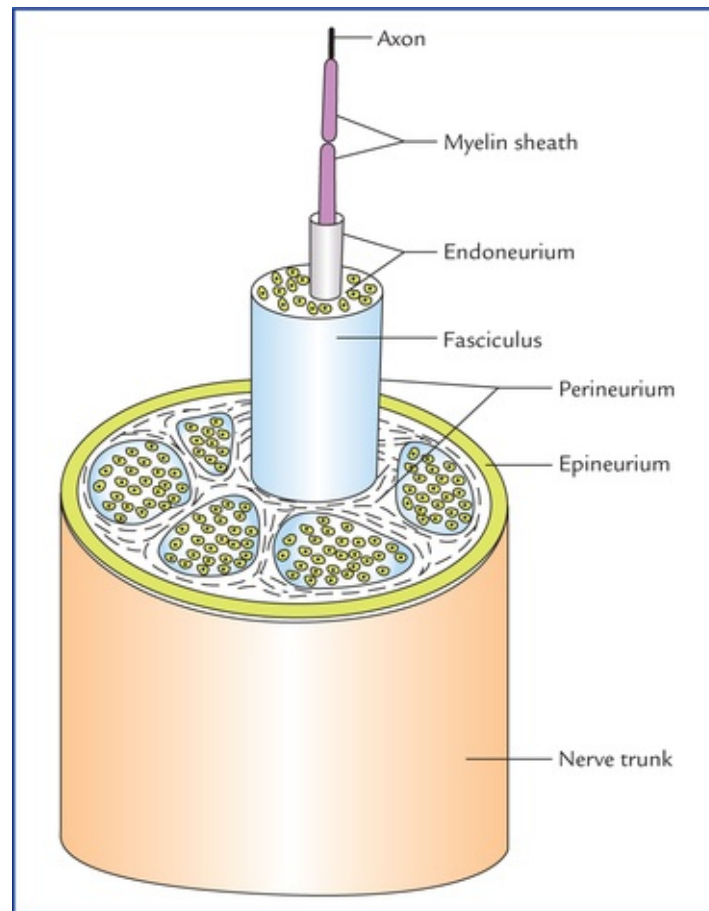


FIG. 3.9 The structure of a peripheral nerve showing three protective coverings.

There are three protective coverings of connective tissue in each nerve trunk:

1. **Endoneurium:** It is a loose delicate connective tissue that surrounds the individual nerve fibres. In fact it lies between the nerve fibres within a nerve bundle.
2. **Perineurium:** It is a smooth sheath, made up of a condensed layer of collagenous connective tissue that surrounds the bundle of nerve fibres.
3. **Epineurium:** It is a dense connective tissue sheath which surrounds and encloses the bundles of nerve fibres forming the nerve trunk (i.e. it surrounds the entire nerve). It contains tiny blood and lymph vessels.

The fibres within a peripheral nerve trunk derive considerable mechanical strength from these three layers of connective tissue.

Clinical Correlation

- The connective tissue of epineurium, perineurium and endoneurium is in continuity with each other. The blood capillaries and lymphatics ramify in this connective tissue. The major arterial occlusion in the limbs may cause severe pain due to **ischaemic neuritis**.
- The injuries of peripheral nerve are quite common and can occur due to compression, traction, trauma, injection, cuts, etc.

The nerve injuries are of three types:

1. **Neurotmesis**: In this both axon and its myelin sheath is damaged.
2. **Axonotmesis**: In this axon is damaged but its myelin sheath is preserved.
3. **Neuropraxia**: In this both axon and its myelin sheath are preserved.

Recovery can occur in cases of neuropraxia and axonotmesis but functional loss is inevitable in case of neurotmesis.

Degeneration and Regeneration of the Peripheral Nerves after Injury

Degeneration of the nerve fibre (Fig. 3.10)

When a nerve fibre is cut, the axon is no longer in continuity with its trophic centre*—the nerve cell body. The immediate reaction in the neuron is that of degeneration. The series of degenerative changes will take place: (a) in the nerve fibre—(i) the distal segment that is separated from the cell body, (ii) a portion of axon proximal to the injury, and (b) possibly in the cell body from which the axon arises.

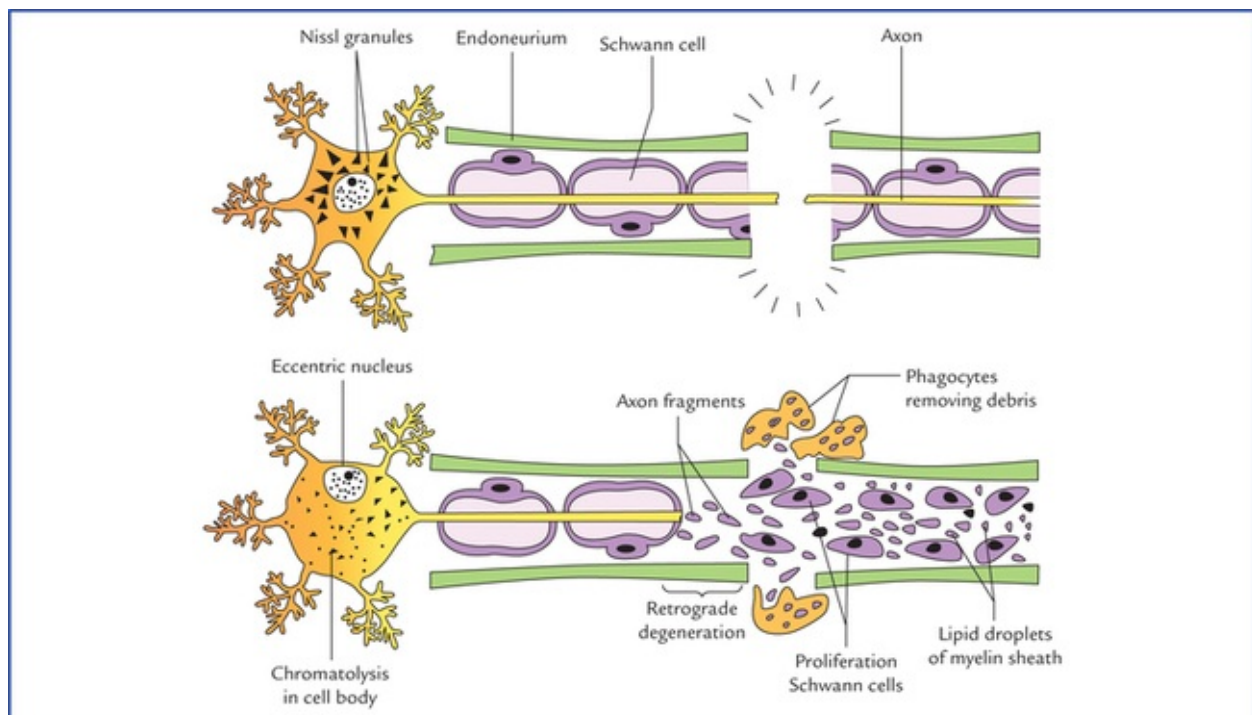


FIG. 3.10 Degeneration of a nerve fibre (Wallerian degeneration).

Changes in the nerve fibre

- The distal segment immediately undergoes degeneration from the site of lesion to its termination. This process of anterograde degeneration is called **Wallerian degeneration**.
- The degeneration also extends proximally from the site of lesion, for a short distance as far as the first node of Ranvier.

In the process of degeneration, parts of the axon distal and proximal to cut, disintegrate and their myelin sheaths break up into lipid droplets.

Changes in the nerve cell body

- The cell body swells and nucleus becomes eccentric.
- The Nissl bodies disintegrate and become fine and granular, and dispersed throughout the cytoplasm, a process known as **chromatolysis**.

The amount of swelling of the cell body and chromatolysis is greatest when the injury to the axon is close to the cell body. The changes that occur in the cell body following an injury to its axon are referred to as **retrograde degeneration**.

Regeneration of nerve fibre (Fig. 3.11)

Regeneration of nerve fibre usually begins two weeks after the injury. The various regenerative steps are as follows:

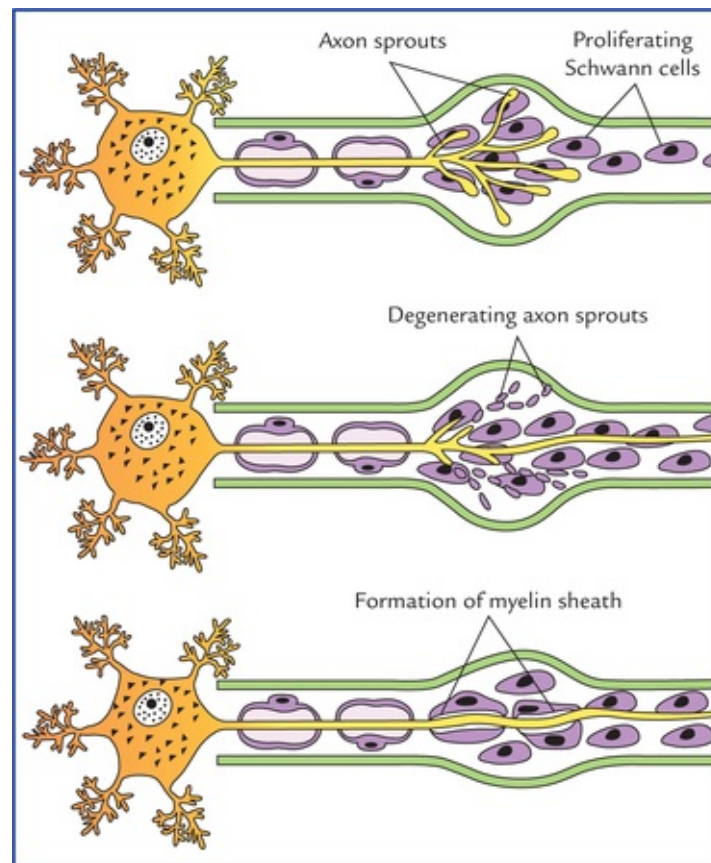


FIG. 3.11 Regeneration of a divided nerve.

- The macrophages migrate at the site of lesion and remove the debris by phagocytosis.
- The Schwann cells then proliferate and fill the endoneurial tube to form a solid cellular cord (column of

cells). The endoneural sheath and the contained cord of Schwann cells is known as **band fibre**.

A small gap that exists between the proximal and distal stumps is also filled by the proliferating Schwann cells. The macrophages probably secrete the substances the **nerve growth factors** that cause proliferation of Schwann cells.

The proximal axon now gives rise to multiple sprouts with bulbous tips that enter the proximal end of endoneural tube of distal segment.

The course of sprouts is guided by the cord of Schwann cells. Several sprouts from different axons may enter into one endoneural tube but only one of the sprouts from each axon persists, the remainders degenerate. The persisting sprout now grows distally to reinnervate a motor or sensory end organ.

If it stops growing or wanders in some new direction, the normal function will not return.

Factors necessary for satisfactory regeneration

- *Endoneural sheath should be intact, viz.* in crush nerve injuries, the axon is divided and its blood supply is interfered but the endoneural sheaths remain intact.
- *Distance between proximal and distal stumps should not be more than few millimetres.*
- *Infection should be absent at the site of wound.*
- *Presence of nerve growth factors.*
- *Proper physiotherapy:* Inadequate physiotherapy to the paralyzed muscles will cause their atrophy before it is reinnervated by the regenerating axons.

N.B. *The axon grows at the rate of 3.5 to 4.5 mm per day, and if the cut ends of the peripheral nerves are sutured the regeneration is facilitated.*

Clinical Correlation

- If a mixed nerve (containing sensory, motor and autonomic fibres) is cut, then during the process of regeneration, its autonomic, motor and sensory fibres may travel to an inappropriate peripheral end organs as the growing axon of one type may enter the endoneural tube of the other type. This results in inappropriate responses. The classical example is **Frey's syndrome**, a clinical condition in which when the patient eats, the ipsilateral cheek becomes red, hot and painful, followed by beads of perspiration. Further, there is hyperaesthesia in front and above the ear. This syndrome occurs following auriculotemporal nerve injury. What happens actually is that when the auriculotemporal nerve (a mixed nerve) is cut, the axons conveying secretory impulses to salivary glands grow into the endoneural tubes of axons supplying cutaneous receptors for pain, touch and temperature; and sympathetic axons supplying sweat glands and blood vessels. Consequently, a stimulus intended for salivary secretion during eating evokes cutaneous hyperaesthesia, sweating and flushing.
- If the distance between the proximal and distal stumps of the completely severed nerve is greater, or the gap becomes filled with the proliferating fibrous tissue or by adjacent muscular tissue that bulges into the gap. The growing axonal sprouts enter into the surrounding connective tissue and form a tangled mass called **neuroma**.

Ganglia (Swelling or Knot)

The collection of nerve cell bodies outside the CNS is called **ganglion**. They are of two types: (a) sensory ganglia, and (b) autonomic ganglia.

Sensory Ganglia

The sensory ganglia located on the dorsal roots of spinal nerves and on the trunks of some cranial nerves (trigeminal, facial, glossopharyngeal and vagus) have the same structure. Each ganglion has a connective tissue capsule surrounding the cell bodies of primary sensory neurons. These neurons are of unipolar (pseudounipolar) type having oval or rounded cell body. A single process leaves the cell body and after a short convoluted course bifurcates at a T-junction into peripheral and central processes. The peripheral process terminates in the peripheral receptors and the central process enters the CNS.

The peripheral process conducting impulses towards the cell body is functionally a dendrite but has the structural and physiological characteristics of an axon.

The impulses pass directly from the peripheral to the central process bypassing the cell body. Each nerve cell body is closely surrounded by a layer of flattened cells called **capsular cells** or **satellite cells**. The satellite cells are similar in structure to Schwann cells and separate the nerve cell bodies from the capillaries. They help to provide nutrition, and structural support to the nerve cells of ganglia.

Autonomic Ganglia

The autonomic ganglia are of two types: sympathetic and parasympathetic.

The **sympathetic ganglia** are located in the sympathetic chains present one on each side into the paravertebral region (**paravertebral ganglia**). They are also located in front of the vertebral column in the abdominal cavity— **prevertebral ganglia** (e.g. coeliac, superior mesenteric and inferior mesenteric ganglia).

The **parasympathetic ganglia** are located close to or in the walls of the viscera.

Each autonomic ganglion consists of a collection of mul-tipolar neurons, and is covered by a layer of connective tissue called capsule. The autonomic ganglia are the sites where preganglionic nerve fibres synapse on postganglionic neurons. They are relay stations in the visceromotor (auto-nomic motor) pathway. The preganglionic fibres are myelinated while the postganglionic fibres are non-myelinated.

Clinical Correlation

- **Peripheral neuropathy** (neuritis)

It is the most common disorder of the peripheral nervous system. It consists of degenerative changes in the peripheral nerves which produce sensory loss and motor weakness. The distal portions of the nerves are affected first, hence symptoms appears first in hands and feet (*glove and stocking paraesthesia*). There are multiple causes of peripheral of neuropathy, viz. nutritional deficiencies such as deficiency of vit. B₁, B₆ and B₁₂, toxins of various kinds such as drugs, alcohol, and metabolic disorders such as diabetes.

- **Entrapment syndromes**

They occur due to compression of peripheral nerves, e.g. compression of median nerve in the carpal tunnel (carpal tunnel syndrome).

- **Radiculopathy**

It occurs due to compression of nerve roots due to variety of disorders, e.g. spondylosis, disc prolapse, etc.

Clinical Problems

1. In patients with **multiple sclerosis** and **diabetes mellitus**, there is an impaired control of skeletal and smooth muscles. Why?
2. By what route the **tetanus toxin** travel from the site of wound to the central nervous system?
3. The injured nerve fibres in the peripheral nervous system are able to regenerate but in the central nervous system they fail to do so. Why?
4. A man on returning home after attending a party on Saturday night, slept on a hard chair the whole night with his right hand suspended over the edge of the chair back. Next day when he woke up, he found that he was not able to extend his right hand, but by end of the day his hand became normal without treatment. What is the likely diagnosis? Mention its anatomical basis.
5. If muscles are paralyzed following a nerve injury due to crush or traction, the recovery is rapid and nearly complete, but if the paralysis occurs due to complete section of a nerve trunk, the recovery is not possible at all. Mention the reason for this.

Clinical Problem Solving

1. In diseases like multiple sclerosis (skleros = hardening) and diabetes mellitus the myelin sheath is gradually destroyed. Consequently, the transmission of nerve impulse is slowed leading to an impaired control of the skeletal and smooth muscles.
2. The tetanus toxin travels from the site of wound to the CNS through the spaces in the endoneurium of nerve fibres.
3. The regeneration of nerve fibres is possible in the peripheral nervous system due to following factors:
 - (a) Presence of endoneural tubes.
 - (b) Presence of large number of Schwann cells.
 - (c) Presence of nerves growth factors (see [page 26](#)).

In the CNS also there is an attempt at regeneration of the axons as evidenced by sprouting of the axons, but the process ceases after 2 weeks due to the following factors:

- (a) Absence of endoneural tubes.
- (b) Failure of oligodendrocytes to serve in the same manner as Schwann cells. The oligodendrocytes in number and are at a short distance away from the axon consequently when myelin sheath degenerates, no column of cells are formed to

guide the growing axon sprouts.

(c) Absence of nerve growth factors in the CNS.

(d) Laying down of scar tissue by the active astrocytes.

4. This is typical case of **Saturday night paralysis** due to *neurapraxia of radial nerve*.
The term neurapraxia is applied to transient nerve block due to pressure on the nerve.
The paralysis is incomplete and the recovery is rapid and complete. Also see [page 25](#).
5. This is because in nerve lesion due to crush injury or traction, the axons are damaged but the surrounding connective tissue remains intact, a condition called **axonotmesis**.
Consequently, the nerve regenerates and function returns to normal. However, if there is complete section of the nerve, both axons and surrounding connective tissue sheaths are damaged, a condition called **neurotmesis**. Consequently, the nerve fails to regenerate.

*Trophic = having to do with the nutrition.

Receptors and Effectors

Whenever a clinician performs a neurological examination in a patient, he/she tests for normal function of the sensory input and motor output so that he/she may find out any sensory or motor deficit if it is there. The knowledge of structure and function of sensory and motor nerve endings responsible for sensory input and motor output is essential while performing these tests.

Receptors

An individual receives information from outside and from within the body by special sensory nerve endings called **receptors**. The receptor receives stimulus and converts it into a nerve impulse. The receptors thus act as transducers,* converting mechanical and other stimuli into electrical impulses. *Thus, receptors are sensory nerve endings specialized for reception of stimuli and transmitting them in the form of nerve impulses.*

Classification of Receptors

The receptors can be classified broadly into:

1. Functional types.
2. Anatomical types.

Functional types

On the basis of the kind of information they provide

- **Exteroceptors:** They provide information of touch, pain, temperature and pressure. These are superficially located, such as in skin, and are also called *cutaneous receptors*.
- **Proprioceptors:** They provide information about state of contraction of muscles and of joint movement and position.
- **Interoceptors:** They provide information from viscera and blood vessels.

On the basis of the manner in which they are stimulated

- **Mechanoreceptors:** They are stimulated by mechanical deformation.
- **Chemoreceptors:** They are stimulated by chemical influences.
- **Thermoreceptors:** They respond to alternation in temperature, e.g. cold and heat.
- **Nociceptors:** These respond to any stimuli that bring about damage to the tissue. Damage to tissue is perceived as pain, discomfort or irritation.
- **Photoreceptors:** They are stimulated by light, e.g. rods and cones of retina.
- **Osmoreceptors:** They respond to changes in the osmotic pressure.

Anatomical types

Structurally the receptors are classified into two types: non-encapsulated and encapsulated.

Non-encapsulated receptors

Here the sensory nerve endings do not show any particular specialization of structure and are directly applied to the tissue cells or may lie freely in the extracellular spaces.

- **Free nerve endings (Fig. 4.1):** They are widely distributed in the body tissues such as skin, cornea, periosteum, dental pulp, etc. The afferent fibres from free nerve endings are either myelinated or non-myelinated. The terminal endings are devoid of a myelin sheath and there are no Schwann cells covering their tips. Most of these endings carry pain sensations (*pain fibres*), but they are also sensitive to temperature, touch, pressure and tickle sensations.

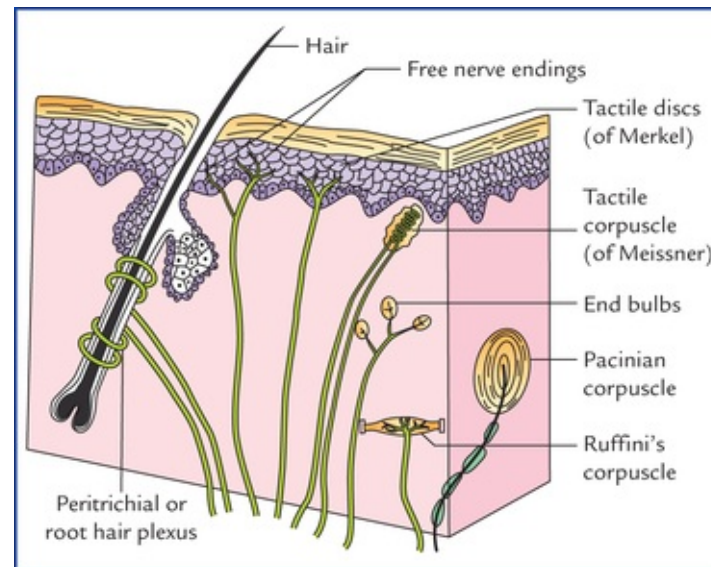


FIG. 4.1 Sensory nerve endings (receptors) in skin.

- **Peritrichial or root hair plexus (Fig. 4.1):** It is a network of dendritic branches that surrounds the outer root sheath of hair follicles and is stimulated by light touch causing movement of hair.
- **Tactile discs (of Merkel):** They are expanded disc-like nerve endings in the germinative epidermal layer of hairless skin (Fig. 4.1). They make close contact with Merkel cells, which are specialized epithelial cells in the deeper part of the epidermis. The tactile discs are slowly adapting touch receptors that transmit information about the degree of pressure exerted on skin, e.g. when one is holding a pen.

Encapsulated receptors

Here the sensory nerve endings are enclosed in a capsule derived from surrounding non-neural cells.

- **Tactile corpuscles (of Meissner):** They are ovoid in shape and found in the dermal papillae of the skin in those areas where tactile sensitivities are extremely well developed, viz. eyelids, lips, fingertips, nipples and external genitalia. The corpuscle consists of a capsule and a central core. The central core contains epithelioid cells (modified Schwann cells) and is supplied by several myelinated nerve fibres. The capsule is continuous with the perineurium of nerves supplying the corpuscle. They function as low threshold rapidly adapting mechanoreceptors and are responsible for close spatial 'two point' discrimination (i.e. they enable an individual to distinguish between two pointed structures when they are placed close to each other on the skin).

- **Pacinian corpuscles (Fig. 4.1):** They are the largest and most numerous encapsulated receptors. Each corpuscle is ovoid in shape, measuring up to 2 mm in length and consists of an outer laminated capsule of flat cells which are arranged in concentric layers like an onion peel and a central core. A myelinated nerve fibre loses its sheath to enter its central core. Pacinian corpuscles are rapidly adapting mechanoreceptors that are particularly sensitive to *firm pressure* (pushing) and *vibration*. These are scattered throughout the integument of the body notably in the subcutaneous tissue of palm, sole, fingers and breasts.
- **End bulbs of various types:** They consist of multiple branched nerve terminals, which are encapsulated (Fig. 4.1).
 - *Bulbous corpuscles (of Krause)* are spherical and found mainly at the mucocutaneous junctions.
 - *Genital corpuscles (or Golgi-Mazzoni)* are slightly different from bulbous corpuscles (of Krause) and occur in the genital skin.
- **Ruffini's corpuscles:** They are spindle-shaped structures located into the dermis of hairy skin. Each corpuscle consists of several non-myelinated nerve endings of a large myelinated axon within a bundle of collagen fibres and surrounded by a cellular capsule. They are slowly adapting mechanoreceptors which respond when skin is stretched causing stresses in dermal collagen. Hence, these are stretch receptors like Golgi tendon organs.

The sensory modalities can be easily tested clinically in skin, muscles, tendons and joints; therefore receptors in these structures are discussed in detail in this chapter.

Cutaneous Receptors (Fig. 4.1)

The skin contains both non-capsulated and encapsulated receptors such as free nerve endings, Merkel's discs, root hair plexus, Meissner's, Pacinian and Ruffini's corpuscles. Various sensory modalities detected by different receptors in skin are listed in Table 4.1.

Table 4.1

Sensory modalities and receptors in skin

Sensory modalities	Type of receptors
Pain, touch and temperature	<ul style="list-style-type: none"> • Free nerve endings • Merkel's discs • Root hair (peritrichial) plexus
Pressure and vibration	<ul style="list-style-type: none"> • Meissner's corpuscles • Lamellated (pacinian) corpuscles
Deep pressure	<ul style="list-style-type: none"> • Ruffini's corpuscles

The structure of cutaneous receptors is already described (see Anatomical Classification of Receptors).

Muscle Receptors

Neuromuscular spindles

The muscle receptors comprise *neuromuscular spindles* (Fig. 4.2). These are spindle-shaped sensory end organs found in the skeletal muscles and are most numerous towards the tendinous attachment of the muscle. They provide sensory information to the CNS to control the motor activity and tone of the muscle. Each spindle consists of a bundle of small specialized skeletal muscle fibres (3–10), and is surrounded by a fusiform capsule of connective tissue. The specialized muscle fibres within the capsule are called **intrafusal fibres** and ordinary muscle fibres situated outside the spindle are referred to as **extrafusal fibres**. The slender intrafusal fibres are striated only at the ends; therefore, only the ends of these fibres can contract.

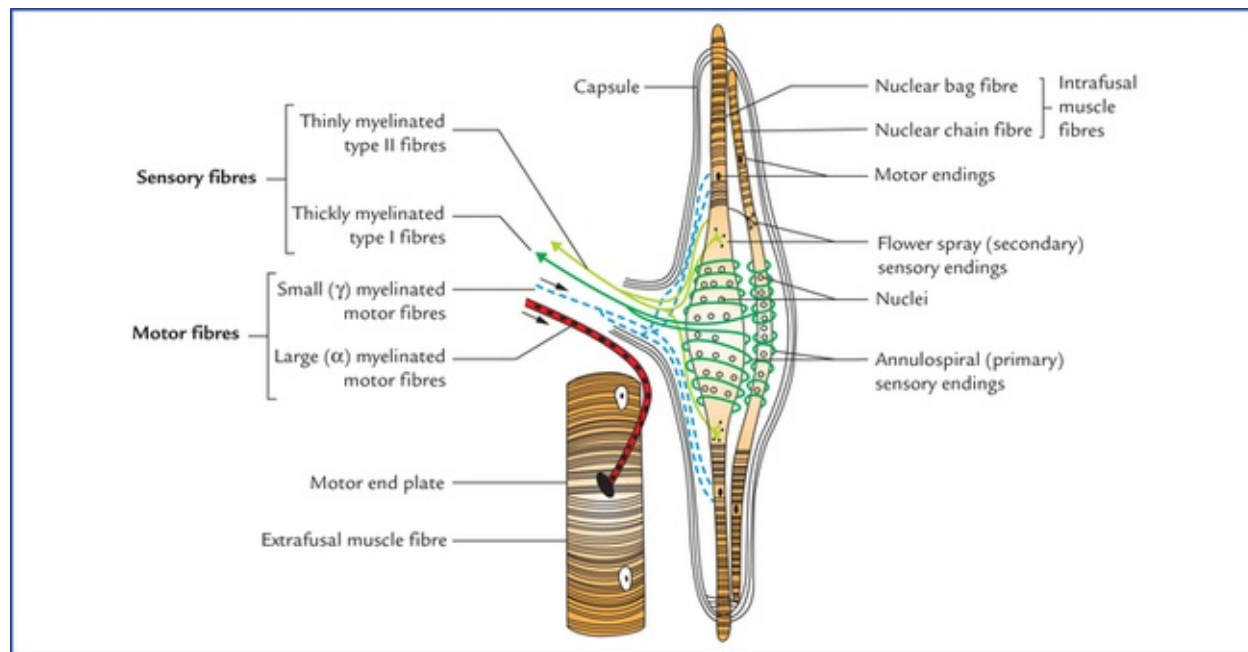


FIG. 4.2 A neuromuscular spindle. Note the two types of intrafusal fibres and their innervation.

The extrafusal fibres that form the main mass of the muscle are supplied by large alpha (α) motor neurons of the anterior horn and the intrafusal fibres of the neuro-muscular spindle are supplied by small gamma (γ) motor neurons of the anterior horn (Fig. 4.2).

The intrafusal muscle fibres are oriented parallel to the surrounding (extrafusal) muscle fibres. They are attached at each pole to intramuscular connective tissue; thus, when muscle elongates, the spindles are stretched.

The sensory nerve endings are wrapped around the centre of the intrafusal fibres, and the gamma (γ) motor neurons supply their striated ends.

Types of intrafusal fibres

The intrafusal fibres of the muscle spindle are of two types: the **nuclear chain fibres** and **nuclear bag fibres**. The nuclear bag fibres contain many nuclei in the expanded equatorial region while in nuclear chain fibres the nuclei form a single longitudinal chain in the centre at the unexpanded equatorial region. Nuclear bag fibres are thicker and longer than nuclear chain fibres, projecting beyond the capsule at each end and attached to extrafusal connective tissue.

Types of sensory nerve endings supplying muscle spindle

The muscle spindle is innervated by two types of sensory nerve endings, **annulospiral** and **flower spray**.

The **annulospiral (primary) endings** wind spirally around the equator of intrafusal fibres and come from thickly myelinated (Type 1a) nerves; the **flower spray (secondary) endings** are located at some distance from equator, mostly on nuclear chain fibres. They are terminals of more thinly myelinated (Type II) nerves, which end as varicosities resembling a spray of flowers.

The neuromuscular spindles maintain muscle tone by functioning as sensory receptor for stretch reflex and has significant role in controlling motor activity for being a component of gamma reflex loop.

Stretch reflex (Fig. 4.3)

When the skeletal muscle is stretched, the intrafusal muscle fibres of muscle spindle are elongated, producing stimulation of sensory nerve endings around them.

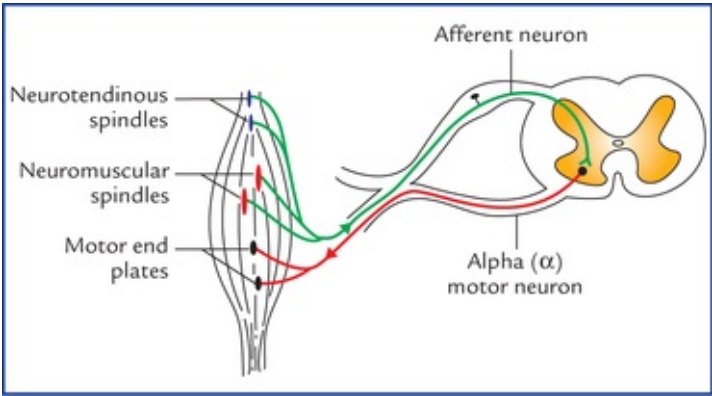


FIG. 4.3 Stretch reflex. A **simple reflex** arc consisting of an afferent neuron (arising from neuromuscular spindle or neurotendinous spindle) and an efferent alpha motor neuron stimulating extrafusal muscle fibres.

The sensory neurons carrying the nerve impulse synapse with the alpha (α) motor neurons in the anterior horn of the spinal cord. When alpha motor neurons are stimulated, they cause rapid contraction of the stretched muscle (the **stretch reflex**). This, in turn, reduces tension in the intrafusal fibres.

The stretch reflex is used by clinicians to elicit the tendon jerks (see page 38).

Gamma reflex loop

During active muscle contraction, a considerable proportion of motor fibres that arise from higher centres in the brain stimulate gamma (γ) motor neurons that innervate intrafusal muscle fibres causing their contraction. When intrafusal muscle fibres contract, spindle sensory neurons respond and through spinal reflex connection to alpha (α) motor neurons, extrafusal muscle fibres contract. The gamma reflex loop thus consists of gamma motor neuron, neuromuscular spindle, afferent neuron, and alpha motor neuron supplying extrafusal muscle fibres.

Gamma reflex loop is an important adjunct to the more direct control of muscular activity by means of descending fibres from the brain that control the alpha motor neurons.

Tendon Receptors

Golgi tendon organs

The tendon receptors comprise *Golgi tendon organs* (also called *neurotendinous spindles*) (Fig. 4.4) which are more numerous near the musculotendinous junctions and are responsible for **Golgi tendon**

reflexes.

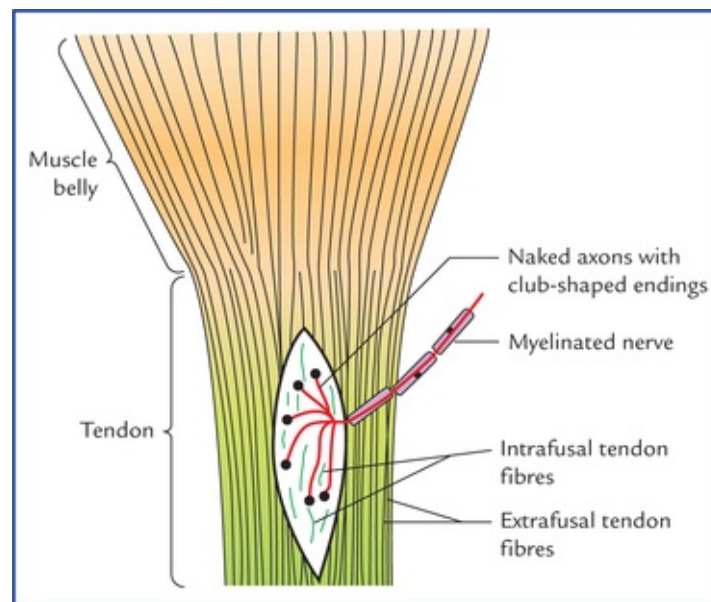


FIG. 4.4 Golgi tendon organ (a neurotendinous spindle).

The Golgi tendon organs monitor the tension produced during muscle contraction and prevent damage to muscle or tendon by excessive stresses.

Each Golgi tendon organ is spindle-shaped and consists of a fibrous capsule that surrounds a small bundle of loosely arranged tendon (collagen) fibres called **intrafusal tendon fibres**. One or more myelinated sensory fibres pierce the capsule, lose their myelin sheath, branch and terminate in club-shaped endings. When collagen fibres of tendon stretch, the sensory neurons of Golgi tendon organs are stimulated which in turn stimulate inhibitory interneurons that synapse with alpha motor neurons. This inhibitory effect on alpha motor neurons causes relaxation of the muscle to which the particular tendon is attached. The opposing functions of the neuromuscular spindles (excitatory) and neurotendinous spindles (inhibitory) are in balance during stretch reflex activity. Unlike the neuro-muscular spindles which are sensitive to changes in the muscle length, the neurotendinous organs detect changes in the muscle tension.

Joint Receptors

The joint receptors are as follows:

- **Free nerve endings** are profusely present in synovial membrane and articular capsule, reacting to painful stimuli.
- **Ruffini's corpuscles** and **lamellated (pacinian) corpuscles** in joint capsule respond to movements and pressure.
- **Neurotendinous spindles** in the articular ligaments prevent excessive stretch of the capsular ligament. Awareness of joint positions is mainly dependent on neuromuscular spindle receptors.

The important receptors and their functions are summarized in [Table 4.2](#).

Table 4.2
Receptors and associated functions

--	--

Receptor	Function (sensory modality)
Free nerve endings	Pain, touch, temperature (heat and cold) and pressure
Merkel's discs	Touch and pressure
Hair follicle receptor	Touch
Meissner's corpuscles	Touch (two-point tactile discrimination)
Pacinian corpuscles	Pressure and vibration
Ruffini's corpuscles	Stretch
Neuromuscular spindles	Elongation of muscle (stretch)
Neurotendinous spindles	Muscle tension

Effector Nerve Endings

Somatic Effectors

Somatic effectors are the terminals of myelinated motor neurons, which arise from lower motor neurons and pass without interruption from the CNS to the skeletal muscles.

Motor innervation of skeletal muscle

The nerve supply and blood supply to a muscle enter it at a more or less constant site called **neuromuscular hilum**. The nerve to a muscle contains motor and sensory fibres.

The **motor fibres** supplying the skeletal muscle are of two types:

- *Large alpha (α) myelinated fibres*. These are the axons of alpha anterior horn cells and supply the extrafusal muscle fibres that form the main mass of the muscle.
- *Small gamma (γ) myelinated fibres*. They are the axons of gamma anterior horn cells and supply the intrafusal fibres of the muscle spindles.

Motor unit

A single alpha motor neuron and muscle fibres innervated by it constitute a *motor unit*. A motor unit thus consists of, an anterior horn cell, its axon and the muscle fibres innervated by it (Fig. 4.5).

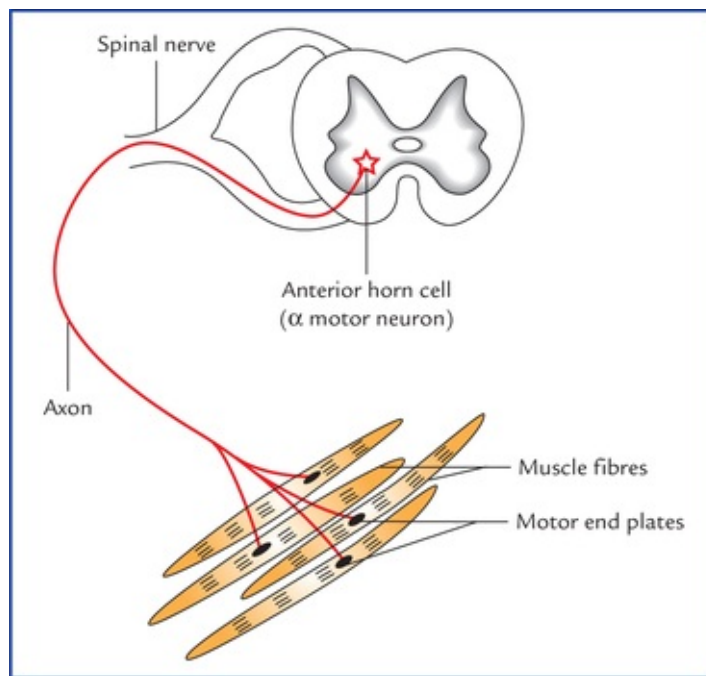


FIG. 4.5 A motor unit consisting of alpha motor neuron and muscle fibres that it innervates.

Depending upon the number of muscle fibres innervated by a motor neuron, the motor units may be small or big. In muscles producing gross movements such as *gluteus maximus* hundreds of muscle fibres (about 500) are supplied by a single neuron, i.e. these muscles have larger motor units, while in muscles having precise movements, viz. extraocular muscles and intrinsic hand muscles, the motor units are very small as only few fibres (about 10) are supplied by a single axon.

Neuromuscular junction or motor end-plate

The communication between the nerve and the muscle fibre occurs across a specialized junction, called **neuro-muscular junction** or **myoneural junction** (Fig. 4.6).

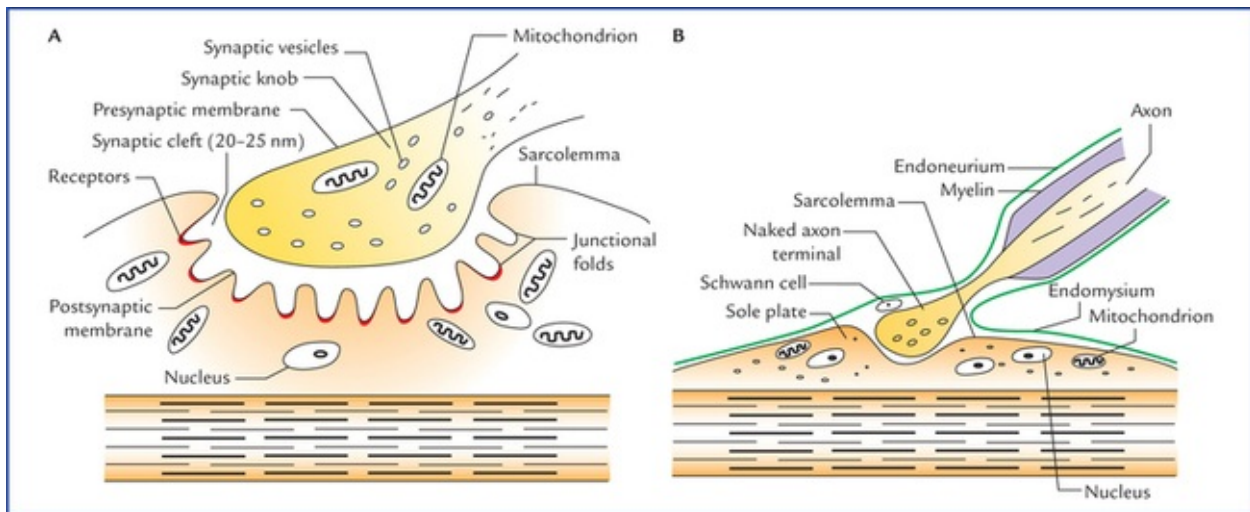


FIG. 4.6 (A) A neuromuscular junction in skeletal muscle. (B) An enlarged view of a naked axon terminal (synaptic knob) lying in the surface groove on the sole-plate of muscle fibre.

As motor neuron enters a skeletal muscle, it branches many times. The number of branches depends on the size of the motor unit. On reaching the muscle fibre, the nerve loses its myelin sheath and breaks up

into number of branches. Each branch is a naked axon terminal which ends into an expansion called **synaptic knob**.

The expanded, naked axon terminal (the synaptic knob) is apposed to a region of sarcolemma (cell membrane of muscle fibre) called **sole-plate**.

The naked axon terminal and the sole-plate form the neural and muscular elements of the **motor end-plate**, respectively.

Adjacent to the site of motor end-plate, the surface of the muscle fibre is elevated slightly due to local accumulation of granular sarcoplasm beneath sarcolemma and the presence of numerous nuclei and mitochondria. The expanded naked axon lies in a groove on the surface of the muscle fibre.

A narrow space, the **synaptic cleft**, separates the two. The sarcolemma forms many junctional folds, increasing the surface area of sole-plate.

The axoplasm of synaptic knob contains mitochondria and presynaptic vesicles filled with molecules of acetylcholine (ACh). The apposing sole-plate contains receptors that will bind to ACh.

The axolemma and sarcolemma are separated by a synaptic cleft of 20–50 nm.

Both the presynaptic membrane (axolemma) and post-synaptic membrane (sarcolemma) contain enzyme acetyl-cholinesterase (AChE) or cholinesterase which breaks down the molecules of ACh.

A nerve impulse, on reaching a neuromuscular junction, causes the release of acetylcholine from synaptic vesicles into the synaptic cleft by **exocytosis**. The acetylcholine diffuses rapidly across the synaptic cleft and binds to the receptors on the postsynaptic membrane. This causes depolarization of postsynaptic membrane (sarcolemma). If depolarization reaches a threshold, an action potential is initiated and muscle contracts.

As the action potential is initiated the acetylcholine is immediately broken down (hydrolysis) by the enzyme, **acetylcholinesterase (AChE)** into acetic acid and choline. The acetylcholinesterase keeps away acetylcholine from accumulating within the synaptic cleft where it would otherwise act as a constant stimulus to postsynaptic membrane leading to continuous contraction of muscle fibres without relaxation.

The sequence of events that take place at the neuromuscular junction upon stimulation of a nerve are similar to those which occur at a typical cholinergic synapse (*see page 17*).

Clinical Correlation

The **myasthenia gravis** is a disease characterized by drooping of the upper eyelids (ptosis), general muscle weakness and fatigue. The condition is an autoimmune disorder in which antibodies are produced against the acetylcholine receptors on the postsynaptic membrane. The antibodies bind to, and destroy the acetylcholine receptors, thus reducing their number. Consequently, less number of ACh molecules bind to postsynaptic membrane causing reduced action potential in plasma membrane of muscle fibre. As a result, muscles exhibit a degree of flaccid paralysis.

The condition can be relieved by giving anticholinesterase drugs such as **neostigmine**, which potentiates the action of acetylcholine.

Visceral Effectors

The visceral effectors are the terminals of non-myelinated axons which arise from the cells in the

autonomic ganglia.

Nerve endings in cardiac and smooth muscle

There are no specialized nerve endings in the cardiac and smooth muscles as in the striated muscles. Here a naked axon terminal of postganglionic non-myelinated fibre occupies a shallow groove in the plasma membrane of cardiac or smooth muscle fibre.

Nerve endings in glands

Like nerve endings in the cardiac and smooth muscle, the nerve endings in the glands are also not specialized. Here the non-myelinated postganglionic nerves enter into the connective tissue of the gland and branch close to the secretory cells.

Clinical Problems

1. If a limb is immobilized in a plaster cast for long duration, the muscles undergo atrophy. Physiotherapy is required after the cast is removed. Explain.
2. The actions of extraocular muscles and intrinsic muscles of hand are more precise and accurately controlled whereas the actions of muscles of trunk and lower limbs are gross and generalized. Why?
3. In organophosphorous poisoning (ingestion of insecticides containing organophosphates) death occurs due to spastic paralysis of respiratory muscles. Why?
4. When ligamentum patellae is struck with reflex hammer, there occurs an involuntary extension of the knee joint (knee jerk). Mention the reason for this.
5. Why muscles undergo atrophy if motor nerves supplying them are cut.

Clinical Problem Solving

1. The activity of muscle receptors (neuromuscular spindles) is necessary for the maintenance of muscle tone and muscle mass. The sensitivity and activity of these receptors increase with the exercise training (**physiotherapy**). Hence, exercise leads to increased muscle tone and muscle mass due to enlargement of muscle fibres (**muscle hypertrophy**). On the other hand, if muscles are not stimulated (limb is immobilized in a plaster cast), the muscle loses its tone and mass (due to decrease in size of muscle fibres) and becomes limp or flaccid (**muscular atrophy**). For this reason physiotherapy is essential after the removal of the cast.
2. A motor unit consists of a single alpha motor neuron and the group of muscle fibres that it supplies. The precision with which movements are produced by muscles depend on the ratio between a motor neuron and the number of muscle fibres innervated by it. The nerve-muscle fibre innervation ratio of extraocular muscles and intrinsic muscles of hand is small (about 1:10) and those of trunk and lower limb muscles big (about 1:500). Therefore, actions of extraocular muscles and intrinsic muscles of hand are more precise than the muscles of trunk and lower limbs.

3. The organophosphates bind to and inhibit the action of acetylcholinesterase. As a result, the acetylcholine accumulates in the synaptic cleft causing continuous stimulation of plasma membrane of muscle fibres. Consequently, the skeletal muscles responsible for respiration contract continuously without relaxation leading to spastic paralysis of respiratory muscles and death.
4. See Clinical correlation on [page 38](#).
5. The maintenance of normal muscle mass depends on continued reception of acetylcholine and trophic substances from the motor nerve terminals on the postsynaptic membrane (sarcolemma of muscle fibre) at the neuromuscular junction. But this is not possible if the motor nerve supplying the muscle is cut. Consequently, the muscle undergoes atrophy.

*Transducer is a device that converts energy from one form to the other.

Dermatomes and Muscular Activity

An accurate assessment of the degree and type of cutaneous sensory impairment and muscular activity play a key role in making the correct diagnosis of a neurological disease.

The precise knowledge of cutaneous sensory impairment enables the physician to identify the peripheral nerve lesion, or the segmental nerve loss or the level of spinal cord involvement.

The observation of specific muscles at rest and during action indicates whether the muscle itself is diseased or it is affected due to impairment of its innervation.

The students, therefore, should have clear concept of segmental innervation of skin and muscles.

Segmental Innervation of Skin

The area of skin supplied by a single spinal nerve, and therefore, a single spinal segment, is called **dermatome**. With the exception of the first cervical nerve (C1), all of the spinal nerves are associated with specific dermatomes.

In the trunk the arrangement of dermatomes is simple because the thoracic and upper lumbar spinal nerve supplying it are arranged segmentally. On the trunk the dermatome extends around the body from the posterior median line to the anterior median line. [Figures 5.1](#) and [5.2](#) depict the dermatomal maps for the anterior and posterior surfaces of the body. Adjacent dermatomes overlap considerably ([Fig. 5.3](#)); therefore to produce a region of complete anaesthesia at least three contiguous nerves have to be severed. Further, it is important to note that the area of tactile loss is always larger than the area of loss of thermal and painful sensations. This is due to the fact that the degree of overlap of fibres carrying pain and temperature sensations is much more extensive than the overlap of fibres carrying tactile sensations.

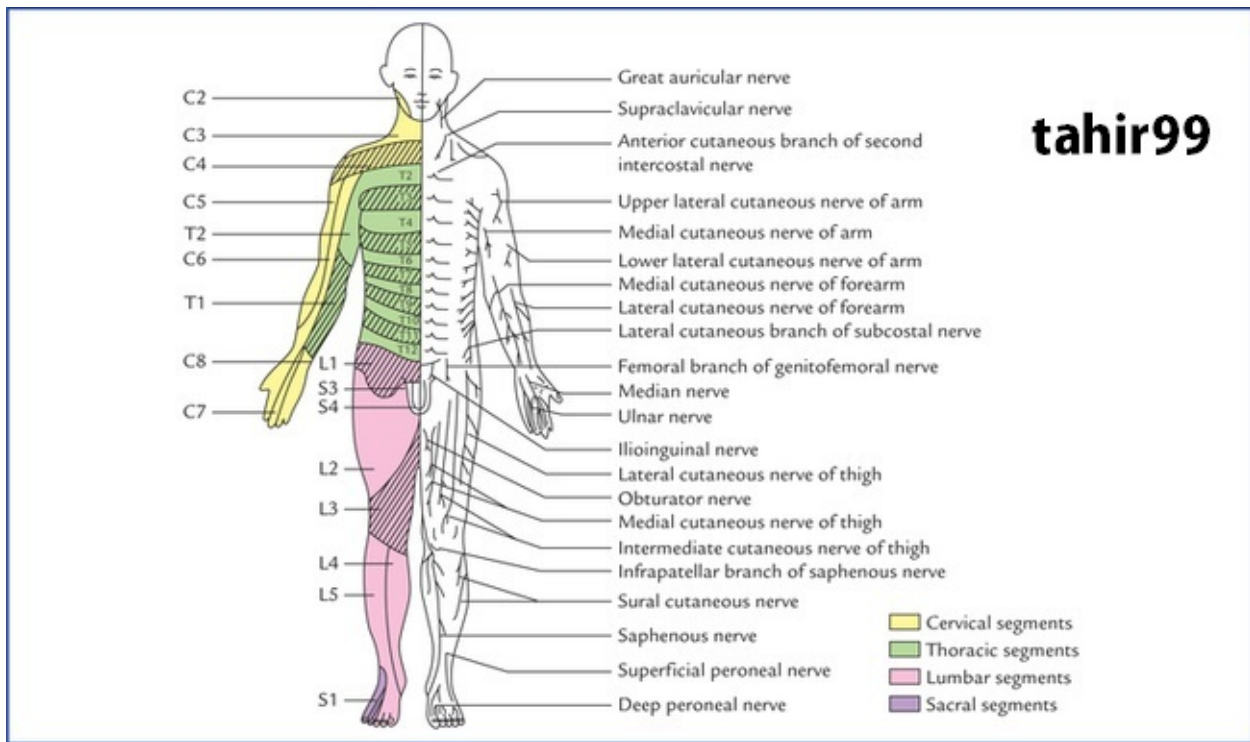


FIG. 5.1 Anterior aspect of the body showing the pattern of dermatomes on the left side, and distribution of cutaneous nerves on the right side.

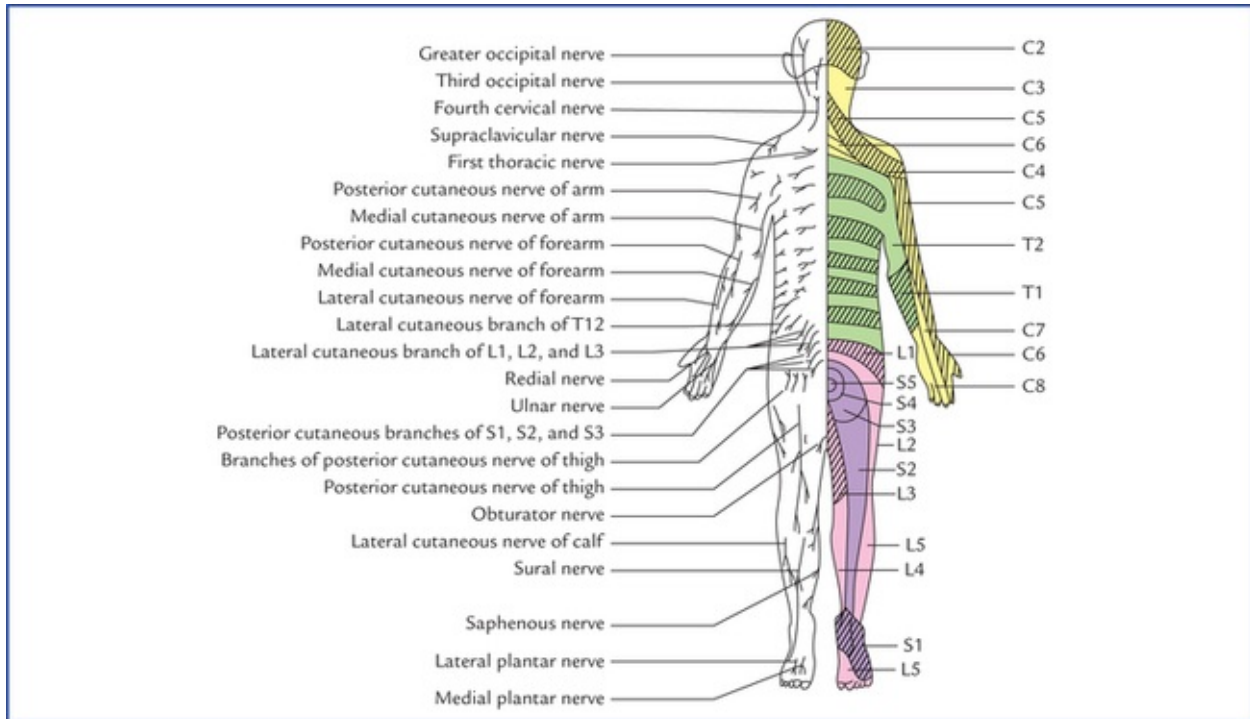


FIG. 5.2 Posterior aspect of the body showing pattern of dermatomes on the right side and distribution of cutaneous nerves on the left side.

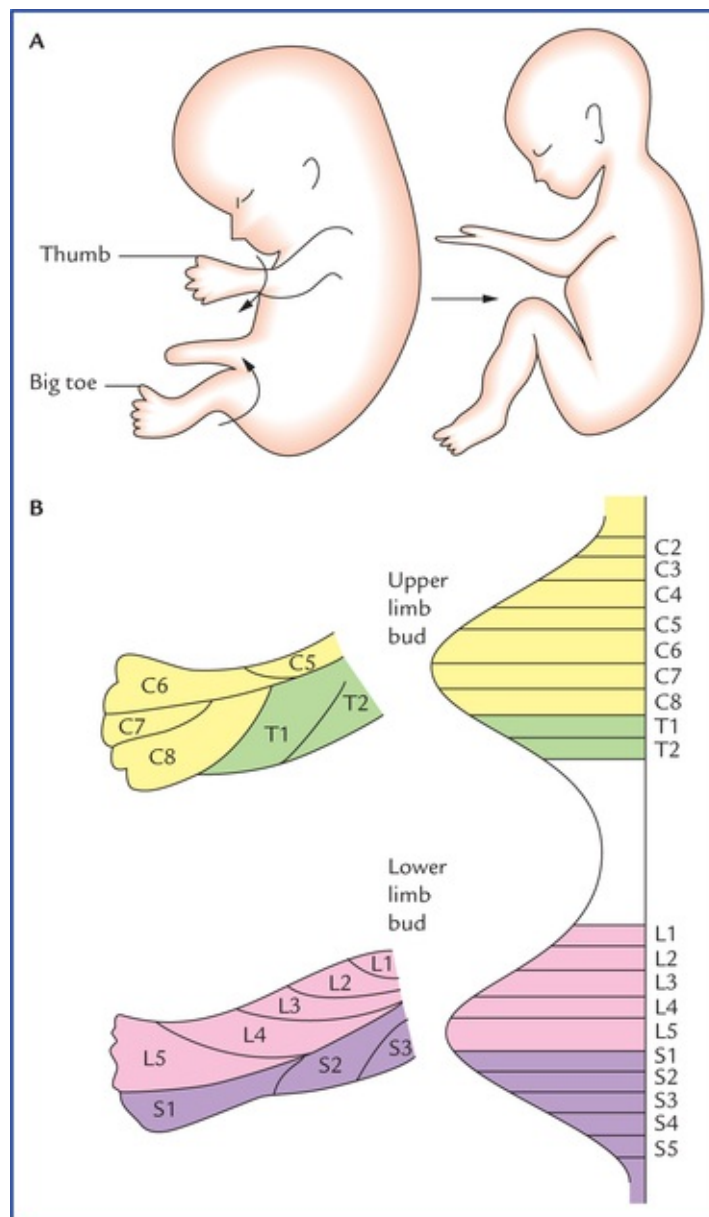


FIG. 5.3 (A) The rotation of the limbs during embryonic development. (B) The arrangement of dermatomes in the upper and lower limbs of the embryo.

In the limbs the arrangement of dermatomes is complicated and this is because of two reasons: (a) the embryo-logical rotation of the limbs as they grow out from the trunk, and (b) the spinal nerves that supply them form plexuses.

In early embryonic development, the upper and lower limbs appear as paired paddle-shaped limb buds. Each bud has preaxial and postaxial borders, with former being towards the head. Later in the development the ends become expanded and flattened to form hand and foot plates, in which the digits develop. The digits along the preaxial border are the thumb and big toe. The limbs then rotate. The upper limb rotates laterally so that its preaxial border and thumb come to lie on the lateral side. On the other hand, the lower limb rotates medially and its preaxial border and big toe come to lie on the medial side. It is now easier to understand why the dermatomes innervated by spinal nerves of brachial plexus are arranged consecutively down on the lateral side and up on the medial side of the upper limb, and dermatomes innervated by spinal nerves of lumbosacral plexus are arranged down the medial side and up the lateral side and back of the lower limb (Fig. 5.3 A, B).

The spinal nerves that supply the upper limb form plexuses from which individual named nerves arise. Each of these named nerves may contain fibres derived from a number of spinal nerves so that the area of

skin supplied by one of the named nerves will be quite different from the area supplied by the individual spinal nerves.

In the head and face region, each of the three divisions of the trigeminal nerve supply a precise area of skin and there is little or no overlap to the cutaneous area of the another division (Fig. 9.8).

Points to Note

- Because of the development of the upper limbs the anterior primary rami of lower cervical and first thoracic spinal nerves have lost their cutaneous innervation of the trunk anteriorly, and at the level of the sternal angle, the fourth cervical der-matome is contiguous with the second thoracic dermatome (Fig. 5.1).
- During the development of head and neck, due to upward migration of upper cervical dermatomes the back of the head is supplied by upper cervical spinal nerves, and at the interauricular line, the second cervical dermatome is continuous with the cutaneous area innervated by the trigeminal nerve (Figs 5.1 and 9.9).

Clinical Correlation

- **Abnormalities of muscle tone:** In disease conditions, the muscle tone is either increased (*hypertonia*) or decreased (*hypotonia*). In hypertonia there is increased resistance to the passive movement. If this increased resistance is greatest at the initial phase of the movement, and then suddenly it gives way during the later phase, it is termed as **clasp-knife rigidity**. When resistance to passive movement is uniformly increased throughout the range of the movement, it is termed as **plastic-type of rigidity** or **lead-pipe rigidity**.

If the increased resistance is felt intermittently throughout the range of movement, it is termed **cogwheel-type of rigidity**.

- **Abnormalities of Sensory Perception**

In disease conditions, the patient may have areas of reduced sensitivity to pain (**hypoalgesia**) or areas of reduced sensitivity to touch (**hypoesthesia**) or areas of exaggerated sensitivity (**hyperaesthesia**) or areas of abnormal sensations (**paraesthesia**). The paraesthesia includes sensations like feeling of pins and needles, burning, prickling, etc.

Segmental Innervation of Muscles

The skeletal muscles are also segmentally innervated. Most of these muscles are innervated by more than one spinal nerve and therefore by the same number of spinal segments. Therefore, to paralyze a muscle completely it would be necessary to section several spinal nerves or damage several segments of the spinal cord.

It is important to note the following facts carefully:

- Most of the skeletal muscles are supplied by two or more spinal segments (the intrinsic muscles of the hand are exception as they are unisegmental).
- Muscles sharing a common primary action are supplied by the same spinal segments and the opposing muscles by the lower segments in sequence with the former. For example, the flexors of the elbow

joint are supplied by C5 and C6 spinal segments and the extensors by the C7 and C8 spinal segments.

- There is correlation among the innervation of muscles, joints and the skin, i.e. the branches of those spinal nerves which supply the muscles moving a joint also supply the skin over the insertions of the same muscles and the interior of the joint.

It is neither necessary nor possible to remember the segmental innervation of all the muscles of the body but one should remember the segmental innervation of the muscles given in [Table 5.1](#) because they can be tested by eliciting the simple muscle reflexes/stretch reflexes (also called tendon jerks) in the patient during physical examination.

Table 5.1

Segmental innervation of muscles used for eliciting tendon reflexes

Muscle	Segmental innervation	Reflex
Biceps brachii	C5, 6 (Musculocutaneous nerve)	Biceps jerk (flexion of elbow by tapping the biceps tendon)
Triceps brachii	C7, 8 (Radial nerve)	Triceps jerk (extension of elbow by tapping the triceps tendon)
Brachioradialis	C5, 6 (Radial nerve)	Brachioradialis/supinator jerk* (flexion of forearm in midprone position by tapping the insertion of brachioradialis)
Quadriceps femoris	L2, 3, 4 (Femoral nerve)	Quadriceps jerk/knee jerk/patellar jerk (extension of knee by tapping the ligamentum patellae/patellar tendon)
Triceps surae (gastrocnemius and soleus)	S1, 2 (Tibial nerve)	Achilles tendon reflex/ankle jerk (plantar flexion of ankle by tapping the tendocalcaneus, also called Achilles tendon)

*The **brachioradialis jerk** is commonly termed **supinator jerk** by clinicians after the old name of the brachioradialis muscle, the supinator longus.

Clinical Correlation

The **knee jerk (patellar jerk)** is a classical example of the stretch reflex and used by clinicians to determine if higher centres that normally influence the reflex are functional. When ligamentum patellae are tapped with a reflex hammer the quadriceps muscle is stretched. As a result the intrafusal fibres within the muscle spindles are also stretched. Consequently sensory fibres innervating the intrafusal fibres of muscle spindle are stimulated and send afferent action potentials to the spinal cord segments (L2, L3 and L4) where they stimulate alpha motor neurons directly. The efferent fibres arising from these neurons transmit action potentials to the extrafusal fibres of the quadriceps muscle, causing a rapid contraction of the stretched muscle leading to extension of leg—**positive knee jerk response** ([Fig. 5.4](#)).

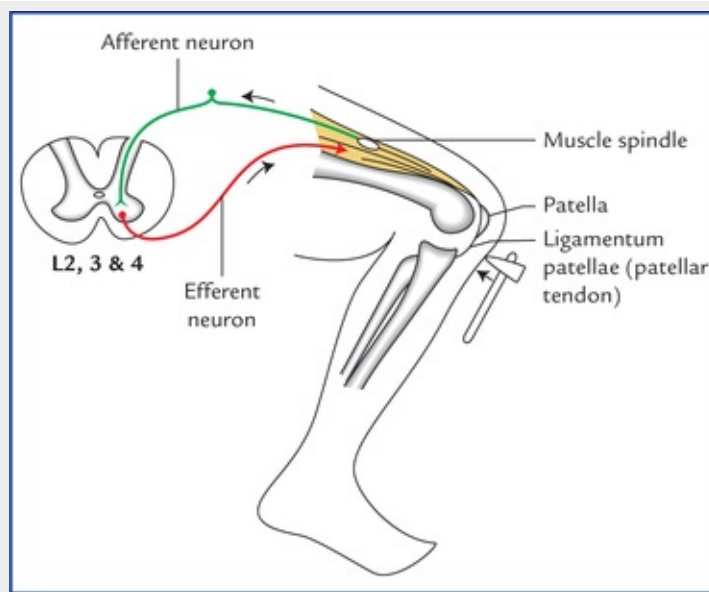


FIG. 5.4 Knee jerk (patellar jerk). Note that the reflex arc passes through L2-4 spinal segments of the spinal cord. The stretch reflex is monosynaptic.

N.B. The stretch reflex is unique in that it does not require an association neuron between the afferent and efferent neurons (i.e. monosynaptic).

Muscle Tone

Every muscle while at rest is in a state of partial contraction, which provides a tone to the muscle. The muscle tone is tested by assessing the resistance offered by the muscles to passive stretch. Since muscle fibres remain either in the state of full contraction or full relaxation (they are never in state of partial contraction or relaxation). This means that a few muscle fibres within a muscle are fully contracted all the time. Therefore, to keep the tone maintained continuously and simultaneously not allowing the muscle to fatigue, the different groups of muscle fibres belonging to different motor units are brought into action at different times.

Basically the muscle tone is dependent on the integrity of a simple monosynaptic reflex arcs composed of two neurons. The nerve impulses travel along the afferent fibres to the spinal cord, where they synapse with the alpha (α) motor neurons in the anterior horn, which in turn send impulses along their axons (efferent fibres) to the muscle fibres (Fig. 5.4).

Two types of sensory receptors are present in the muscle including its tendon: (a) *muscle spindles*, and (b) *tendon spindles*. The former detects the lengthening and shortening in the muscle while the latter detects the tension in the tendon.

The muscle spindles themselves are innervated by small gamma (γ) efferent fibres which regulate the response of the muscle spindles. In this way the muscle tone is maintained reflexly according to the needs of posture and movement.

If the afferent or efferent limb of the reflex arc is cut, the muscle will lose its tone immediately and become flaccid. On palpation, the flaccid muscle feels like a mass of dough (dough = mass of flour) and shows no resilience at all. It quickly atrophies and becomes reduced in volume.

Movement and Posture

Movement

The **movement** is accomplished by the action of muscles. The muscle acts by contraction and with rare exceptions single muscle does not contract alone, because the whole movement rather than individual muscles are represented in the cerebral cortex. Therefore, each movement generally requires the contraction and relaxation of a whole group of muscles. For example, the lifting of the arm from the side not only requires the contraction of abductors of the shoulder joint but also simultaneous relaxation of the adductors of the shoulder joint. It follows that muscle movement is accomplished by bringing into action increasing number of motor units of **synergist muscles** which contract and at the same time, reducing the activity of the motor units of the **antagonist muscles** that oppose the movement.

The **muscle fatigue** occurs due to progressive loss of strength of muscle with prolonged contraction. It occurs due to reduction in the amount of adenosine triphosphate (ATP) within the muscle fibres.

Muscle power

The muscle power is the force or strength of contraction of muscle or muscle groups. In normal individuals the power in different groups of muscles varies according to their physiological requirements. In general, the larger the muscle, the greater the muscle power.

Grading of muscle power

The power of muscles is objectively expressed in grades. The Medical Research Council (MRC) grading is generally adopted. It is given in [Table 5.2](#).

Table 5.2

The grades of muscle power

Grade	Movement
Grade 0	Complete paralysis with not even a flicker of movement
Grade 1	A flicker of movement is possible
Grade 2	The part can be moved, if the gravity is eliminated by suitable positioning
Grade 3	The muscle can contract against gravity but not against the resistance
Grade 4	The muscle can contract against mild or moderate resistance
Grade 5	Normal power is present. Movement against full resistance is possible

- The lesions of the peripheral nerve that supplies the muscle or involvement of anterior horn cells in diseases (e.g. poliomyelitis) reduce the power of or paralyze the muscles involved.
 - The **muscular wasting** occurs within 2-3 weeks after peripheral nerve lesion.
 - The **muscular fasciculations**, i.e. twitching of group of muscle fibres is very commonly seen in patients with chronic disease that affects the anterior horn cells.
 - The **muscular contracture** occurs most commonly in the muscles that normally oppose the paralyzed muscles. The contracture leads to permanent shortening of the muscle.
- The **localized wasting of muscles** is associated with lower motor neuron (LMN) type of paralysis and disuse atrophy.
- **Generalized wasting of muscles** occur in debilitating diseases such as cancer, pulmonary tuberculosis, etc.

Posture (= physical disposition of the body)

The posture may be defined as the position adopted by an individual in his/her environment. The posture of an individual depends on the degree and distribution of muscle tone and, therefore, on the activity of motor nerves which supply the muscles. The normal postural tone of skeletal muscle is dependent not only on the integrity of the 'simple muscle reflex' (stretch reflex) but also on the summation of nerve impulses or information received by anterior horn cells of spinal cord from other sources, viz.

from membranous labyrinths of internal ears,

from cerebellum, midbrain and cerebral cortex, and

from the eyes.

While standing erect, the line of gravity passes through the dens of the second cervical vertebra, behind the centres of hip joints, and in front of the centres of knee and ankle joints.

Since humans have acquired an erect posture in animal kingdom, it is not surprising that in humans in order to stabilize and prevent the body from falling, the **antigravity muscles** (extensors of leg and flexors of the arm) are well developed and exhibit maximal degree of tone.

Clinical Problems

1. Explain, why a physician while testing exteroceptive sensations (pain, touch and temperature) applies stimulus in a longitudinal direction in limbs and in a horizontal direction in the trunk.
2. What are the various types of muscular rigidities that are found in patients suffering from paralysis and how their knowledge helps to know whether the paralysis is due to upper motor neuron lesion or extrapyramidal lesion?
3. A 55-year-old man developed skin rashes (vesicles containing clear fluid) in his right 5th intercostal space and experienced shooting/burning pain. Name the disease and the spinal nerve involved.

Clinical Problem Solving

1. The sensations of pain, touch and temperature are tested by using sterile pin, wisp of cotton wool, and holding hot and cold test tubes respectively.

The stimulus is applied by moving the above-mentioned objects longitudinally along the long axis of the limb because dermatomes run longitudinally along the long axis of the limb. In the trunk the dermatomes run almost horizontally, therefore the stimulus is applied in a horizontal direction.

2. The **muscular rigidity** (increased muscle tone) can be classified into three types: (a) *clasp-knife type*, (b) *lead-pipe type*, and (c) *cogwheel type*.

The following tabular presentation of facts is of great diagnostic help in determining the site of lesion.

Rigidity	Feature	Lesion
Clasp-knife	The initial resistance to the movement is suddenly overcome	Upper motor neuron lesion
Lead-pipe	A steady increase in resistance throughout the movement	Extrapyramidal lesion
Cogwheel	Ratchet-like (intermittent) increase in resistance to movement	Extrapyramidal lesion

3. The **herpes zoster** is a viral infection that affects the posterior root (sensory) ganglia of the spinal nerves and sensory ganglia of cranial nerves. The posterior root ganglia of thoracic spinal nerves and sensory ganglion of trigeminal nerve (geniculate ganglion) are most commonly affected. Since the patient is experiencing severe pain and has skin vesicles in the areas of right fifth intercostal space. It is for sure that dorsal root ganglion of right 5th intercostal nerve is infected by herpes zoster virus.

N.B. *The infection of trigeminal ganglion by herpes zoster virus mostly involves the ophthalmic division of trigeminal nerve and vesicles appear above the eye along the distribution of supratrochlear and supraorbital nerves. This condition is termed herpes zoster ophthalmicus.*

Central Nervous System: an Overview

The central nervous system (CNS) consists of the brain and spinal cord, which are located in the cranial cavity and vertebral canal respectively (Fig. 6.1).

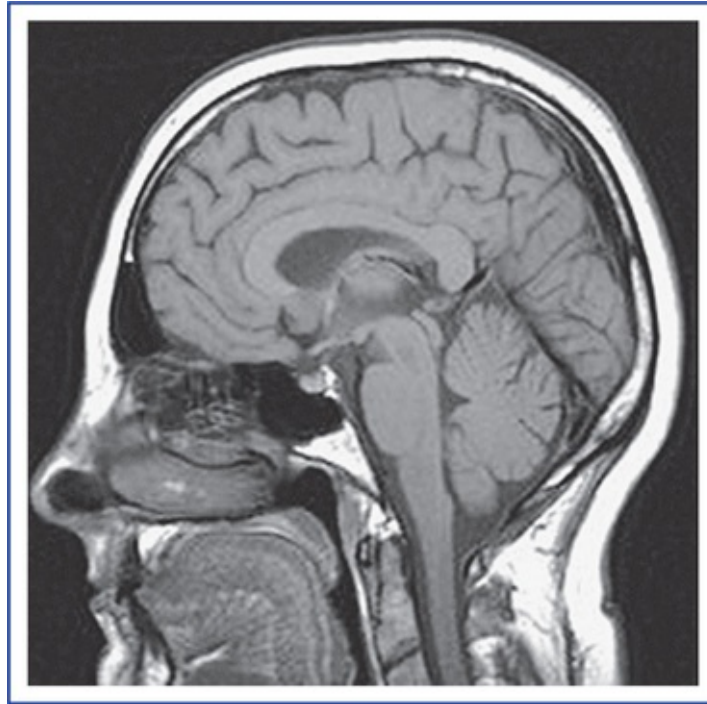


FIG. 6.1 A sagittal view of MRI of the skull, brain and cranial portion of the spinal cord.

The delicate CNS is well protected because it is enclosed by the skull and vertebral canal and meninges, and is bathed in cerebrospinal fluid (CSF).

Structurally, the brain and spinal cord consist of grey and white matter. Therefore, sections through the CNS present greyish and whitish regions.

The **grey matter** consists of nerve cell bodies and dendrites, and the **white matter** is made up predominantly of myelinated nerve fibres.

N.B. Both grey matter and white matter contain neuroglia and blood vessels.

In the brain (except the brainstem), the grey matter is present at the periphery and the white matter in the centre. Contrary to it, in the spinal cord the grey matter is present in the centre and white matter at the periphery.

Brain

The brain is that part of the CNS which lies within the cranial cavity.

The functions of the brain are as follows:

- It receives information from, and controls the activities of trunk and limbs mainly through its connections with the spinal cord.
- It receives the information from, and controls the activities of head and neck structures through cranial nerves.
- It assimilates experiences, a requisite to higher mental processes such as memory, learning and intelligence.
- It is also responsible for one's personality, thoughts and aspirations.

N.B. Plato (427 BC) referred to the brain as the “divinest part of the body”.

The adult brain constitutes about one-fiftieth of body weight and weighs about 1400 g in males and 1200 g in females. It consists of six major parts: (a) the cerebrum, (b) the diencephalon, (c) the midbrain, (d) the pons, (e) the medulla oblongata, and (f) the cerebellum (Fig. 6.2).

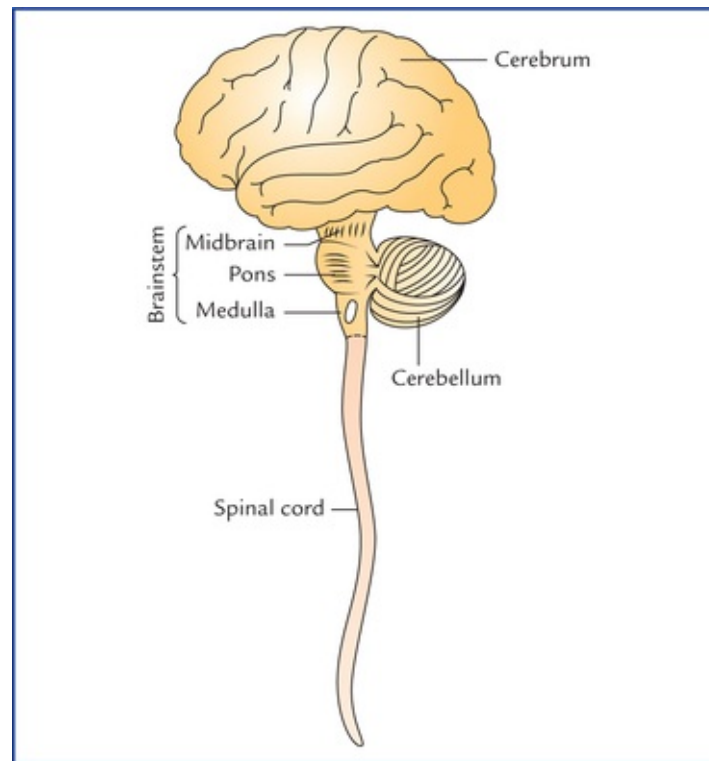


FIG. 6.2 The diagram showing parts of central nervous system. The diencephalon is not seen. The superior, middle and inferior cerebellar peduncles, which connect the cerebellum with the mid-brain, pons and medulla oblongata are shown schematically.

The midbrain, pons and medulla oblongata collectively form the **brainstem**.

The [Figure 6.3](#) shows the superolateral aspect of the brain, as seen in dissection.

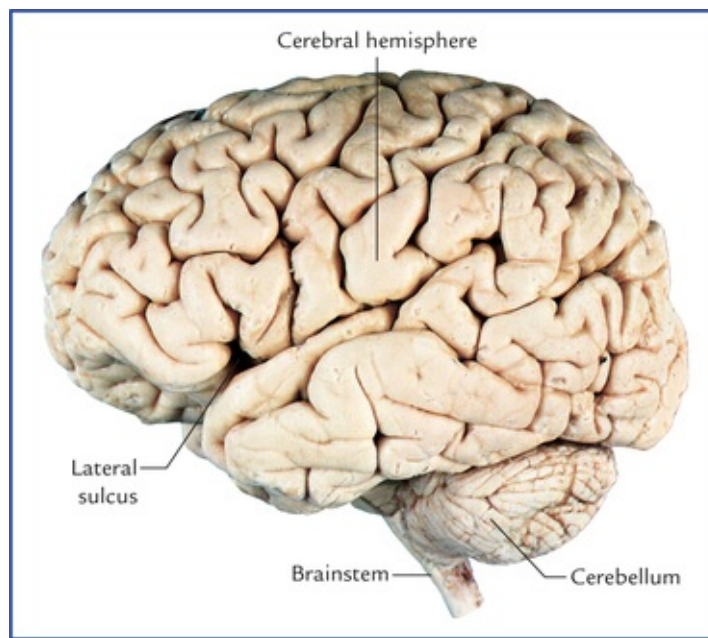


FIG. 6.3 Superolateral surface of the brain (left lateral view) as seen in the dissection.

Cerebrum

The **cerebrum** is the largest part of the brain. It consists of two large, hemispheres (the **left** and the **right cerebral hemispheres**), which occupy the anterior and middle cranial fossae, and the supratentorial region of posterior cranial fossa.

Each cerebral hemisphere consists of a surface layer of grey matter, called **cerebral cortex** and a central core of **white matter**. In the basal part of the latter are located large masses of grey matter, known as **basal nuclei/ganglia** (Fig. 6.4).

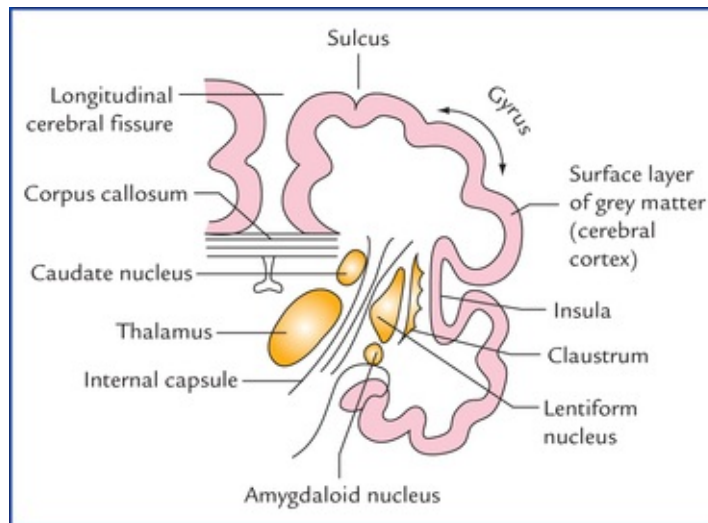


FIG. 6.4 A coronal section of the cerebral hemisphere showing surface layer of grey matter (cerebral cortex), central core of white matter and basal nuclei.

The two hemispheres are partly separated from each other by a deep median longitudinal fissure, called **longitudinal cerebral fissure**. A massive commissure, the **corpus callosum**, whose fibres interconnect the corresponding cortical areas of the two cerebral hemispheres, lies in the floor of the

fissure.

The surface of cerebral hemisphere is convoluted, i.e. it has a series of elevations, the **gyri**, separated by shallow depressions, the **sulci** or deep grooves called **fissures** (Fig. 6.3).

A **central sulcus** which runs downwards and forwards from superomedial border to the lateral sulcus is located about midway along the length of the hemisphere.

There are individual differences in the appearance of the sulci and gyri, but some sulci are constant in their position and appearance, and serve as an important landmark.

The **superolateral surface of each cerebral hemisphere** is divided into four lobes, which are named after the overlying skull bones (Fig. 6.5):

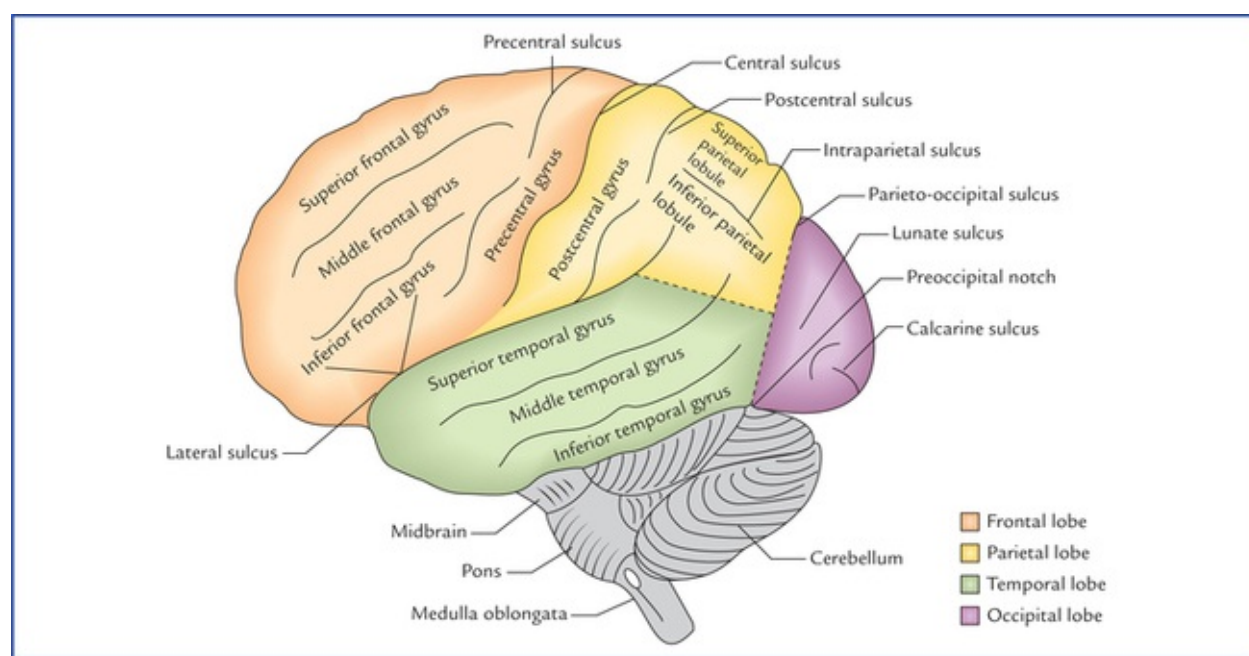


FIG. 6.5 Superolateral surface of the brain. Note the demarcation of lobes on the superolateral surface of the cerebral hemisphere.

- **Frontal lobe** is anterior to the central sulcus and above the lateral sulcus.
- **Parietal lobe** is posterior to the central sulcus and above the lateral sulcus.
- **Occipital lobe** is behind a line extending from parieto-occipital sulcus to the pre-occipital notch.
- **Temporal lobe** is below the lateral sulcus and in front of parieto-occipital notch.

The *frontal lobe* is important for voluntary motor functions, motivation, aggression, emotions, effect, drive and awareness of self.

The *parietal lobe* is the major centre for reception and evaluation of all sensory informations except for smell, hearing, and vision.

The *occipital lobe* is responsible for reception and integration of visual input.

The *temporal lobe* receives and evaluates input for smell and hearing and plays an important role in memory.

N.B. Deep within the lateral sulcus lies a submerged portion of cerebral cortex, the **insula** which is often referred to as **fifth lobe** or **central lobe**.

The so-called **limbic lobe** is a composite bordering zone (limbus = border) between the telencephalon and diencephalon. It is somewhat ring-shaped. It is associated with basic survival instincts, viz. the

acquisition of food and water and reproduction. It provides ability to store and retrieve information and is particularly important for short-term memory.

The **medial surface of the cerebral hemisphere** is visualized in the sagittal section of brain and presents a number of features as shown in [Figure 6.6](#).

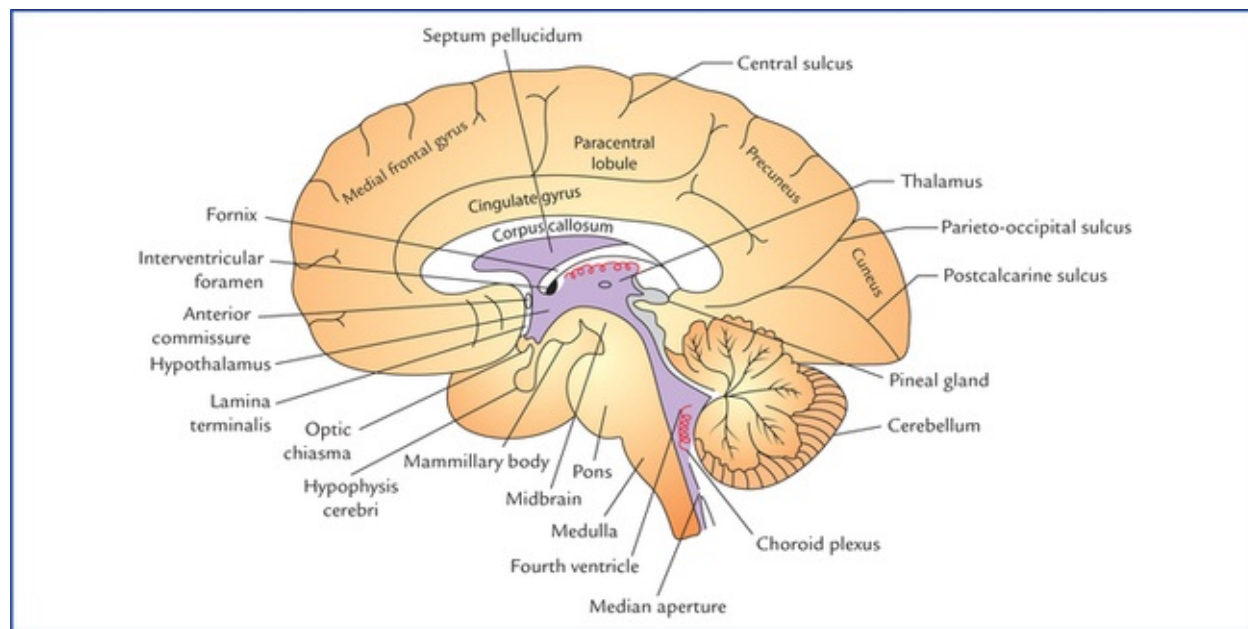


FIG. 6.6 Median sagittal section of the brain.

The **inferior surface of the cerebral hemisphere** is uneven and presents orbital and tentorial surfaces.

Basal ganglia/nuclei

The basal ganglia are subcortical masses of grey matter which are situated in the white core of each cerebral hemisphere.

The basal ganglia include the lentiform nucleus, caudate nucleus, claustrum, and amygdaloid body ([Fig. 6.4](#)).

During development of connections between the cerebral cortex and the brainstem, the bundles of fibres, converging as the **internal capsule**, partly divide the corpus striatum into a medial **caudate nucleus** and a lateral **lentiform nucleus**. Between the internal capsule and the cerebral cortex, the nerve fibres diverge as the **corona radiata**.

Functionally, the basal ganglia also include the subthalamic nucleus of diencephalon, and the substantia nigra and red nucleus of midbrain.

The basal ganglia influence the quality of motor functions and are sometimes termed **extrapyramidal nuclei**.

The major effect of basal ganglia is to decrease the muscle tone and inhibit the unwanted muscular activity.

Diencephalon

The diencephalon is the part of brain between the cerebrum and the brainstem. Its main components are: (a) two thalami, (b) hypothalamus, (c) metathalamus, (d) epithalamus, and (e) subthalamus.

Thalamus

The two thalami form by far the largest mass of the diencephalon and are separated from each other by a cavity of third ventricle, and joined with each other by an interthalamic adhesion. Each thalamus is a large ovoid mass of nuclei, lying obliquely across the path of cerebral peduncle as it ascends into the cerebral hemisphere. *It forms a great relay station for all sensory impulses except smell*, and appreciate crude sensations like pain and touch. The thalamic neurons send projections to the sensory area of the cerebral cortex.

The thalamus also integrates motor functions, relaying impulses from the cerebellum and corpus striatum to the motor area of the cerebral cortex. The connections of thalamus with limbic system influence mood, behaviour and memory.

Hypothalamus

The hypothalamus is the most inferior portion of the diencephalon and contains several small nuclei and nerve tracts. The most conspicuous nuclei called **mammillary bodies** appear as rounded elevations on the base of the brain in the region of interpeduncular fossa.

The hypothalamus regulates visceral activity through the autonomic nervous system and hormonal activity through the hypophysis cerebri.

Metathalamus

The metathalamus consists of two rounded medial and lateral geniculate bodies which protrude from the postero-inferior surface of the thalamus.

The medial and lateral geniculate bodies form the relay stations for the special senses of hearing and vision respectively.

Epithalamus

The epithalamus is a small area of diencephalon, postero-superior to the thalamus. It consists of **pineal gland** and **habenular nuclei**. The pineal gland plays an important role in controlling the onset of puberty through its secretion, the melatonin. The reduction of pineal secretion precipitates puberty. Pineal gland is also involved in *sleep-wake cycle*.

The habenular nuclei have olfactory and limbic connections. They are influenced by smell and are involved in emotional and visceral responses to odours.

Subthalamus

The subthalamus is a small area of diencephalon, that lies between the thalamus and the midbrain. It contains several nerve tracts, and the subthalamic nuclei which are associated with basal ganglia and are involved in controlling motor functions.

Midbrain

The midbrain is the smallest segment of the brainstem ([Fig. 6.7](#)). It is just superior to the pons, and contains the nuclei of IIIrd (oculomotor), IVth (trochlear), and Vth (trigeminal) cranial nerves.

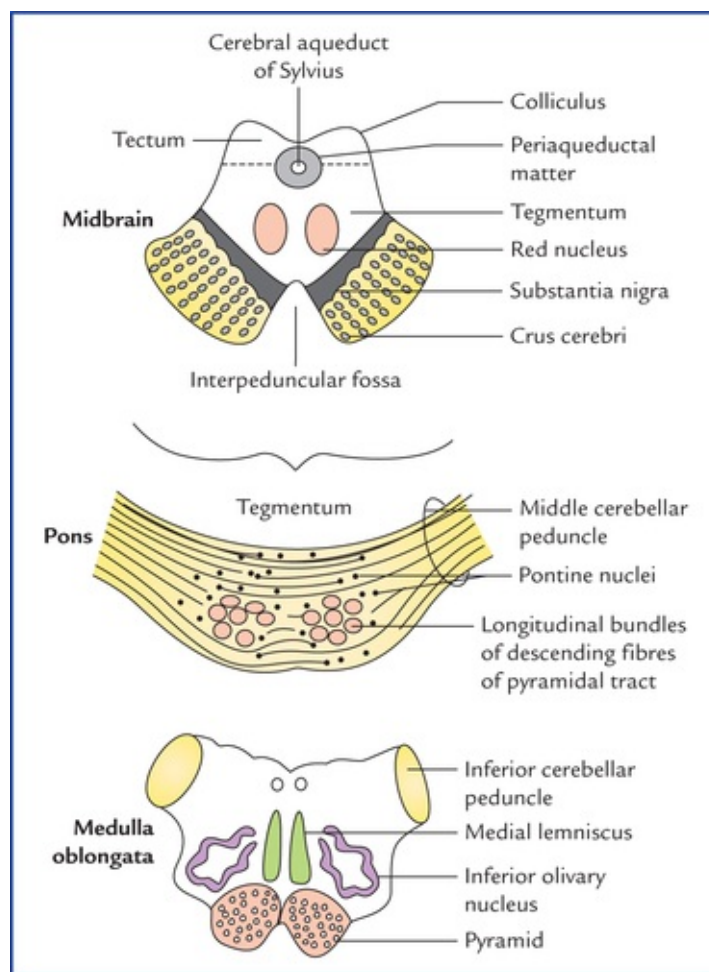


FIG. 6.7 Transverse sections through the three components of the brainstem.

The midbrain is traversed by the cerebral aqueduct. The part dorsal to the aqueduct, is called **tectum**, and consists of four surface elevations, the **corpora quadrigemina** (comprising two superior and two inferior **colliculi**). The superior and inferior colliculi receive visual and auditory impulses respectively, and are concerned with reflexes involving these senses. The part ventral to the aqueduct is divided into right and left halves, the **cerebral peduncles**. Each cerebral peduncle consists of a central part, the **tegmentum** which is separated ventrally from the crus cerebri by a mass of pigmented grey matter, the **substantia nigra**.

The crus cerebri is continuing ipsilaterally with the internal capsule above and contains descending fibres from cerebral cortex to the brainstem and spinal cord. The space between the two crura is termed interpeduncular fossa.

The tegmentum largely consists of ascending tracts from the spinal cord to the thalamus and contains two large cigar-shaped nuclei, called **red nuclei**. In cross-section the red nuclei appear as oval masses of pinkish grey matter.

The red nuclei help in unconscious regulation and coordination of motor activities.

Pons (= Bridge)

The pons is the large middle part of the brainstem. It is continuous above with the midbrain and below with the medulla oblongata. It is so named because it forms a broad bridge between the two cerebellar hemispheres by its transverse fibres constituting the **middle cerebellar peduncles**. The vertical median sulcus on its ventral aspect lodges the basilar artery and therefore, termed *basilar sulcus*.

In transverse section (Fig. 6.7) the pons is seen to consist of a large ventral and a smaller dorsal region.

The **ventral portion** contains large number of nuclei, the **pontine nuclei** and longitudinal bundles of descending fibres of pyramidal tract. The pontine nuclei relay information from cerebrum to the cerebellum (**cortico-ponto-cerebellar pathway**).

The **dorsal portion** or tegmentum of pons contains important **pontine sleep** and **respiratory centres**. The *pontine respiratory centre* functions with the respiratory centre in the medulla to help control the respiratory movements.

Medulla Oblongata

The medulla oblongata is the lower part of the brainstem, and is continuous inferiorly with the spinal cord at the foramen magnum.

On the ventral aspect of medulla, there are two pyramid-shaped elevations, one on either side of median plane called **pyramids**. These elevations are produced by the descending fibres of the corticospinal tracts involved in the conscious control of the skeletal muscles. Lateral to the pyramids there are two rounded oval elevations, called olives containing **inferior olivary nuclei**. Dorsal to each olive is an **inferior cerebellar peduncle** (Fig. 6.7).

On the dorsal aspect, the medulla has cuneate and gracile tubercles produced by similarly named nuclei on either side of the median plane.

Medulla contains various vital autonomic centres responsible for several reflexes, such as those involved in the regulation of the heart rate, blood vessel diameter, breathing, swallowing, vomiting, coughing and sneezing.

Cerebellum (= Little Brain)

The cerebellum lies dorsal to the pons and medulla, and consists of two lateral hemispheres, the **cerebellar hemispheres** and a median worm-like part called **vermis**. It is connected to the midbrain, pons and medulla by superior, middle and inferior cerebellar peduncles respectively. The surface of cerebellum has narrow transverse ridges called **folia** (leaf-like in sections) separated by deep **fissures**.

Functionally, the cerebellum is mainly concerned with involuntary control of somatic motor activities, essential for maintenance of equilibrium, muscle tone, and posture.

Base of the Brain

The base of the brain as seen in dissection is shown in Figure 6.8. The base of the brain presents: (a) orbital and tentorial surfaces of the frontal and temporal lobes of both the cerebral hemispheres, (b) interpeduncular fossa, (c) ventral aspects of midbrain, pons, medulla oblongata and cerebellum, and (d) superficial attachment of the cranial nerves (Fig. 6.9).

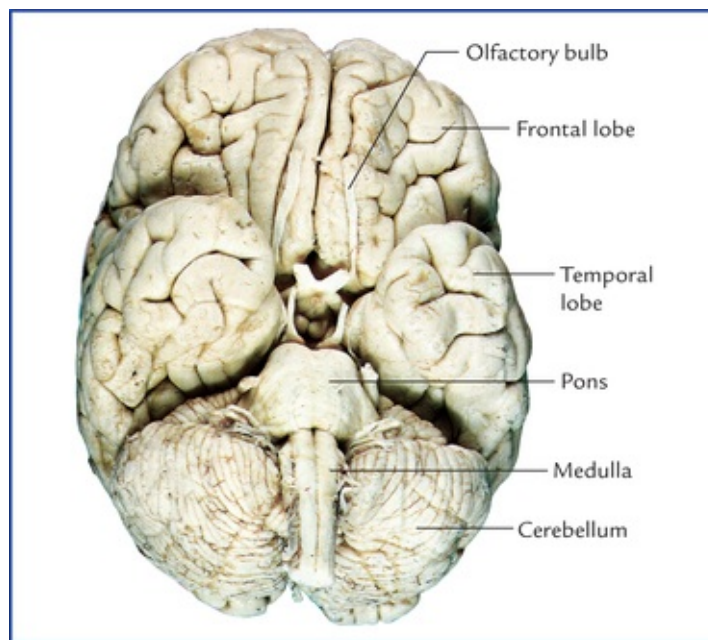


FIG. 6.8 The base of the brain; the midbrain lying between the pons and hypothalamus is not seen.

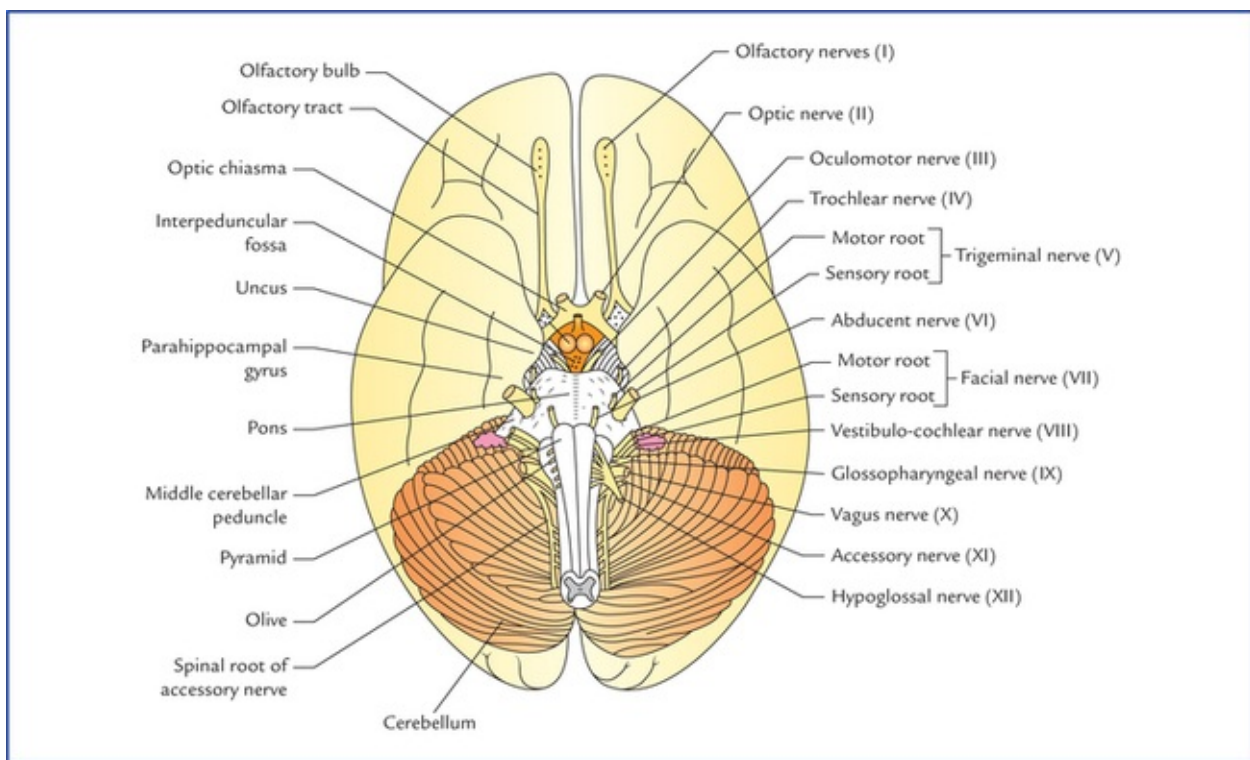


FIG. 6.9 Base (inferior aspect) of the brain. (Source: Singh Vishram. Anatomy of Head, Neck and Brain. New Delhi: Elsevier, 2009.)

The interpeduncular fossa and superficial attachments of cranial nerves are described in brief.

Interpeduncular fossa (Fig. 6.10)

The interpeduncular fossa is a rhomboidal space bounded on either side by crus cerebri of cerebral peduncles, anteriorly by optic chiasma and optic tracts; and posteriorly by the pons. The interpeduncular fossa contains: (a) a raised area of grey matter lying anterior to the mammillary bodies called **tuber**

cinereum, (b) two small spherical bodies called **mammillary bodies**, (c) a narrow stalk which connects the hypophysis cerebri with the tuber cinereum called **infundibulum**, (d) posterior perforated substance, which is a layer of grey matter in the angle between the crus cerebri, and is pierced by central branches of the posterior cerebral arteries, and (e) **oculomotor nerve** which emerges immediately dorsomedial to the corresponding crus.

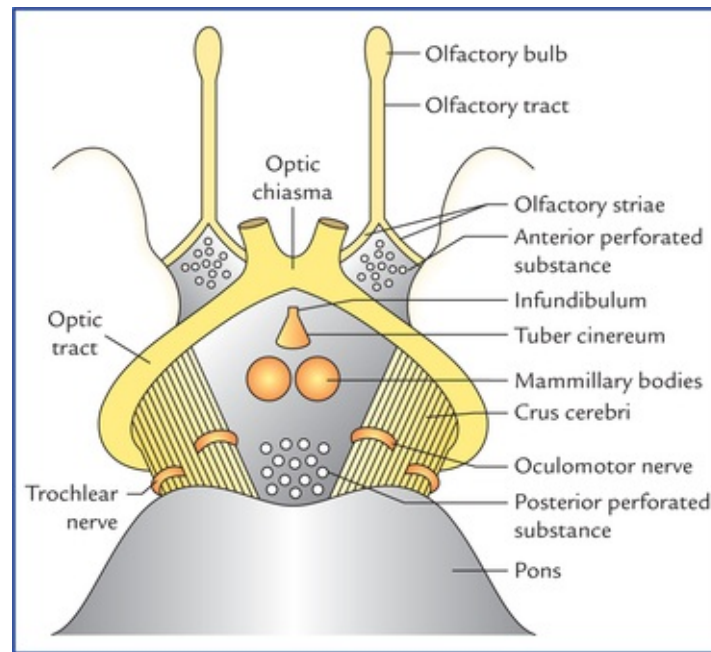


FIG. 6.10 Boundaries and contents of interpeduncular fossa.

The divisions and functions of the brain are summarized in [Table 6.1](#).

Table 6.1
Divisions and functions of the brain

Brain region	Function
Cerebrum	Conscious perception of sensory modalities, conscious motor activity, cognition,* etc.
• Basal ganglia	Control of muscular activity and posture. Largely inhibit unintentional movement
• Limbic system	Autonomic response to smell, emotion, mood, recent memory, etc.
Diencephalon	
• Thalamus	Major sensory relay centre; influences mood and movement
• Hypothalamus	Major control centre for maintaining homeostasis and regulating endocrine function
• Subthalamus	Associated with basal ganglia and help in coordinating motor functions
• Epithalamus	Sleep-wake cycle, smell
Brainstem	Contains ascending and descending nerve tracts, houses nuclei of all cranial nerves except 1st and 11nd
• Midbrain	Visual and auditory reflex centres
• Pons	Relay centre between cerebrum and cerebellum, houses sleep centre
• Medulla	Centre for several vital autonomic reflexes, viz. heart rate, breathing, swallowing and vomiting
Cerebellum	Control of muscle movement and tone; regulates extent of intentional movement

*Cognition – The intellectual functions or ways of knowing and thinking including the processes of perceiving, imagining, remembering, reasoning and judging.

Superficial Attachments of the Cranial Nerves

All the 12 pairs of cranial nerves are attached on the ventral aspect of the brain except the fourth pair (trochlear nerves) which are attached on the dorsal aspect.

Each cranial nerve enters or leaves the brain surface at its superficial attachment and the fibres, which it contains, either arise from (efferent or motor fibres) or terminate in (afferent or sensory fibres) nuclei within the brain.

The first two pairs are attached to the forebrain; the third and fourth to the midbrain; the fifth to the pons, and the remainder to the medulla oblongata. The eleventh cranial nerve also receives a root from the upper part of spinal cord.

Sites of Attachments

- **Olfactory nerves.** There are about 20 olfactory nerves on each side. They arise from olfactory epithelium of nasal cavity and pass through the cribriform plate of ethmoid and end in the olfactory bulb, which lies on the orbital surface of the frontal lobe. They are so delicate that no trace of them is seen on the olfactory bulb when the brain is removed from the cranial cavity.
- **Optic nerve.** This is a thick cylindrical nerve which arises from the retina and joins the anterolateral angle of the optic chiasma.
- **Oculomotor nerve.** It emerges from the groove on the medial aspect of the cerebral peduncle in the posterior part of the inter-peduncular fossa.
- **Trochlear nerve.** It is a slender nerve which emerges on the dorsal aspect of the midbrain, lateral to the median plane. It winds round the lateral aspect of the midbrain towards the interpeduncular fossa immediately superior to the pons.
- **Trigeminal nerve.** It is largest of the cranial nerves and attached to the junction of the pons and middle cerebellar peduncle by two roots: a large lateral sensory root, and a small medial motor root.
- **Abducent nerve.** It emerges at the inferior border of the pons, opposite to the upper end of the pyramid.
- **Facial nerve.** It emerges at the inferior border of pons lateral to the abducent nerve by two roots: a thick medial motor root and a slender lateral sensory root called *nervus intermedius*.
- **Vestibulocochlear nerve.** It consists of two nerves: vestibular and cochlear which are attached in the cerebellopontine angle. The cochlear nerve lies posterior to the inferior cerebellar peduncle and vestibular anterior to it.
- **Glossopharyngeal nerve.** It emerges by number of rootlets from a groove between the olive and inferior cerebellar peduncle.
- **Vagus nerve.** It also emerges by number of rootlets from a groove between the olive and inferior cerebellar peduncle below the rootlets of glossopharyngeal nerve.
- **Accessory nerve.** It has two parts: cranial and spinal. The cranial part emerges by number of rootlets from medulla below the rootlets of vagus nerve and it is joined by spinal part, the rootlets of which are attached to the upper five cervical spinal segments.
- **Hypoglossal nerve.** It arises by a row of rootlets from a groove between the pyramid and olive.

Spinal Cord

The spinal cord is the long cylindrical lower part of the CNS occupying the upper two thirds of the vertebral canal. It is continuous rostrally with the medulla oblongata at foramen magnum and ends caudally as tapered **conus medullaris**, at the level of lower border of first lumbar vertebra (L1).

It gives origin to 31 pairs of spinal nerves. The region of origin of a pair of spinal nerves is called **spinal segment**.

The spinal cord has central grey and peripheral white matter. In transverse section the grey matter has an irregular H-shape, and looking somewhat similar to a butterfly (Fig. 6.11) with two **anterior horns**, two **posterior horns** and a **grey commissure** containing a central canal. In the thoracic and upper two lumbar segments there are also **lateral horns** because these segments of spinal cord are associated with the autonomic nervous system.

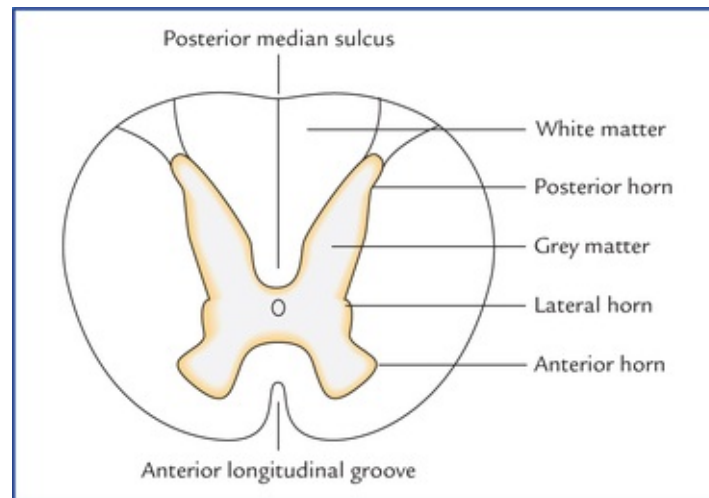


FIG. 6.11 Transverse section of the spinal cord at the level of thoracic segments.

In three-dimensional view of grey matter of a spinal segment, the horns appear as long vertical pillars (Fig. 6.12) hence now a days, they are termed grey columns. However, the term 'horn' is still frequently used in texts on physiology and medicine.

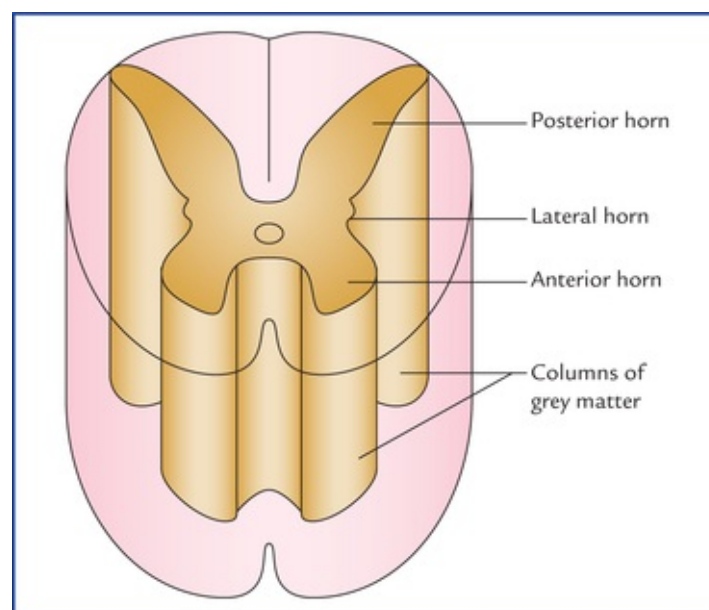


FIG. 6.12 Three-dimensional view of grey matter of a spinal segment.

In each half of the spinal cord, the white matter is divided into **anterior, lateral** and **posterior white columns** or funiculi.

Each funiculus is subdivided into fasciculi or nerve tracts. *The individual nerve fibres carrying action potentials to (ascending) or from (descending) the brain are usually grouped together to form fasciculi/tracts.*

The spinal cord is extremely important for the overall function of the nervous system. It forms the communication link between the brain and the peripheral nervous system below the head, integrating incoming information and producing responses through reflex mechanisms.

Ventricular System and CSF in CNS

There are four ventricles of the brain (Fig. 6.13): two lateral ventricles, a third ventricle, and a fourth ventricle.

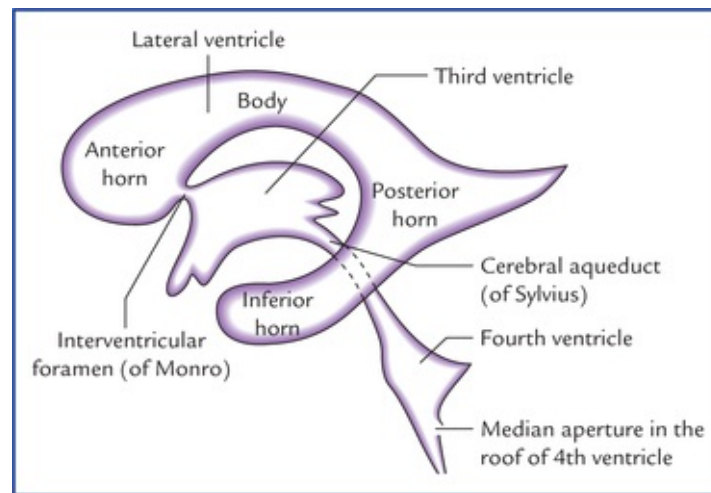


FIG. 6.13 The ventricles of the brain.

The two **lateral ventricles**, one in each cerebral hemisphere, form the largest component of the ventricular system.

They occupy a considerable part of the cerebral hemisphere and are separated from each other by the septum pellucidum, extending between the corpus callosum and fornix (Fig. 6.6). The **third ventricle** is a narrow slitlike cavity of the diencephalon. Two lateral ventricles are connected with the third ventricle via the interventricular foramina (of Monro). The third ventricle communicates via the cerebral aqueduct of midbrain to the fourth ventricle, a cavity within the hindbrain. The fourth ventricle in turn is continuous with the **central canal** of the spinal cord. The central canal has a small dilatation at its inferior end, the **terminal ventricle**.

The cerebrospinal fluid is formed in the ventricles by the choroid plexuses and passes through apertures in the roof of fourth ventricle into the subarachnoid space around brain and spinal cord.

Meninges and CSF

The brain and spinal cord are surrounded by three protective membranes called *meninges*. From within outwards these are: (a) pia mater, (b) arachnoid mater, and (c) dura mater.

The subarachnoid space between the pia and arachnoid mater contains the cerebrospinal fluid (CSF)

and the major arteries.

Clinical Correlation

Disorders Of The Central Nervous System

- **Multiple sclerosis:** It is a debilitating, degenerative disorder of unknown cause. Multiple sclerosis is characterized by multifocal demyelination throughout the white matter of the CNS.
- **Seizure disorder (epilepsy):** It is characterized by episodic, sudden, violent, and involuntary contractions of group of muscles, resulting from excessive discharge of cerebral neurons.
- **Meningitis:** It is the inflammation of meninges caused by bacteria and viruses.
- **Encephalitis:** The inflammation of brain and spinal cord that also involves the meninges.
- **Space-occupying lesions:** A space-occupying lesion is an abnormal growth of neural or non-neural tissue within the cranial cavity that may be primary or secondary (metastatic cancer).
- **Herniation of the brain:** The herniation of brain occurs due to an increased intracranial pressure produced by a space-occupying lesion such as tumour. The various types of brain herniation are (Fig. 6.14):

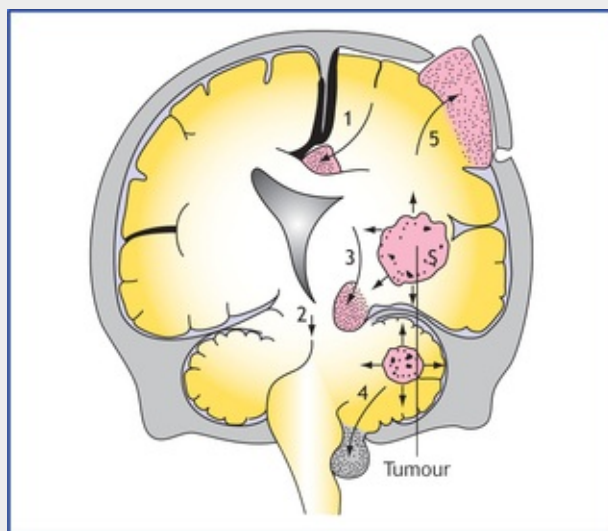


FIG. 6.14 The types of brain herniation: (1) cingulate gyrus herniation, (2) lateral tentorial herniation (temporal uncal herniation), (3) central tentorial herniation, (4) cerebellar tonsil herniation, and (5) herniation of brain-tissue through the craniotomy defect. *Adapted from: Singh, Vishram. Clinical and Surgical Anatomy, 2nd edn. New Delhi: Elsevier; 2007.*

- **Cingulate gyrus herniation** (subfalcine herniation), occurs below the falx cerebri.
- **Transtentorial (uncal) herniation**, is the herniation of medial edge of the temporal lobe (uncus) through the tentorial notch.
- **Central tentorial herniation**, is a vertical displacement of the brainstem and diencephalon through the tentorial notch.
- **Tonsillar herniation**, is the protrusion cerebellar tonsil through the foramen magnum.

Herniation through cranial defecture may occur.

- **Cerebrovascular accidents (stroke):** It is a sudden, focal neurological deficit resulting from impaired circulation of the brain. It is associated with a cardiovascular disease such as thrombosis, embolism, or haemorrhage which causes impairment of circulation.

Clinical Problems

1. Explain why the older individuals often show: (a) slow response to various stimuli, (b) diminution in sensory perception, (c) decline in problem solving skills, and (d) decreased efficiency for recent memory.
2. Why do patients suffering from space-occupying lesions within skull, viz. tumour, haematoma and abscess, commonly complain of severe headache and vomiting?
3. What is **contre-coup injury of brain**, and how does it occur?
4. What injuries may occur to the brain in a motor-bike accident, how wearing of a crash helmet helps to prevent or minimize such injuries to the brain?
5. Explain how spinal cord injury in the cervical region above the level of 3rd spinal segment can cause sudden death.
6. What are the five most common brain tumours?

Clinical Problem Solving

1. These changes occur due to the reduction in the number of cerebral **neurons** at the rate of 1% a year beginning at 50 years of age. However, if the brain is kept active, the **reserve cerebral neurons** may delay the onset of such symptoms.
2. Since the skull is a rigid container of fixed volume, the space-occupying lesions add to the normal bulk of the intracranial contents producing an increased intracranial pressure. The severe headache occurs due to stretching of dura mater, and vomiting due to stimulation of 'vomiting centre' in brainstem because of increased intracranial pressure.
3. The contre-coup injury to brain is an injury to the pole of the brain opposite to the side of impact. The head is freely mobile on the neck and the brain is floating in the cerebrospinal fluid within the skull. Therefore, when the head is hit suddenly and with great force on the back or front, the brain is displaced in opposite direction and strikes against the cranial bones on that side and gets injured.
4. The brain is floating in the cerebrospinal fluid within the cranium, so that a severe blow to the head or sudden deceleration leads to the displacement of the brain. This may cause intracranial haemorrhage (viz. extradural, intracerebral, etc.) leading to pressure symptoms such as unconsciousness, coma, etc. A crash helmet helps to protect the brain by cushioning the blow on the head and slows down rate of deceleration of the brain.
5. Sudden death occurs due to spinal shock, and respiratory arrest following paralysis of diaphragm and intercostal muscles. As the lesion is above the origin of phrenic nerves (C3, 4 and 5) supplying diaphragm and intercostal nerves (from thoracic segments)

supplying intercostal muscles.

6. The five most common brain tumours are as follows:

- (a) **Glioblastoma multiforme:** It is the commonest and most fatal brain tumour and arises from astrocytes.
- (b) **Meningioma:** It is the second most common tumour and arises from meninges (arachnoid granulations).
- (c) **Schwannoma:** It arises from Schwann cells.
- (d) **Ependymoma:** It arises from ependymal lining of the brain.
- (e) **Medulloblastoma:** It arises from neurectodermal cells.

Spinal Cord

The spinal cord is the lower elongated part of the central nervous system (CNS). It is cylindrical in shape, slightly flattened anteroposteriorly and occupies the upper two-third of the vertebral canal.

Spinal cord measures about 45 cm (18”) in adult male and 42 cm in adult female, and weighs about 30 g. It extends as a downward continuation of medulla oblongata from the upper border of the posterior arch of first cervical vertebra (C1) to the lower border of the first lumbar vertebra (L1). Its lower tapering extremity is called **conus medullaris**. The apex of conus medullaris continues downwards as a thin, thread-like filament called **filum terminale**. Spinal cord provides attachment to 31 pairs of spinal nerves which connect it to the tissues of the trunk, girdles, limbs, and the viscera.

The spinal cord contains large number of ascending and descending pathways, which serve as conduits for nervous information, passing to and fro between different parts of the body and the brain.

Functions of the spinal cord

- The execution of simple reflexes.
- The transmission of impulses to and from the brain.

Positional Changes Of The Cord

Up to the 3rd month of intrauterine development, the spinal cord extends throughout the entire length of the vertebral canal and the spinal nerves pass through the intervertebral foramina at their level of origin. Thereafter, the vertebral column grows faster than the spinal cord and the terminal end of the spinal cord gradually shifts to a higher level. Consequently at birth spinal cord ends at the level of third lumbar vertebra while in adult, it terminates at the level of lower border of L1 (or the intervertebral disc between the L1 and L2). The knowledge of these variations in the vertebral level of the lower end of the cord is important to avoid injury to the cord while performing lumbar puncture, especially in children.

Spinal Meninges

The spinal cord is surrounded by three protective membranes called **spinal meninges**. From outside inwards these are: dura mater, arachnoid mater, and pia mater ([Figs 7.1](#) and [7.2](#)).

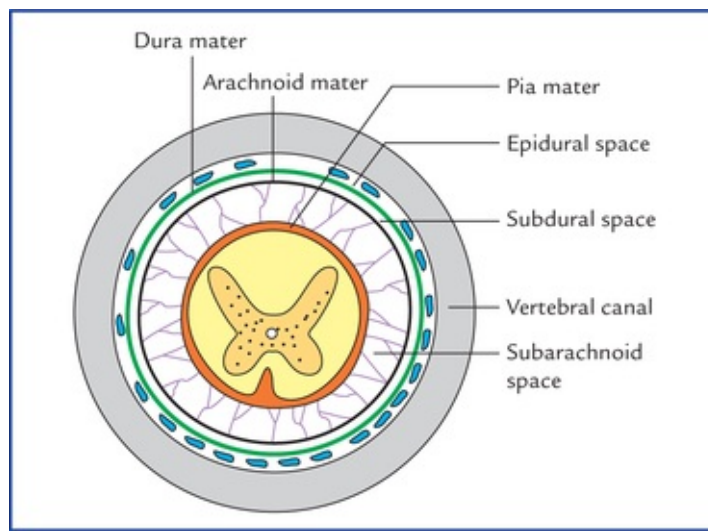


FIG. 7.1 Schematic transection of vertebral canal showing spinal cord and its surrounding meninges.

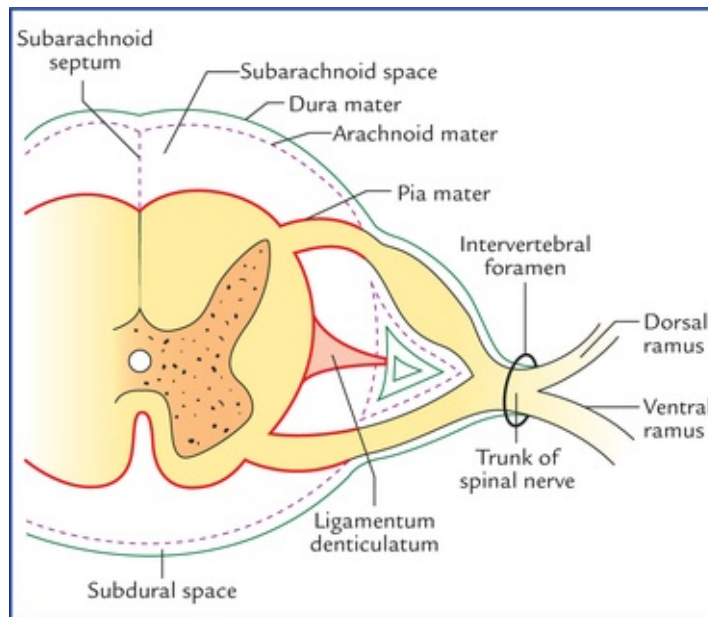


FIG. 7.2 Schematic transverse section of spinal cord showing meninges and formation of meningeal sheaths onto the spinal nerve roots.

Dura Mater

The spinal dura extends from foramen magnum to the lower border of second sacral vertebra (S2).

The space between spinal dura and vertebral canal is termed **epidural space**. This space contains loose areolar tissue, semiliquid fat and internal vertebral venous plexus.

The space between dura and arachnoid mater termed **subdural space**. It contains capillary layer of fluid.

The spinal dura differs from cranial dura. The differences between the two are enumerated in [Table 7.1](#).

Differences between spinal and cranial dura

Spinal dura	Cranial dura
Single layered and consists of meningeal layer only	Double layered and consists of an inner meningeal layer and outer endosteal layer
Does not form folds	Forms folds, viz. falx cerebri, falx cerebelli, tentorium cerebelli and diaphragma sellae
Epidural space present	Epidural space absent

Arachnoid Mater

Arachnoid mater is a thin delicate transparent avascular membrane which invests the spinal cord loosely. Above it is continuous with the arachnoid mater of the brain and below it extends up to the lower border of the second sacral vertebra (S2).

Pia Mater

Pia mater is a thin highly vascular membrane that closely invests the spinal cord and continues below the spinal cord as a thin thread-like prolongation, the **filum terminale**.

The **subarachnoid space** between the pia mater and the arachnoid mater is filled with cerebrospinal fluid (CSF). Above it is continuous with subarachnoid space around the brain. Distal to the termination of spinal cord, the sub-arachnoid space around the filum terminale, becomes roomy, forming a pool of CSF called **lumbar cistern**. The lumbar puncture is done at this site to take out the CSF (Fig. 7.3).

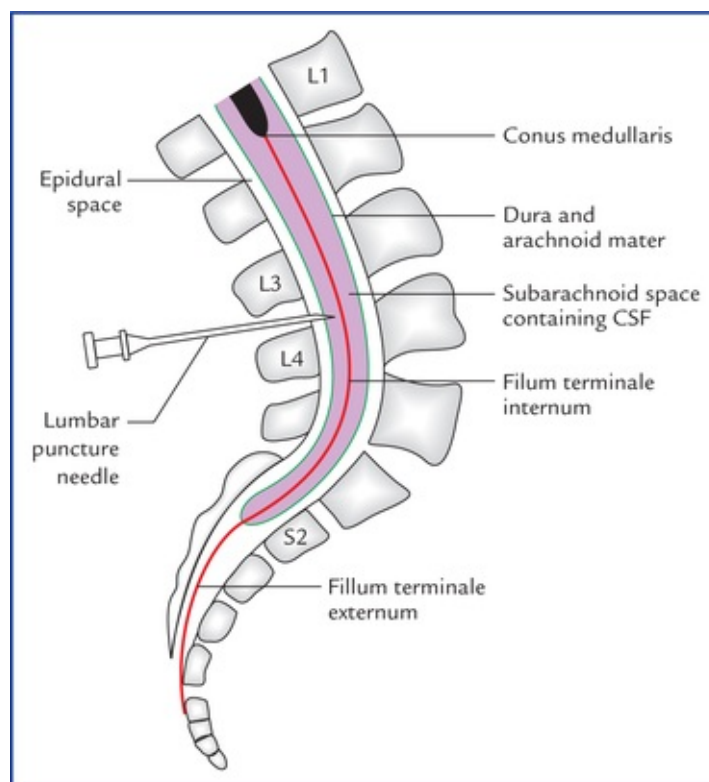


FIG. 7.3 Sagittal section through lumbosacral region showing conus medullaris, filum terminale (internum and externum), lower end of subarachnoid space and site of lumbar puncture.

N.B. The spinal subarachnoid space is commonly termed 'spinal intrathecal space' by the clinicians.

Clinical Correlation

Lumbar puncture

Lumbar puncture is done to withdraw cerebrospinal fluid for various diagnostic and therapeutic purposes. The puncture should be done well below the termination of the cord, i.e. lower border of L1.

A horizontal line joining the highest points of the iliac crests passes through the spine of the fourth lumbar vertebra. Therefore, the interspinous spaces immediately above and below this landmark can be used with safety. The interspinous space between L3 and L4 is the most preferred site (Fig. 7.3). Because in this region subarachnoid space is more roomy and contains only filum terminale and roots of lumbar, sacral and coccygeal nerves forming the cauda equina. During this procedure, the spine must be fully flexed with patient either lying on the side or seated. So, that the interspinous spaces are opened up to their maximum extent and lower end of spinal cord is slightly raised. The needle is passed inwards and somewhat crani-ally exactly in the midline. The supraspinous and interspinous ligaments are traversed; and then dura mater is penetrated, the latter with a distinct feel of 'give way'. Occasionally, the root pain is experienced if the roots of cauda equina are impinged upon, but usually, they float clear of the needle.

Processes of the pia mater (also called special parts of the pia mater)

1 Filum terminale

It is a delicate, glistening white thread-like structure extending from tip of conus medullaris to the first coccygeal vertebra (dorsal aspect). The filum terminale is about 20 cm long and mainly composed of non-nervous fibrous tissue (pia), but few nerve fibres (considered to be the rudiments of 2nd, 3rd and 4th coccygeal nerves) are found embedded in its upper part.

The central canal of spinal cord extends into the upper part of the filum terminale for about 5 mm.

The filum terminale consists of two parts: (a) filum terminale internum, and (b) filum terminale externum. The **filum terminale internum** is about 15 cm in length and lies within the dural sac. The **filum terminale externum** is about 5 cm in length and lies outside the dural sac, i. e. below the level of second sacral vertebra (Fig. 7.3).

2 Subarachnoid septum

It is a mid-sagittal fenestrated pial septum which connects the dorsal surface of the spinal cord with the arachnoid mater.

3 Linea splendens

The pia gives off a septum into the anterior median fissure. Where this process is given off, the pia mater

presents a thickening, called *linea splendens*.

4 Ligamenta denticulata

These are two transparent ribbon-like thickened bands of pia mater (one on each side) extending laterally between posterior and anterior nerve roots from pia mater covering the cord. The lateral margin of each band presents 21 tooth-like processes which pierce the arachnoid, to be attached to the inner surface of the dura mater between the points of emergence of the spinal nerves (Fig. 7.4).

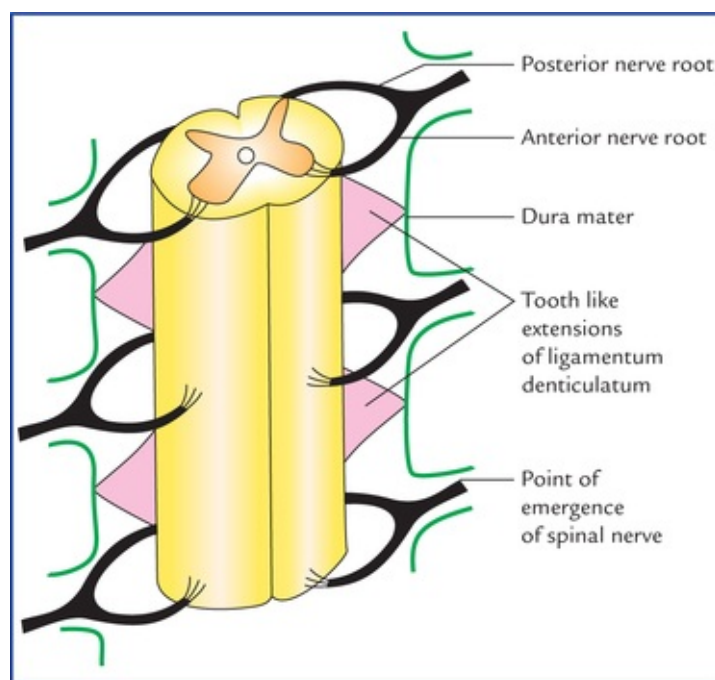


FIG. 7.4 Anterior view of part of spinal cord, showing position of ligamenta denticulata and their attachments to the dura mater.

The ligamenta denticulata help to anchor the spinal cord in the middle of subarachnoid space.

The first teeth of ligamentum denticulatum lies at the level of foramen magnum while the last between T12 and L1 spinal nerves.

Clinical Correlation

The ligamenta denticulata serve as a guide to neuro-surgeons during cordotomy operation. When sensory tract requires section to relieve pain, the knife is put in front of the ligament, and if the section of motor tract (*viz.* pyramidal tract) is desired, the knife is placed behind the ligament.

The lowest tooth is forked, and the posterior root of the first lumbar nerve lies on the outer prong of the fork (Fig. 7.5). In the lower region of the spinal cord, it is the surgeon's guide to the first lumbar nerve and gives him a nerve root of known number from which he can determine the position of whatever nerve roots he is in search of.

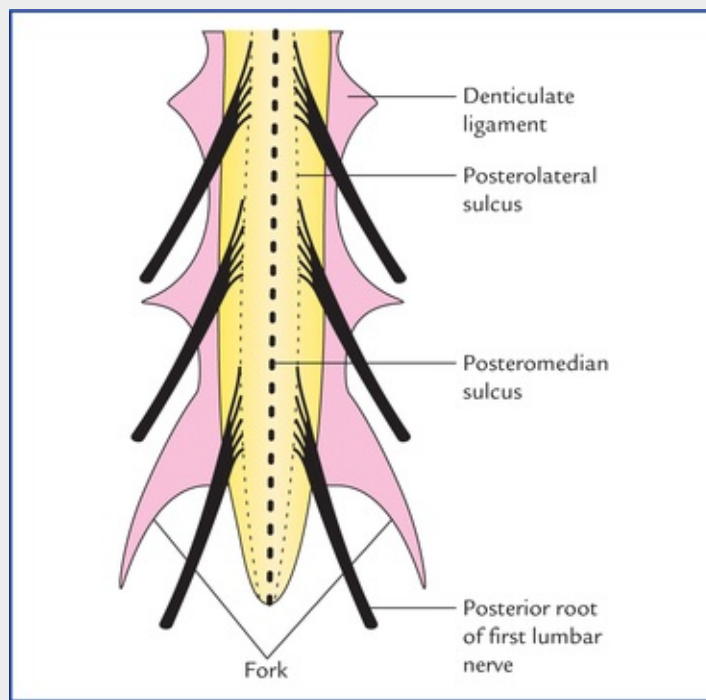


FIG. 7.5 Posterior view of a part of spinal cord showing forked lowest tooth of ligamentum denticulatum.

External Features of the Spinal Cord

The external features of the spinal cord are (Fig. 7.6):

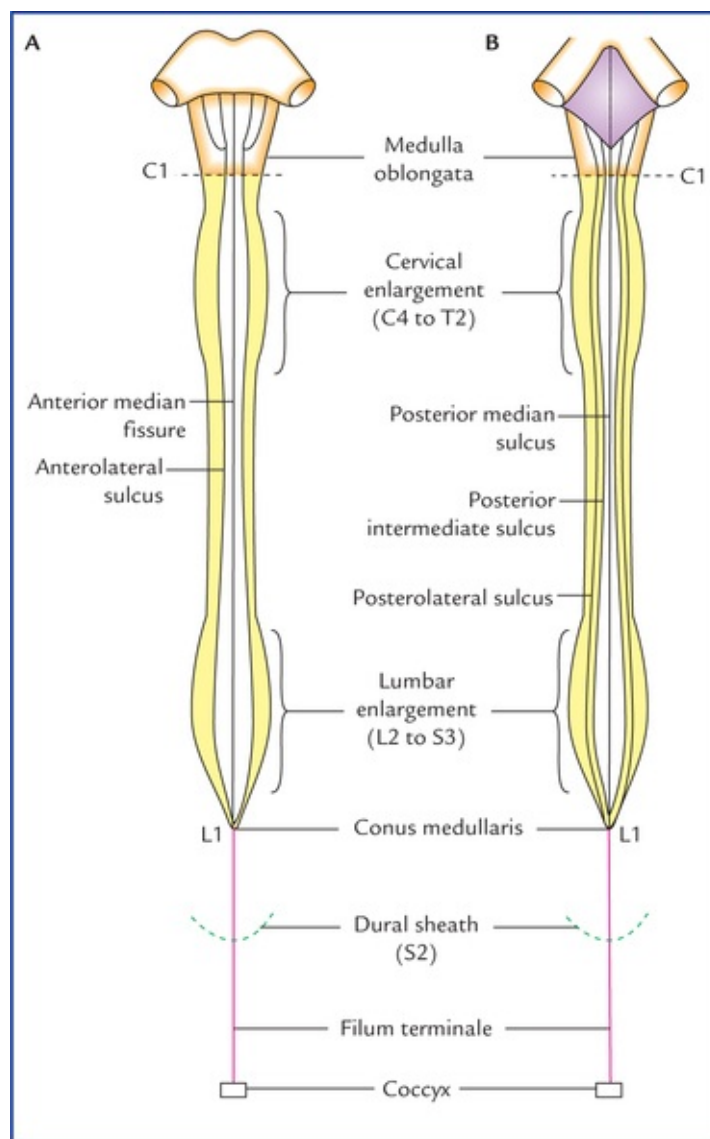


FIG. 7.6 External features of the spinal cord: (A) on anterior aspect, and (B) on posterior aspect. Also note the important levels (C1, L1, S2, etc.) in relation to the spinal cord.

1. Fissures and sulci.
2. Attachment of spinal nerves.
3. Enlargements.
4. Cauda equina.

Fissures and Sulci

The anterior aspect of the spinal cord (Fig. 7.6A) presents anterior median fissure, and two anterolateral sulci while the posterior aspect (Fig. 7.6B) presents: posteromedian sulcus, two posterolateral and two posterointermediate sulci.

The *anterior median fissure* is deep and extends along the entire length of the cord. The anterior spinal artery runs in it.

The *posterior median sulcus* is a faint longitudinal groove. From its floor, a septum of neuroglial tissue (posterior median septum) extends into the substance of the cord to a variable extent.

The surface of the cord is divided into two symmetrical halves by an anterior median fissure and a posterior median sulcus.

Each half of the cord is further subdivided into posterior, lateral and anterior regions by anterolateral

and posterolateral sulci. Through anterolateral sulcus emerge the ventral root fibres and through posterolateral sulcus enter the dorsal root fibres of the spinal nerves.

Attachment of Spinal Nerves

Thirty-one pairs of spinal nerves emerge from the sides of the cord.

Of these, 8 are cervical, 12 are thoracic, 5 are lumbar, 5 are sacral, and 1 is coccygeal.

The cervical nerves leave the vertebral canal above the corresponding vertebrae with the exception of eighth, which emerges between seventh cervical and first thoracic vertebrae. The remainder spinal nerves emerge below the corresponding vertebrae. Each spinal nerve is attached to the cord by two roots, anterior motor root and posterior sensory root. The posterior root has a ganglion, the posterior root ganglion consisting of pseudounipolar cells. Each of the two roots is made up of number of rootlets that arise from the spinal cord over a certain length (Fig. 7.7). The rootlets of posterior root enter the dorsolateral aspect of the cord along the posterolateral sulcus whereas the rootlets of anterior root emerge from the anterolateral sulcus/anterolateral aspect of cord opposite to the anterior grey column.

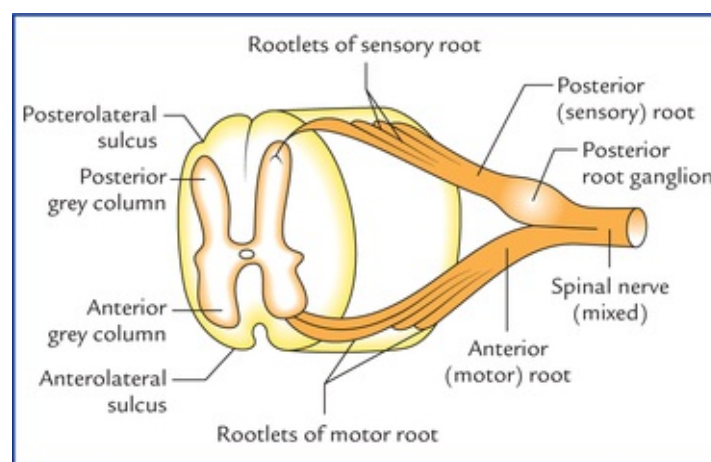


FIG. 7.7 A section of spinal cord showing attachment of nerve roots on one side.

Spinal segments

Like the vertebral column, the spinal cord is also segmented though the segments are not visible externally. The part of spinal cord to which a pair of spinal nerves (right and left) is attached is known as **spinal segment** (Fig. 7.8).

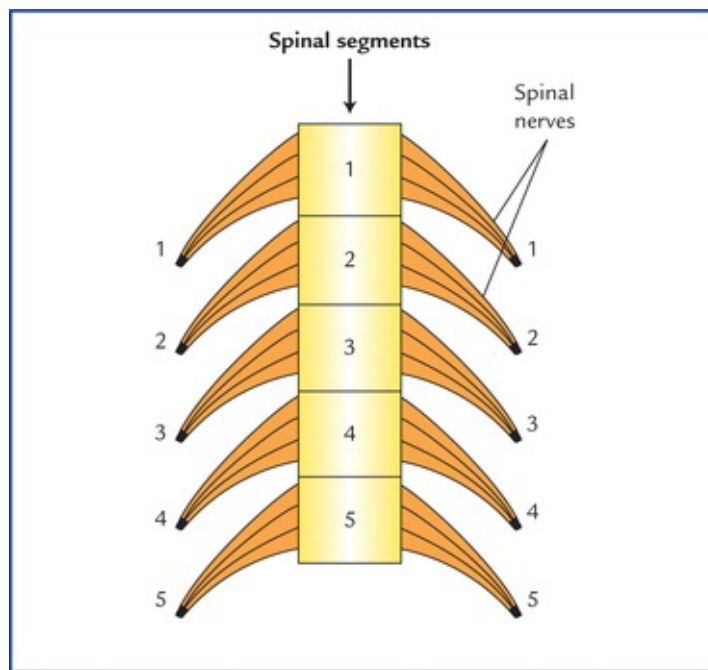


FIG. 7.8 Schematic diagram to represent the spinal segments.

The number of spinal segments corresponds to the number of vertebrae in thoracic, lumbar and sacral regions, but in cervical region, one segment is more than the number of vertebrae, whereas in coccygeal region there is only one segment for four coccygeal vertebrae.

Thus, the spinal cord is made up of 31 spinal segments: 8 cervical, 12 thoracic, 5 lumbar, 5 sacral, and one coccy-geal. Since, the length of spinal cord (45 cm) is smaller than the length of vertebral column (65 cm), the spinal segments are, short and crowded, especially in the lower part of the cord. Thus, the spinal and vertebral segments (spines) do not lie at the same level. *The spinal segments as a rule always lie above their numerically corresponding vertebral spines.* In the lower part of the spinal cord, they lie well above their corresponding vertebrae (Fig. 7.9). For example, the lumbar segments are related to the thoracic vertebrae.

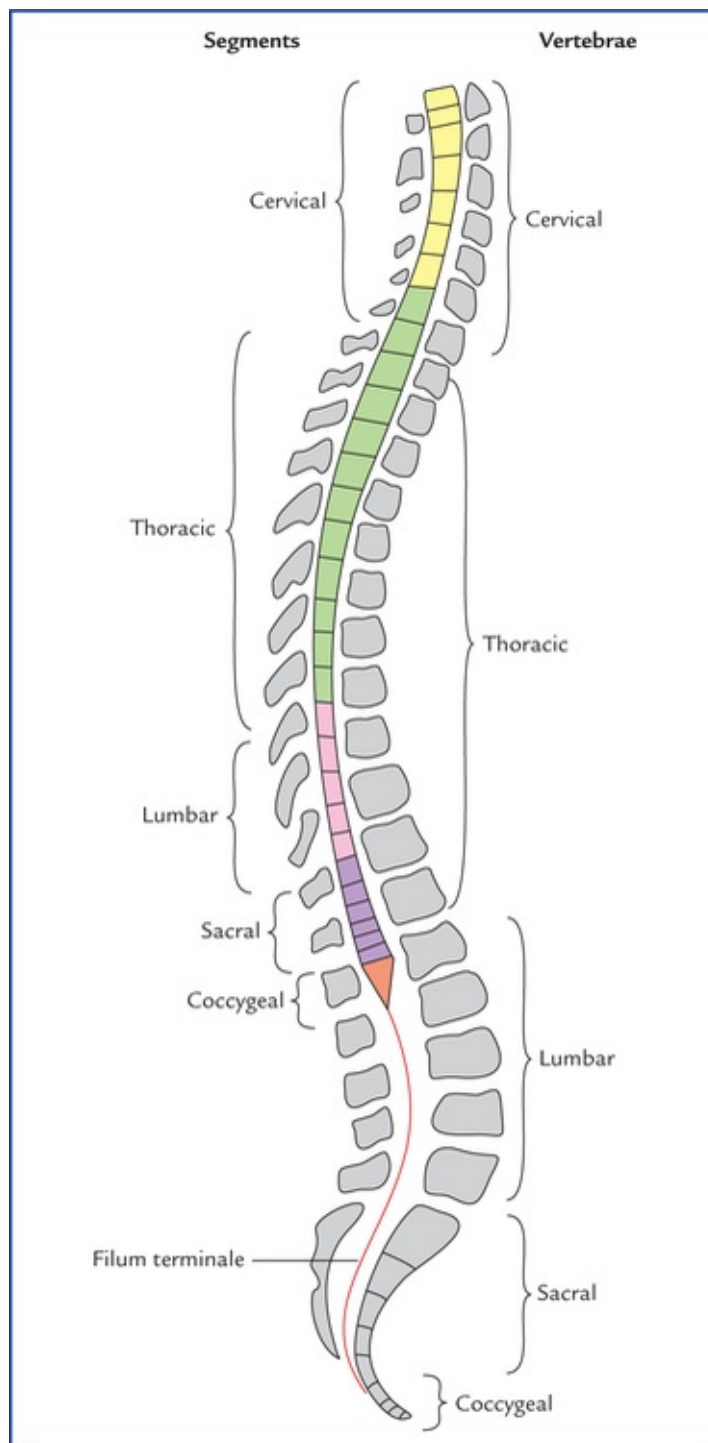


FIG. 7.9 The spinal segments and their corresponding vertebrae levels.

Approximate vertebral levels matched to spinal cord segments are presented in [Table 7.2](#).

Table 7.2

Approximate vertebral levels of the spinal cord segments

Regions	Spinal segments	Vertebral level	General rule
Upper cervical	C2	C2	Same level
Lower cervical	C6	C5	One vertebra above
Upper thoracic	T5	T3	Two vertebrae above
Lower thoracic	T10	T7	Three vertebrae above
Lumbar	L1–L5	T10–T11	Three to five vertebrae above
Sacral and coccygeal	S1–S5 and C × 1	T12–L1	Six to ten vertebrae above

These levels, although not strictly accurate, give a reliable assessment of the level of cord compression following an injury or disease of the surrounding vertebrae. The approximate relationship helps in understanding the consequences of spinal injuries and clinical findings of motor and sensory levels. They also help in planning for surgical approach for diagnostic and therapeutic purposes.

Enlargements

The spinal cord is roughly cylindrical in shape with an average diameter of about 1.25 cm. However, opposite to the attachments of the nerve roots contributing to the formation of brachial and lumbosacral plexuses, the spinal cord presents definite fusiform swellings called **cervical** and **lumbar enlargements** respectively (Fig. 7.6A, B).

These enlargements are produced due to the presence of large number of large motor neurons in these regions to supply the musculature of the upper and lower limbs and associated girdles.

The *cervical enlargement* extends from C5 to T1 spinal segments whereas *lumbar enlargement* extends from L2 to S3 spinal segments.

The vertebral levels of these enlargements are quite different from those of spinal segments, viz. the cervical enlargement lies opposite C3 to T1 vertebrae and lumbar enlargement lies opposite T9 to L1 vertebra.

The two enlargements are compared in Table 7.3.

Table 7.3

Comparison between cervical and lumbar spinal enlargements

	Cervical enlargement	Lumbar enlargement
Extent	From C5 to T1 spinal segments	From L2 to S3 spinal segments
Vertebral level	From C3 to T1 vertebrae	From T9 to L1 vertebrae
Widest circumference	About 38 mm at the level of C6 segment	About 35 mm at the level of S1 segment
Innervation	Muscles of upper limbs and their associated girdles	Muscles of the lower limbs and their associated girdles

Cauda Equina

Since the cord is shorter than the vertebral column, length and obliquity of spinal nerve roots increase progressively from above downwards, so that spinal nerves may emerge through their respective intervertebral foramina (Fig. 7.10A). As a result the nerve roots of lumbar, sacral and coccygeal nerves from the caudal part of the cord takes more or less a vertical course and form a bunch of nerve fibres around the filum terminale called **cauda equina** because of its fancied resemblance to the tail of a horse

(cauda – tail; equina – horse). The cauda equina consists of the roots of the lower four pairs of lumbar, five pairs of sacral and one pair of coccygeal nerves (Fig. 7.10B).

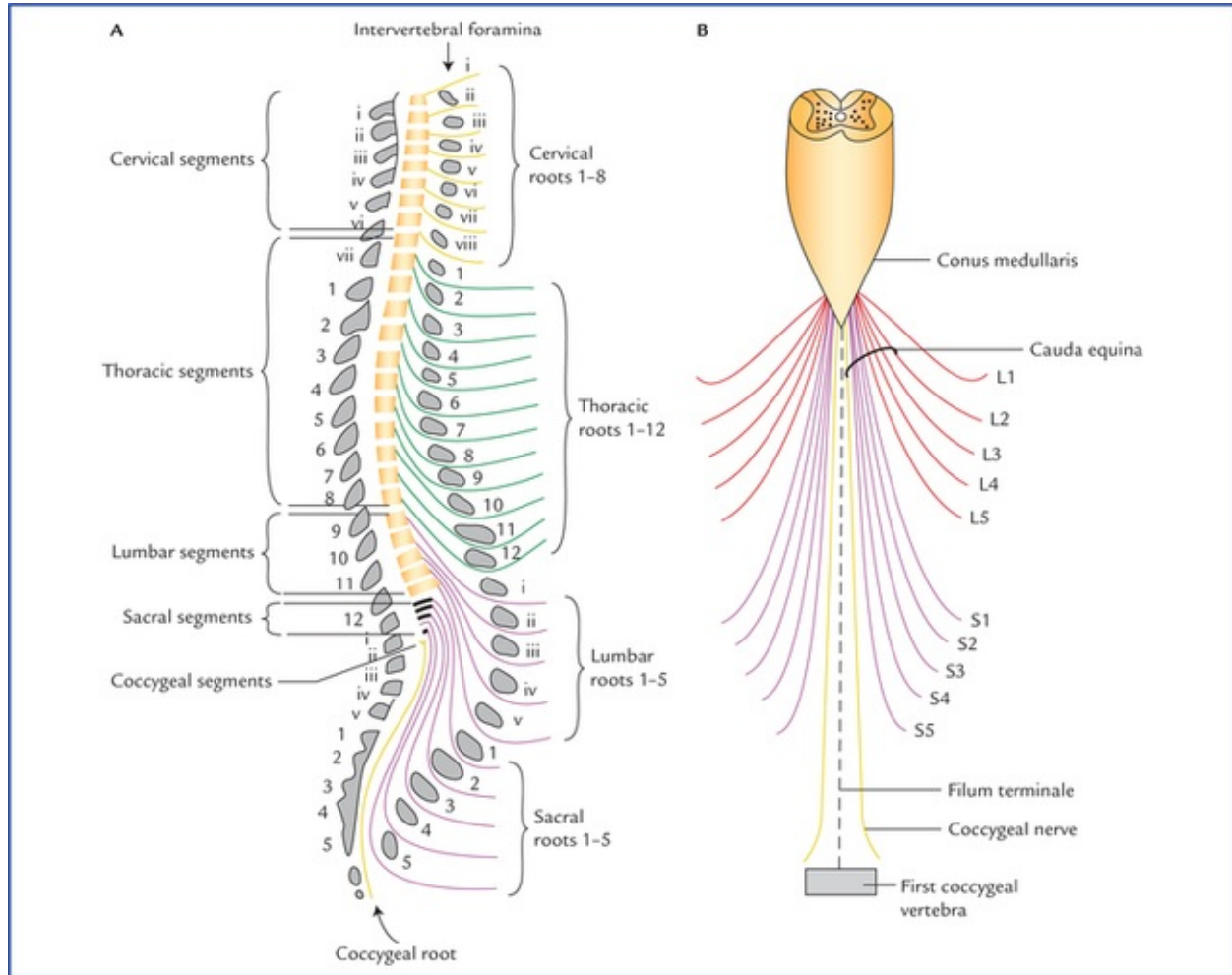
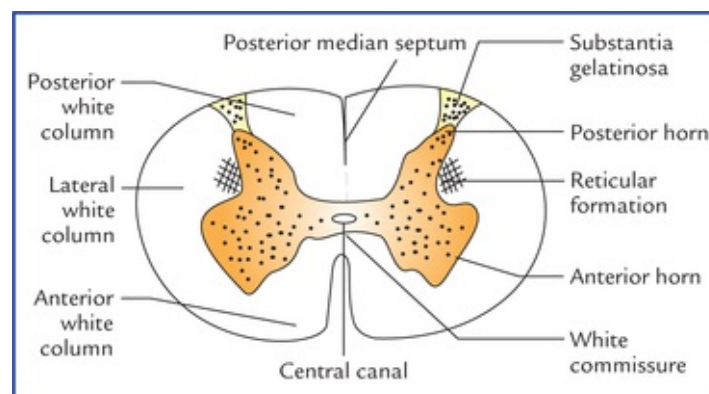


FIG. 7.10 (A) Lateral view showing exit of emerging spinal nerves through the intervertebral foramina. (B) Lower end of spinal cord with filum terminale and lumbar, sacral and coccygeal nerve roots. The spinal nerve roots forming the cauda equina are encircled.

Internal Structure of the Spinal Cord

The cross-section of the spinal cord (Fig. 7.11) shows that it consists of an inner core of grey matter, and a peripheral zone of white matter.



Grey Matter

In cross-section of cord the grey matter is seen as H-shaped (or butterfly-shaped) fluted column, extending throughout the length of the spinal cord. It is divided into symmetrical right and left comma-shaped masses which are connected across the midline by a *transverse grey commissure*. The central canal of the cord passes through the centre of grey commissure. The canal is surrounded by *substantia gelatinosa centralis*. The lateral comma-shaped mass of grey matter is further divided by a transverse grey commissure into a narrow elongated *posterior horn*, and a broad *anterior horn*.

In the thoracic region and upper two lumbar segments (T1 to L2), a triangular projection juts out from the side of lateral grey mass between the anterior and posterior horns, nearly opposite to the grey commissure. It is called *lateral horn*. The posterior horns are connected to the surface by a gelatinous substance called *substantia gelatinosa*. The amount of grey matter and shapes of its horns, and amount of white matter varies at different levels (Fig. 7.12).

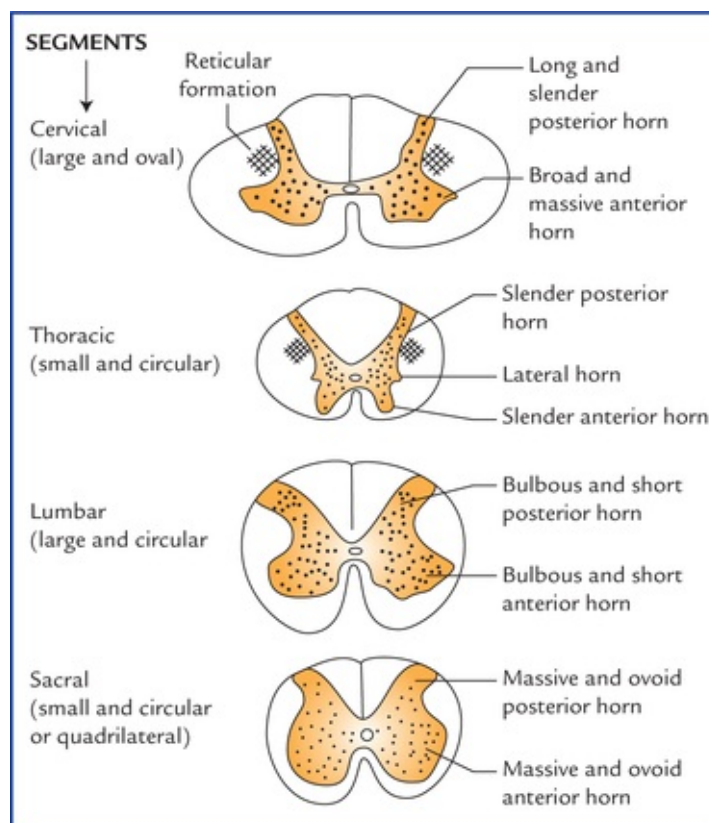


FIG. 7.12 Transverse sections of the spinal cord at different levels showing the arrangement of grey and white matters.

The amount of the grey matter seen at a particular level is well correlated with the mass of tissue it supplies. It is, therefore, maximum in the regions of cervical and lumbar enlargements, which supply the limbs and their associated girdles.

The horns are thus largest in the regions—cervical and lumbar enlargements.

The amount of white matter in the spinal cord undergoes progressive increase from below upwards. This occurs due to following facts:

1. Progressively more and more ascending fibres are added to the cord from below upwards.

2. Number of descending fibres decreases in the cord from above downwards as some of them terminate in each spinal segment.

For this reason, the amount of white matter is massive in the cervical segments and very less in the sacral segments.

Table 7.4 reveals the characteristic features of the spinal segments in different regions of the spinal cord.

Table 7.4
Characteristic features of spinal segments as seen in transverse sections at various levels of the spinal cord

Features	Levels			
	Cervical	Thoracic	Lumbar	Sacral
Outline of section	Oval (greatest diameter transverse)	Oval to circular	Nearly circular	Circular to quadrilateral
Grey matter	Large	Small	Large	Relatively large
• Posterior horn	Slender and extends far posteriorly	Slender	Bulbous	Massive
• Lateral horn	Massive	Slender	Bulbous	Massive
• Anterior horn	Absent	Present	Present only in L1 and L2 segments	Present only in (S2, 3, 4) segments
Reticular formation	Well developed	Poorly developed	Absent	Absent
Amount of white matter	Massive + + + +	Large (less than in the cervical region) + + +	Less (slightly less than in the thoracic region) + + +	Very less +
Posterointermediate sulcus	Present throughout	Present in upper seven thoracic segments	Absent	Absent

Structure of the grey matter

Like in other regions of the CNS, the grey matter of spinal cord consists of (a) nerve cells, (b) neuroglia, and (c) blood vessels.

Neurons in the grey matter of the spinal cord

The nerve cells in the grey matter of spinal cord are multi-polar and can be classified into the following two ways:

Structural classification

- **Golgi type I**, having long axons, which leave the grey matter and either join the anterior nerve roots or form the nerve tracts.
- **Golgi type II**, having short axons, which do not leave the grey matter and remain intrasegmental or intersegmental in position.

Functional classification

- **Motor neurons:** These are present in the anterior and lateral horns.

Types of motor neurons in the anterior grey columns:

1. **Alpha (α) neurons:** They are large multipolar cells (25 μm or more in diameter) and supply the

extrafusal skeletal muscle fibres.

2. **Gamma (γ) neurons:** They are small multipolar cells (15–25 μm in diameter) and supply the intrafusal muscle fibres of the neuromuscular spindles in skeletal muscles.

N.B. The axons of motor neurons leave the spinal cord as the final common path (Sherrington) through the ventral roots of the spinal nerves and reach the skeletal muscles.

- **Sensory neurons:** These are present in the posterior horn and involved in relay of sensory information to the different parts of the brain, forming **ascending tracts**; or to the other segments of spinal cord forming **interseg-mental tracts**.
- **Interneurons:** These are small neurons present throughout the grey matter of the spinal cord. They connect different types of neurons, hence also called *association neurons*. These are either inhibitory or excitatory, and concerned with integration of segmental activities.

Nerve cell groups in the grey columns of the spinal cord (Fig. 7.13)

Cell groups in the anterior grey column

Numerous groups of motor neurons are found in the cross-section of anterior grey column, representing several longitudinally arranged columns of varying lengths. They are divided into three main groups or nuclei: (a) medial, (b) lateral, and (c) central.

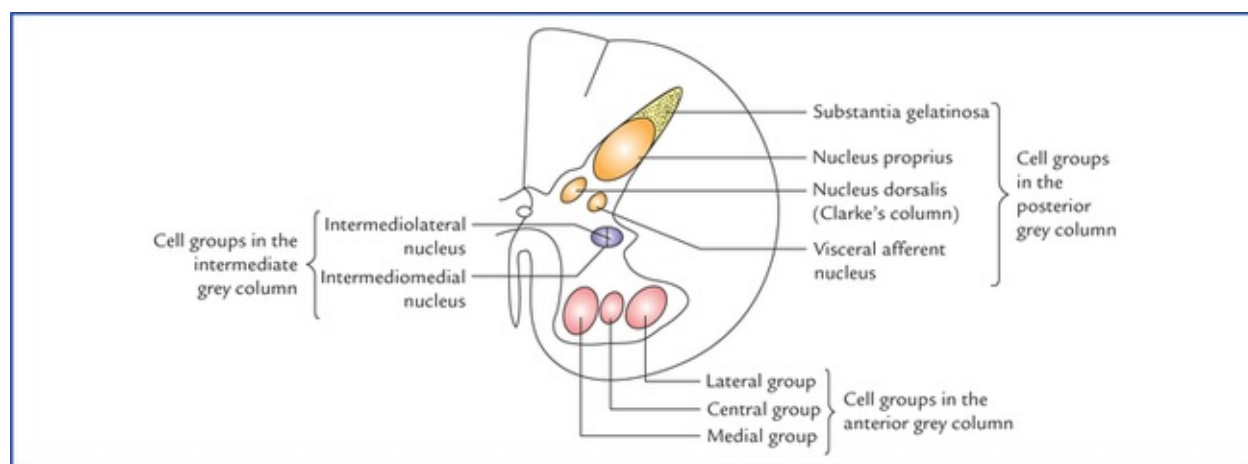


FIG. 7.13 Nerve cell groups in grey columns of the spinal cord.

- **Medial group** extends along most of the length of the spinal cord and innervate the axial musculature of the neck and trunk. This is further subdivided into *ventro-medial* and *dorsomedial* parts.
- **Lateral group** confines in the cervical and lumbosacral enlargements and supply the limb muscles.
- **Central group** forms three definite nuclei which are fairly localized. These are as follows:
 - *Phrenic nucleus*, in the cervical region (extending from C3 to C5 segments) and innervating the diaphragm.
 - *Lumbosacral nucleus* in the lumbosacral region (extending from L2 to S3 segments). Its function is unknown so far.
 - *Spinal nucleus of accessory (XI cranial) nerve* in the cervical region (extending from C1 to C5 segments) and giving origin to spinal root of accessory.

Cell groups in the posterior grey column

In the posterior grey column, the cell groups are arranged into four longitudinal columns; from the apex towards the base, they are: (a) substantia gelatinosa (of Rolandi), (b) nucleus proprius, (c) nucleus dorsalis (or Clarke's column), and (d) visceral afferent nucleus.

- **Substantia gelatinosa** is situated at the apex of the posterior grey column and extended throughout the length of spinal cord. It is composed of small Golgi type II neurons (also called interneurons). It receives the afferent fibres of the lateral division of the posterior nerve roots conveying primarily, the pain and temperature sensations. Some of these fibres synapse with the interneurons of substantia gelatinosa. *The substantia gelatinosa is continuous above with the nucleus of spinal tract of the trigeminal nerve.*
- **Nucleus proprius** is a group of large nerve cells situated anterior to the substantia gelatinosa and constitutes the main bulk of cells present in the posterior grey column. It extends along the whole length of the spinal cord and receives the fibres from posterior white column that are associated with the sense of position and movement (pro-prioception), two-point discrimination, and vibration.
- **Nucleus dorsalis (Clarke's column)** occupies the medial part of the base of the posterior grey column, projecting somewhat into the posterior funiculus, and extends from C8 to L2/L3 segments of the cord and receives pro-prioceptive afferents (muscle and joint sense) and exteroceptive afferents (touch and pressure) from the trunk and lower limb.
- **Visceral afferent nucleus** is located lateral to the nucleus dorsalis and extends from T1 to L2 and from S2 to S4 segments of the cord; and receives visceral afferent from dorsal nerve roots.

Cell groups in the intermediate (lateral) grey column

The cells of the lateral grey column form two nuclei: (a) intermediolateral, and (b) intermediomedial.

- **Intermediolateral nucleus** extends from T1 to L2 segments of the cord and gives origin to preganglionic fibres of the sympathetic nervous system (*thoracolumbar outflow*) which leave the cord along with anterior nerve roots.
- **Intermediomedial nucleus** extends from S2 to S4 segments of the cord and gives origin to preganglionic fibres of parasympathetic nervous system (*sacral outflow*), which also pass out through the anterior nerve roots of the corresponding sacral nerves.

The summary of the characteristics of the various cell columns in the spinal cord is presented in the [Table 7.5](#).

Table 7.5

Summary of the various cell columns/nuclei in different horns (grey columns) of the spinal cord

Cell columns/nuclei	Extend in the cord	Functions
Posterior horn		
I. Substantia gelatinosa	Entire cord	Relay nucleus for pain and temperature, modification of transmission of sensory input
II. Nucleus dorsalis (Clarke's column)	C8 to L2 or L3	Gives origin to axons which form posterior spinocerebellar tract
III. Nucleus proprius	Entire cord	Contains internuncial neurons for spinal reflexes and second order sensory neurons of the ventral spinothalamic tract
IV. Visceral afferent nucleus	T1 to L2 or L3 and S2	Relay nucleus for visceral afferent impulses

to S4

Anterior horn

V. Medial motor cell column	Entire cord	Supplies muscles of the neck and trunk
VI. Lateral motor cell column	C4 to T1 and L2 to S3	Supplies muscles of the extremities
VII. Phrenic nucleus	C3 to C5	Motor innervations of the diaphragm
VIII. Spinal accessory nucleus	C1 to C5	Origin of spinal root of accessory nerve
Lateral horn		
IX. Intermediolateral cell column	T1 to L2 or L3	Source of preganglionic sympathetic fibres
X. Sacral parasympathetic nucleus	S2 to S4	Source of preganglionic parasympathetic fibres

N.B. Apart from the central grey matter, there are strands of grey matter in the lateral white column adjacent to the base of the posterior horn, which are termed reticular formation.

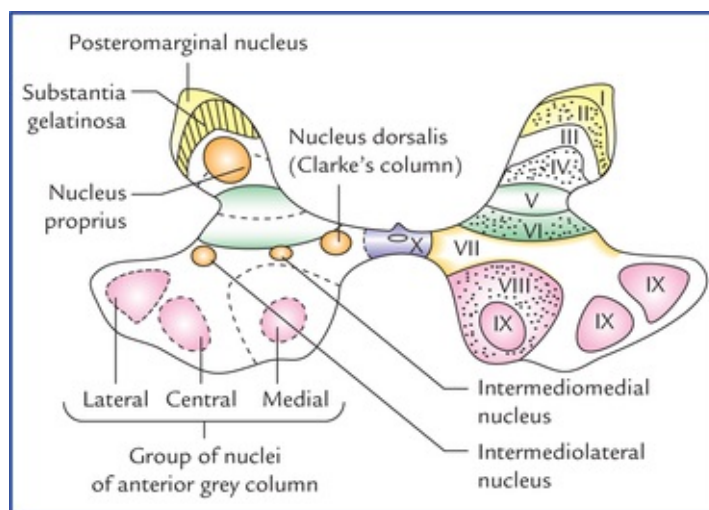
Laminar architecture of grey matter (Rexed laminae) (Fig. 7.14)

The cytoarchitecture of grey matter of spinal cord is alternatively divided into 10 zones or laminae by Rexed (Table 7.6). These are numbered consecutively by Roman numerals, starting at the tip of the posterior horn and moving ven-trally into the anterior horn.

Table 7.6

Rexed laminae and nuclear groups

Laminae	Corresponding grey column nuclei
I	Posteromarginal nucleus
II	Substantia gelatinosa
III and IV	Nucleus proprius
V and VI	Base of dorsal column
VII	Nucleus dorsalis (Clarke's column) and intermediolateral and intermediomedial nuclei of lateral horn
VIII and IX	Medial and lateral groups of nuclei of anterior grey column
X	Surrounds the central canal and composed of the grey commissure and substantia gelatinosa centralis



This concept of laminae is useful in experimental works only and provides information about the localization of terminal degenerating fibres after section of posterior nerve roots or descending nerve tracts.

White Matter

The white matter of the spinal cord surrounds the central 'H-shaped mass of grey matter, and mainly consists of nerve fibres, the large proportion of them being myelinated, give it a white appearance'.

Types of fibres in the white matter

Functionally, the fibres in the white matter of spinal cord are divided into following three types:

1. **Sensory fibres:** These include:
 - The central processes of primary sensory neurons of the posterior root ganglia which enter the spinal cord and ascend or descend for varying lengths, and
 - The ascending fibres from the nuclei of spinal grey columns that convey sensory modalities to the higher centres.
2. **Motor fibres:** These include:
 - The descending fibres from higher centres (supraspinal levels) to the spinal cord, and
 - The nerve fibres of anterior and lateral horn cells that go to the motor roots of the spinal nerves.
3. **Association fibres:** These fibres originate and end within the spinal cord, interconnecting the neurons of the same segment or of different segmental levels.

Divisions of white matter

In each half of the spinal cord, the white matter is divided into three parts called white columns or funiculi (Fig. 7.11):

- **Posterior white column**, between the posterior median septum, and the posterior horn.
- **Lateral white column**, between the anterior and posterior horns.
- **Anterior white column**, between the anterior median fissure and the anterior horn.

The anterior white columns are joined together by the **white commissure**.

Each white column is made up of tracts which are either ascending (sensory), descending (motor) or intersegmental (association).

N.B. In general, the posterior white column is sensory, the anterior column is motor and lateral column is mixed (i.e. motor as well as sensory). Further, the ascending tracts are located at the periphery and the descending tracts in the centre.

Tracts of the Spinal Cord (Fig. 7.15)

The tracts are defined as collections of nerve fibres within the central nervous system, which have same origin, course and termination. They are sometimes referred to as **fasciculi** (= bundles) or **lemnisci** (= ribbons).

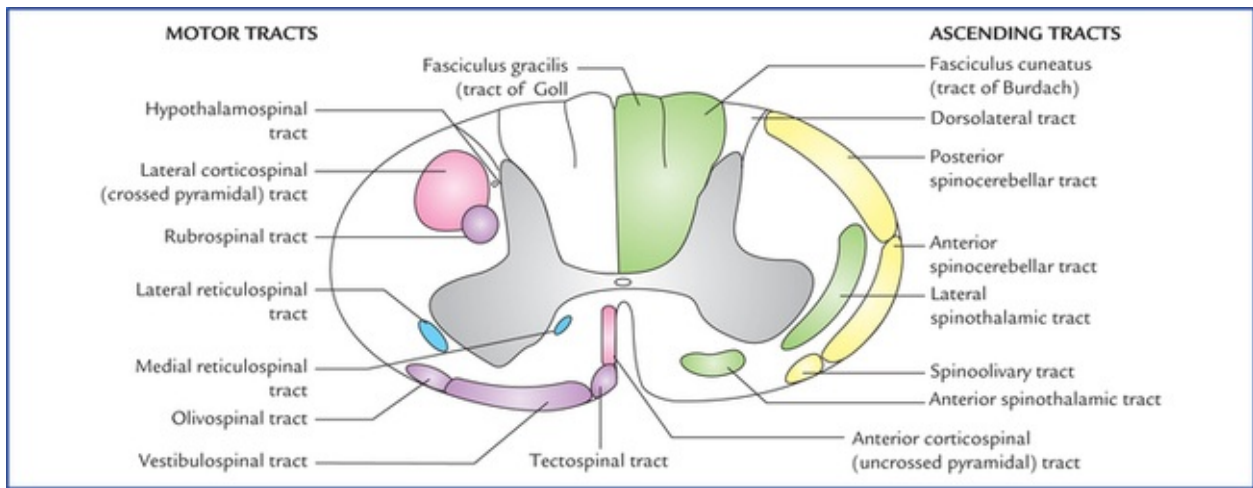


FIG. 7.15 Transverse section of spinal cord at mid-cervical region showing main descending (motor) tracts in the left half and ascending (sensory) tracts in the right half of the spinal cord.

The tracts are named after the names of masses of grey matter connected by them (Fig 7.16). The name usually consists of two components (or terms), the first term denotes the origin and second the termination of the tract. For example, a tract arising in cerebral cortex and terminating in the spinal cord is called corticospinal tract, similarly a tract arising in the spinal cord and terminating in the thalamus is called spinothalamic tract.

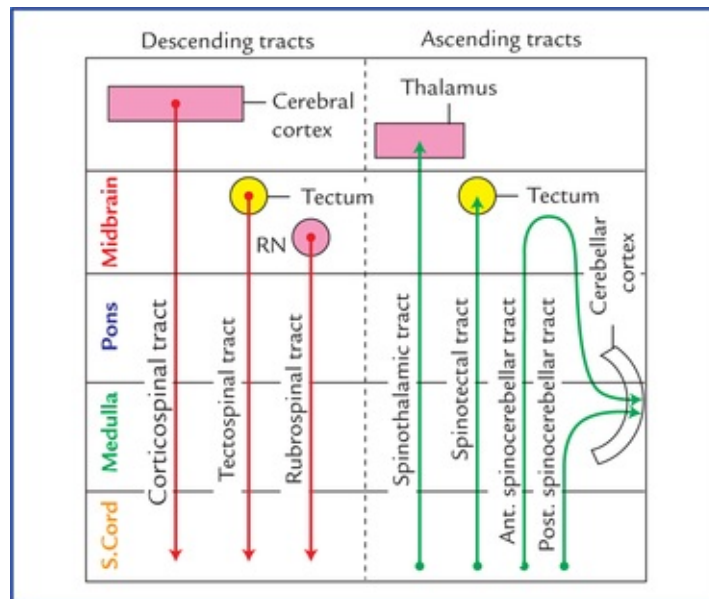


FIG. 7.16 Scheme to show the basis of nomenclature of the tracts. (RN = Red nucleus.)

Classification of the Tracts

The tracts are classified into three types: (a) descending, (b) ascending, and (c) intersegmental (Table 7.7).

Table 7.7

Classification of the tracts of the spinal cord

Descending (motor) tracts	Ascending (sensory) tracts	Intersegmental tracts
• Lateral corticospinal (crossed pyramidal)	• Lateral spinothalamic	• Dorsolateral fasciculus (tract of Lissauer)
• Anterior corticospinal (uncrossed pyramidal)	• Anterior spinothalamic	• Septomarginal
• Rubrospinal	• Posterior spinothalamic	• Comma (semilunar) tract
• Tectospinal	• Anterior spinocerebellar	
• Vestibulospinal	• Fasciculus gracilis (tract of Goll)	
• Olivospinal	• Fasciculus cuneatus (tract of Burdach)	
• Reticulospinal (a) medial, (b) lateral		

The distribution of different descending and ascending tracts in three white columns (anterior, lateral, and posterior) of the spinal cord are summarized in [Table 7.8](#).

Table 7.8

The presence of different tracts in anterior, lateral and posterior white columns of the spinal cord

Column	Descending tracts	Ascending tracts
Anterior white column	Anterior corticospinal, vestibulospinal, tectospinal, medial reticulospinal	Anterior spinothalamic
Lateral white column	Lateral corticospinal, rubrospinal, lateral reticulospinal, hypothalamospinal	Lateral spinothalamic, anterior spinocerebellar, posterior spinocerebellar, spinotectal
Posterior white column		Fasciculus gracilis (tract of Goll), fasciculus cuneatus (tract of Burdach)

Descending tracts

The descending tracts conduct the impulses to the spinal cord from the brain. The location, origin, termination and function of the major tracts are summarized in [Table 7.9](#).

Table 7.9

Major descending tracts in the spinal cord

Tract	Location	Origin*	Termination	Functions
Lateral corticospinal (crossed pyramidal) tract	Lateral white column of spinal cord	Primary motor cortex (area 4), premotor cortex (area 6) of the opposite cerebral hemisphere (upper motor neurons)	Anterior horn cells of the spinal cord (lower motor neurons)	Controls conscious skilled movements especially of hands (contraction of individual or small group of muscles particularly those which move hands, fingers, feet and toes)
Anterior corticospinal (uncrossed pyramidal) tract	Anterior white column	Primary motor cortex (area 4), premotor cortex (area 6) of the opposite cerebral hemisphere upper motor neurons)	Anterior horn cells of the spinal cord (lower motor neurons)	Same as that of lateral corticospinal tracts
Rubrospinal tract	Lateral white column	Red nucleus of the opposite side located in midbrain	Anterior horn cells of the spinal cord	Unconscious coordination of movements (controls muscle tone and synergy)
Vestibulospinal tract	Anterior white column	Vestibular nucleus	Anterior horn cells of the spinal cord	Unconscious maintenance of posture and balance
Tectospinal tract	Anterior white column	Superior colliculus of the opposite side	Cranial nerve nuclei in medulla and anterior horn cells of the upper spinal segments	Controls movements of head, neck and arms in response to visual stimuli
Lateral reticulospinal tract	Lateral white column	Reticular formation in midbrain, pons and medulla	Anterior horn cells of the spinal cord	Mainly responsible for facilitatory influence on the motor neurons to the skeletal muscles
Medial reticulospinal tract	Anterior white column	Reticular formation in medulla	Anterior horn cells of the spinal cord	Mainly responsible for inhibitory influence on the motor neurons to the skeletal muscles

*Location of cell bodies of neurons from which axons of a particular tract arise.

Some of these tracts are discussed below in brief.

Corticospinal tract (pyramidal tract; Fig. 7.17)

The pyramidal tract consists of about one million fibres.

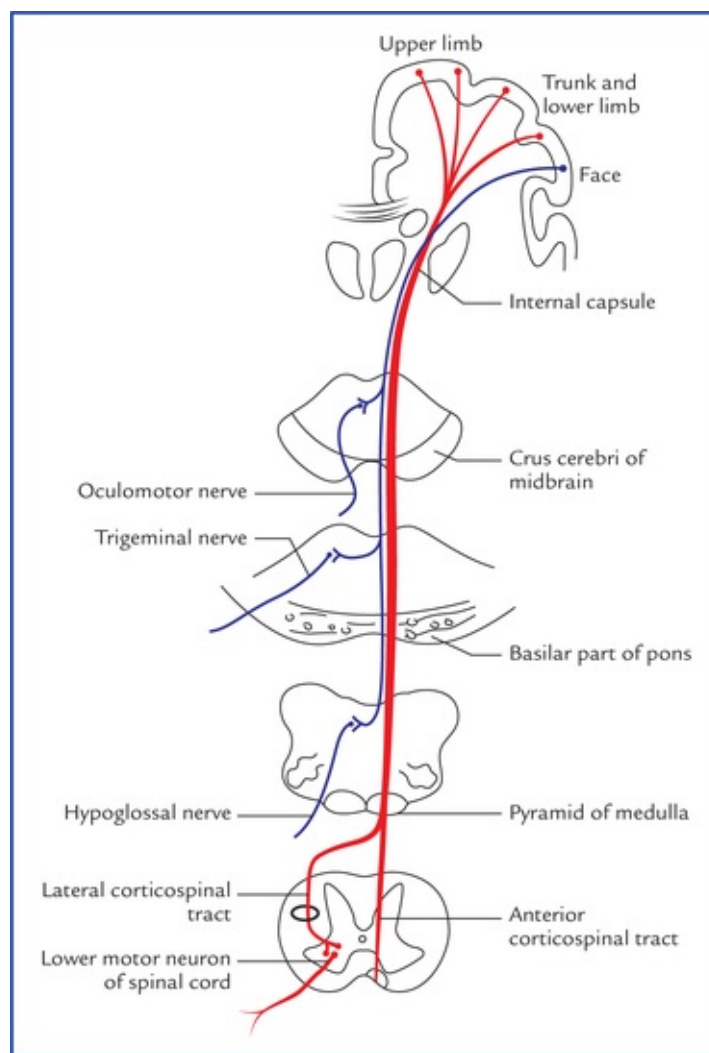


FIG. 7.17 Pyramidal tracts (corticospinal tract is shown in red and corticobulbar/corticonuclear in blue).

The pyramidal tract is so named because corticospinal tract traverses the medullary pyramids, but it also includes corticobulbar/corticonuclear fibres which descend to brain-stem, across to the opposite side and terminate by synapsing with nerve cells of brainstem nuclei of the cranial nerves.

Origin: The most of the fibres of corticospinal tracts arise from pyramidal cells (of Betz) of the motor area of the cerebral cortex. Some fibres arise from other parts of the cortex.

Course: The fibres pass through corona radiata, internal capsule, crus cerebri of cerebral peduncles, ventral part of the pons and pyramids of the medulla oblongata. In the lower part of the medulla majority of fibres (about 75%) cross to the opposite side at the pyramidal decussation of the medulla and descend in the lateral white column of the spinal cord as the **lateral corticospinal tract**. The uncrossed fibres descend in the anterior white column of the spinal cord as the **anterior corticospinal tract**. The lateral corticospinal part also contains some fibres which arise from the ipsilateral cerebral cortex.

The lateral corticospinal tract lies in the lateral white column in front of the posterior horn and medial to the posterior spinocerebellar tract. The anterior corticospinal tract lies in the anterior white column close to the anterior median fissure.

Lower down the fibres of anterior corticospinal tract also cross to the opposite side in the anterior white commissure of the spinal cord at the level of their termination.

Termination: The most of the fibres of both lateral and anterior corticospinal tracts terminate by synapsing with the interneurons, which in turn project to the motor neurons (α and γ) of the anterior horn. Only 2% of the fibres synapse directly with the motor neurons.

N.B. Because of decussation of corticospinal fibres in the medulla (medullary decussation), the cerebral cortex of one side controls the muscles of the opposite half of the body.

Clinical Correlation

The lesions of pyramidal tract above the level of decussation (i.e. *upper motor neuron (UMN) lesions*) result in the loss of voluntary movements in the opposite half of the body below the level of the lesion. The muscles are not actually paralyzed but the control of upper motor neurons and the *lower motor neurons (LMN)* supplying muscles is lost. As a result LMNs become hyperactive and the tone of muscles is increased leading to **spastic paralysis**.

Rubrospinal tract

The fibres of this tract arise from the cells of red nucleus (nucleus ruber) located in the midbrain and immediately caudal to red nucleus they decussate with those of the opposite side and descend as a compact bundle in the lateral white column of the spinal cord, ventral to the lateral corticospinal tract. The fibres of this tract end just like those of corticospinal tract in the anterior horn cells of the spinal cord. This tract forms a part of extrapyramidal system.

Rubrospinal tract facilitates the activity of the flexor muscles and inhibits the activity of the extensor or anti-gravity muscles.

Reticulospinal tracts

- **Lateral reticulospinal tract:** lies in the lateral white column. Its fibres arise from cells of the reticular formation in the brainstem (midbrain, pons and medulla) and relay in the anterior horn cells. This tract exerts facilitatory influence on the motor neurons, which supply the skeletal muscles.
- **Medial reticulospinal tract:** lies in the anterior white column. Its fibres arise from the cells of the reticular formation in the medulla and relay in the anterior horn cells of the spinal cord. This tract exerts inhibitory influence on the motor neurons supplying the skeletal muscles.

N.B. The reticulospinal fibres are now thought to include the descending autonomic fibres. The reticulospinal tracts thus provide a pathway by which the hypothalamus can control the thoracolumbar sympathetic outflow and the sacral parasympathetic outflow.

- **Hypothalamospinal tract:** projects from the hypothalamus, descends in the lateral white column of spinal cord on the medial side of the lateral corticospinal tract, and terminates by synapsing with lateral horn cells of T1 to L2 spinal segments responsible for sympathetic outflow; and lateral horn cells of S2, S3, and S4 spinal segments responsible for parasympathetic outflow.

Ascending Tracts

The ascending tracts conduct the impulses from the periphery to the brain through the cord.

The important ascending tracts fall into the following three types:

1. Those concerned with **pain and temperature sensations and crude touch**, e.g. lateral and anterior spi-nothalamic tracts.

- Those concerned with **fine touch and conscious proprioceptive sensations**, e.g. fasciculus gracilis and fasciculus cuneatus.
- Those concerned with **unconscious proprioception and muscular coordination**, e.g. anterior and posterior spinocerebellar tracts.

Lateral spinothalamic tract (Fig. 7.18)

The cell bodies of first order sensory neurons (pseudouni-polar neurons) of this tract lie in the dorsal root ganglia of the spinal nerves. The central processes of these cells enter the cord through the lateral division of the dorsal root of the spinal nerves. In the cord the fibres ascend one or two segments in the **dorsolateral tract of Lissauer** at the tip of posterior horns and then relay in the posterior horn by synapsing with the cells of substantia gelatinosa. The axons of second order sensory neurons of substantia gelatinosa cross to the opposite side in the anterior white commissure and ascend up as **lateral spinothalamic tract** in the opposite lateral white column just lateral to the anterior horn. They terminate in the **ventral posterolateral nucleus (VPL) of the thalamus**. The sacral, lumbar, thoracic and cervical fibres are situated in layers in this tract from superficial to deep (somatotrophic organization).

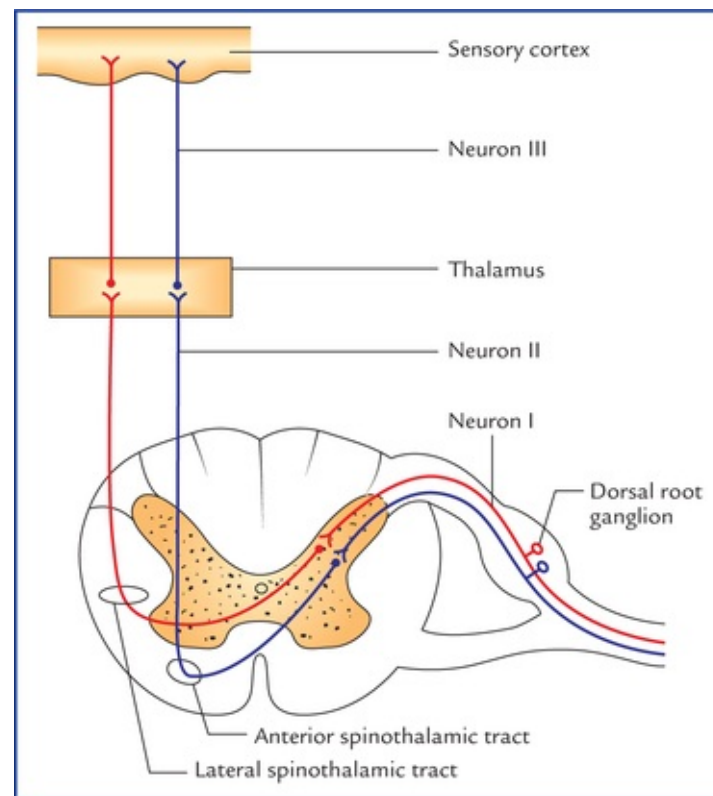


FIG. 7.18 Lateral and anterior spinothalamic tracts.

The axons of the third order sensory neurons project to the primary sensory cortex of the cerebral hemisphere.

Clinical Correlation

The fibres of this tract carry pain and temperature sensations—the pain fibres being lateral to the temperature. The pain fibres become very superficial in the lateral white column of the cord in the cervical region. Therefore, *cordotomy* can be performed safely at this level to

relieve pain in the opposite half of the body.

The involvement of decussating fibres of this tract in the anterior commissure in *syringomyelia* leads to bilateral loss of pain and temperature sensations below the level of the lesion.

Anterior spinothalamic tract

The anterior (or ventral) spinothalamic tract carries light touch, pressure, tickle, and itch sensations from the opposite half of the body.

The cell bodies of the first order sensory neurons of this tract lie in the dorsal root ganglia of the spinal nerves. The central process of these cells (large and heavily myelinated) enter the cord through the medial division of the dorsal roots of the spinal nerves and ascends in the cord 1 or 2 segments in the **dorsolateral tract of Lissauer** and relay in the substantia gelatinosa of the posterior horn. The axons of second order sensory neurons of substantia gelatinosa cross the midline in the anterior white commissure and then ascend as **ventral spinothalamic tract** in the opposite anterior white column just in front of the anterior horn. These fibres terminate in the ventral posterolateral nucleus of the thalamus (Fig. 7.18).

N.B. The lateral spinothalamic tract carries pain and temperature sensations whereas anterior spinothalamic tract carries sensations of crude touch and pressure.

Clinical Correlation

The damage of anterior spinothalamic tract leads to loss of light touch and pressure on the opposite of the body below the level of the lesion.

Fasciculus gracilis (tract of Goll) and fasciculus cuneatus (tract of Burdach)

These two tracts occupy the posterior white column of the cord, the fasciculus gracilis being medial to the fasciculus cuneatus.

They carry sensations of **conscious proprioception**, two point tactile discrimination and vibration. The cell bodies of the first order sensory neurons lie in the dorsal root ganglia of the spinal nerves. The central processes of these cells (thickly myelinated) enter the cord through the medial division of the roots of spinal nerves and continue in the posterior white column as fasciculus gracilis and fasciculus cuneatus (Fig. 7.19).

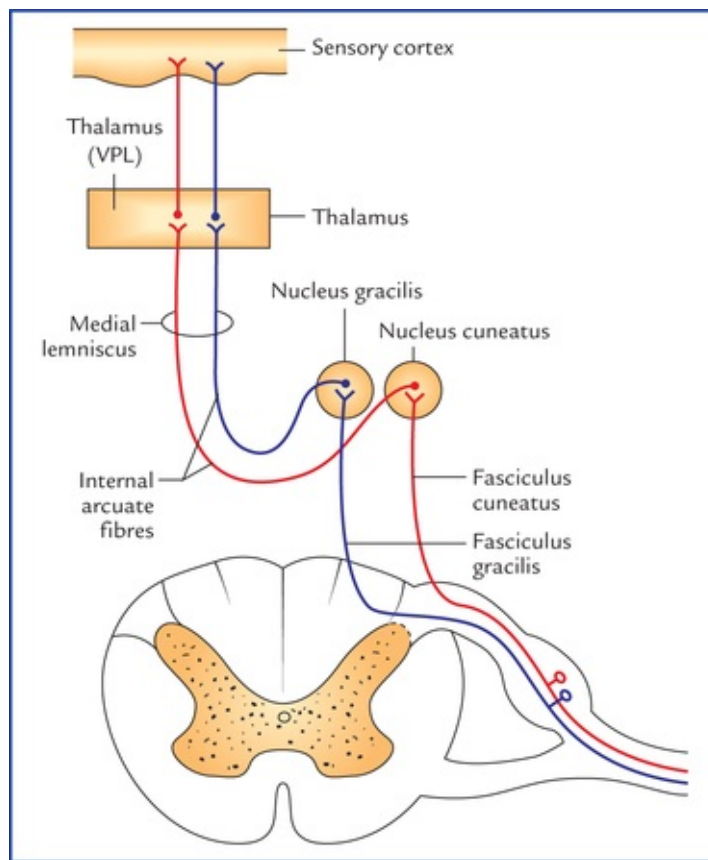


FIG. 7.19 Fasciculus gracilis and fasciculus cuneatus (posterior column—medial lemniscus pathway).

Fibres from the coccygeal, sacral, lumbar, and lower thoracic segments ascend up in the fasciculus gracilis while the fibres from the upper thoracic and cervical segments run in the fasciculus cuneatus. The cervical, thoracic, lumbar, and sacral fibres are arranged in that order from lateral to medial in these tracts.

The fibres of fasciculus gracilis and fasciculus cuneatus terminate in nucleus gracilis and nucleus cuneatus respectively. The axons of second order sensory neurons from nucleus gracilis and nucleus cuneatus curve ventromedi-ally around the central grey matter of the medulla as internal arcuate fibres to undergo decussation. The fibres after crossing the midline turn upwards as a flat tract called **medial lemniscus** which courses upwards to terminate in the ventral posterolateral nucleus (VPL) nucleus of the thalamus. The third order sensory neurons from thalamus project into the cerebral cortex of the cerebral hemisphere. This pathway carrying conscious proprioceptive sensations is termed '**dorsal column—medial lemniscus-pathway**'.

Clinical Correlation

The involvement of posterior white columns and posterior nerve roots in syphilitic degenerative disease called **tabes dorsalis** leads to loss of sense of position. The patient is not able to tell the position or movements of his lower limbs unless he sees them. Therefore, when he is asked to stand up with his feet together and eyes closed, he staggers and falls because he cannot maintain his correct position due to lack of proprioceptive information (*Romberg's sign*).

Spinocerebellar tracts (Fig. 7.20)

The spinocerebellar fibres are located in the lateral white column of the cord and are divided into two tracts: **posterior spinocerebellar tract** and **anterior spinocerebellar tract** according to their location in the cord. They carry unconscious proprioceptive sensations from cord to the cerebellum and play an important role in muscular coordination.

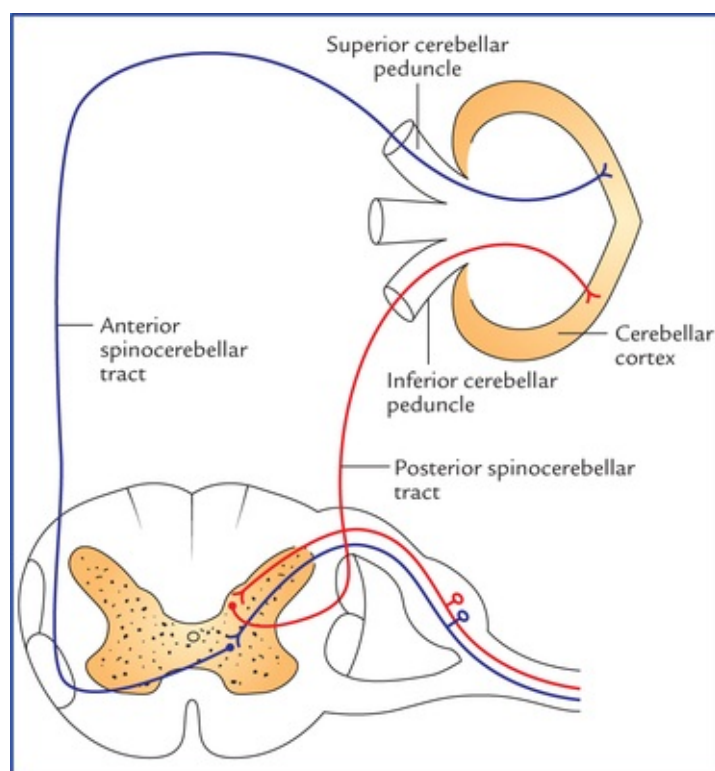


FIG. 7.20 Schematic diagram to show posterior (in red) and anterior (in blue) cerebellar tracts.

- **Posterior (dorsal) spinocerebellar tract:** The cell bodies of the first order sensory neurons lie in the dorsal root ganglia of the spinal nerves. The central processes of these cells enter the posterior horn of the grey matter through posterior roots of spinal nerves and relay in the **nucleus dorsalis (Clarke's column)**. The axons from cells of nucleus dorsalis (second order sensory neurons) pass to the dorsolateral part of the white column on the same side and ascend as *posterior spinocerebellar tract*. The fibres of the tract enter the cerebellum through the inferior cerebellar peduncle and terminate in the ipsilateral cerebellar cortex.
- **Anterior (ventral) spinocerebellar tract:** The origin and course of the first order sensory neurons is same as that of posterior spinocerebellar tract. The axons of cells of nucleus dorsalis (second order sensory neurons) cross to the opposite side and pass to the anterolateral part of the lateral white column of the spinal cord and then ascend to form the anterior spinocerebellar tract. The fibres of anterior spinocerebellar tract enter the cerebellum through superior cerebellar peduncle and terminate in the ipsilateral cerebellar cortex.

The input of both posterior and anterior spinocerebellar tracts is ipsilateral.

Functionally, both posterior and anterior spinocerebellar tracts carry impulses from the lower limb. The posterior tract is concerned with fine movements, whereas anterior tract is concerned with gross movements of the limb as a whole.

To summarize, the motor impulses travel from the brain to the anterior horn cells of spinal cord through the descending tracts and then out to the periphery via the spinal nerves. The sensory impulses from the

periphery travel through spinal nerves into the spinal cord via posterior or dorsal horn and then up the spinal cord to the brain through ascending tracts.

The major descending and ascending tracts passing through the spinal cord and brainstem are shown schematically in Figs 7.21A and 7.21B.

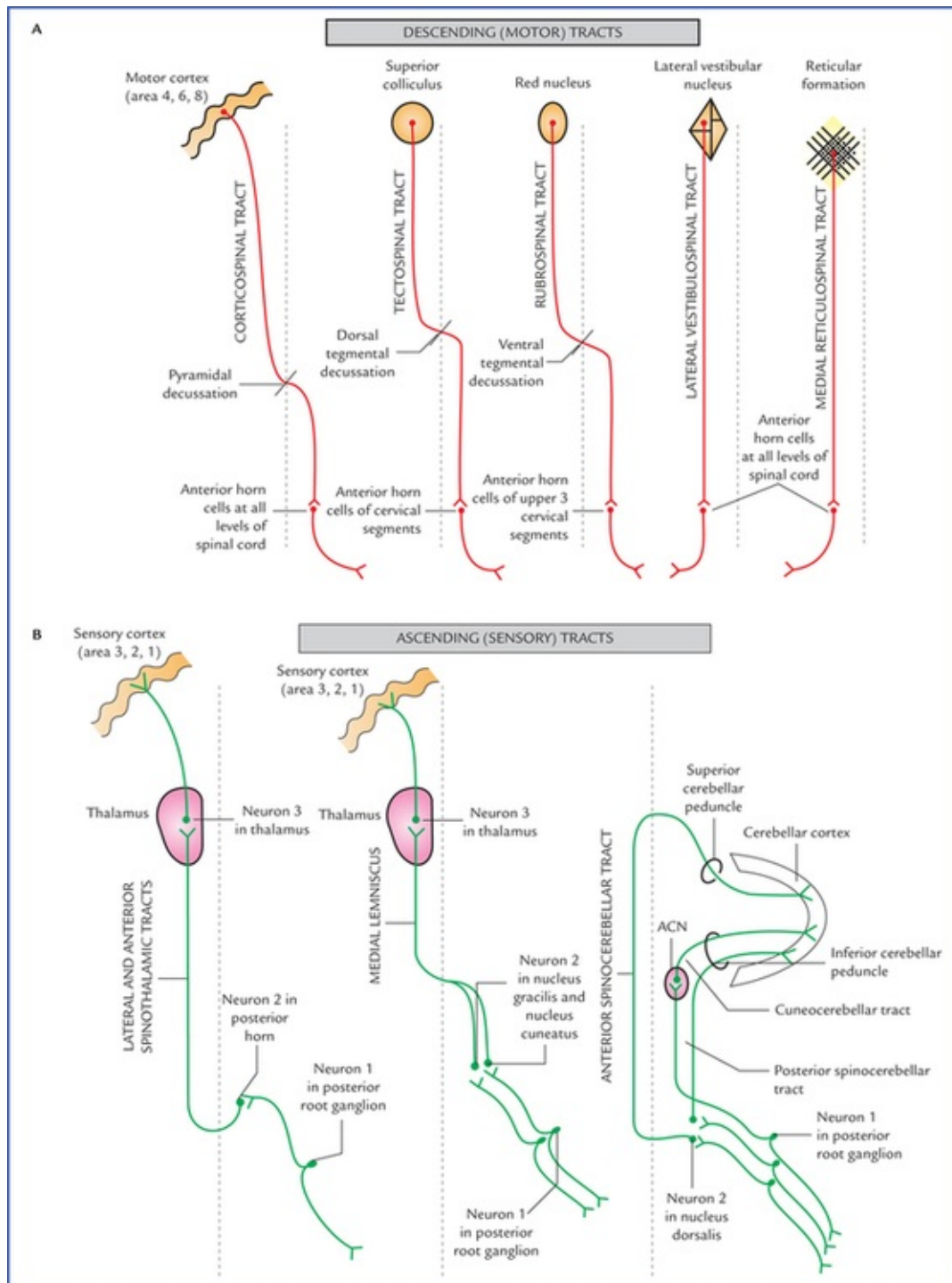


FIG. 7.21 (A) Schematic line diagram to show the major descending tracts, and (B) the major ascending tracts. The median planes are shown by interrupted lines.

They are described in detail in Chapter 17. The location, origin, termination and function of major ascending tracts are listed in Table 7.10.

Table 7.10

Major ascending tracts in the spinal cord

Tract	Location	Origin*	Termination	Functions
Lateral spinothalamic tract	Lateral white column	Posterior horn cells of spinal cord of opposite side	Ventral posterolateral (VPL) nucleus of thalamus	Carry pain and temperature from opposite side of the body
Anterior spinothalamic tract	Anterior white column	Posterior horn cells of spinal cord of opposite side	Ventral posterolateral (VPL) nucleus of thalamus	Carry light touch, pressure, tickle, and itch sensation from opposite side of the body
Spinotectal tract	Lateral white column	Posterior horn cells of spinal cord of opposite side	Superior colliculus of tectum of midbrain	Visuomotor reflexes, . head and eye movements towards the source of stimulation
Spinocerebellar (anterior and posterior) tracts	Lateral white column (superficially)	Posterior horn cells of spinal cord of same side	Cerebellum	Unconscious kinaesthesia (proprioception)
Fasciculus gracilis and fasciculus cuneatus (tracts of Gall and Burdach)	Posterior white column of spinal cord	Dorsal root ganglia of spinal nerves of the same side	Nucleus gracilis and nucleus cuneatus in medulla of the same side	Joint sense, vibration sense, two-point discrimination, stereognosis, conscious kinaesthesia

*Location of cell bodies of neurons from which the axons of tract arise.

Intersegmental tracts

The short ascending and descending tracts, which originate and end within the spinal cord, exist in the anterior, lateral and posterior white columns. The function of these tracts is to interconnect the neurons of different segmental levels. These tracts are particularly important in **intersegmental spinal reflexes**.

Intrinsic Spinal Mechanisms

Spinal Reflexes

The **reflex** may be defined as ‘an automatic response to a stimulus that occurs without conscious thought’.

The major spinal reflexes include the withdrawal reflex, the stretch reflex, and the Golgi tendon reflex.

- **Withdrawal reflex** (also called ‘flexor withdrawal reflex’). This reflex is very important as it is directed towards the preservation of the animal. For example, if the sole of the foot of a sleeping person is pricked with a sharp pin, the leg is reflexly drawn up. The neural mechanism for this response is as follows: The action potentials (nerve impulses) produced by painful stimulus travel through the afferent neurons of the dorsal root of the spinal nerve to the spinal cord, where they synapse with the excitatory association neurons, which in turn synapse with the alpha motor neurons. The alpha motor neurons stimulate flexor muscles which remove the limb from the source of painful stimulus.

The **reflex arc** involved in this reflex consists of five basic components (Fig. 7.22). and involves more than one synapse; hence, it is called *polysynaptic reflex arc*.

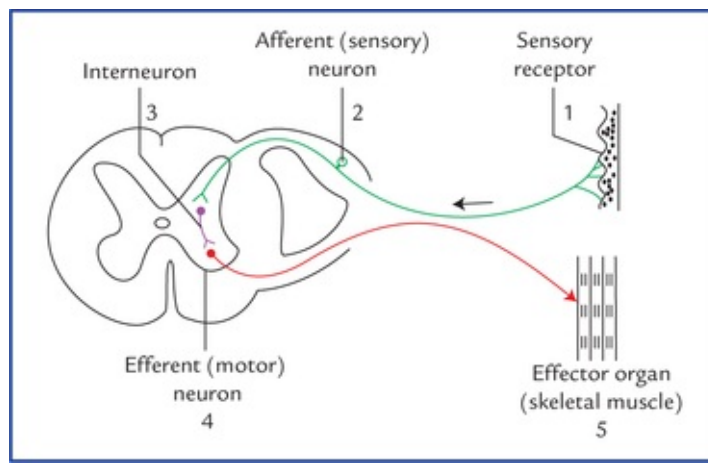


FIG. 7.22 Polysynaptic spinal reflex arc involved in withdrawal reflex. Note the five components: (1) a sensory receptor, (2) an afferent or sensory neuron, (3) an association neuron, (4) an efferent or motor neuron, and (5) an effector organ.

- **Stretch reflex** (see page 31)
- **Golgi tendon reflex** (see page 32).

The classification of spinal reflexes is given in [Table 7.11](#).

Table 7.11
Classification of spinal reflexes

Type	Features	Examples
1. Monosynaptic	Only one synapse is present between afferent and efferent neurons	Stretch reflexes (biceps, triceps and knee jerks)
2. Polysynaptic	More than one synapses (i.e. one or more interneurons are present between afferent and efferent neurons)	Withdrawal reflexes (gross flexor reflex, gross extensor reflex)

Reciprocal inhibition

The reciprocal inhibition is associated with the withdrawal reflex and increases the efficiency of this reflex. The collateral branches of afferent neurons that carry action potentials from pain receptors innervate inhibitory association neurons, which in turn synapse with and inhibit alpha motor neurons supplying extensor (antagonist) muscles. Thus, when withdrawal reflex is initiated, the flexor muscles contract and extensor (antagonist) muscles relax.

Renshaw cell inhibition

The Renshaw cells are inhibitory interneurons in the anterior grey column. Some of alpha motor neurons give off collateral branches which make inhibitory synapses with the Renshaw cells. In turn, axons of Renshaw cells loop back to make synapses with the bodies of alpha motor neurons and prevent the excessive alpha firing.

N.B. Tetanus toxin suppresses the actions of Renshaw cells and produces convulsions.

Clinical Correlation

- **Syringomyelia (Fig. 7.23)**

In this condition, a fluid cavity (or cavities) develops near the centre of the spinal cord usually in the cervical segments (Fig. 7.23). This leads to the destruction of the cord involving central canal and its surrounding area.

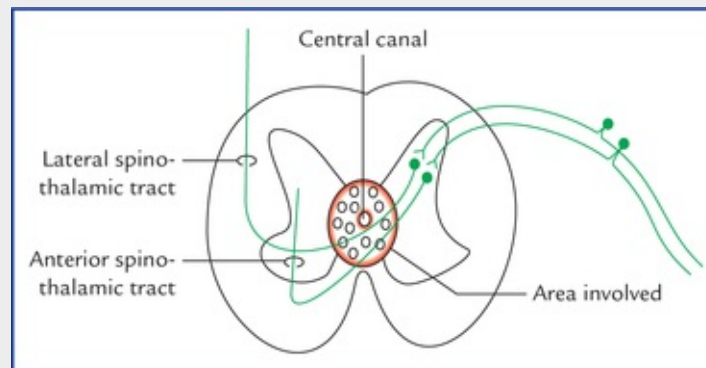


FIG 7.23 The site of lesion in syringomyelia.

This lesion involves the decussating spinothalamic fibres in the anterior white commissure (Fig. 7.23) so that there is bilateral loss of pain and temperature sensations below the lesion but other sensations below the lesion but other sensations are preserved in the uncrossed tracts of posterior columns. Thus, this condition results in what is called **dissociated sensory loss**.

• Hemisection of the spinal cord (Brown-Sequard syndrome)

Effects of the hemisection of the spinal cord are as follows (Fig. 7.24):

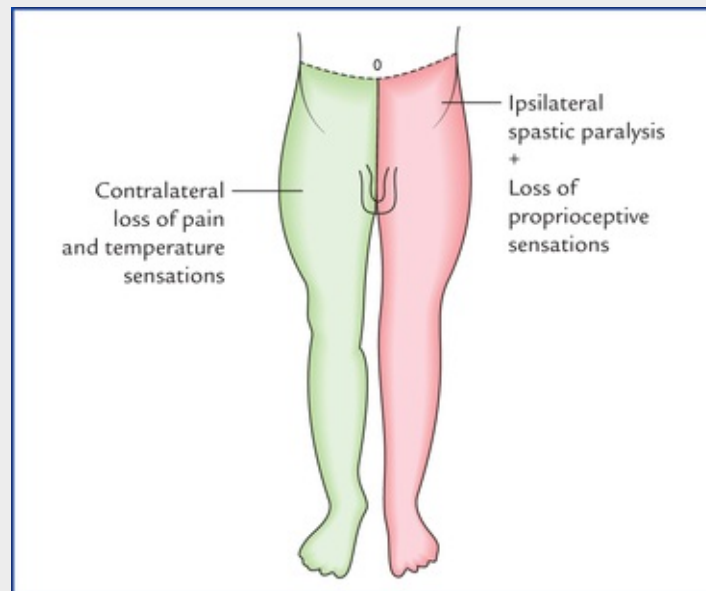


FIG. 7.24 Brown-Sequard syndrome, due to hemisection of spinal cord on the left side at the level of T10 segment.

- Ipsilateral upper motor neuron type of (spastic) paralysis below the level of hemisection (due to involvement of pyramidal tract).
- Ipsilateral loss of proprioceptive sensations (sense of position, posture, passive movement)

- and vibrations) and fine touch/discrimination (due to involvement of posterior columns).
- Contralateral loss of pain and temperature sensations below the level of lesion (due to involvement of spinothalamic tract).

N.B. Touch is not completely lost because tactile impulses ascend on both sides of the cord.

• **Tabes dorsalis**

It is a syphilitic degenerative lesion of the posterior white columns and posterior nerve roots (Fig. 7.25).

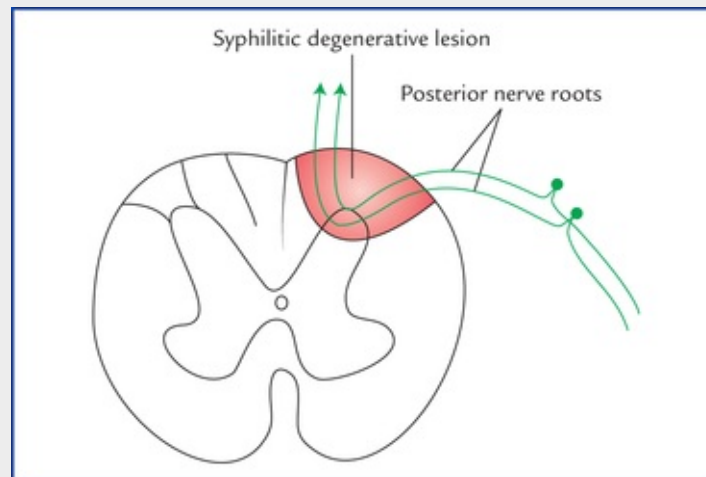


FIG. 7.25 Site of lesion in 'tabes dorsalis.' Note the involvement of posterior white column and posterior nerve roots at the point of their entrance into the spinal cord.

It is characterised by impairment of proprioceptive sensibility. The patient loses the sense of tactile discrimination, vibration, passive movement and appreciation of posture. The patient becomes ataxic, particularly if he closes his eyes, because he has lost his position sense for which he can partially compensate by visual knowledge of his spatial relationship (*Romberg's sign*).

• **Posterior rhizotomy or cordotomy**

The intractable pain can be treated in selected cases by cutting the appropriate posterior nerve roots (posterior rhizotomy) or by division of the spinothalamic tract on the side opposite to the pain (cordotomy). A knife is passed 3 mm deep into the cord, anterior to the denticulate ligament, and then swept forward. It severs the lateral spinothalamic tract but preserves the pyramidal tract lying immediately behind it.

Blood Supply of The Spinal Cord Arterial Supply

The spinal cord is supplied by following arteries (Fig. 7.26 A, B):

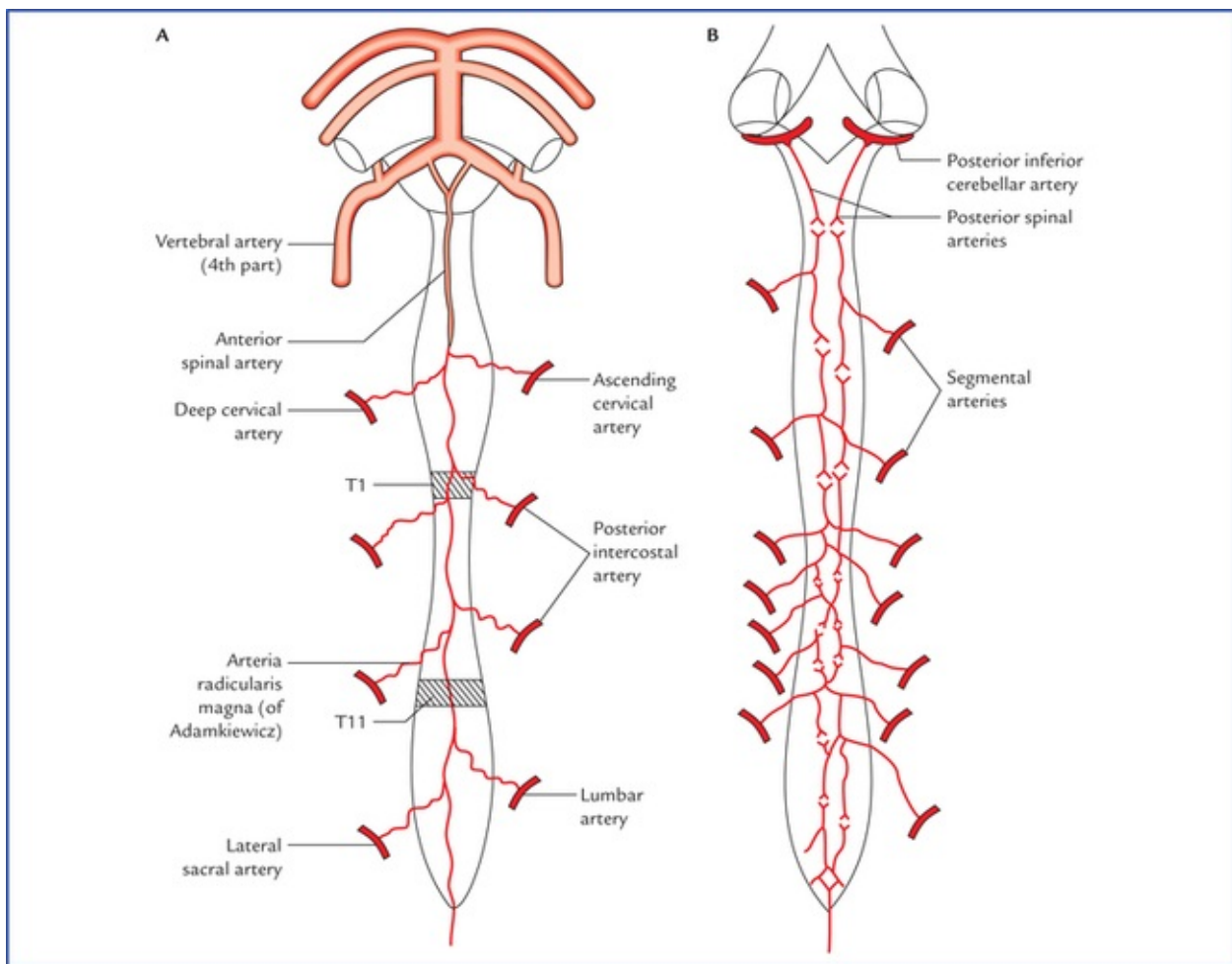


FIG. 7.26 Arterial supply of the spinal cord: (A) viewed from anterior aspect, and (B) viewed from the posterior aspect.

1. Anterior spinal artery.

2. Two posterior spinal arteries.

3. Segmental arteries.

- The **anterior spinal artery** is formed by the union of two small spinal branches of the right and left vertebral arteries in the upper cervical canal. It runs caudally in the anterior median fissure of the spinal cord and terminates along the filum terminale.
- There are **two posterior spinal arteries** (Fig. 15.3) each arising as a small branch from either the vertebral or posterior inferior cerebellar artery. Each posterior spinal artery runs down on the posterolateral aspect of the cord in the posterolateral sulcus along the line of attachment of posterior nerve roots and usually divides into two collateral arteries along the medial and lateral sides of the posterior nerve roots. Thus, there are five longitudinal arteries around the spinal cord.

These arteries are reinforced by the segmental arteries to form 5 longitudinal arterial trunks. These arterial trunks communicate around the cord forming a pial plexus, the **arterial vaso-corona/arteriae coronae**. The arteriae coronae give peripheral branches which supply the superficial regions of the cord (Fig. 7.27).

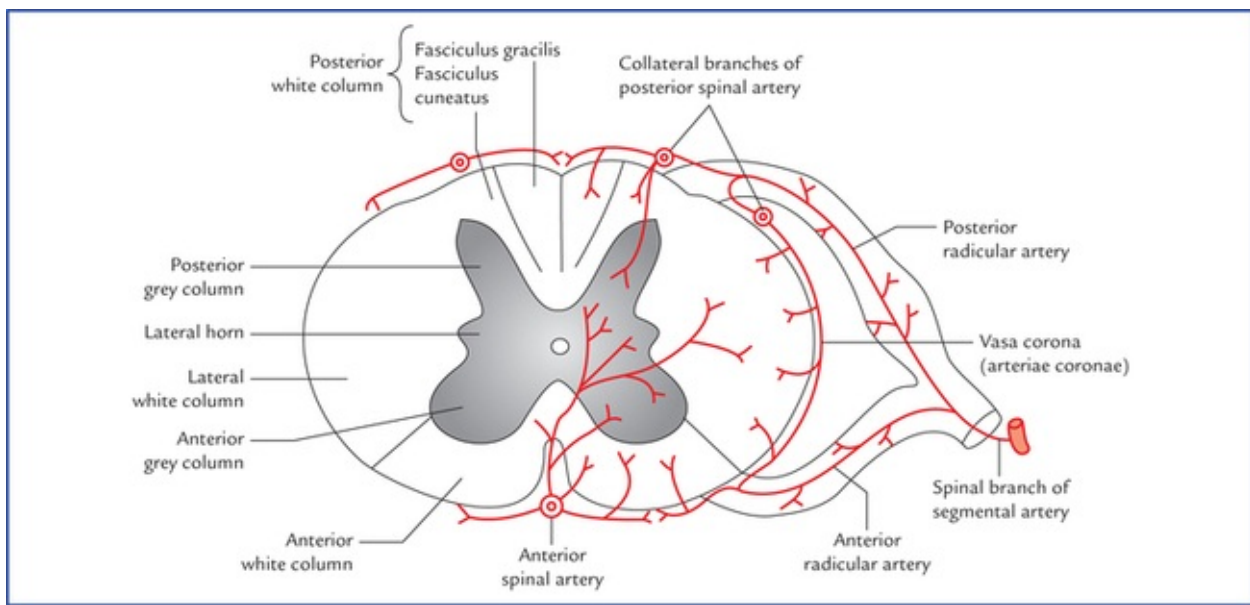


FIG. 7.27 Arterial supply of the interior part of spinal cord.

The anterior spinal artery supplies the anterior two-third of the cord, while two posterior spinal arteries together supply the posterior one-third of the cord.

Clinical Correlation

• Anterior spinal artery syndrome

It occurs due to occlusion (thrombosis or compression of the anterior spinal artery).

Each segmental artery divides into anterior and posterior branch which enter the vertebral canal along the anterior and posterior nerve roots of corresponding spinal nerve; hence termed anterior and posterior radicular arteries respectively. Many of these radicular arteries are small and end by supplying the spinal nerve roots.

Since the anterior spinal artery supplies anterior two-third of the cord, the occlusion of this artery will therefore result in:

- motor symptoms*, due to involvement of corticospinal tracts and anterior grey columns, and
- bilateral loss of pain and temperature sensation* due to ischaemia of spinothalamic tracts.

N.B. The conscious proprioceptive; sensations are preserved because the region of posterior white column is supplied by posterior spinal arteries.

- The **segmental arteries** are spinal branches of *deep cervical, ascending cervical, posterior intercostal, lumbar and lateral sacral arteries*. They reach the spinal cord, as the anterior and posterior radicular arteries along the corresponding roots of the spinal nerves respectively and nourish the nerve roots.

There are about 8 anterior and 12 posterior radicular arteries which reach the spinal cord. After

reaching the spinal cord they reinforce the anterior and posterior spinal arteries to form five longitudinal arterial trunks. The radicular arteries are regular serial enforcements to the spinal arteries. The anterior radicular arteries are larger but less in number than the posterior radicular arteries.

Frequently anterior arteries at the first (T1) and eleventh thoracic (T11) segmental levels are very large and termed **arteria radicularis magna (arteries of Adamkiewicz)**.

Clinical Correlation

The artery of T11 spinal segment is remarkably large and supplies several segments of the cord upwards and downwards. A fracture of vertebra involving this artery leads to softening of several segments of the cord. The artery at the level of T1 segment anastomoses with the other arteries in such a fashion (valvular fashion) that its supply is directed only downwards. Therefore, if this segmental artery is involved, the C8 segment is most affected.

***N.B.** Radicular (segmental) arteries are more important in the vascular supply of the cord because they are end arteries and, therefore, if any one of them is blocked the area supplied by that particular artery will be damaged.*

Venous Drainage (Fig. 7.28)

The veins draining the cord form six longitudinal venous (Fig. 7.28) channels around the cord, viz.

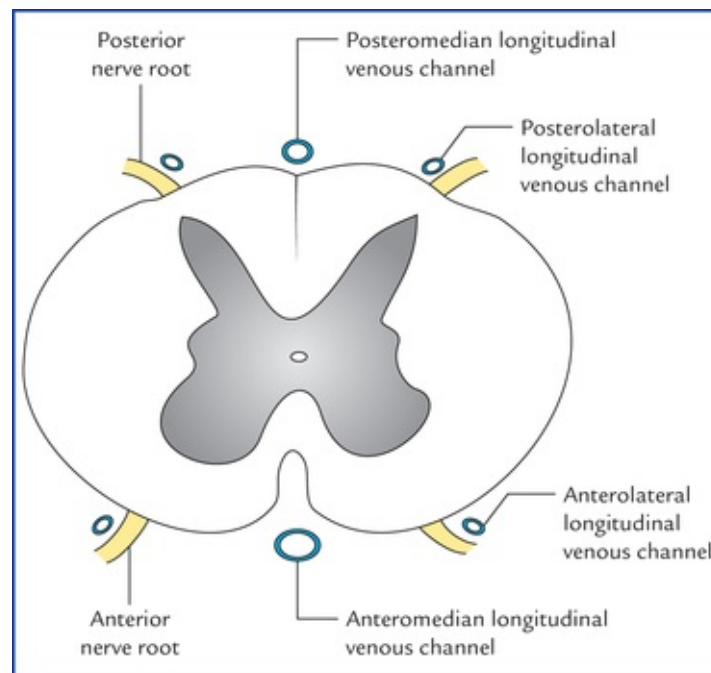


FIG. 7.28 Venous drainage of the spinal cord.

- **Two median longitudinal**, one in the anterior median fissure and the other in the posteromedian sulcus.
- **Two anterolateral**, one on either side, posterior to the anterior nerve roots.
- **Two posterolateral**, one on either side posterior to the posterior nerve roots.

These longitudinal venous channels communicate with the **internal vertebral venous plexus** and drained by veins which leave through the intervertebral foramina to empty into the vertebral, posterior intercostal, lumbar and lateral sacral veins.

The internal vertebral venous plexus communicates above with the basilar venous plexus.

Clinical Problems

1. Why are spinal cord injuries more common in the thoracic region of the vertebral column?
2. Explain why the herniation of intervertebral discs (also called disc prolapse or slipped disc) occurs most commonly in the lower parts of the cervical and lumbar regions of vertebral column.
3. What are the types and effects of intervertebral disc herniation?
4. What is cervical spondylitis and its effects?
5. What is the anatomical basis of **atonic bladder** or **automatic reflex bladder** or **autonomous bladder** in spinal cord injuries?
6. While performing **lumbar puncture**, why the lumbar puncture needle is most commonly inserted in the interspinous space between L3 and L4 vertebrae and the spine (vertebral column) is kept fully flexed.

Clinical Problem Solving

1. This is due to considerable displacement of the fractured segments of vertebra against the resistance provided by the rib-cage, and also smaller diameter of the vertebral canal in the thoracic region.
2. The herniation of the intervertebral disc occurs most commonly in those areas of the vertebral column where a mobile part joins a relatively immobile part, viz. lower parts of cervical and lumbar regions as they join with relatively fixed thoracic and sacral regions respectively.
The disc commonly involved in the cervical region are those between the C5 and C6, and C6 and C7 vertebrae. The discs commonly involved in the lumbar region are those between L3 and L4 vertebrae and between L4 and L5.
3. In herniation of the intervertebral disc, the posterior part of the annulus fibrosus ruptures and nucleus pulposus is pushed out like a paste coming out of a tube on pressure. The herniation may occur either in the midline (the *central prolapse*) leading to the compression of spinal cord, or posterolaterally close to the intervertebral foramen (the *lateral prolapse*) causing compression of roots of spinal nerves.
4. The cervical spondylitis is a degenerative condition characterised by: (a) degeneration of the intervertebral discs, and (b) the formation of osteophytes/spurs from *neurocentral joints of Luschka* which project backwards into the intervertebral foramina causing the narrowing of intervertebral foramina. Consequently the nerve roots are compressed leading to pain and muscle wasting along the distribution of the spinal nerves.

5. See [page 245](#).

6. See [page 52](#).

Brainstem

The brainstem is the stalk-like part of the brain which connects the spinal cord with the forebrain. From below upwards it consists of three parts: medulla oblongata, pons, and midbrain. The midbrain is continuous above with the cerebral hemispheres and the medulla oblongata is continuous below with spinal cord. Brainstem is located in the posterior cranial fossa. Its ventral surface lies on the clivus. Posteriorly, the pons and medulla are separated from the cerebellum by the cavity of the fourth ventricle.

The brainstem, like spinal cord consists of nerve fibres and nerve cells. Most of the nerve fibres in the brainstem are arranged longitudinally in the form of tracts as in the spinal cord. But the nerve cells of the brainstem do not form a single central mass of grey matter as in the spinal cord; rather most of them are aggregated to form the well defined nuclei. In addition to the well defined tracts and nuclei, the brainstem consists of diffuse system of nerve cells and nerve fibres called **reticular formation**. The central canal of spinal cord continues upwards in the lower part of the brainstem and then it widens and moves dorsally to form the fourth ventricle.

The brainstem serves the following four major functions:

- It provides passage to various ascending and descending tracts that connect the spinal cord to the different parts of the forebrain.
- It contains important autonomic reflex centres (**vital centres**) associated with the control of respiration heart rate and blood pressure.
- It contains reticular activating system which controls consciousness.
- It contains important nuclei of the last ten cranial nerves (i.e. IIIrd to XIIth).

***N.B.** The bilateral destructive lesions of the brainstem are fatal because of damage to 'vital centres' which control respiration, heart rate, and blood pressure. The impairment of reticular activating system leads to progressive loss of consciousness, followed by stupor and coma.*

Medulla Oblongata

The medulla oblongata is the direct upward continuation of the spinal cord, extending from foramen magnum to the lower border of the pons. It forms the lowest part of the brainstem and lies almost vertically in the anterior part of the posterior cranial fossa between the clivus (superior surface of the basi-occiput) in front and the vallecula of the cerebellum behind.

The medulla is shaped like a truncated cone (bulb-like) hence its alternative name '**bulb**' (cf. bulbar paralysis).

Medulla oblongata measures about 3 cm in length, 2 cm in breadth (at the widest part) and 1.25 cm in thickness).

The medulla contains **vital centres** which are essential for life. These are: (a) cardiac centre, (b) vasomotor centre, and (c) respiratory centre.

Medulla provides attachment to last four cranial nerves.

The lower part of the medulla like the spinal cord contains the central canal. In the upper part of the

medulla this canal widens and moves dorsally to form the lower part of the fourth ventricle. Thus, the medulla is divided into a lower closed part and an upper open part.

An overview of structural components of medulla and their functions is provided in [Table 8.1](#).

Table 8.1

Structural components and functions of the medulla oblongata

Components	Functions
Grey matter	
• Nucleus gracilis and nucleus cuneatus	Relay conscious proprioceptive sensations to the thalamus
• Olivary nuclei	Relay information associated with voluntary muscle movement to the cerebellum
• Vital centres	
– Cardiac centre	Regulates heart rate and force of contraction
– Vasomotor centre	Regulates distribution of blood flow in vessels
– Respiratory centre	Regulates respiratory movements
• Nuclei of last four cranial nerves (IX, X, XI and XII)	See Chapter 9
• Other nuclei	Relay ascending sensory information from spinal cord to the higher centres
White matter	
• Ascending and descending tracts	Connect the spinal cord with the other parts of the brain (to and fro)

Clinical Correlation

- Since the medulla contains **vital centres**, an injury to it is usually fatal. The respiratory centre is particularly vulnerable to compression and poliomyelitis with subsequent respiratory failure.
- The **bulbar paralysis** is characterised by the paralysis of muscles supplied by last four cranial nerves arising from the medulla.

External Features

The medulla is divided into right and left symmetrical halves by **anterior median fissure** and **posterior median sulcus** ([Fig. 8.1](#)).

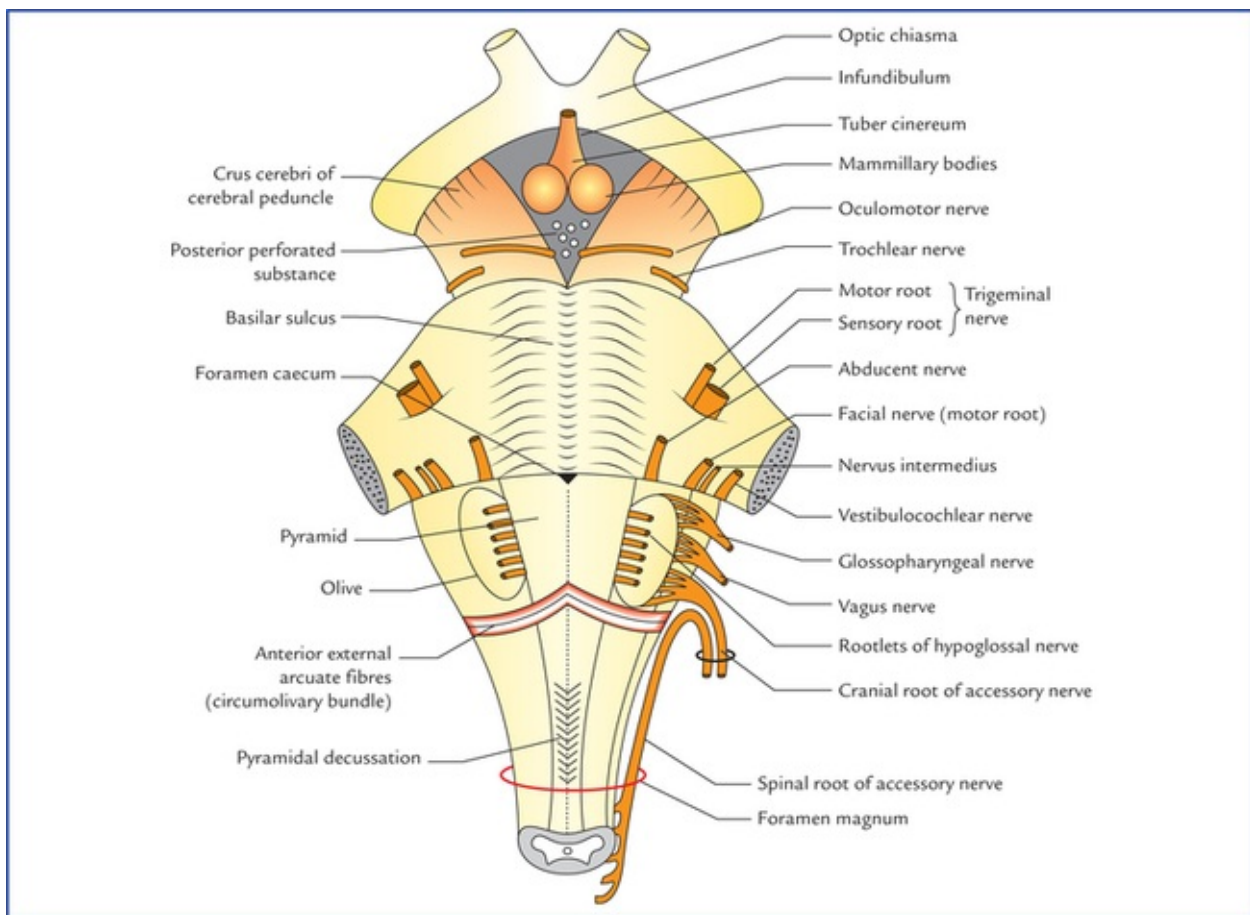


FIG. 8.1 External features on the anterior (ventral) aspect of the brainstem. Note the attachment of last cranial nerves.

The anterior median fissure is continuous below with the corresponding fissure on the spinal cord, and above it ends into a small triangular depression called **foramen caecum**, at the lower border of the pons. It is interrupted in its lower part by the bundles of fibres crossing obliquely from one side to the other, the *decussation of pyramids*.

The posterior median sulcus continues below with the corresponding sulcus of the cord and is present only in the lower half of the medulla. Above its lips diverge to form the boundaries of a triangular area, the lower part of the floor of fourth ventricle.

Each half of the medulla is marked by two sulci— anterolateral and posterolateral, which are direct upward continuations of the corresponding sulci of the cord.

The anterolateral sulcus extends along the lateral border of the pyramid and along it emerges the rootlets of the hypoglossal (XII cranial) nerve.

The posterolateral sulcus lies between the olive and the inferior cerebellar peduncle and along it emerges the rootlets of glossopharyngeal (IX), vagus (X) and accessory (XI) cranial nerves.

The anterolateral and posterolateral sulci with nerve roots divide the surface of each half of the medulla oblongata into anterior, posterior and lateral regions like that in the spinal cord.

Features on the anterior (ventral) aspect of medulla (Fig. 8.1)

The ventral aspect of medulla presents following features:

- **Pyramids.** These are two elongated elevations, one on either side of anterior median fissure and are produced by the corticospinal (pyramidal) fibres. Most of these fibres about (75%) cross to the opposite side (pyramidal decussation) in the lower part of medulla and then descend as lateral corticospinal tract in the lateral white column of the spinal cord. About 20% of uncrossed fibres run

downwards as anterior corticospinal tract in the anterior white column of the spinal cord; the remaining 5% run downwards along with uncrossed fibres in the lateral white column of the spinal cord (Fig. 8.2).

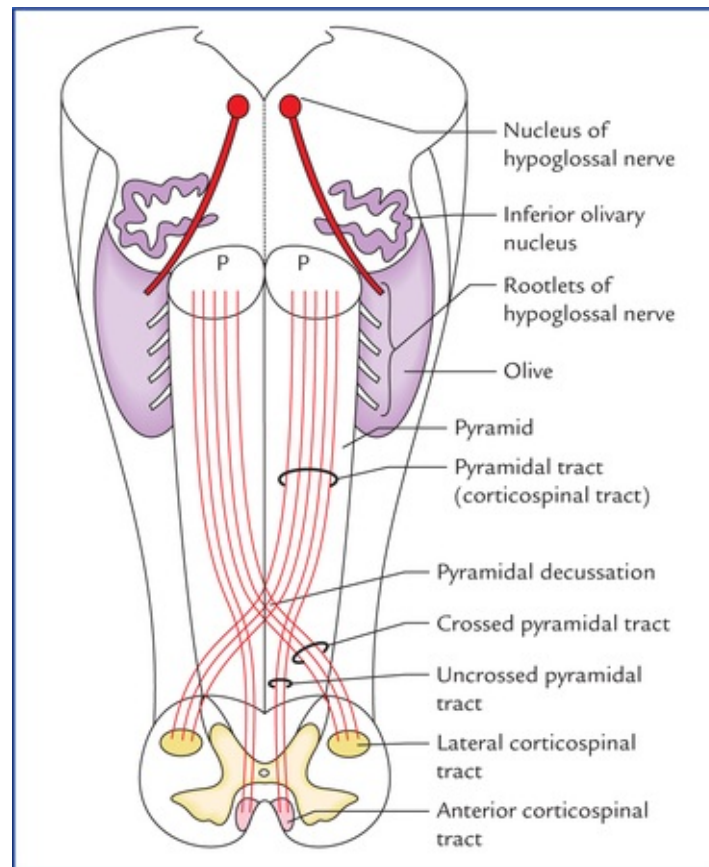


FIG. 8.2 Showing decussation of pyramidal (corticospinal) tracts in the lower part of medulla oblongata and location of lateral and anterior corticospinal tracts in the spinal cord. (P = pyramid.)

- **Olivives.** These are oval elevations, posterolateral to the pyramids and are produced by an underlying mass of grey matter called **inferior olivary nucleus**.
- **Rootlets of the hypoglossal nerve.** These emerge from the anterolateral sulcus between the pyramid and the olive.
- **Inferior cerebellar peduncles.** These are thick bundles of fibres lying posterolateral to the olive, and attach the medulla with the cerebellum.
- **Rootlets of the IXth, Xth, and XIth (cranial part) cranial nerves.** These emerge through the posterolateral sulcus separating the olive from the inferior cerebellar peduncle.

Features on the Posterior (Dorsal) Aspect of Medulla (Fig. 8.3)

The dorsal aspect the medulla is well demarcated into lower closed and upper open parts.

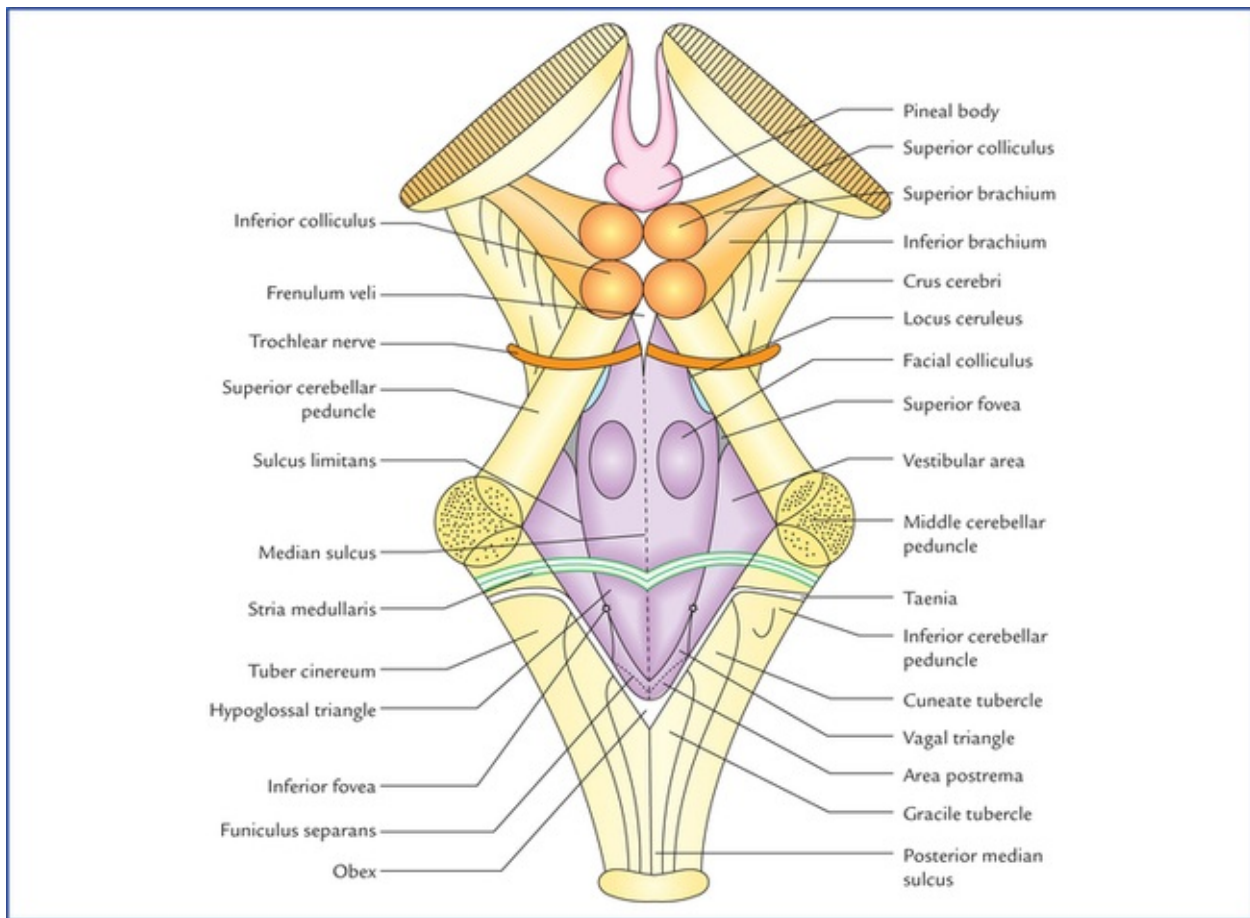


FIG. 8.3 External features on the posterior (dorsal) aspect of the brainstem. Note the features in the floor of the fourth ventricle.

Features of the closed part

The closed part, on either side of posterior median sulcus, presents three longitudinal elevations. From medial to lateral these are: fasciculus gracilis, fasciculus cuneatus, and inferior cerebellar peduncle. The upper ends of the fasciculus gracilis and fasciculus cuneatus expand to form the gracile and cuneate tubercles respectively due to underlying nuclei of the same name.

Another elevation present lateral to cuneate tubercle, the *tuber cinereum* is produced by the spinal nucleus of trigeminal nerve.

Features of the open part

The open part of the medulla forms the lower part of the floor of fourth ventricle, which presents number of features like, median sulcus, hypoglossal and vagal triangles, vestibular areas, area postrema, stria medullaris, etc. (Fig. 8.3). For details see floor of fourth ventricle on [page 122](#).

Internal Structure

As in the spinal cord, in the medulla also, the white matter surrounds the central mass of grey matter but in the latter, the grey matter is broken up into nuclei that are separated by nerve fibres. The internal structure of medulla is well appreciated by examining its transverse sections at the following four levels:

- At the level of decussation of pyramids.
- At the level of decussation of medial lemnisci.

- At the level of the olives.
- At the level just inferior to the pons.

Transverse section of medulla at the level of pyramidal decussation (the great motor decussation)

The section at this level passes through the inferior half of the medulla, and closely resembles to that of spinal cord. However, following important features are observed at this level (Fig. 8.4):

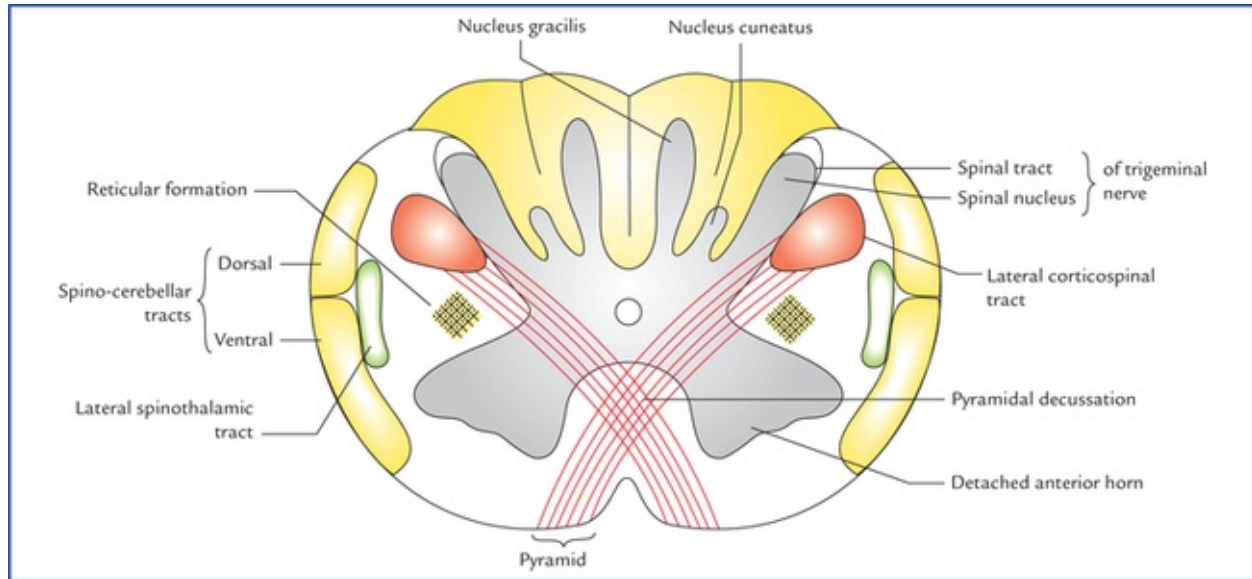


FIG. 8.4 Transverse section through the lower closed part of the medulla oblongata at the level of pyramidal decussation.

- The *nucleus gracilis* and *nucleus cuneatus* appear as the narrow strip like projections from the posterior aspect of the central grey matter.
- The apex of posterior horn gets swollen up to form the *nucleus of spinal tract of trigeminal nerve*. It is an upward continuation of the substantia gelatinosa in the posterior grey column of the spinal cord.
- The *spinal tract of trigeminal nerve* is a bundle of fibres which caps over the nucleus of spinal tract of trigeminal nerve.
- **Decussation of pyramidal tracts forms the most important feature of medulla at this level.** About 75% fibres of pyramidal tract run backwards and laterally across the midline to reach the lateral white column of the opposite side of the spinal cord, where they run downwards as the lateral corticospinal tract. In doing so the anterior horns are detached from the central grey matter.
- Each detached anterior horn divides to form the *spinal nucleus of accessory nerve and supraspinal nucleus of first cervical nerve*. The *nucleus of accessory nerve* extends downwards up to fifth cervical spinal segment. The *supraspinal nucleus* gives off the efferent fibres of the first cervical nerve, and is continuous above with the nucleus of the hypoglossal nerve.
- Appearance of diffuse zone containing a network of fibres and scattered nerve cells within it the lateral white column adjacent to nucleus of spinal tract of trigeminal nerve is called *reticular formation*.

Transverse section of medulla at the level of sensory decussation

This section passes through the middle of medulla and displays following features (Fig. 8.5):

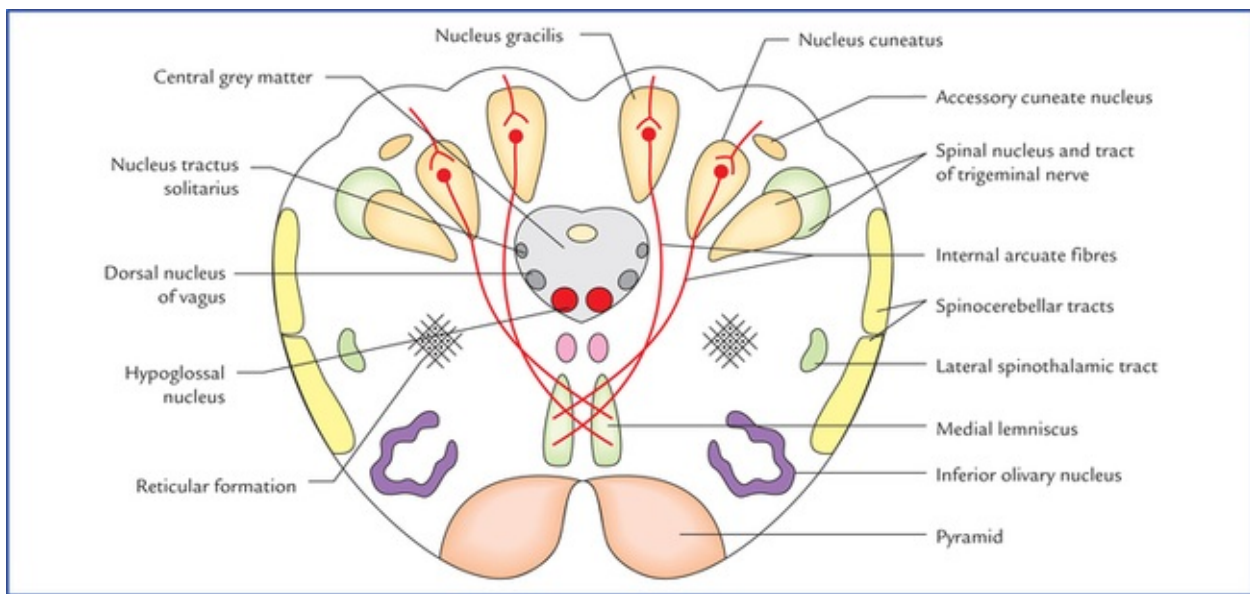


FIG. 8.5 Transverse section of medulla oblongata at the level of sensory decussation.

- The *nucleus gracilis* and *nucleus cuneatus* become more pronounced and are separated from the central grey matter. The fibres of fasciculus gracilis and fasciculus cuneatus occupy the broad posterior white column and terminate in these nuclei.
- The *internal arcuate fibres* arising from the cells of gracile and cuneate nuclei (second order sensory neurons conducting sensations of discriminative touch, position and vibration) course forwards and medially around the central grey matter and decussate with corresponding fibres of opposite side in the median plane (*sensory decussation*) and then turn upwards to ascend as the medial lemniscus on the opposite side close to the median plane. *In this decussation the gracile fibres are medial to that of cuneate fibres.*
- The *internal arcuate fibres* cut off the spinal nucleus and tract of trigeminal nerve from the central grey matter.

As the fibres from nucleus gracilis and nucleus cuneatus pass forwards and medially they intercross so that the most medial fibres (from the feet and leg) come to lie anteriorly in the medial lemniscus. In the medial lemniscus the body is represented with the head posteriorly and the feet anteriorly. The fibres of lemniscus relay into the corresponding thalamus.

- Immediately dorsolateral to the cuneate nucleus lies the *accessory cuneate nucleus* which receives the more lateral fibres (derived from the cervical segments of the cord) of the fasciculus cuneatus and gives rise to *posterior external arcuate fibres* conveying proprioceptive impulses to the cerebellum of the same side through inferior cerebellar peduncle.
- The separated *spinal nucleus and tract of trigeminal nerve* lies ventrolateral to the cuneate nucleus.
- The lower part of *inferior olivary nucleus* is seen.
- The *pyramids* lie on either side of the anterior median fissure.
- The central grey matter contains: (a) *hypoglossal nucleus*, (b) *dorsal nucleus of vagus*, and (c) *nucleus of tractus solitarius*. The hypoglossal nucleus occupies the ventro-medial position close to the midline in the central grey matter. The dorsal nucleus of vagus lies dorsolateral to the hypoglossal nucleus and nucleus of tractus solitarius lies just dorsolateral to the dorsal nucleus of vagus.
- *Medial longitudinal bundle* lies posterior to the medial lemniscus. It is small compact tract of nerve fibres which interconnect the IIIrd, IVth, VIth, VIIIth and spinal nucleus of XIth cranial nerve nuclei.
- *Spinocerebellar* and *lateral spinothalamic tracts* lie in the anterolateral area of lateral white column.

- *Lateral and anterior spinothalamic tracts* are very close to each other and collectively form **spinal lemniscus**.

Transverse section of medulla at the level of olives

Transverse section passes across the floor of the fourth ventricle and through the middle of olives and presents following features (Fig. 8.6):

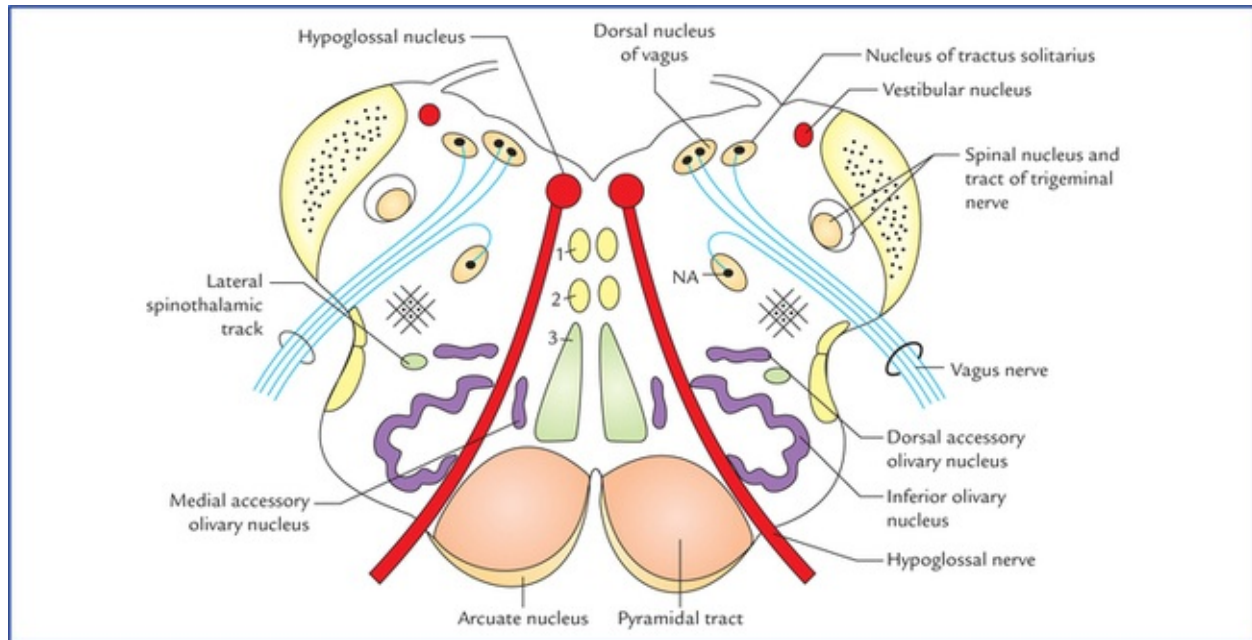


FIG. 8.6 Transverse section of medulla at the level of olives: 1. medial longitudinal fasciculus, 2. tectospinal tract, 3. medial lemniscus. (NA = nucleus ambiguus).

- The *central grey matter* is spread over the floor of the fourth ventricle and contains the nuclei of several cranial nerves. From medial to lateral these are: *hypoglossal nucleus, nucleus intercalatus, dorsal nucleus of vagus* and *vestibular nuclei* (inferior and medial).
- The *nucleus of tractus solitarius* lies ventral to vestibular nuclei.
- The *nucleus ambiguus* lies deep within the reticular formation and gives origin to the motor fibres of IXth, Xth and XIth cranial nerves.
- On either side of midline (paramedian region), from dorsal to ventral lie: *medial longitudinal fasciculus, tectospinal tract, medial lemniscus, and pyramidal (corticospinal) tract*.
- The **arcuate nuclei**, thought to be inferiorly displaced pontine nuclei are situated on the anteromedial aspect of the pyramids. They receive fibres from the cerebral cortex and send efferent fibres to the cerebellum of the opposite side through the anterior external arcuate fibres.
- Laterally, from dorsal to ventral lie two prominent structures: (a) *inferior cerebellar peduncle*, and (b) *inferior olivary nucleus*.

1. The **inferior cerebellar peduncle** occupies posterolateral part.
2. The **inferior olivary nucleus** is the largest mass of grey matter, and forms the most prominent feature in the section through upper part of medulla. It presents a crumbled bag like appearance. Close to the main nucleus lies medial and dorsal accessory olivary nuclei.

Transverse section of medulla just inferior to the pons (ponto-medullary junction)

There are no major changes in the distribution of grey and white matter in this section from that seen in the section of medulla at the level of olives. Only following features are observed:

- The *lateral vestibular nucleus* replaces the inferior vestibular nucleus.
- The *cochlear nuclei* are now visible. The dorsal and ventral cochlear nuclei lie on the dorsolateral and ventrolateral aspects of the inferior cerebellar peduncle respectively.

Blood Supply of the Medulla

The medulla is supplied by the following arteries:

- Two vertebral arteries.
- Anterior and posterior spinal arteries.
- Anterior and posterior inferior cerebellar arteries.
- Basilar artery.

Clinical Correlation

Vascular Disorders of Medulla Oblongata

The common vascular lesions involving the medulla are the thrombosis of posterior inferior cerebellar and vertebral arteries leading to lateral and medial medullary syndromes respectively.

- **Lateral medullary (posterior inferior cerebellar artery) syndrome of Wallenberg**

The dorsolateral part of the medulla is supplied by the posterior inferior cerebellar artery, which is usually the branch of the vertebral artery. This artery also supplies the inferior surface of the cerebellum.

Thrombosis of posterior inferior cerebellar artery therefore, affects a wedge-shaped area on the dorsolateral aspect of medulla (Fig. 8.7) and the inferior surface of the cerebellum and produces following signs and symptoms.

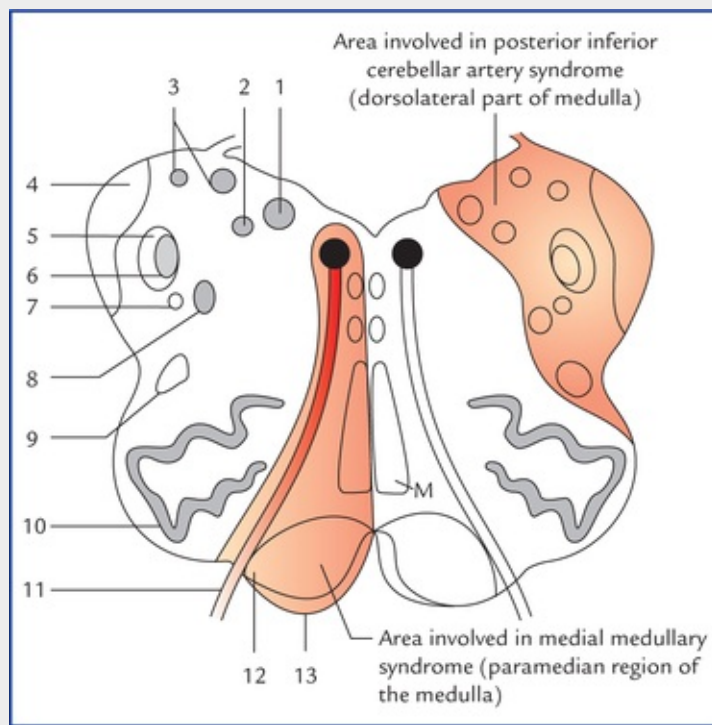


FIG. 8.7 The transverse section of the upper part of the medulla. The red areas indicate the sites of lesions: 1. dorsal nucleus of vagus, 2. nucleus of tractus solitarius, 3. vestibular nuclei, 4. inferior cerebellar peduncle, 5. spinal tract of trigeminal nerve, 6. spinal nucleus of trigeminal nerve, 7. descending sympathetic tract, 8. nucleus ambiguus, 9. lateral spinothalamic tract, 10. inferior olivary nucleus, 11. hypoglossal nerve, 12. pyramidal tract, 13. arcuate nucleus. (M = medial lemniscus.)

- *Contralateral loss of pain and temperature sensation, in the trunk and limbs, due to involvement of spinothalamic tract.*
- *Ipsilateral loss of pain and temperature sensation over the face, due to involvement of the spinal nucleus and tract of trigeminal nerve.*
- *Ipsilateral paralysis of muscles of palate, pharynx and larynx due to involvement of nucleus ambiguus.*
- *Ipsilateral ataxia, due to involvement of inferior cerebellar peduncle and cerebellum.*
- *Giddiness, due to involvement of vestibular nuclei.*
- *Horner's syndrome, due to involvement of descending sympathetic pathway in the reticular formation of medulla.*
- **Medial medullary syndrome (Dejerine's anterior bulbar syndrome; Fig. 8.7)**

The paramedian region of the medulla is supplied by the branches of vertebral artery. The vascular involvement (ischaemia) of this region produces following signs and symptoms:

- *Contralateral hemiplegia/paralysis of arm and leg, due to damage of pyramid.*
- *Ipsilateral paralysis and atrophy of the half of the tongue, due to damage of hypoglossal nerve.*
- *Contralateral loss of position and vibration sense due to damage of medial lemniscus.*

The pons is the middle part of brainstem and situated between the midbrain and the medulla. It lies in the posterior cranial fossa on the clivus (formed by the fusion of basi-sphenoid and basi-occiput) anterior to the cerebellum.

On either side, the pons is continuous as the middle cerebellar peduncle, thus forming a bridge between the two cerebellar hemispheres, hence its name, pons (L. *pons* = bridge).

Pons is about 2.5 cm long and forms the upper half of the floor of the fourth ventricle. Structurally the pons consists of grey and white matter containing number of nuclei and fibre tracts respectively.

An overview of various structural components of pons and their functions is provided in [Table 8.2](#).

Table 8.2
Structural components and functions of the pons

Components	Functions
Grey matter	
• Pontine nuclei	Relay stations of corticopontine fibres and give origin to the pontocerebellar fibres
• Nuclei of V, VI, VII and VIII cranial nerves	Give or receive nerve fibres of these cranial nerves
• Pontine respiratory centre	Modifies the output of the respiratory centres in the medulla
White matter	
• Ascending and descending tracts	Subserves the motor and sensory functions
• Transverse pontocerebellar fibres	Form the distal segment of the recently evolved 'cortico-ponto-cerebellar pathway'

External Features

The pons has two surfaces: a ventral and a dorsal; and two borders: a superior and an inferior.

Ventral (anterior) surface (Fig. 8.1)

Ventral surface is convex in both the directions, i.e. from before backwards and from side to side. It is transversely striated due to underlying ponto-cerebellar fibres.

In the median plane, it presents a vertical groove, the **basilar groove**, which lodges the basilar artery.

The **trigeminal nerve** is attached to this surface by two roots: a small motor and a large sensory root (the motor root lies medial to the sensory root). *A vertical line drawn just lateral to the attachment of sensory root demarcates the junction between the pons and middle cerebellar peduncle.*

Rostrally, the junction between midbrain and pons is marked by the *cerebral peduncles* disappearing into the upper part of the pons; caudally the pontomedullary junction is marked by a shallow groove. In this groove from medial to lateral, the abducent (VI), facial (VII), nervus intermedius, and vestibulocochlear (VIII) nerves emerge.

Dorsal (posterior) surface (Fig. 8.3)

The dorsal surface of the pons is covered by the cerebellum, and separated from it by the cavity of the fourth ventricle. The dorsal surface of the pons is triangular in shape and forms the upper part of the floor of the fourth ventricle. For details of features on the dorsal surface of pons see the floor of fourth ventricle on [page 122](#).

Superior border

The cerebral peduncles are attached to this border. The superior cerebellar arteries curve along this border, intervening between the oculomotor and trochlear nerves.

Inferior border

The upper end of the medulla is continuous with this border. The anterior inferior cerebellar arteries curve round this border.

Internal Structure

A cross-section at any level of pons shows two distinct regions: (a) a large ventral or **basilar part**, and (b) a small dorsal or **tegmental part**.

The **ventral** or **basilar part** is continuous inferiorly with the pyramids of the medulla and on each side with the middle cerebellar peduncle.

The **dorsal** or **tegmental part** is a direct upward continuation of the medulla excluding the pyramids.

The structure of basilar part is basically the same at all levels of pons, but the structure of tegmental part vary considerably in the upper and lower parts of the pons.

Basilar part

- This part is composed of the longitudinal bundles of fibres, the transverse fibres, and the pontine nuclei.
 - *Longitudinal bundles of fibres* include corticopontine, corticonuclear, and corticospinal fibres.
 - The *corticopontine fibres* relay in the ipsilateral pontine nuclei.
 - The *corticonuclear fibres* terminate in the contralateral (and to some extent ipsilateral) motor nuclei of the cranial nerves.
 - The *corticospinal fibres* converge towards the lower part of the pons and form the pyramids of the medulla.
- *Transverse fibres*, arise in the pontine nuclei and cross to the opposite side to form the middle cerebellar peduncle. These are *pontocerebellar fibres*.
- *Pontine nuclei*, are scattered among the longitudinal and transverse fibres. The pontine nuclei form an important part of the *cortico-ponto-cerebellar pathway* which connects the cerebral cortex of one side to the cerebellar hemisphere of the opposite side.

N.B. During development, some of the pontine nuclei got displaced and form the **arcuate nucleus** and the **pontobulbar body**.

Tegmental part

The tegmental part is traversed by a number of ascending and descending tracts and contained a decussation of transversely running fibres, the *trapezoid body*. It also contains the nuclei of trigeminal (V), abducent (VI), facial (VII), and vestibulocochlear (VIII) nerves.

Since, the structures of tegmentum differs in the upper (cranial) and lower (caudal) parts of the pons, it is studied by examining transverse sections at these two levels.

Transverse section through the lower (caudal) part of the pons (Fig. 8.8)

Transverse section through the lower caudal part of the pons passes through the facial colliculi.

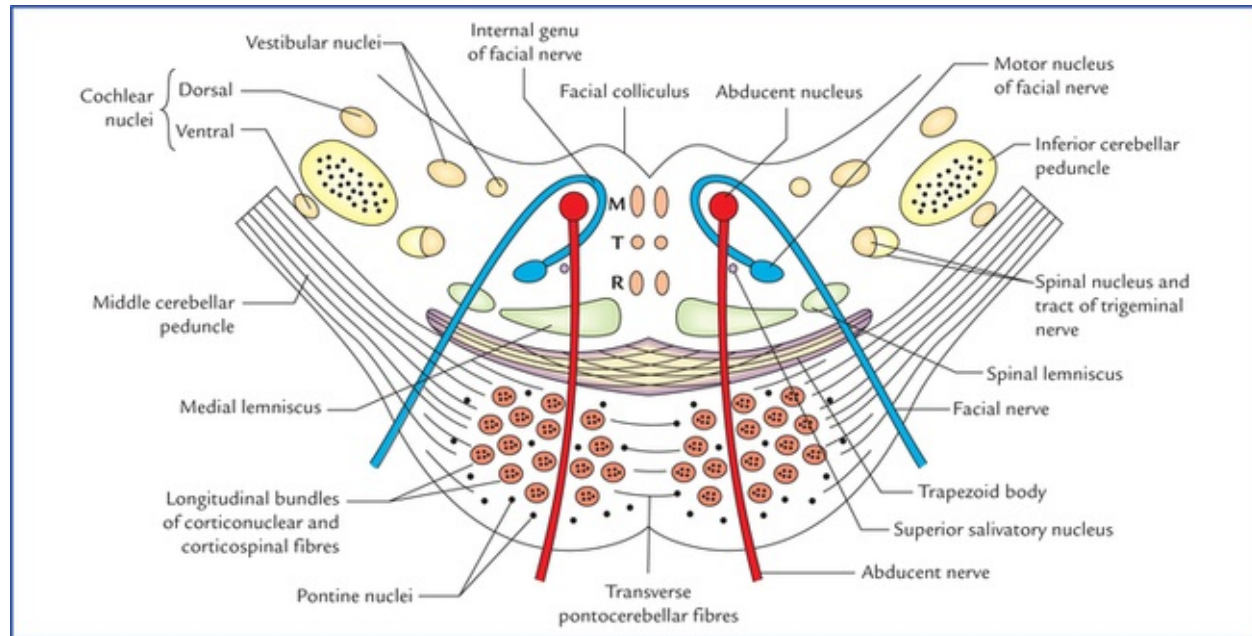


FIG. 8.8 Transverse section through the lower part of the pons. (M = medial longitudinal bundle, T = tectospinal tract, R = rubrospinal tract.)

The tegmentum at this level presents following features:

Grey matter

The grey matter at this level comprises abducent (VI), nerve nucleus, facial (VII) nerve nucleus, vestibulocochlear (VIII) nuclei, and spinal nucleus of trigeminal nerve.

- The *abducent nerve nucleus* lies beneath the facial colliculus in the floor of fourth ventricle, just lateral to the medial longitudinal bundle (MLB).
- The *motor nucleus of facial nerve* lies ventrolateral to the abducent nucleus. The fibres of facial nerve first wind round the abducent nucleus, producing the **facial colliculus** (Fig. 8.8), then pass anteriorly between the facial nucleus and the nucleus of the spinal tract of trigeminal nerve.

N.B. In the early embryogenesis the motor nucleus of facial nerve is located dorsolateral to the cranial end of abducent nucleus, thereafter, it migrates caudally along the dorsal surface of that nucleus and then ventromedial to the latter until the facial nerve nucleus reaches its permanent position in close proximity to the spinal nucleus of the trigeminal nerve (a site of maximum sensory stimulus) which establishes quick reflex responses. Such migration of motor nucleus towards the sensory nucleus is known as the “**neurobiotaxis**”. Eventually the motor fibres of the facial nerve undergo a loop course (internal genu of facial nerve) around the dorsomedial aspect of the abducent nerve nucleus.

- The *superior salivatory, inferior salivatory and lacrimatory nuclei* lie medial to the motor nucleus of facial nerve.
- The *nucleus of tractus solitarius* lies lateral to the superior salivatory nucleus.
- The *vestibular nuclei* lie beneath the vestibular area in the floor of the fourth ventricle (For details see

page 122).

- The *dorsal and ventral cochlear nuclei* are situated dorsal and ventral to inferior cerebellar peduncle respectively.
- The *spinal nucleus of trigeminal nerve and its tract* are located on the anteromedial aspect of the inferior cerebellar peduncle.

White matter

The white matter at this level comprises trapezoid body, large long (medial and spinal lemnisci) and small short (spinal tract of trigeminal nerve) tracts, medial longitudinal bundle (MLB), and small extrapyramidal and autonomic tracts.

- The *trapezoid body* is a trapezium-shaped mass of white fibres lying in the anterior part of the tegmentum, just posterior to the basilar part of the pons. It is formed by the decussation of transversely running fibres arising from the cochlear nuclei of both the sides.
- The *medial lemniscus* rotates as it passes from the medulla into the pons, and is situated in the most anterior part of the tegmentum with its long axis running transversely (Fig. 8.8). The medial lemniscus rotates in such a way that the fibres from nucleus cuneatus are medial to those from nucleus gracilis. The somatotopic representation is therefore neck, arm, trunk, and leg, in a medial to lateral sequence.
- The *spinal lemniscus* lies lateral to the medial lemniscus and occupies the same peripheral position as in the medulla.
- The *medial longitudinal bundle* occupies a paramedian position in the most posterior part.
- The *tectospinal tracts* are located ventral to the medial longitudinal bundles.
- The *spinal tract of trigeminal nerve* lies lateral and dorsal to the motor nucleus of facial nerve.

N.B. The lateral lemniscus is not yet formed as a sizeable tract.

Transverse section through the upper (cranial) part of the pons (Fig. 8.9)

Transverse section through the upper part of the pons passes through the trigeminal nuclei. The tegmentum at this level exhibits a small cavity of fourth ventricle, which is bounded dorsolaterally on either side by a superior cerebellar peduncle, and roofed by the superior medullary velum.

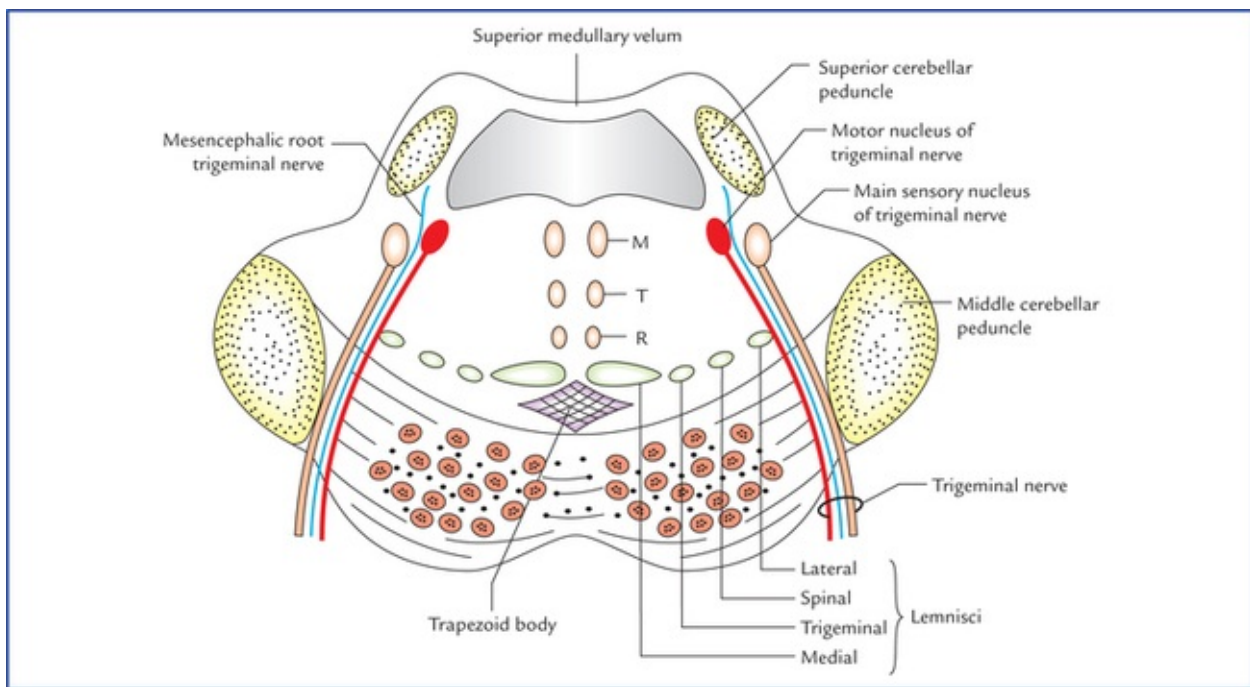


FIG. 8.9. Transverse section through the upper part of the pons. (M = medial longitudinal bundle, T = tectospinal tract, R = rubrospinal tract.)

Grey matter

The grey matter at this level comprises motor and main sensory nuclei of trigeminal nerve (*Note that the nuclear components of the abducent (VI), facial (VII) and vestibulocochlear nerves (VIII) are missing at this level. The trapezoid body and nuclei are also not seen at this level.*)

- The *motor nucleus of trigeminal nerve* is situated in the dorsolateral part, beneath the lateral part of the fourth ventricle. The emerging motor fibres travel anteriorly through the substance of the pons and exit on its anterior surface.
- The *principal (main) sensory nucleus of the trigeminal nerve* is situated lateral to the motor nucleus (*Fig. 8.9*). Caudally it is continuous with nucleus of spinal tract trigeminal nerve, and rostrally with the mesencephalic nucleus of trigeminal nerve.

N.B. *The nucleus of locus ceruleus (nucleus pigmentosus pontis) extends from lower part of the midbrain to this level of pons.*

White matter

The white matter at this level consists of the same ascending tracts as in the lower part. However, the *lateral lemniscus* is well formed here. The spinal lemniscus lies between the medial and lateral lemnisci.

The *trigeminal lemniscus* consisting of trigeminothalamic fibres is also seen between medial lemniscus and spinal lemniscus. For details, see [page 95](#).

Thus, the ventral part of tegmentum, immediately posterior to the basilar part presents four lemnisci. From medial to lateral side, these are medial lemniscus, trigeminal lemniscus, spinal lemniscus, and lateral lemniscus.

The main structural differences of the tegmentum in the lower and upper parts of the pons are given in [Table 8.3](#).

Table 8.3**Main structural differences of tegmentum in the lower and upper parts of the pons**

	Lower part	Upper part
Grey matter	Contains: nuclei of VIth, VIIth and VIIIth cranial nerves; and nucleus of spinal tract of trigeminal nerve	Contains: motor and principal sensory nuclei of trigeminal nerve; and caudal part of nucleus ceruleus
White matter	Contains 2 lemnisci: medial and spinal Trapezoid body and nuclei present	Contains 4 lemnisci: medial, trigeminal, spinal and lateral Trapezoid body and nuclei absent

Blood Supply of the Pons

The pons is supplied by the following arteries:

- Numerous (pontine) branches from the basilar artery.
- Anterior inferior cerebellar artery.

Clinical Correlation

- **Millard-Gubler syndrome (Medial inferior pontine syndrome)**

It results from a lesion in the lower part of the pons, which is so placed that it includes the pyramidal tract, the emerging fibres of the abducent and facial nerves (Fig. 8.10).

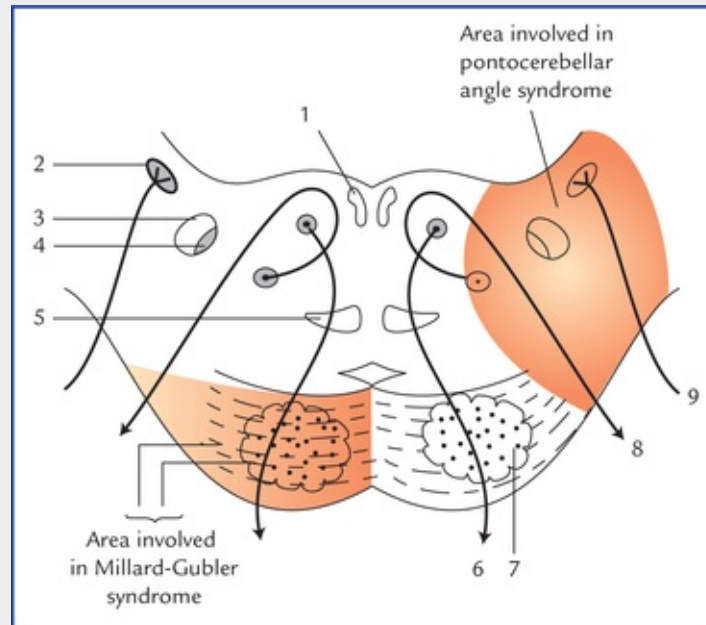


FIG. 8.10 Transverse section through the lower part of the pons. The red areas indicate the sites of lesion: 1. medial longitudinal bundle, 2. superior vestibular nucleus, 3. spinal tract of Vth cranial nerve, 4. nucleus of spinal tract of Vth cranial nerve, 5. medial lemniscus, 6. Vth cranial nerve, 7. pyramidal tract, 8. VIIth cranial nerve, 9. VIIIth cranial nerve.

The characteristic features of this syndrome are as follows:

- *Ipsilateral medial squint (inward deviation of eye towards the side of lesion) due to involvement of abducent nerve.*
- *Ipsilateral facial palsy, due to involvement of facial nerve fibres.*

– *Contralateral hemiplegia*, due to involvement of corticospinal tract.

N.B. *The term abducent alternating hemiplegia is sometimes used, as there is ipsilateral medial squint and contralateral hemiplegia.*

• **Pontocerebellar angle syndrome**

The anatomical structures located in the pontocerebellar angle include VIIth and VIIIth cranial nerves, flocculus of cerebellum and choroid plexus of fourth ventricle.

The pontocerebellar angle syndrome occurs due to pressure exerted on the lateral region of the caudal part of the pons by **acoustic neuroma**, a tumour which develops from the Schwann cells surrounding the cochlear nerve near its attachment to the brainstem.

The characteristic signs and symptoms are as follows ([Fig. 8.10](#)):

- *Tinnitus, progressive deafness, and vertigo* due to damage of VIIIth cranial nerve.
- *Ipsilateral ataxia and staggering gait* due to compression of cerebellar peduncle.
- *Ipsilateral lower motor neuron type of facial palsy*, due to involvement of facial nerve.
- *Ipsilateral loss of pain and temperature sensation and loss of corneal reflex* due to involvement of spinal tract and nucleus of trigeminal nerve.

• **Pontine haemorrhage**

The pontine haemorrhage may occur due to involvement of branches of basilar and anterior inferior cerebellar arteries. If the pontine haemorrhage is extensive and bilateral, the patient presents following clinical picture:

- *Pin-point pupil*, due to involvement of ocular sympathetic fibres.
- *Hyperpyrexia*, due to severe damage to pons, the body is cut off from heat regulating centres in the hypothalamus.
- *Deep coma*, due to involvement of reticular formation.
- *Bilateral paralysis of face and limbs*, due to involvement of facial nerve nuclei and corticospinal fibres.

• **Tumours of the pons**

The astrocytoma of the pons is the most common tumour of the brainstem. It usually occurs in childhood. The signs and symptoms depend on the area affected.

Midbrain

The midbrain is the upper and shortest part of the brain-stem. It is about 2.5 cm long and 2.5 cm wide. It connects the hindbrain with the forebrain. Its cavity, the cerebral aqueduct (aqueduct of Sylvius) connects the third ventricle with the fourth ventricle. The midbrain passes through the tentorial notch. It is related *on each side* to the optic tract, parahippocampal gyrus, posterior cerebral artery, and basal vein; *anteriorly* to the interpeduncular structures, viz. mammillary bodies, tuber cinereum, etc.; *posteriorly* to the splenium of corpus callosum, great cerebral vein, pineal body and posterior ends of right and left thalami.

The midbrain like the other parts of the brainstem consists of grey and white matter. An overview of various structural components of midbrain and their functions is provided in [Table 8.4](#).

Table 8.4**Structural components and functions of the midbrain**

Components	Functions
Grey matter	
• Superior colliculi	Reflex centres for visual reflexes
• Inferior colliculi	Lower auditory centres, probably concerned with reflexes involving auditory stimuli
• Red nuclei	Involuntary control of muscle tone and posture
• Substantia nigra	Regulate the activity of basal nuclei
• Nuclei of oculomotor and trochlear nerves	Give motor fibres to these nerves which are concerned with the activities of both intrinsic and extrinsic muscles of the eyeball
White matter	
• Cerebral peduncles containing number of ascending and descending tracts	Provides passage to the fibres of motor and sensory tracts

External Features

Ventral surface

The ventral surface of midbrain presents two *crura cerebri* which emerges from the cerebral hemispheres and converge downwards to enter the pons forming the posterolateral boundaries of the interpeduncular fossa.

The superficial surface of the crus cerebri is finely corrugated by the underlying longitudinal fibres. It is crossed transversely from above downwards by optic tract, posterior cerebral artery, superior cerebellar artery and taenia pontis (white ridge).

The oculomotor nerve emerges from a groove on the medial side of the crus cerebri.

The trochlear nerve emerges on the dorsal aspect of the midbrain and curls around the lateral aspect of the cerebral peduncle to appear on the ventral aspect of the midbrain lateral to the oculomotor nerve. These two nerves run forward between the posterior cerebral and the superior cerebellar arteries.

Dorsal surface

The dorsal surface of the midbrain presents four rounded elevations: two superior and two inferior colliculi (or *corpora quadrigemina*). The colliculi are separated from each other by a cruciform sulcus. The vertical limb of sulcus when traced above forms a surface depression which lodges the *pineal body* and when traced below, it becomes continuous with the *frenulum veli* (a median ridge on the dorsal surface of the *superior medullary velum*).

The trochlear nerves emerges one on each side of the upper part of frenulum veli after decussation in the superior medullary velum.

Thick ridges of white matter extending from lateral side of each colliculus constitute their brachia.

The *superior brachium* connect the superior colliculus to the lateral geniculate body and the optic tract, and is made up of optic tract fibres. The *inferior brachium* connect the inferior colliculus to the medial geniculate body, and is made up of auditory fibres. The superior and inferior colliculi are concerned with reflex activities triggered by auditory and visual impulses respectively.

Internal Structure

The internal structure of the midbrain is studied conveniently by examining its transverse sections. The transverse section of midbrain shows a tiny canal, called **cerebral aqueduct**. A coronal plane passing through the aqueduct divides the midbrain into two parts; a small posterior part and large anterior part (Fig. 8.11).

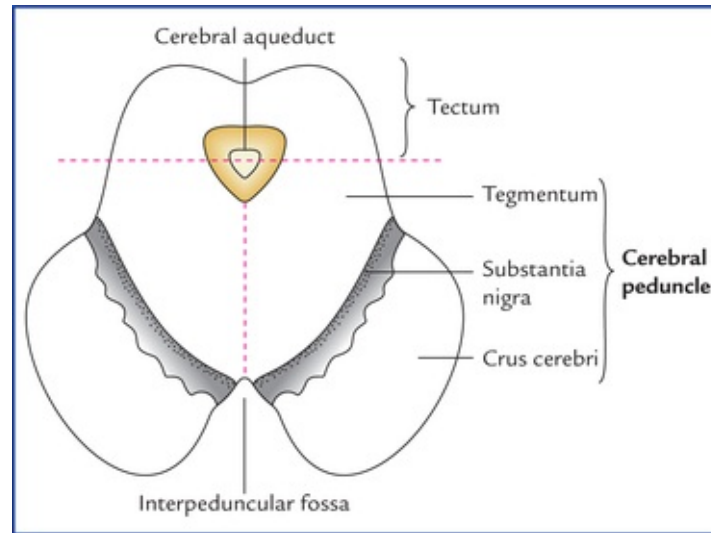


FIG. 8.11 Transverse section of the midbrain showing its main subdivisions.

The small posterior part is called **tegmentum** and consists of four colliculi. The large anterior part is divided into two equal right and left halves by a vertical plane, the **cerebral peduncle**. Each cerebral peduncle is further subdivided into three parts, from dorsal to ventral these are: (a) tegmentum, (b) substantia nigra, and (c) crus cerebri.

The structures in the tectum and tegmentum vary at different levels of the midbrain, but those of the crus cerebri and substantia nigra are nearly the same throughout the length of the midbrain.

Crus cerebri (basis pedunculi)

The crus cerebri is the part of cerebral peduncle situated anterolateral to the substantia nigra. It contains important descending tracts which connect the cerebral cortex to the anterior horn cells of the spinal cord, cranial nerve nuclei, and pontine nuclei. The **corticospinal** and **corticonuclear fibres** (pyramidal tract) occupy the middle two-thirds of the crus. The **frontopontine fibres** occupy the medial one-sixth of the crus. The **temporopontine**, **parietopontine**, and **occipitopontine fibres** occupy the lateral one-sixth of the crus.

Substantia nigra

The substantia nigra is a curved (crescent-shaped) pigmented band of grey matter (thicker medially than laterally) situated between tegmentum and crus cerebri. Its concavity is smooth and directed towards the tegmentum. From its convex margin spiky processes project into the substance of the crus cerebri.

The substantia nigra is a large motor nucleus that extends throughout the length of midbrain. It is divided into two parts: (a) the dorsal part (*pars compacta*) containing medium sized cells and (b) a ventral part (*pars reticularis*) containing fewer cells. The *pars reticularis* is intermingled with the fibres of crus cerebri.

The substantia nigra is made up of deeply pigmented nerve cells which contain melanin (a polymerized form of dopamine) and iron. These cells synthesize dopamine which is carried through their axons (*nigrostriatal fibres*) to the corpus striatum.

Clinical Correlation

The degeneration or destruction of substantia nigra causes deficiency of dopamine in the corpus striatum leading to a clinical condition called **Parkinsonism** (see Clinical correlation on page 159).

As mentioned earlier the structure of tectum and tegmentum vary at different levels, therefore it is again best studied by examining the transverse sections of the mid-brain at the following two levels: (a) at the level of the inferior colliculi, and (b) at the level of superior colliculi.

Transverse Section of the Midbrain at the Level of the Inferior Colliculi

The grey and white matter at this level present following features (Fig. 8.12):

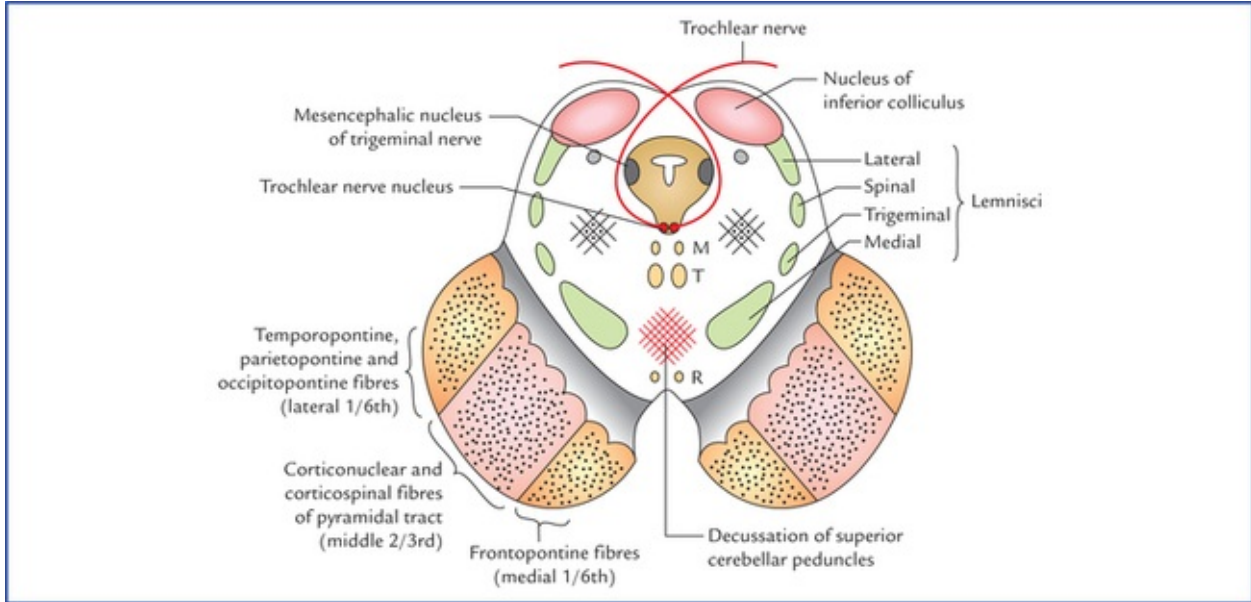


FIG. 8.12 Transverse section of the midbrain at the level of inferior colliculi. (M = medial longitudinal fasciculus, T = tectospinal tract, R = rubrospinal tract.)

Grey matter

- The central grey matter (grey matter around the cerebral aqueduct) contains two nuclei: (a) nucleus of trochlear nerve, and (b) mesencephalic nucleus of trigeminal nerve.

1. The **trochlear nerve nucleus** is situated close to the median plane just posterior to the medial

longitudinal fasciculus (MLF). The emerging fibres of the trochlear nerve pass laterally and posteriorly around the central grey matter and leave the midbrain just below the inferior colliculi. The fibres of trochlear nerve now decussate in the superior medullary vellum and wind round the lateral aspect of the midbrain to enter the lateral wall of cavernous sinus (also see [page 190](#)).

2. The *mesencephalic nucleus of trigeminal nerve* lies in the lateral edge of the central grey matter. It receives proprioceptive impulses from muscles of mastication, teeth, ocular and facial muscles.

- An ovoid mass of grey matter underneath the inferior colliculus forms the *nucleus of inferior colliculus*. It receives the afferent fibres of lateral lemniscus and gives the efferent fibres to the medial geniculate body through the inferior brachium.
- *Substantia nigra*.
- The *reticular formation* is smaller than that in the pons and is situated ventrolaterally between the medial lemniscus and the central grey matter.

White matter

- The *decussation of the superior cerebellar peduncles* occupies the central part of the tegmentum and forms the most important feature in the lower part of the midbrain.
- The *lemnisci* are arranged in the form of a curved compact band of white fibres in the ventrolateral part of the tegmentum, lateral to cerebellar decussation and dorsal to the substantia nigra. From medial to lateral side these are: *medial lemniscus*, *trigeminal lemniscus*, *spinal lemniscus*, and *lateral lemniscus*. Strictly speaking the lateral lemniscus is posterior to the spinal lemniscus and ends into the inferior colliculus.
- The *medial longitudinal fasciculus* lies on the side of median plane ventral to the trochlear nerve nucleus.
- The *tectospinal tracts* lie ventral to the medial longitudinal fasciculi.
- The *rubrospinal tracts* lie ventral to the decussation of the superior cerebellar peduncles.

Transverse Section of the Midbrain at the Level of the Superior Colliculi

The grey and white matter in the midbrain at this level present following features ([Fig. 8.13](#)):

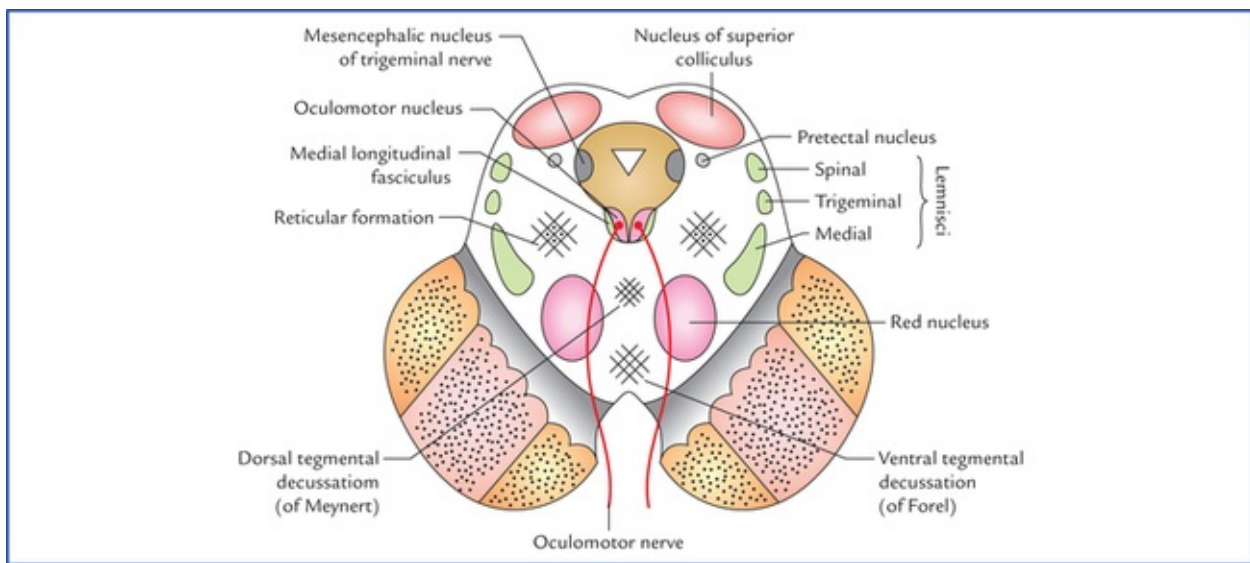


FIG. 8.13 Transverse section of the midbrain at the level of superior colliculi.

Grey matter

- The **central grey matter** in each half contains two nuclei: the oculomotor nerve nucleus and mesencephalic nucleus.
 - The **oculomotor nucleus** lies in the ventromedial part. The nuclei of two sides fuse together forming a single complex having a triangular outline. The oculomotor nuclei are bounded laterally by the medial longitudinal fasciculus. (The **Edinger-Westphal nucleus** which supplies the sphincter pupillae and ciliary muscle, forms part of the oculomotor nucleus and is located dorsal to the rostral two-thirds of the main oculomotor nucleus). The emerging fibres of oculomotor nerve pass ventrally through the tegmentum intersecting red nucleus and medial part of the substantia nigra, and emerge in the posterior part of interpeduncular fossa through the sulcus on the medial aspect of crus cerebri.
 - The **mesencephalic nucleus** occupies the same position as in the lower part of the midbrain.
- The **superior colliculus** is a flattened mass formed of seven concentric alternating laminae of white matter and grey matter.

Connections of the superior colliculus

The superior colliculus receives *afferent fibres* from:

1. The retinae (mainly the contralateral) through the lateral geniculate body and superior brachium,
2. The spinal cord (pain and tactile fibres) through spinotectaltract,
3. The frontal and occipital visual cortex (conjugate eye movements), and
4. The inferior colliculus.

The *efferent fibres* from superior colliculus form tectospinal and tectobulbar tracts, which are probably responsible for the reflex movements of the eyes, head, and neck in response to visual stimuli.

Clinical Correlation

Unilateral lesion of the superior colliculus results in relative neglect of the visual stimuli and inability to track moving objects in the contralateral field of vision, although the eye

movements are normal.

- **Pretectal nucleus** is a small group of neurons and lies deep to the superolateral part of the superior colliculus. It receives afferents from the lateral root of the optic tract and gives efferents to the Edinger-Westphal nucleus (the parasympathetic component of the oculomotor nucleus) of the same as well as of the opposite side.

The pretectal nucleus is an important part of the pathway for *pupillary light reflex* and *consensual light reflex*. Its lesion causes *Argyll Robertson pupil* in which light reflex is lost but accommodation reflex remains intact.

- **Red nucleus** is a cigar-shaped mass of grey matter which appears ovoid in cross-section. It is about 0.5 cm in diameter and situated dorsomedial to the substantia nigra. In the fresh specimen it is red/pink in colour due to its high vascular supply and an iron containing pigment present in the cytoplasm of its cells.

Connections of red nucleus (Fig. 8.14)

Afferents: (a) *Cerebellorubral fibres* from contralateral dentate nucleus of the cerebellum through superior cerebellar peduncle, (b) *corticorubral fibres*, mostly from the ipsilateral motor area (area 4 and 6 of frontal cortex), (c) *pallidorubral fibres* from globus pallidus of the same side, (d) red nucleus also receives fibres from: subthalamic nucleus (corpus luisi), hypothalamus, substantia nigra and tectum.

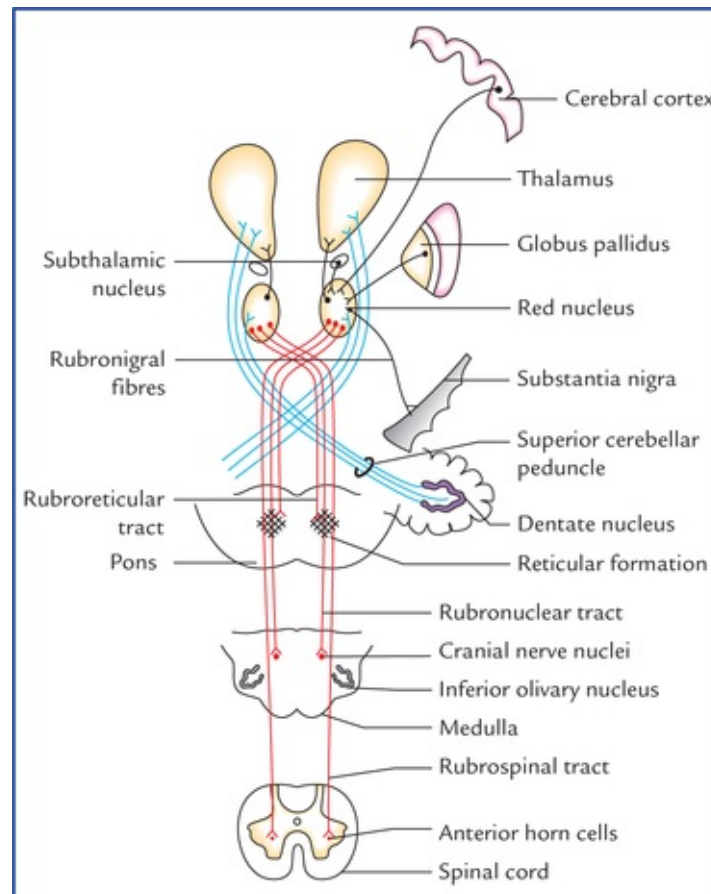


FIG. 8.14 Main connections of the red nucleus. (D = dorsal tegmental decussation, V = ventral tegmental decussation.)

Efferents: (a) *Rubrospinal, rubrobulbar and rubroreticular tracts*. The fibres from red nucleus before forming these tracts decussate forming '*ventral tegmental decussation of Forel*'. The fibres of rubrospinal tract end in the anterior horn cells of the opposite side. The rubrobulbar tract ends in the motor nuclei of Vth and VIIth cranial nerves (also in the nuclei of IIIrd, IVth and VIth cranial nerves). (b) rubroolivary fibres, (c) rubrothalamic fibres, (d) rubrocerebellar fibres, (e) rubronigral fibres.

N.B. *The red nucleus is considered as an integrating and relay centre on the following pathways: (a) cortico-rubro-spinal, (b) cortico-rubro-nuclear, and (c) cerebello-rubro-spinal.*

White matter

- Decussation of fibres (tectospinal and tectobulbar tracts) arising from superior colliculi forming **dorsal tegmental decussation (of Meynert)**.
- Decussation of fibres (rubrospinal tracts) arising from red nuclei forming **ventral tegmental decussation (of Forel)**.
- *Medial longitudinal fasciculus (MLF)* lies ventrolateral to the oculomotor nucleus.
- Tegmentum at this level also contains the same lemnisci (i.e. medial, trigeminal and spinal) as those at the level of inferior colliculus except for the lateral lemniscus. The lateral lemniscus is not seen at this level because it terminates in the nucleus of inferior colliculus.
- Emerging fibres of oculomotor nerve.

Medial Longitudinal Fasciculus (Fig. 8.15)

Medial longitudinal fasciculus (MLF) is a heavily myelinated composite tract found in the paramedian plane of the brainstem. It retains its position relative to the central grey matter throughout the midbrain, pons and cranial part of the medulla oblongata.

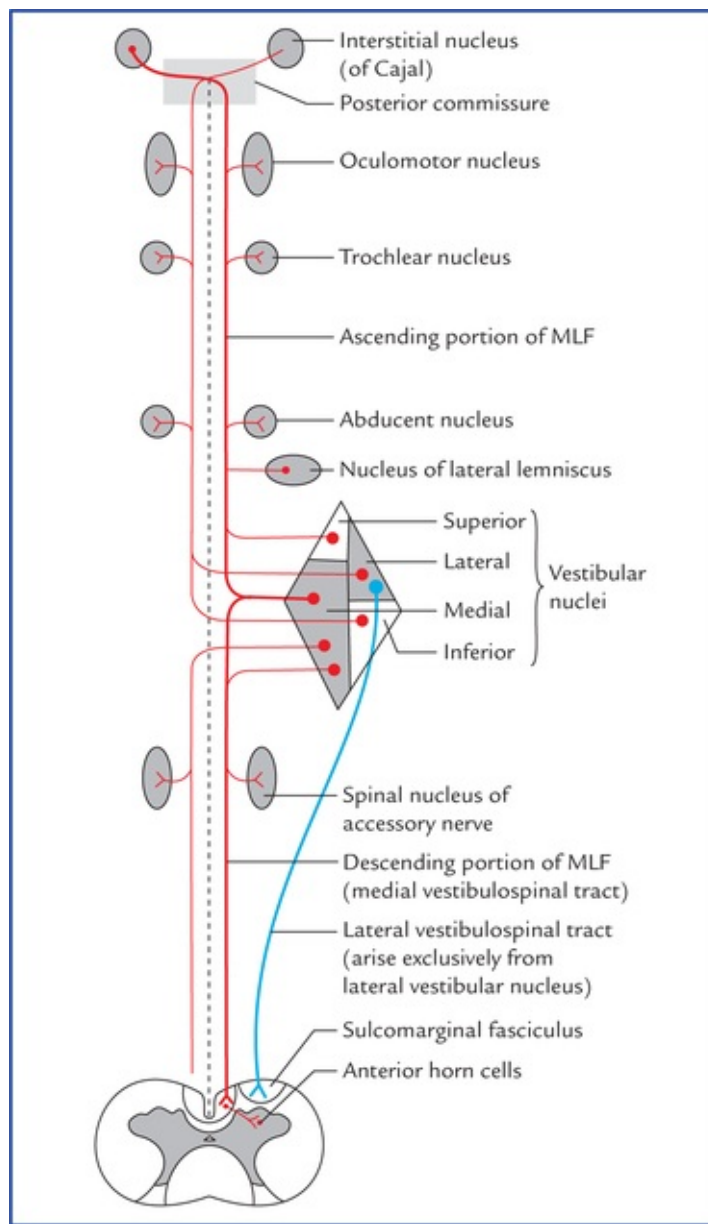


FIG. 8.15 Simplified diagram to show components of medial longitudinal fasciculus (MLF) and distribution of its fibres to cranial nerve nuclei.

The MLF extends cranially to the *interstitial nucleus of Cajal (accessory oculomotor nucleus)* located at the junction of midbrain and diencephalon near the rostral end of the cerebral aqueduct, and caudally it becomes continuous with anterior intersegmental fasciculus of the spinal cord.

The MLF consists of fibres arising mainly from vestibular nuclei (however, some fibres also arise from nucleus of lateral lemniscus and interstitial nucleus of Cajal).

The fibres of MLF interconnect the nuclei of IIIrd, IVth, Vth and VIth cranial nerves and spinal nucleus of accessory nerve.

The chief function of MLF is to coordinate the movements of eyes, head and neck in response to stimulation of the vestibulocochlear nerve.

MLF syndrome (internuclear ophthalmoplegia): It occurs due to lesion of in the upper part of the pons in the region between abducent and oculomotor nuclei. The MLF syndrome is mostly seen in multiple sclerosis and presents following clinical features:

1. Isolates paralysis of medial rectus muscle of eyeball on the side of lesion on attempted lateral gaze.
2. Mononuclear horizontal nystagmus in the adducting eye contralateral to the side of lesion.

N.B. The convergence and vertical remain unaffected.

Blood Supply of the Midbrain

Arterial supply

The midbrain is supplied by following arteries:

- Basilar artery through its posterior cerebral and superior cerebellar arteries. Basilar artery also supplies mid-brain through direct branches.
- Branches of posterior communicating and anterior choroidal arteries.

Venous drainage

- The veins of midbrain drains into the great cerebral and the basal veins.

Clinical Correlation

• Weber's syndrome

Weber's syndrome is produced by a vascular lesion in the basal region of the cerebral peduncle due to occlusion of a branch of the posterior cerebral artery. This lesion involves the oculomotor nerve and the crus cerebri (Fig. 8.16) and produce following important signs and symptoms:

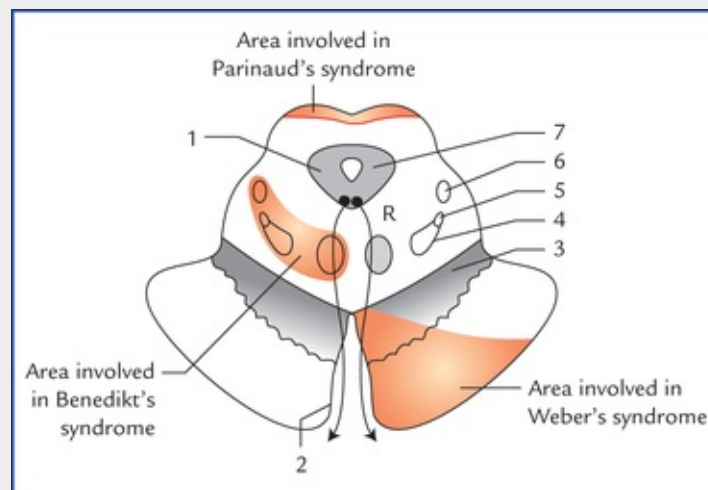


FIG. 8.16 Transverse section through the upper part of the mid-brain. The red areas indicate the sites of lesions: 1. oculomotor nucleus, 2. oculomotor nerve, 3. substantia nigra, 4. medial lemniscus, 5. trigeminal lemniscus, 6. spinal lemniscus, 7. cerebral aqueduct.

- *Ipsilateral lateral squint*, due to involvement of third cranial nerve.
- *Contralateral hemiplegia*, due to involvement of corticospinal tract in the crus cerebri.
- *Contralateral paralysis of the lower part of the face and tongue*, due to involvement of the corticobulbar tract in the crus cerebri.
- *Drooping of the upper lid (ptosis)*, due to paralysis of levator palpebrae superioris supplied by oculomotor nerve.
- *Pupil is dilated and fixed to light and accommodation is lost on the side of lesion* due to

involvement of parasympathetic component of oculomotor nerve (Edinger-Westphal nucleus).

• **Benedikt's syndrome**

Benedikt's syndrome occurs due to the vascular ischaemia of the tegmentum of midbrain involving the medial lemniscus, spinal lemniscus, red nucleus, superior cerebellar peduncle and fibres of oculomotor nerve (Fig. 8.16). It is characterised by following signs and symptoms:

- *Ipsilateral lateral squint and ptosis*, due to involvement of oculomotor nerve fibres.
- *Contralateral loss of pain and temperature sensation*, due to involvement of trigeminal and spinal lemnisci.
- *Contralateral loss of tactile, muscle, joint and vibration sense*, due to involvement of medial lemniscus.
- *Contralateral tremors and involuntary movements in the limbs*, due to involvement of red nucleus and fibres of superior cerebellar peduncle entering into it.

• **Parinaud's syndrome**

Parinaud's syndrome results from a lesion of the superior colliculi as occurs when this area becomes compressed by the tumours of the pineal gland (Fig. 8.16). It is characterised by the loss of upward gaze without affecting the other eye movements (the anatomical basis for this is obscure but experiments indicate that the area involved may contain a centre for upward movements of the eyes).

• **Argyll Robertson pupil**

The Argyll Robertson's pupil is a clinical condition in which light reflex is lost but the accommodation reflex remains intact. Generally, it occurs because of lesion in the vicinity of pretectal nucleus (for details see Chapter 18).

Clinical Problems

1. Why brainstem lesions are more dangerous than those of cerebrum and cerebellum?
2. What are the **criteria for certification of death** in majority of cases and mention the signs of **brainstem death**?
3. What is **Arnold-Chiari malformation** or phenomenon? Explain.
4. What are the presenting symptoms and signs of a patient suffering from **posterior inferior cerebellar artery syndrome**?
5. What are the signs and symptoms of a **pontine haemorrhage** patient?

Clinical Problem Solving

1. The brainstem lesions are more dangerous because they can cause sudden death as brainstem contains *vital centres* such as cardiac centre, vasomotor centre and respiratory centre. The damage of relatively large areas of cerebrum and cerebellum do

not cause death because they do not contain vital centres.

2. The complete and continuous cessation of the heart beats and respiration for 5 minutes are the criteria for the certification of death in majority of cases. The language used by doctors is that “Mr X died of cardiorespiratory arrest.”

But nowadays these functions can be maintained for years by using cardioresuscitatory measures and artificial ventilators even after the irreversible brain death. Therefore, the criteria for certifying a death in such cases have been redefined.

Since brainstem death is irreversible and incompatible with life due to involvement of cardiac and respiratory centres, the following signs of brainstem death have universally been accepted as signs of death in patients who have been kept on artificial life-supporting system:

- Absence of pupillary light reflex.
- Absence of corneal blink reflex.
- Absence of conjugate deviation of the eyes when the head is gently but fully rotated to the other side.
- Absence of eyeball movements when ice-cold water (50 ml) is poured into either external auditory meatus for 30 seconds.
- Absence of any kind of motor response to pressure on the supraorbital margins.
- Absence of gag reflex and cough reflex following stimulation of the soft palate and larynx by suction catheter.

If all the above signs are present (elicited independently by two clinicians) in addition to the cessation of the heart beats and respiration, the death can be declared safely in patients who are kept on life-supporting measures.

3. The *Arnold-Chiari malformation* is a congenital anomaly characterized by herniation of cerebellar tonsils and medulla oblongata through the foramen magnum into the vertebral canal. This results in: (a) the blockage of the openings in the roof of fourth ventricle preventing flow of CSF from ventricular system into the subarachnoid space producing internal hydrocephalus, (b) lengthening of last four cranial nerves due to downward displacement of the medulla oblongata.

4. See [page 78](#).

5. See [page 82](#).

Nuclei, Functional Components and Distribution of Cranial Nerves

There are 12 pairs of cranial nerves, out of these two pairs arise from the forebrain and 10 pairs from the brainstem (see related text on [page 47](#) and [Figs 6.9, 8.1](#)). The cranial nerves are designated by Roman numerals in order from before backwards in which they are attached on to the brain:

- I – Olfactory
- II – Optic
- III – Oculomotor
- IV – Trochlear
- V – Trigeminal
- VI – Abducent
- VII – Facial
- VIII – Vestibulocochlear
- IX – Glossopharyngeal
- X – Vagus
- XI – Accessory
- XII – Hypoglossal

***N.B.** A pair of small nerves closely related to the olfactory nerves has been described as the **thirteenth pair** (or “**O**” pair) of cranial nerves (the **nervi terminalis**). Each nerve is a minute bundle of mainly unmyelinated nerve fibres which is attached to the cerebrum posterior to olfactory stria close to anterior perforated substance and septal areas. The nerve runs forward along the medial side of corresponding olfactory tract and its branches traverse the cribriform plate of ethmoid and are distributed to the nasal mucous membrane, but its exact function is unknown.*

It is thought to: (a) provide a special chemosensory pathway of olfaction and affects the secretion of luteinizing hormone releasing factor (LHRF) from hypothalamus, (b) play an important role in smell mediated sex-behaviour.

Morphological Classification of Cranial Nerves

The cranial nerves can be classified into the following three morphological groups:

- Those **supplying the muscles derived from cranial myotomes**, viz. oculomotor (III), trochlear (IV), abducent (VI), and hypoglossal (XII) nerves.
- Those **supplying the muscles derived from branchial arches**, viz. trigeminal (V), facial (VII), glossopharyngeal (IX), vagus (X), and accessory (XI) nerves.
- Those **associated with special sense** organs, viz. olfactory (I), optic (II) and vestibulocochlear (VIII)

nerves.

Functional Columns and Nuclei of Cranial Nerves

A cranial nerve consists of motor fibres (**motor nerve**) or sensory fibres (**sensory nerve**) or both motor and sensory fibres (**mixed nerve**).

The questions on cranial nerve nuclei and their functional components are frequently asked in the examinations. The arrangement of cranial nerve nuclei, and the functional columns they represent are linked with the development of the brain; hence the following text discusses in brief, the development of functional columns and nuclei of cranial nerves.

Development of Functional Columns and Nuclei of Cranial Nerves

During the development of spinal cord due to the appearance of a longitudinal groove (the *sulcus limitans*), the lateral wall of the neural tube is divided into two parts or laminae: (a) a **dorsal alar lamina**, and (b) a **ventral basal lamina**. The cells of basal lamina are motor while those of alar lamina are sensory in function. The cells of each of these two laminae, gets arranged into two longitudinal columns: the somatic and the visceral, the visceral components lying close to the sulcus limitans. Thus, there are four functional components/columns in the lateral wall of the spinal cord from ventral to dorsal side, *viz.*

1. General somatic efferent column.
2. General visceral efferent column.
3. General visceral afferent column.
4. General somatic afferent column.

During the development of hindbrain two significant events occur: (a) the neural tube widens to form the fourth ventricle, as a result the alar laminae are splayed apart like opening a book, consequently the functional components undergo a directional change from ventrodorsal to mediolateral, and (b) an extra branchial (special) column appears between somatic and visceral columns in both basal and alar laminae to supply the derivatives of pharyngeal arches.

Apart from this, an extra special somatic column appears in the most lateral part of the alar lamina to receive sensations of hearing and balance.

Thus, there are seven functional columns in the brainstem ([Fig. 9.1A](#)), from medial to lateral side they are:

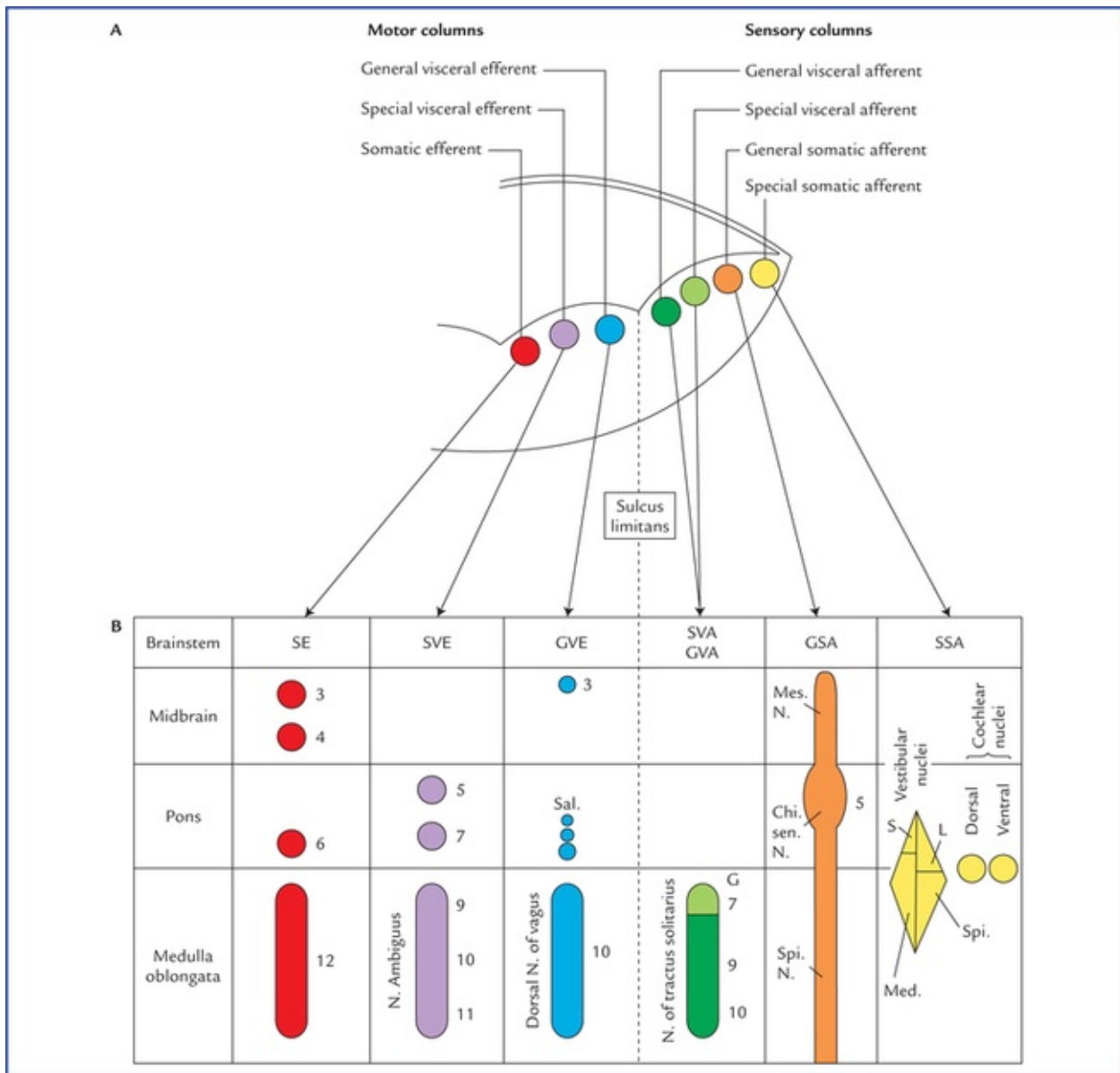


FIG. 9.1 (A) Functional columns of grey matter in brainstem (of embryo). (B) Schematic diagram to show different cranial nerve nuclei in adult brain derived from seven functional columns of grey matter. (N = nucleus, Mes = mesencephalic, Spi = spinal, Chi Sen = chief sensory, S = superior, L = lateral, Med = medial, G = gustatory nucleus, EW = Edinger-Westphal, Sal = salivatory nuclei, 3 = oculomotor, 4 = trochlear, 5 = trigeminal, 6 = abducent, 7 = facial, 8 = glossopharyngeal, 9 = vagus.)

- | | |
|------------------------------------|-------------------|
| 1. Generalsomatic efferent (GSE) | } Motor columns |
| 2. Special visceral efferent (SVE) | |
| 3. General visceral efferent (GVE) | |
| 4. General visceral afferent (GVA) | } Sensory columns |
| 5. Special visceral afferent (SVA) | |
| 6. General somatic afferent (GSA) | |
| 7. Special somatic afferent (SSA) | |

As the development proceeds, these columns differentiate into one or more discrete cranial nerve nuclei. Nuclei derived from various functional columns are enumerated in [Table 9.1](#) and shown in [Figure 9.1B](#). The surface projection of these nuclei on the dorsal aspect of the brainstem is shown in [Figure 9.2](#).

Table 9.1
Cranial nerve nuclei derived from various functional columns in the brainstem

GSE column	SVE column	GVE column	GVA/SVA column	GSA column	SSA column
• Oculomotor nucleus	• Motor nucleus of trigeminal n.	• Edinger-Westphal nucleus	• Nucleus of solitary tract (nucleus tractus solitarius)	• Sensory nuclei of trigeminal n.	• Vestibular nuclei
• Trochlear nucleus	• Motor nucleus of facial n.	• Lacrimal nucleus		1. Chief	• Cochlear nuclei
• Abducent nucleus	• Nucleus ambiguus	• Superior salivatory nucleus		2. Mesencephalic	
• Hypoglossal nucleus		• Inferior salivatory nucleus		3. Spinal	
		• Dorsal nucleus of vagus nerve			

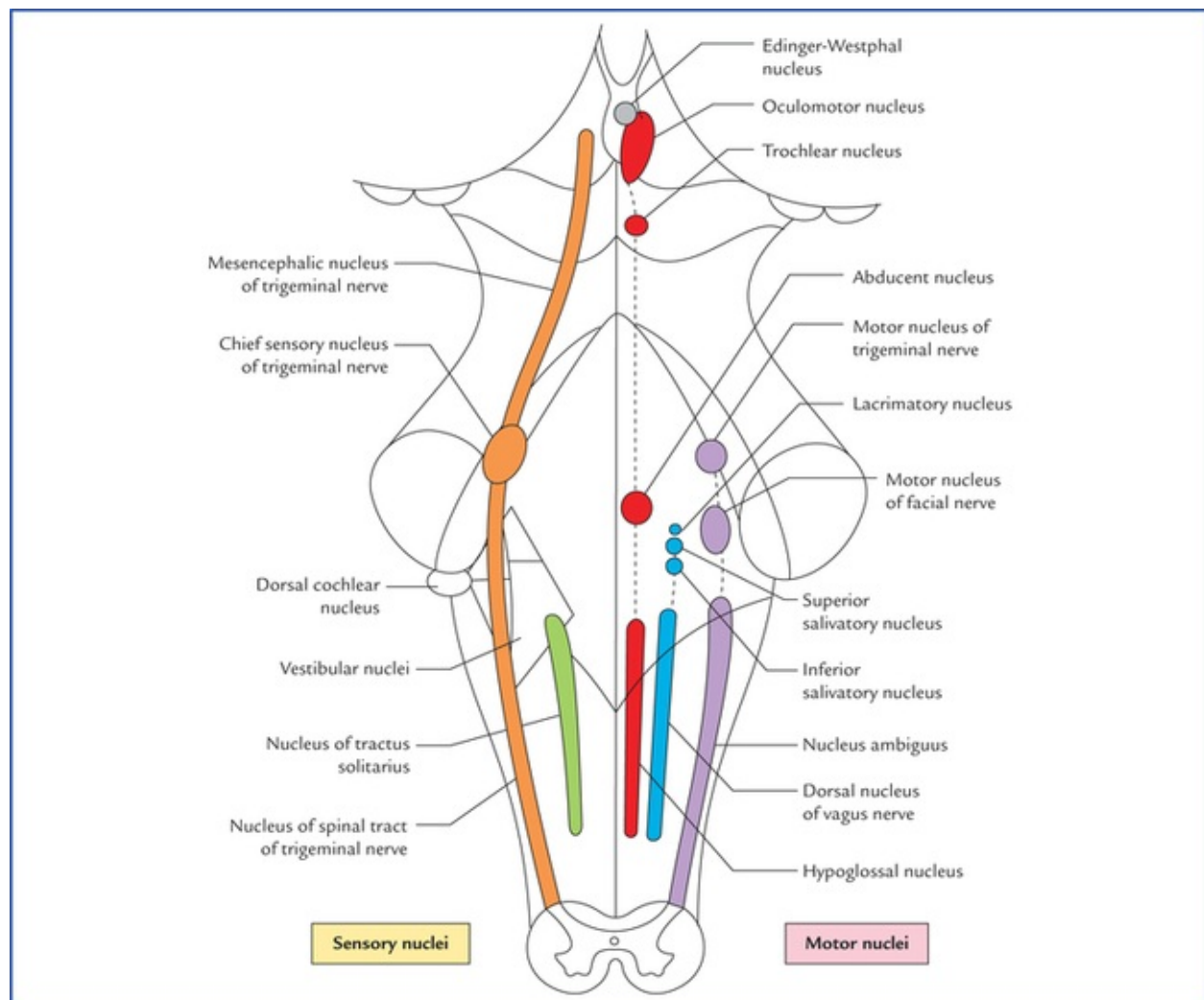


FIG. 9.2 Surface projection of cranial nerve nuclei on the dorsal aspect of the brainstem. Motor nuclei are shown on the right side and sensory nuclei on the left side.

Thus, in total there are seven functional components to which the fibres of cranial nerve may belong:

- The **general somatic efferent fibres** arise from the nuclei of general somatic efferent column, and supply the striated muscles of the limbs and body wall developing from somites ('soma' = body wall).
- The **special visceral (branchial) efferent fibres** arise from the nuclei of special visceral (branchial) efferent column and supply the striated muscles developing from branchial or pharyngeal arches, *viz.* muscles of facial expression, muscles of palate, pharynx and larynx.
- The **general visceral efferent fibres** arise from the nuclei of general visceral efferent column and supply the glands and the smooth muscles of vessels and viscera. These fibres form the *cranial outflow* of the parasympathetic nervous system.
- The **general visceral afferent fibres** carry general sensations (sense of distention and ischaemia) from the viscera, *viz.* lung, heart and upper part of GIT and associated glands to the general visceral afferent column.
- The **special visceral (branchial) afferent fibres** carry special sensation of taste from tongue, etc. to the nuclei of special visceral afferent column (this is because the epithelium of tongue including taste buds develop from endoderm (visceral)).
- The **general somatic afferent fibres** carry general sensations (pain, touch and temperature from skin) and proprioceptive sensations (vibration, muscle and joint sense) to the nuclei of general somatic afferent column.
- The **special somatic afferent fibres** carry special sensations of hearing and equilibrium to the nuclei of special somatic afferent column (this is because the organs concerned with these sensations develop from ectoderm of the body wall).

General Somatic Efferent Nuclei

General somatic efferent nuclei supply the striated muscles of somatic origin.

Oculomotor nucleus

Oculomotor nucleus is located in the central grey matter of midbrain, ventral to cerebral aqueduct at the level of superior colliculi (for details see [page 85](#)).

Trochlear nucleus

Trochlear nucleus is located in the central grey matter of midbrain, ventral to cerebral aqueduct and close to midline at the level of inferior colliculi. It is just caudal to the oculomotor nucleus and its ventral aspect is closely related to medial longitudinal fasciculus. Fibres from each trochlear nucleus course dorsally and then medially around the central grey matter to reach the cranial end of superior medullary velum, wherein they decussate to emerge on the lateral side of frenulum veli on the dorsal aspect of the midbrain ([Figs 8.3, 8.12](#)). The trochlear nerve fibres have an unusual course and this is the only nerve which emerges from the dorsal aspect of brainstem. It has been suggested that this nerve originally supplied the muscles of **pineal eye**, which would account for its dorsal course.

Unique features of the trochlear nerve

- It is the smallest and most slender cranial nerve.
- It decussates before emerging from the brain.

- It emerges on the dorsal aspect of the brain.

Abducent nucleus

Abducent nucleus is located in the lower part of the pons beneath the facial colliculus in the floor of fourth ventricle, a short distance from the median plane and in line with the nuclei of IIIrd and IVth cranial nerves above, and hypoglossal nerve below. Medial longitudinal fasciculus is closely related to its ventromedial aspect. Fibres from abducent nucleus pass ventrally downwards through the reticular formation intersecting the trapezoid body and medial lemniscus and traversing the basilar part of pons to emerge at the junction of pons and pyramid of medulla. The abducent nerve supplies the lateral rectus muscle of eyeball.

The cells in the reticular formation adjacent to the abducent nucleus constitute a “**para-abducent nucleus**” which functions as a “**centre for lateral gaze.**” These cells send fibres to the ipsilateral abducent nucleus and through the medial longitudinal fasciculus, to those cells of contralateral oculomotor nucleus that supply the medial rectus muscle. The actions of medial and lateral recti muscles are thus coordinated in horizontal movements of the eye.

Hypoglossal nucleus

Hypoglossal nucleus is an elongated column consisting of motor cells like those of anterior horn cells of the spinal cord. It extends throughout the length of medulla oblongata in the paramedian plane. The upper part of nucleus lies deep to hypoglossal triangle in the floor of IVth ventricle. The medial longitudinal bundle lies immediately ventral to it. In the closed part (lower part) of medulla, the nucleus lies in the central grey matter ventral to the central canal. The fibres from the hypoglossal nucleus course ventrally on the lateral side of medial lemniscus and emerge on the ventral aspect of medulla as a series of about 12 rootlets in the sulcus between pyramid and olive to form hypoglossal nerve ([Fig. 8.6](#)).

Special Visceral (Branchial) Efferent Nuclei

Special visceral efferent nuclei supply the striated muscles derived from branchial arches.

Motor nucleus of trigeminal nerve

Motor nucleus of trigeminal nerve is situated in the upper part of the pons, in its dorsal region, medial and just cranial to chief sensory nucleus of trigeminal nerve. Fibres from the motor nucleus constitute the motor root of trigeminal nerve which emerges on the ventral aspect of pons medial to the sensory root. The motor root crosses the superior border of petrous temporal bone and passes posterior to trigeminal ganglion. Then it passes through the foramen ovale and immediately joins the sensory root of the mandibular nerve ([Figs 8.9, 9.4](#)).

Nucleus of facial nerve

Nucleus of facial nerve is situated in the lower part of the pons, in the ventrolateral part of its tegmentum, more or less in line with the motor nucleus of the trigeminal nerve. Its position is anterolateral and caudal to abducent nucleus, and medial to the nucleus of spinal tract of trigeminal nerve. The fibres arising from the nucleus pursue an aberrant course. First they course dorsomedially towards the floor of fourth ventricle to loop behind the motor nucleus of the abducent nerve. The loop (internal genu of facial nerve) elevates the floor of fourth ventricle and forms the **facial colliculus**, and then course ventrolaterally

passing between the nucleus of their origin and nucleus of spinal tract of trigeminal nerve to emerge through the pontomedullary junction on the ventral aspect of the brainstem lateral to the emergence of the abducent nerve.

The unusual course of motor fibres of facial nerve represents an example of **neurobiotaxis** (for details see [page 80](#)).

Nucleus ambiguus

Nucleus ambiguus is an elongated column of typical motor neurons, extending throughout the length of medulla. Nucleus ambiguus is so named because it is not clearly defined in sections of the medulla. It occupies a position dorsal to the inferior olivary nucleus and ventromedial to the nucleus of spinal tract of Vth nerve. Fibres from nucleus ambiguus are first directed dorsally and then turn sharply in the ventrolateral direction to mingle with other fibres of IXth, Xth, and XIth cranial nerves, which emerge from medulla along the posterolateral sulcus ([Fig. 8.6](#)). The fibres from nucleus ambiguus supply the muscles derived from third, fourth and sixth branchial arches.

General Visceral Efferent Nuclei

The cells of these nuclei give origin to preganglionic fibres that constitute the cranial parasympathetic outflow. These fibres end in the peripheral parasympathetic ganglia. The postganglionic fibres arising in these ganglia supply smooth muscles or glands.

Edinger-Westphal nucleus (visceral oculomotor nucleus)

Edinger-Westphal nucleus is located in the upper part of the midbrain dorsal to the rostral two-thirds of the main oculomotor nucleus ([Fig. 9.5](#)). Preganglionic para-sympathetic fibres arising from this nucleus reach the ciliary ganglion by way of oculomotor nerve, where they terminate.

Superior salivatory and lacrimatory nuclei

Superior salivatory and lacrimatory nuclei are seen as “indefinite clusters of small nerve cells” in the dorsal part of pons medial to the motor nucleus of facial nerve.

The preganglionic fibres from **superior salivatory nucleus** pass to the submandibular ganglion through the nervus intermedius, geniculate ganglion, facial nerve and its chorda tympani branch (see [Fig. 20.10](#)).

Preganglionic fibres from **lacrimatory nucleus** reach the pterygopalatine ganglion through nervus intermedius and greater superficial petrosal nerve ([Fig. 20.10](#)).

Inferior salivatory nucleus

Inferior salivatory nucleus is a small collection of nerve cells in the dorsolateral part of pons, just above its junction with the medulla. It lies immediately caudal to the superior salivatory nucleus and just above the upper end of the dorsal nucleus of the vagus nerve. Preganglionic fibres from this nucleus run in the glossopharyngeal nerve, enter its tympanic branch (nerve of Jacobson) and relay in the “otic ganglion” by way of tympanic plexus and lesser superficial petrosal nerve ([Fig. 20.9](#)).

Dorsal nucleus of vagus (also called motor nucleus of vagus)

Motor nucleus of vagus is a long vertical column of cells extending throughout most of the length of

medulla. Its upper end lies deep to the vagal triangle in the floor of the fourth ventricle. When traced downwards in the closed part of medulla, it occupies a position in the lateral part of central grey matter, dorsal to the hypoglossal nucleus (Fig. 8.5). This nucleus is the main source of parasympathetic fibres of vagus nerve.

The dorsal nucleus of vagus is usually described as mixed nucleus representing the fused general visceral efferent and general visceral afferent columns. According to the other school of thought, the general visceral afferent column is incorporated in the special visceral afferent column representing the nucleus of tractus solitarius.

General and Special Visceral Afferent Nuclei

General and special visceral afferent nuclei are represented by only one nucleus, the nucleus of solitary tract.

Nucleus of solitary tract (Fig. 9.3)

Nucleus of solitary tract is an elongated column of cells and is intimately related to a group of descending fibres which constitute the tractus solitarius. The upper part of the nucleus lies deep in the reticular formation, ventrolateral to the dorsal nucleus of vagus (Fig. 8.6). When traced downwards it lies in the dorsal part of central grey matter in the closed part of the medulla, dorsomedial to the dorsal nucleus of vagus (Fig. 8.5). The lower ends of the nuclei of two sides fuse to form the **commissural nucleus of the vagus**. The rostral portion of the nucleus is concerned with taste sensations and receives the special visceral afferent fibres from facial, glossopharyngeal and vagus nerves and is frequently referred to as **gustatory nucleus**. The nuclear terminations of VII, IX and X nerves are in rostrocaudal direction (Fig. 9.3). The caudal portion of the nucleus receives the general visceral sensations from pharynx (glossopharyngeal and vagus) and from oesophagus and abdominal part of alimentary canal up to right two-thirds of the transverse colon (vagus). It is presumed that axons from nucleus of tractus solitarius project to the thalamus and hypothalamus of the opposite side through the *solitariothalamic* and *solitariohypothalamic tracts* respectively. These tracts join the medial lemniscus of the opposite side on their way to thalamus and hypothalamus. The neurons from thalamus then project to the cerebral cortex (Fig. 9.3).

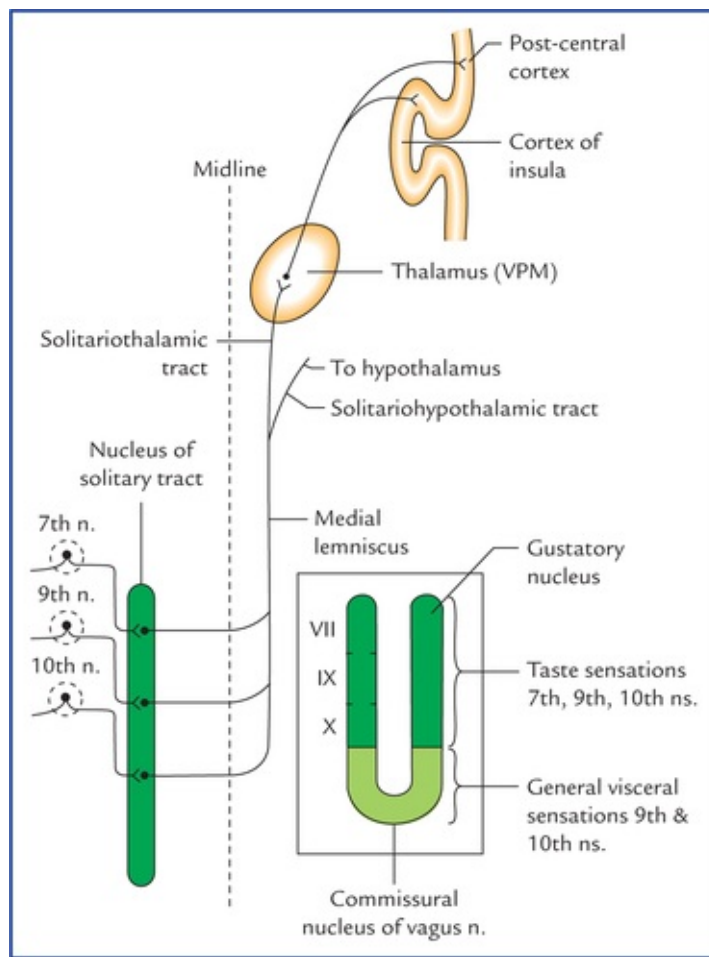


FIG. 9.3 Connections of nucleus tractus solitarius. The inset on the right side shows that the lower ends of the nuclei of two sides fuse to form the *commissural nucleus* of the vagus nerve.

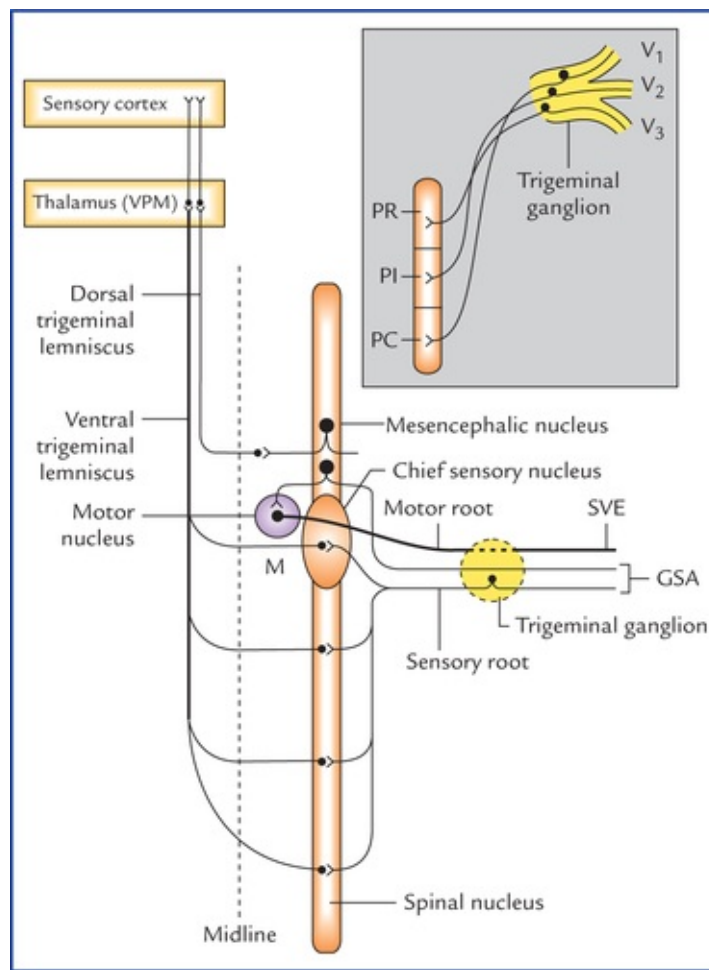


FIG. 9.4 Schematic illustration to show connections of trigeminal nerve nuclei. M = motor nucleus. Inset on the right upper corner shows the subdivisions of spinal nucleus of trigeminal nerve and disposition of afferent fibres from its ophthalmic maxillary and mandibular divisions. (PR = pars rostralis, PI = pars inter-polaris, PC = pars caudalis, V1 = ophthalmic nerve, V2 = maxillary nerve, V3 = mandibular nerve, M = motor nucleus, SVE = special visceral efferent, GSA = general somatic afferent.)

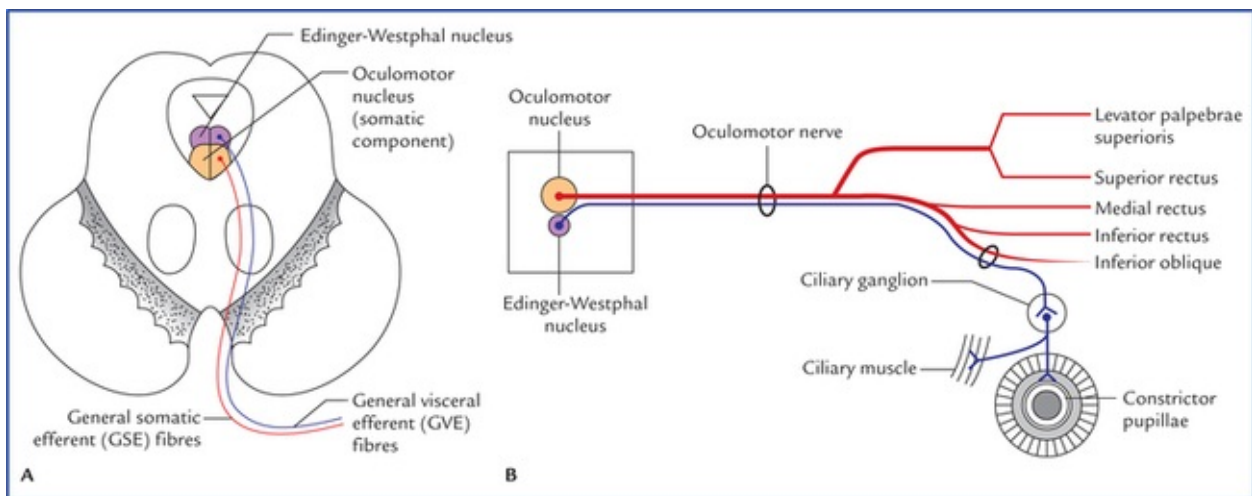


FIG. 9.5 Nuclei, functional components and course of the oculomotor nerve. (A) Functional components, (B) course and distribution.

General Somatic Afferent Nuclei

General somatic afferent nuclei include the three sensory nuclei of the trigeminal nerve.

Chief sensory nucleus of trigeminal nerve

Chief sensory nucleus of trigeminal nerve lies in the dorsolateral region of the tegmentum of the upper part of the pons lateral to the motor nucleus (of trigeminal) and occupies an intermediate position between the mesencephalic nucleus above and the spinal nucleus below (Fig. 9.4). It is concerned only with the tactile sensibility.

Spinal nucleus of trigeminal nerve

Spinal nucleus of trigeminal nerve extends caudally from chief sensory nucleus in the pons to the second cervical spinal segment and lies just medial to the spinal tract of trigeminal nerve. The spinal nucleus and tract of trigeminal nerve are chiefly concerned with the pain and temperature sensations. Based on the cytoarchitecture, the spinal nucleus is divided into three parts (or subnuclei): In craniocaudal direction these are: (a) *pars rostralis*, (b) *pars interpolaris*, and (c) *pars caudalis* (Fig. 9.4).

Main afferents of chief sensory and spinal nuclei are the central processes of cells in the trigeminal ganglion (which makes up the large sensory root). After entering the pons many of these processes divide into ascending and descending branches. Others either ascend or descend without being branched.

The ascending fibres end in the chief sensory nucleus. The descending fibres from a large bundle of fibres called **spinal tract of trigeminal nerve**. Fibres of the spinal tract terminate in the subjacent spinal nucleus. The afferents from three trigeminal divisions rotate, so that the fibres of ophthalmic division terminate in the *pars caudalis*, the fibres of maxillary division in the *pars interpolaris* and the fibres of mandibular division in *pars rostralis*.

As described earlier, the fibres ending in the chief sensory nucleus are predominantly concerned with touch, and those ending in spinal nucleus are concerned predominantly with sensations of pain and temperature.

It is important to note at this juncture that in addition to trigeminal nerve, the spinal tract receives a small component of fibres from the VIIth, IXth and Xth cranial nerves which carry the general somatic sensations from external ear, mucosa of posterior third of tongue, pharynx and larynx.

Fibres arising from cells of chief sensory and spinal nuclei are the second order neurons (comparable to those of the spinothalamic tracts) cross to the opposite side and form a bundle called **trigeminal lemniscus** which ascends up and relay in the thalamus (ventral posteromedial nucleus) from where third order neurons arise and project to the sensory area of the cerebral cortex.

A separate bundle of more dorsally situated trigeminothalamic fibres (also called *dorsal trigeminal lemniscus*) is also described.

Mesencephalic nucleus of trigeminal nerve

Mesencephalic nucleus of trigeminal nerve extends from upper end of chief sensory nucleus in the pons to the midbrain where it lies in the central grey matter lateral to the cerebral aqueduct. Because it extends rostrally into the midbrain, it is called *mesencephalic nucleus*. Like dorsal root ganglia of spinal cord it is made up of pseudounipolar cells (1st order sensory neurons) and appears to have similar functions (*the mesencephalic nucleus is unique in the sense that it is the only site in CNS which contains the cell bodies of first order sensory neurons*). Peripheral processes of these cells carry proprioceptive impulses from the muscles of mastication, temporomandibular joint, teeth and possibly also from the extrinsic muscles of tongue. Central processes terminate in the motor nuclei of trigeminal nerve of the both sides.

These connections establish the stretch reflex originating in the neuromuscular spindles in masticatory muscles, together with a reflex for control of the force and accuracy of bite (Barr, N.L., 1972). These reflexes prevent the tongue from being bitten during chewing. Other central processes relay in the cells of reticular formation. From which fibres arise and run through *dorsal trigeminal lemniscus* to relay in the ventral posteromedial nucleus (VPM) of the thalamus (Fig. 9.4).

N.B. Out of the three sensory nuclei of the trigeminal nerve, the chief sensory nucleus is mainly responsible for sense of touch, the spinal nucleus for sense of pain and temperature, and mesencephalic nucleus for sense of proprioception.

Special Somatic Afferent Nuclei

Cochlear nuclei

Cochlear nuclei are two in number, dorsal and ventral. They are placed on the dorsal and ventral aspects of the inferior cerebellar peduncle respectively in the upper part of the medulla.

The cochlear nuclei contain the cell bodies of the second order sensory neurons in the auditory pathway. Their connections are described in Chapter 18.

Vestibular nuclei

Vestibular nuclei are situated partly in the medulla and partly in the pons, immediately beneath the lateral part of the floor of the fourth ventricle called *vestibular area*. On the basis of cytoarchitecture and afferent and efferent connections, four distinct vestibular nuclei are recognised, viz. (a) inferior or spinal vestibular nucleus, (b) lateral vestibular nucleus (also called Dieter's nucleus), (c) superior vestibular nucleus, and (d) medial vestibular nucleus (Fig. 8.15).

- **Inferior vestibular nucleus** lies in the medulla, just medial to the inferior cerebellar peduncle. It is continuous rostrally with the lateral vestibular nucleus and related medially to the medial vestibular nucleus. It extends from the cranial end of nucleus gracilis to the pontomedullary junction.
- **Lateral vestibular nucleus** lies immediately cranial to inferior vestibular nucleus and extends upwards in the pons almost to the level of nucleus of abducent nerve. It is composed of large multipolar cells resembling typical motor neurons. The cells of this nucleus give origin to the fibres of lateral vestibulospinal tract (Fig. 8.15).
- **Superior vestibular nucleus** is smaller in size and located entirely within the pons above the medial and lateral vestibular nuclei.
- **Medial vestibular nucleus** extends from medulla at the level of olive to the lower part of the pons. It is bounded laterally and rostrally by the other three vestibular nuclei. Its medial border is near the midline of the brainstem. The caudal end of this nucleus is near the caudal limit of the fourth ventricle.

Connections of the vestibular nuclei

Afferents

- *Fibres of the vestibular nerve (main afferents)*: Most of the vestibular nerve terminate in the four vestibular nuclei, however, few pass directly to the cerebellum by way of inferior cerebellar peduncle to the flocculonodular lobe.
- *Cerebellovestibular fibres*: The fibres from cerebellar cortex (flocculonodular lobe) relay in the nucleus fastigius which give rise to the *fastigiobulbar tract*. The fibres of this tract mostly pass

through inferior cerebellar peduncle, some fibres, however, as they pass from cerebellum, loop around the superior cerebellar peduncle to form the *uncinate fasciculus (tract of Russell)* before joining the main tract which terminate in the vestibular nuclei.

Efferents

- *To the cerebellum (vestibulocerebellar fibres):* Most of these fibres arise from vestibular nuclei, however, few are the direct fibres of vestibular nerve from cells of vestibular ganglion as noted above. These fibres pass through the medial portion of the inferior cerebellar peduncle (**juxta-restiform body**) of the same side to relay into the cortex of archicerebellum.
- *To the spinal cord:* The principal connections between the vestibular nuclei and spinal cord are mediated through the vestibulospinal tract and the descending portion of the medial longitudinal fasciculus.
 - *Vestibulospinal tract (also called lateral vestibulospinal tract) (Fig. 8.15):* Fibres of this tract arise exclusively from lateral vestibular nucleus. They descend downwards in the medulla dorsal to the inferior olivary nucleus and continue so in the anterior funiculus of the spinal cord, where they terminate on the anterior horn cells at all level of spinal cord especially in regions of cervical and lumbosacral enlargements. The vestibulospinal tract is uncrossed and regulates the muscle tone throughout the body in such a manner that the balance is maintained.
 - *Descending portion of medial longitudinal fasciculus:* Fibres from vestibular nuclei, mainly from medial, project towards the midline and then turn caudally in the **medial longitudinal fasciculi** of both the sides which continue downward into the *sulcomarginal fasciculus* of anterior funiculus of spinal cord and terminate on anterior horn cells throughout the cervical part of the spinal cord. These connections provide for changes in the tone of neck muscles as required to support the head in various positions and during various movements.
- *To the cranial nerve nuclei:* Fibres from vestibular nuclei first project towards the midline than ascend up in **ascending portions of the medial longitudinal fasciculi** of both the sides and synapse with the cells of IIIrd, IVth and VIth cranial nerve nuclei; and downwards in the **descending portions of the MLFs** and synapse with spinal nucleus of XIth cranial nerve. These connections provide for the synchronized conjugate movements of the eyes, coordinated with the movements of the head (such coordination relies heavily on the information required by vestibular nuclei from semicircular canals or kinetic labyrinth).

Having considered the cranial nerve nuclei and there connections, it is now possible to workout the functional components of the individual cranial nerves.

Nuclei, Functional Components and Distribution of Individual Cranial Nerves

I Olfactory Nerve (Nerve of Smell)

The fibres of this nerve are classified as **special somatic afferent (SSA)**. They carry sense of smell from olfactory epithelium of nose which is derived from ectoderm (of nasal placodes). For details see olfactory system in [Chapter 18](#).

II Optic Nerve (Nerve of Vision)

Optic nerve fibres are also regarded as **special somatic afferent (SSA)**. The retina develops from optic vesicle of the forebrain and contains two types of receptors for light, viz. rods and cones. The visual impulses from these receptors run through bipolar cells to the ganglion cells. The axons of ganglion cells converge towards the optic disc. They pierce the choroid and sclera to leave the eyeball and form the optic nerve. In view of its structure and development the optic nerve is regarded as the tract rather than a peripheral nerve. For details see visual system in [Chapter 18](#).

Unique features of the optic nerve

- It is not a peripheral nerve but a tract (a prolongation of white matter of the brain) as the optic nerve develops from the stalk of optic vesicle.
- It is covered by three meninges (pia, arachnoid and dura) of the brain.
- It is devoid of neurilemmal sheath.
- Its fibres are myelinated by oligodendrocytes.

Clinical Correlation

The optic nerve, if damaged, cannot regenerate because its constituent fibres are devoid of neurilemmal sheath.

III Oculomotor Nerve

Functional components

This nerve has following functional components ([Fig. 9.5A](#)):

- **General somatic efferent fibres (GSE)**. These fibres arise from main oculomotor nucleus and supply all the extrinsic muscles of the eyeball including levator palpebrae superioris except lateral rectus and superior oblique. These fibres form the main component of the oculomotor nerve.
- **General visceral efferent fibres (GVE)**. These fibres arise from Edinger-Westphal nucleus and pass through the oculomotor nerve to terminate in the ciliary ganglion. These are preganglionic parasympathetic fibres. The postganglionic fibres from ciliary ganglion, run through short ciliary nerves to supply the sphincter pupillae and ciliary muscles.

Course and distribution ([Fig. 9.5B](#))

The oculomotor nerve arises from medial aspect of cerebral peduncle. It continues forwards in the interpeduncular cistern between the posterior cerebral and superior cerebellar arteries. It pierces pia and arachnoid as it enters the back of cavernous sinus. Here it lies above the trochlear nerve in the lateral wall of the cavernous sinus. In the anterior part of the cavernous sinus, it divides into upper and lower divisions. Both of these divisions of oculomotor nerve enter the orbit through the middle part of the superior orbital fissure, within the common tendinous ring (of Zinn). The distribution of upper and lower divisions of oculomotor nerve is presented in the [Table 9.2](#).

Table 9.2

Distribution of oculomotor nerve

Division	Functional components	Distribution
Upper	• GSE	– Superior rectus (GSE)
	• GVE	– Levator palpebrae
		– Superioris (GSE + GVE)
		– Dilator pupillae (GVE)
Lower	• GSE	– Inferior rectus (GSE)
		– Inferior oblique (GSE)
		– Medial rectus (GSE)
	• GVE (Parasympathetic)	– Constrictor pupillae (GVE)
		– Ciliary muscle (GVE)

GSE = general somatic efferent fibres, GVE = general visceral efferent fibres.

Along its course in the cavernous sinus the oculomotor nerve picks up the sympathetic fibres (GVE) from the sympathetic plexus around the internal carotid artery. These fibres are postganglionic and arise from superior cervical sympathetic ganglion. The preganglion fibres arise from first thoracic (T1) spinal segment. The sympathetic fibres supply dilator pupillae and smooth part of the levator palpebrae superioris (**muscle of Muller**).

The oculomotor nerve plays an important role in the movements of the eyeball, and is responsible for accommodation. In addition it forms parts of pathways involved in *pupillary reflexes*.

Clinical Correlation

In **oculomotor** nerve palsy: (a) the eye is fixed in lateral and downward position (**lateral squint/strabismus**) due to unopposed action of the lateral rectus and superior oblique, (b) the pupil is dilated due to unopposed action of dilator papillae (which is supplied by sympathetic fibres accompanying the nasociliary branch of the ophthalmic nerve), and (c) the upper eyelid droops down (ptosis) due to paralysis of levator palpebrae superioris.

IV Trochlear Nerve

Functional components

It consists of only *general somatic efferent (GSE) fibres* which arise from the *trochlear nucleus* and supply only one muscle, the superior oblique muscle of the eyeball.

Course and distribution

The trochlear nerve arise on the dorsal aspect of midbrain below the inferior colliculus just lateral to the frenulum veli. It courses ventrally around the cerebral peduncle, along and just below the free margin of the tentorium cerebelli. It pierces pia and arachnoid and enters the back of cavernous sinus lateral to the third nerve. In cavernous sinus, it crosses to the medial side of the oculomotor nerve and occupies a more cranial position. It enters orbit through the lateral part of the superior orbital fissure outside the common

tendinous ring (of Zinn) to supply superior oblique muscle (Fig. 9.6).

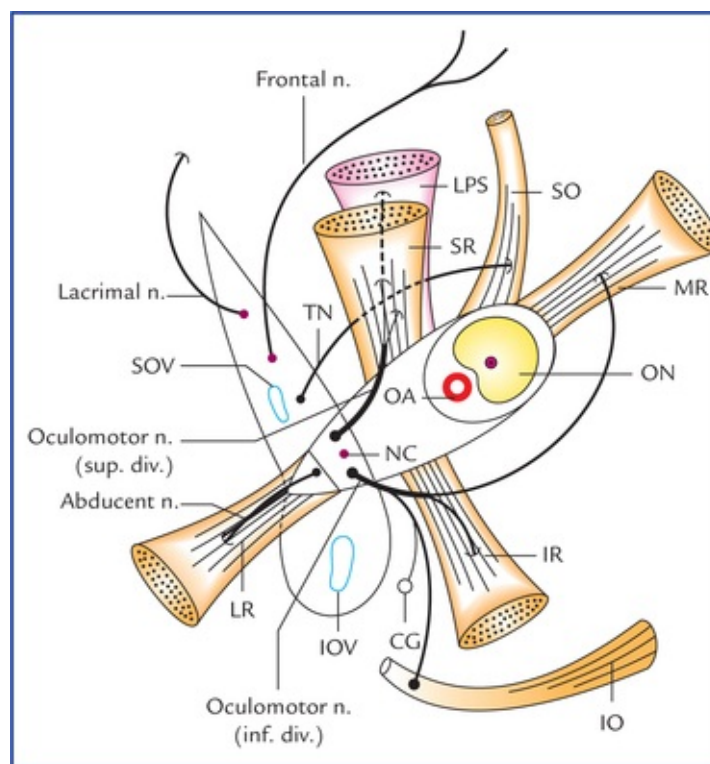


FIG. 9.6 Distribution of IIIrd (oculomotor), IVth (trochlear), and Vth (abducent) cranial nerves. (LPS = levator palpebrae superioris, SR = superior rectus, IR = inferior rectus, MR = medial rectus, LR = lateral rectus, ON = optic nerve, OA = ophthalmic artery, NC = nasociliary nerve, CG = ciliary ganglion, SOV = superior ophthalmic vein, IOV = inferior ophthalmic vein, TN = trochlear nerve.)

Clinical Correlation

The superior oblique is the only depressor of the eyeball during adduction, therefore in **trochlear nerve palsy** (the isolated injury of trochlear nerve is uncommon) the eye is extorted and elevated due to unopposed action of inferior oblique. The vertical diplopia occurs in this position as the image falls on the upper half of the retina. The diplopia worsens when patient looks down, when the eye is adducted.

V Abducent Nerve

Functional components

This nerve consists of *general somatic efferent (GSE) fibres* only which arise from the abducent nucleus and supply only lateral rectus muscle of the eyeball.

Course and distribution

The abducent nerve emerges at pontomedullary junction above the pyramid of the medulla. It runs forwards to the dura on the clivus. It then pierces dura mater lateral to the dorsum sellae below the

petroclinoid ligament (ligament of Grubar). Here it crosses sharp superior border of petroustemporal bone. It enters the back of cavernous sinus. In the sinus it runs along the posterolateral aspect of the internal carotid artery. It enters the orbit, through the intermedial part of superior orbital fissure within the common tendinous ring (of Zinn); to supply the lateral rectus muscle (Fig. 9.7).

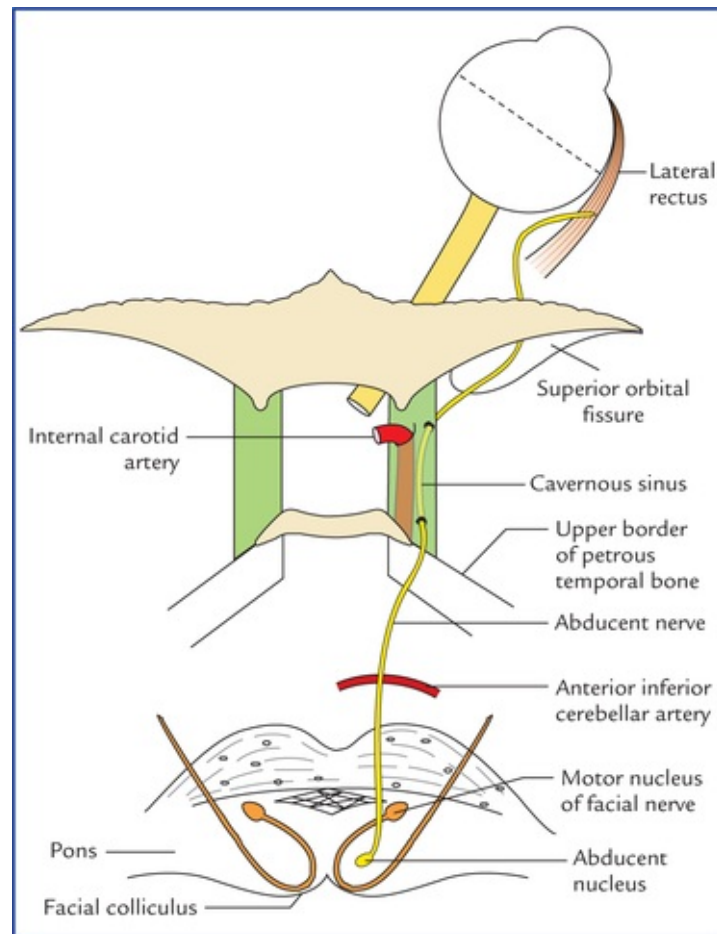


FIG. 9.7 Origin, course and distribution of abducent nerve.

Clinical Correlation

The **abducent nerve palsy** is the most common isolated palsy occurring due to increased intracranial pressure.

The abducent nerve lesion causing paralysis of lateral rectus results in the **medial** or **convergent squint/strabismus** (i.e. eyeball is fixed in the medial position) due to unopposed action of the medial rectus. The horizontal diplopia occurs, which increases when patient attempts to look towards the paralysed side.

The distribution of IIIrd (oculomotor), IVth (trochlear) and VIth (abducent) cranial nerves is shown in Figure 9.6.

VI Trigeminal Nerve

Functional components

This nerve has following functional components:

- **Special visceral efferent (SVE) fibres** arise from **motor nucleus** and supply the muscles derived from the first pharyngeal arch mesoderm, *viz.* muscles of mastication, tensor tympani, tensor palati, anterior belly of digastric and mylohyoid.
- **General somatic afferent (GSA) fibres** are divided into two groups:
 - Fibres carrying exteroceptive sensations from skin of the face and mucous membrane of the mouth and nose. The cell bodies of these neurons lie in the trigeminal ganglion. Most of the central processes of these neurons bifurcate, the ascending branches terminate in the **chief sensory nucleus** whereas descending branches end in the **spinal nucleus**.
 - Fibres carrying proprioceptive sensations from muscles of mastication, temporomandibular joint, teeth and tongue. The cell bodies of these neurons lie in the **mesencephalic nucleus**.

The peripheral processes of nerve cells located in the trigeminal ganglion and mesencephalic nucleus are arranged into three divisions of the trigeminal nerve, *viz.* ophthalmic, maxillary and mandibular. The functional components of these divisions are listed in [Table 9.3](#).

Table 9.3

Functional components in the three divisions of trigeminal nerve

Division	Functional components
Ophthalmic	GSA fibres
Maxillary	GSA fibres
Mandibular	GSA and SVE fibres

Course and distribution (Fig. 9.8)

The trigeminal nerve arises by two roots from pons at its junction with the middle cerebellar peduncle. The two roots are: (a) a very large lateral sensory root, and (b) a small medial motor root.

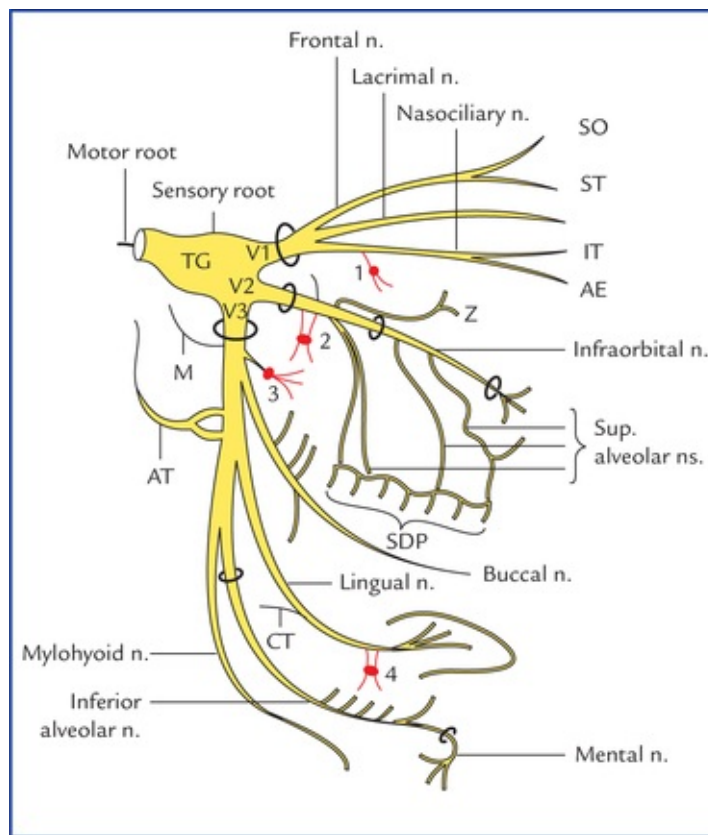


FIG. 9.8 The distribution of trigeminal nerve. (TG = trigeminal ganglion, V1 = ophthalmic division, V2 = maxillary division, V3 = mandibular division, 1 = ciliary ganglion, 2 = pterygopalatine ganglion, 3 = otic ganglion, 4 = submandibular ganglion, NS = nervus spinosus, NM = nerve to medial pterygoid, M = masseteric n., D = deep temporal ns., NL = nerve to lateral pterygoid, AT = auriculo-otemporal n., CT = chorda tympani n., SO = supraorbital n., ST = supratrochlear n., T = infratrochlear n., AE = anterior ethmoidal n., SDP = superior dental plexus). **Note:** All the parasymphathetic ganglia (1, 2, 3, and 4) of head and neck region are morphologically associated with the trigeminal nerve.

The two roots run forward and laterally over the apex of petrous temporal bone to enter the middle cranial fossa. Here the sensory root exhibits an enlargement—the **trigeminal ganglion**. The trigeminal ganglion divides into branches: ophthalmic, maxillary and mandibular.

The ophthalmic nerve runs forwards in the lateral wall of the cavernous sinus and divides into three branches: lacrimal, frontal and nasocilliary before entering the orbit through superior orbital fissure. Through these branches ophthalmic nerve supplies the eyeball, conjunctiva, upper part of nasal cavity, lacrimal gland, the skin of forehead, the external nose and eyelids. The ophthalmic nerve also forms the afferent limb of the **corneal reflex**.

The **maxillary nerve** leaves the skull through foramen rotundum to enter the pterygopalatine fossa, then it enters the orbit through inferior orbital fissure and acquires name *infraorbital nerve*. The **infraorbital nerve** leave the orbit through infraorbital foramen to emerge on the face. Thus, maxillary nerve traverses four regions: middle cranial fossa, pterygopalatine fossa, orbit and face. The branches of maxillary nerve are: (a) *meningeal branch* in the middle cranial fossa, (b) *ganglion branches* to pterygopalatine ganglion, (c) *zygomatic nerve*, and (d) **posterior superior alveolar nerve** in the pterygopalatine fossa, (e) *middle superior alveolar, nerves* in orbit; and palpebral, lateral nasal and labial branches in the face. Through these branches, it supplies, nasal cavity, palate, upper teeth and gums and skin of the middle third of the face. It provides sensory supply to the mucous membrane of the nasopharynx and the maxillary sinus. It conveys secretomotor fibres to the lacrimal gland.

The mandibular nerve leave the skull through the foramen ovale to enter the infratemporal fossa. Here, just below the basal skull it is joined by motor root of the trigeminal nerve. Motor root accompanies the

sensory root, these passes deep at the side of trigeminal ganglion and leaves the skull through mandibular foramen to join the mandibular division of trigeminal nerve to form the trunk of mandibular nerve.

The trunk of mandibular nerve terminates into two large divisions—anterior and posterior. The following branches arise from mandibular nerve:

- Meningeal branch (nervus spinosus).
- Nerve to medial pterygoid from undivided trunk.
- Masseteric nerve.
- Deep temporal nerves (2 in number).
- Lateral pterygoid nerve.
- Buccal nerve from anterior division.
- Auriculotemporal nerve.
- Lingual nerve.
- Inferior alveolar nerve from posterior division.

Through these branches mandibular nerve supplies the muscles of mastication (temporalis, masseter, medial and lateral pterygoids), mylohyoid, anterior belly of diaphragm, tensor veli palatine and tensor tympani. The sensory fibres supply auricle, temporal region, skin of the lower one-third of face except over angle of mandible.

Clinical Correlation

- **Lesion of trigeminal nerve** presents following clinical features:
 - Loss of general sensation from face and mucous membrane of oral and nasal cavities.
 - Loss of corneal reflex.
 - Flaccid paralysis of muscles of mastication. Jaw deviates to the side of lesion due to unopposed action of lateral pterygoid muscle.
 - Hypoacusis (partial deafness to low pitched sounds due to paralysis of tensor tympani muscle).
- **Trigeminal neuralgia (tic douloureux)** is a paroxysmal severe pain of sudden onset and short duration in the area of cutaneous distribution of one or more of the divisions of the trigeminal nerve, usually affecting the 2nd and 3rd divisions ([Fig. 9.9](#)).

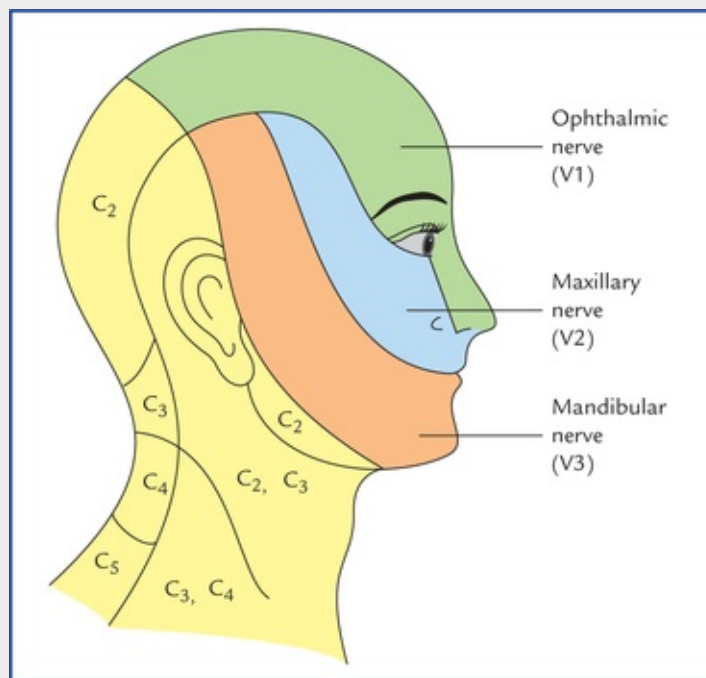


FIG. 9.9 Areas of the face supplied by three divisions of the trigeminal nerve.

VII Facial Nerve

Functional components

Facial nerve has the following functional components (Fig. 9.10):

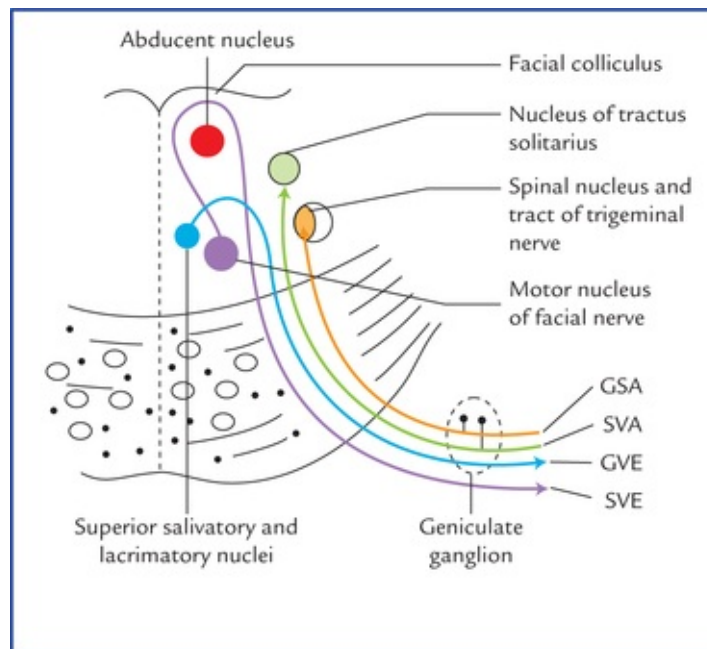


FIG. 9.10 Functional components and nuclei of the facial nerve. (GSA = general somatic efferent, SVA = somatic visceral afferent, GVE = general visceral efferent, SVE = special visceral efferent.)

- **Special visceral efferent (SVE) fibres** arise from *motor nucleus* and supplies the muscles derived

from the mesoderm of 2nd pharyngeal arch, viz. muscles of facial expression, etc.

- **General visceral efferent (GVE) fibres** are preganglionic parasympathetic fibres to the pterygopalatine and submandibular ganglia for lacrimation and salivation respectively. These fibres arise from the *lacrimatory and the superior salivatory nuclei* respectively.
 - The preganglionic fibres arising from lacrimatory nucleus terminate in the pterygopalatine ganglion, from which postganglionic fibres arise and supply the lacrimal gland through zygomatic branch of trigeminal nerve.
 - The preganglionic fibres arising from superior salivatory nucleus relay in the submandibular ganglion, from which postganglionic fibres arise and supply the submandibular and sublingual salivary glands.
- **Special visceral afferent (SVA) fibres** are concerned with the taste sensations. The cell bodies of these fibres lie in the geniculate ganglion. The peripheral processes of ganglion cells carry taste sensations from the taste buds on the anterior two-third of the tongue except vallate papillae. The central processes of ganglion cells carry these sensations to the upper part of the *nucleus of tractus solitarius*.
- **General somatic afferent (GSA) fibres** have their cell bodies in the geniculate ganglion. The peripheral processes of these cells innervate part of the skin of the external ear, while the central processes terminate in the *spinal nucleus of trigeminal nerve*.

Course and distribution (Fig. 9.11)

The facial nerve arises by two roots—motor and sensory on the ventral aspect brainstem from the lower border of the pons opposite the groove between the olive and inferior cerebellar peduncle. The main trunk, i.e. motor root enters the external auditory meatus accompanied by the small sensory root (*nervus intermedius* of Wrisberg), vestibule cochlear nerve and labyrinthine vessels. At the lateral end of meatus two roots unite to form the trunk of the facial canal where it first runs above the bony labyrinth of internal ear and then bends posteriorly in the medial wall of the middle ear, forming **genu of facial nerve**. It runs posteriorly in the middle ear medial wall below the lateral semicircular canal. Finally the nerve turns 90° and runs in the posterior wall of the middle ear till it reaches the stylomastoid foramen at the base, through which it leaves the cranial cavity. Finally, it runs anterolaterally to enter the parotid gland, where it divides into five terminal branches. The facial nerve gives off following branches:

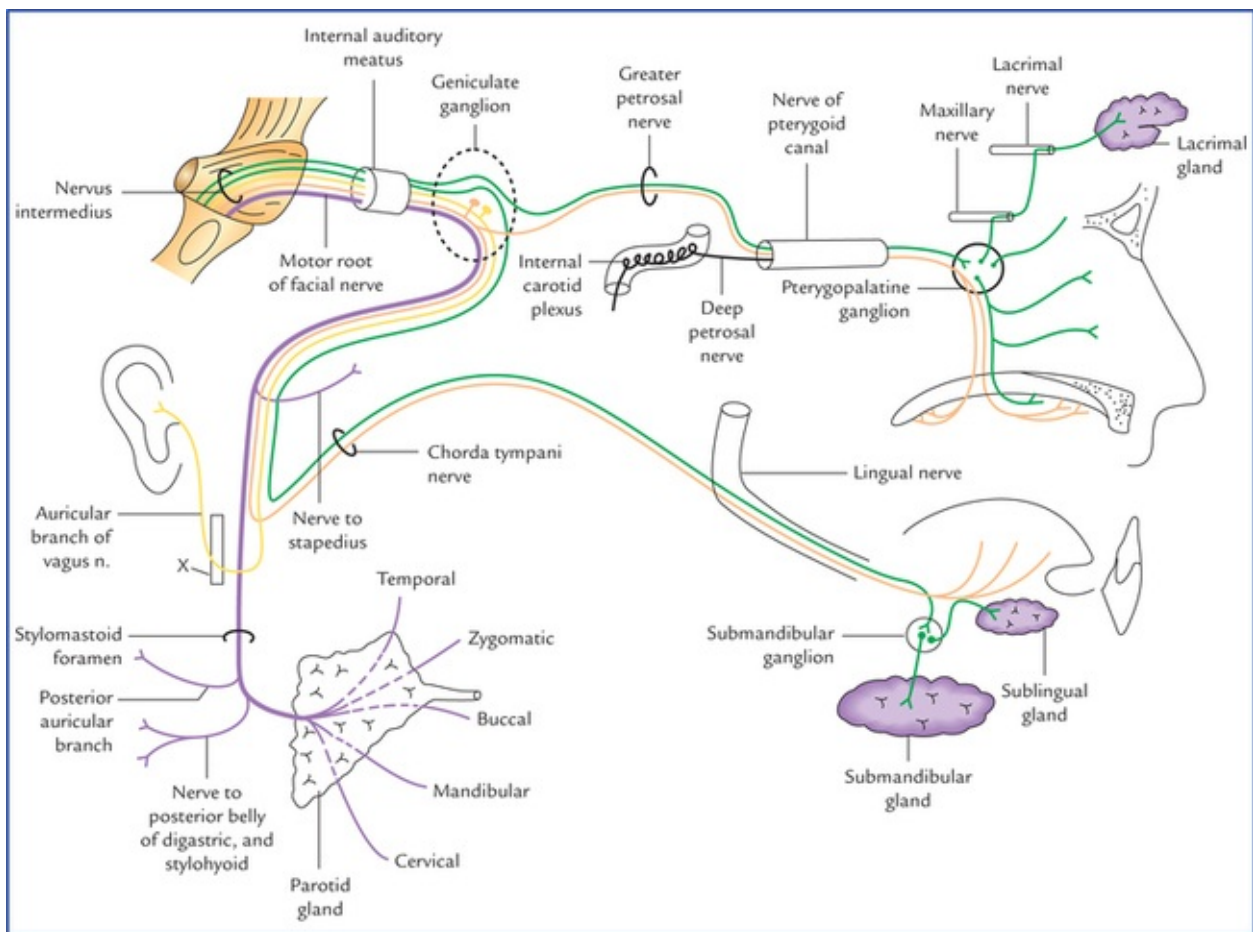


FIG. 9.11 The course and distribution of the facial nerve.

- **Greater petrosal nerve**, which is joined by deep petrosal nerve to form nerve of pterygoid canal. It provides secretomotor supply to lacrimal, nasal and palatal glands.
- **Nerve to stapedius.**
- **Chorda tympani nerve**, which joins lingual nerve. It carry taste fibres from anterior two-third of the tongue and provides preganglion fibres to the submandibular ganglion.
- **Posterior auricular nerve** to supply occipitalis and posterior auricular muscles.
- **Nerve to posterior belly of digastric and stylohyoid muscles.**
- **Terminal branches** (temporal, zygomatic, buccal, mandibular and cervical to the muscles of facial expression).

Clinical Correlation

The part of motor nucleus of facial nerve supplying the muscles of the lower part of the face receives the corticonuclear fibres from the opposite cerebral hemisphere while the part of motor nucleus of facial nerve which supplies the muscles of the upper part of the face (frontalis, orbicularis oculi) receives corticonuclear fibres from both cerebral hemispheres. As a result in supranuclear lesions (i.e. lesions involving the UMNs) of the facial nerve the upper half of the face on both sides is spared and the lower half of the face is affected on the opposite side, on the other hand in nuclear and infranuclear lesions, i.e. lower motor neuron (LMN) lesions whole of the face is affected on the side of lesion (Fig. 9.12).

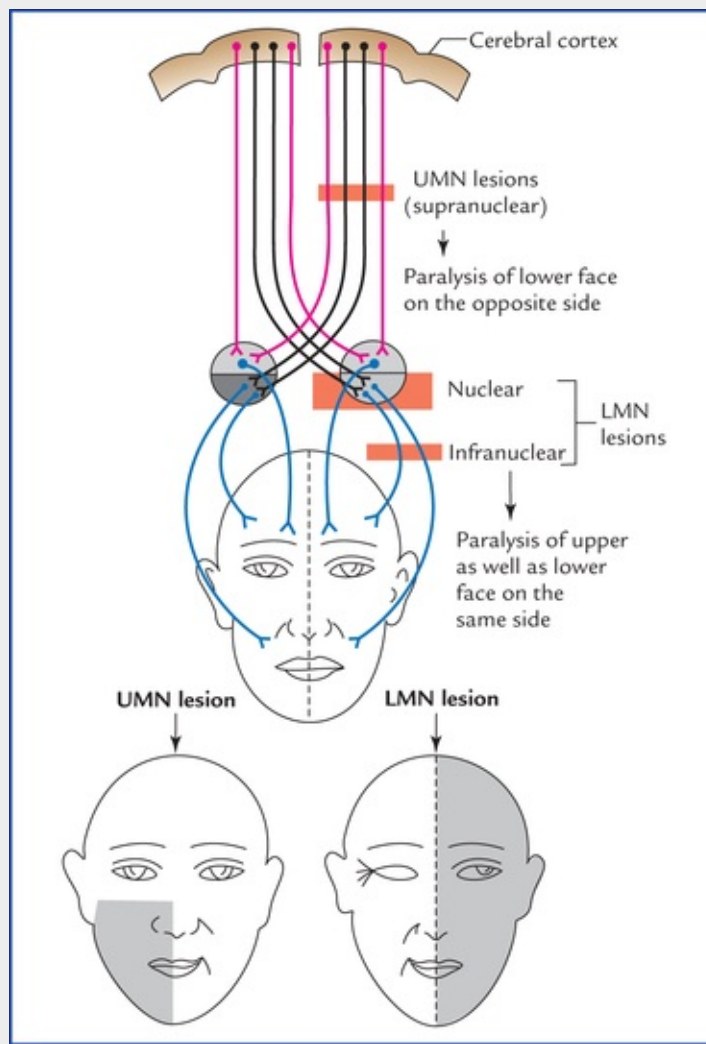


FIG. 9.12 Effects of UMN (corticonuclear fibres) and LMN (nuclear and infranuclear) lesions of the facial nerve.

N.B. That is why upper face escapes in certain hemiplegias due to the supranuclear lesions.

VIII Vestibulocochlear Nerve

Functional components

This nerve consists of two divisions: cochlear and vestibular. Both these divisions consist of **special somatic afferent (SSA) fibres**.

The fibres of the **cochlear nerve** are the central processes of bipolar neurons of the *spiral ganglion*. The peripheral processes of these cells innervate the '**organ of Corti**' (hearing receptor) in the cochlea of the inner ear.

The fibres of the **vestibular nerve** are the central processes of bipolar neurons in the *vestibular ganglion*. The peripheral processes of these neurons innervate the vestibular receptors in the semicircular ducts (for *kinetic balance*) and in the saccule and utricle (for *static balance*) of the inner ear.

Course and distribution

The vestibulocochlear nerve emerges from the lateral aspect of the pontomedullary junction, passes through the cerebellopontine angle to enter the internal acoustic meatus along with facial nerve and labyrinthine vessels, where the cochlear component—the cochlear nerve separates and pierces the fundus of the meatus in the anteroinferior quadrant. Then it runs in the cochlear modiolus where it terminates by supplying the sensory receptor of hearing the **spiral organ of corti** of membranous labyrinth.

The vestibular component—the **vestibular nerve** divides into superior and inferior division and singular nerve. They pierce the posterosuperior and posteroinferior quadrants of the fundus to innervate the sensory receptors of the equilibrium—the **maculae** and **cristae ampullaris** of membranous labyrinth.

For details, see the auditory and vestibular systems in [Chapter 18](#).

IX Glossopharyngeal Nerve

Functional components

This nerve consists of following functional components ([Fig. 9.13](#)).

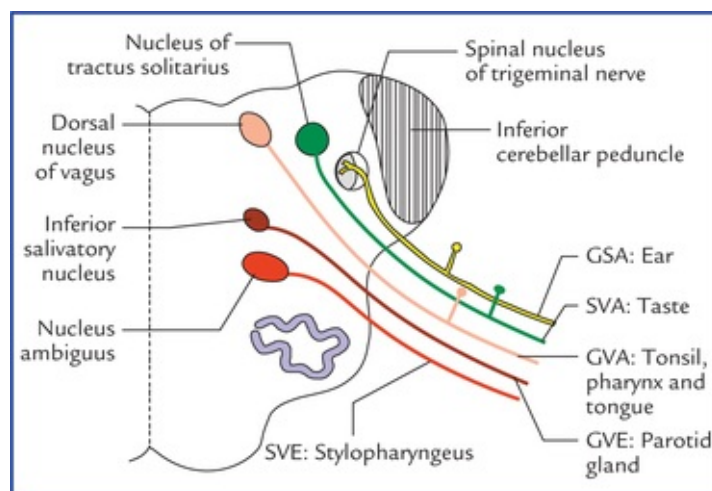


FIG. 9.13 Functional components and nuclei of the glossopharyngeal nerve.

- **Special visceral efferent (SVE) fibres** arise from nucleus ambiguus and supply only one muscle, the stylopharyngeus (the muscle of third pharyngeal arch).
- **General visceral efferent (GVE) fibres** arise from inferior salivatory nucleus and relay in the otic ganglion. The postganglionic fibres arising from ganglion supply the parotid gland via auriculotemporal nerve (a branch of mandibular nerve).
- **General visceral afferent (GVA) fibres.** The cell bodies of these fibres lie in the superior ganglion of the glossopharyngeal nerve. The peripheral processes of these cells carry general sensations (touch, pain and temperature) from posterior one-third of the tongue, pharynx, carotid body and carotid sinus to the ganglion. The central processes carry these sensations to the spinal nucleus of the trigeminal nerve.
- **Special visceral afferent (SVA) fibres** have their cell bodies in the *inferior ganglion of the glossopharyngeal nerve*. The peripheral processes of these cells carry taste sensations from the posterior one-third of the tongue and circumvallate papillae to the ganglion. The central processes convey these impulses to the *nucleus of tractus solitarius*.

Course and distribution (Fig. 9.14)

The glossopharyngeal nerve arise from the upper part of the lateral aspect of the medulla posterior to the olive, as three or four rootlets. The rootlets soon fuse to form a single nerve trunk which passes anterolaterally to leave the cranial cavity through the anterior compartment of the jugular foramen. The nerve passes two ganglia—a smaller superior and a larger inferior ganglion as it passes through the jugular foramen. The nerve passes downwards and forwards between the internal carotid artery and internal jugular vein. Then it runs inferolaterally looping around the lateral aspect of the stylopharyngeus which it supplies. Now it runs deep to hyoglossus to terminate into lingual branches.

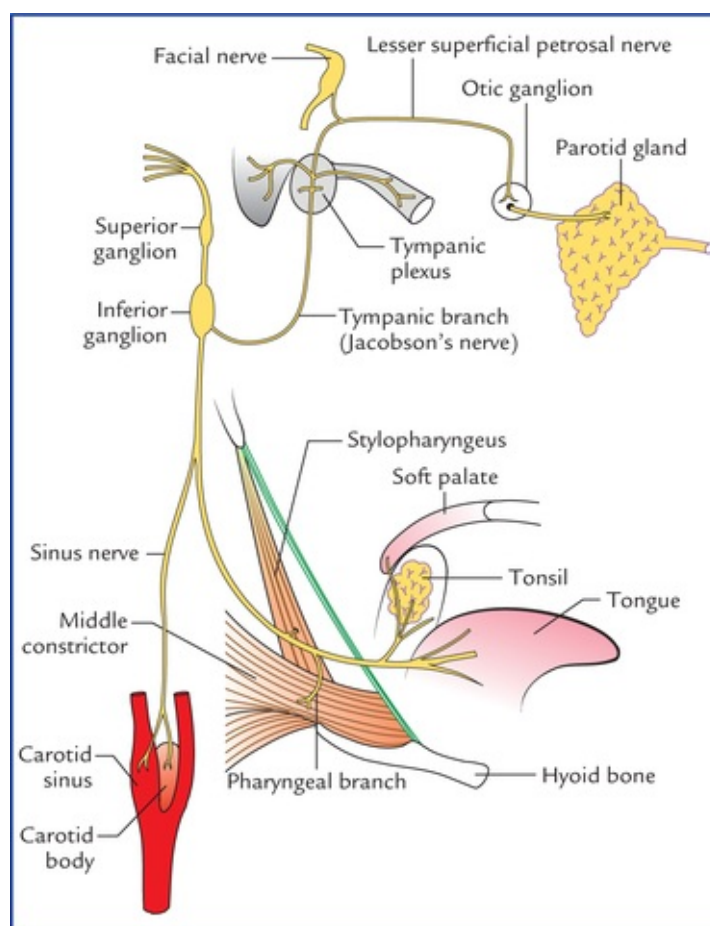


FIG. 9.14 Course and distribution of the glossopharyngeal nerve.

The branches of glossopharyngeal nerve are:

- **Tympanic branch** (Jacobson's nerve), which supplies sensory fibres via the tympanic tube. Its secretomotor fibres run through lesser petrosal nerve to the otic ganglion when they synapse. The postganglionic fibres from ganglion supplies parotid gland via auriculotemporal nerve.
- **Carotid nerve**, to carotid sinus and body. It carries sensory fibres from these structures.
- **Pharyngeal branch**, takes part in the formation of pharyngeal plexus.
- **Nerve to stylopharyngeus**, provides motor supply to this muscle.
- **Tonsillar branches**, supply mucous membrane of tonsil, fauces and palate.
- **Lingual branches**, supply posterior one-third of tongue including vallate papillae and carry taste and general sensations.

Clinical Correlation

Lesions of glossopharyngeal nerve produce following clinical features:

- Loss of gag-reflex, due to interruption of the afferent limb.
- Loss of general sensations in pharynx, tonsils, fauces and posterior one-third of tongue.
- Loss of taste sensations from posterior one-third of the tongue.
- Hypersensitive carotid sinus syndrome (syncope).

X Vagus Nerve

Functional components

The functional components of this nerve are as follows (Fig. 9.15):

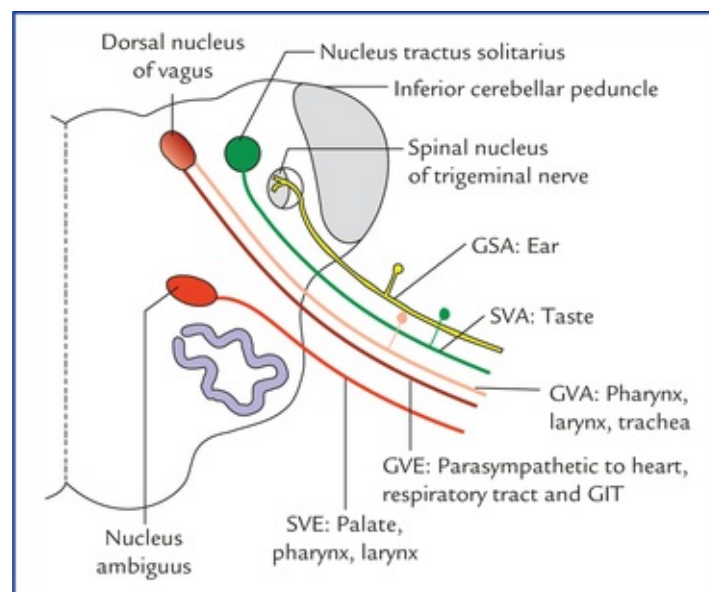


FIG. 9.15 Functional components and nuclei of the vagus nerve.

- **Special visceral efferent (SVE) fibres** arise from *nucleus ambiguus* and supply the muscles of pharynx and larynx.
- **General visceral efferent (GVE) fibres** arise from *dorsal nucleus of vagus* as preganglionic parasympathetic fibres. They supply heart, lungs, GIT up to the junction of right two-third and left one-third of the transverse colon through postganglionic fibres which arise from *small ganglia situated close to or within the walls of the viscera*.
- **General visceral afferent (GVA) fibres.** The cell bodies of these fibres are located in the *inferior ganglion of the vagus nerve*. The peripheral processes of these cells carry sensations from the pharynx, larynx, trachea, oesophagus and from the thoracic and abdominal viscera to the ganglion, from where they are conveyed to the *dorsal nucleus of vagus* and *nucleus of tractus solitarius* through central processes.
- **Special visceral afferent (SVA) fibres.** The cell bodies of these fibres lie in the *inferior ganglion of the vagus nerve*. The peripheral processes of these cells carry taste sensations from the posteriormost

part of the tongue and epiglottis to the ganglion. The central processes of the ganglion cells terminate in the *upper part of the nucleus tractus solitarius*.

- **General somatic afferent (GSA) fibres.** The cell bodies of these fibres are located in the *superior ganglion of the vagus nerve*. The peripheral processes of these neurons innervate the skin of the external ear and central processes terminate in the *spinal nucleus of the trigeminal nerve*.

Course and distribution (Fig. 9.16)

The vagus nerve arises from the lateral aspect of the medulla as a series of rootlets posterior to the olive between glossopharyngeal and cranial accessory rootlets. The rootlets unite to form a single nerve that leaves the cranial cavity through the intermediate compartment of the jugular foramen. Below the foramen it possesses two ganglia, a smaller superior ganglion and a larger inferior ganglion. The cranial root of accessory joins the vagus nerve just below the inferior jugular vein. The nerve passes vertically downwards within the carotid sheath lying between internal carotid artery and internal jugular vein. At the root of the neck on right side it enters the thorax by crossing in front of the right subclavian artery and on the left side by passing between the left common carotid and left subclavian arteries.

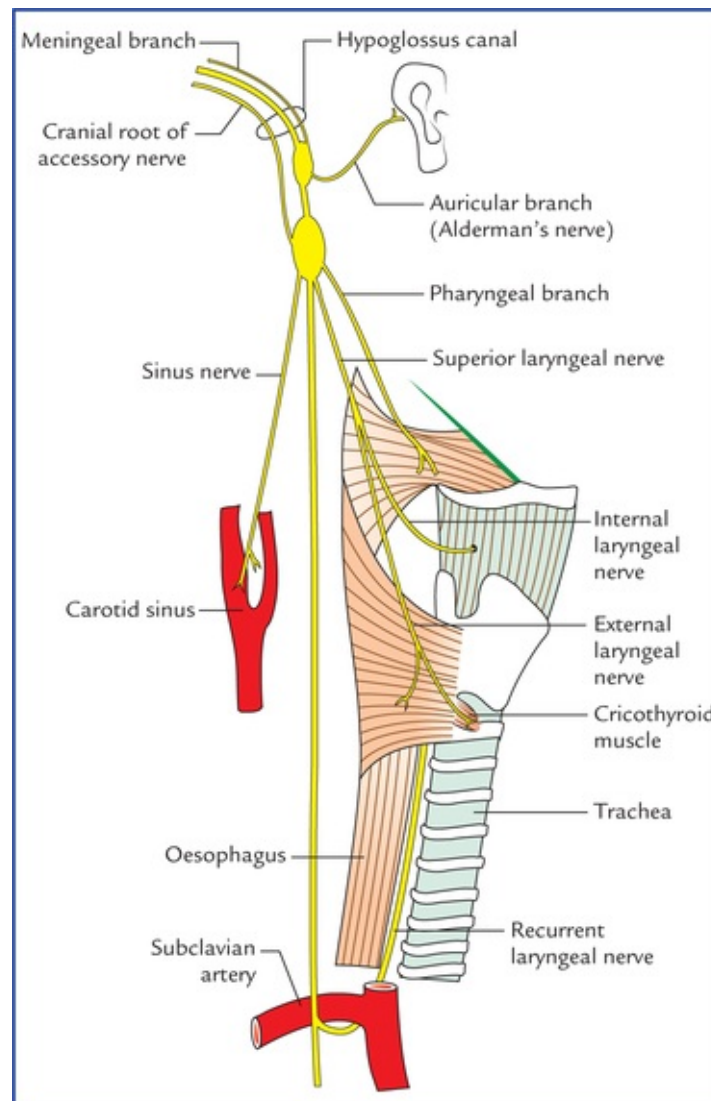


FIG. 9.16 Course and distribution of the vagus nerve.

1. *Meningeal branch*, to supply the dura mater of the posterior cranial fossa.

2. *Sinus nerve*, to carotid sinus and body.
3. *Auricular branch* to supply the exterior of tympanic membrane, the posterior wall of external auditory meatus and cranial surface of the auricle.

Clinical Correlation

Lesions of the vagus nerve produce following clinical features:

- Ipsilateral paralysis of the soft palate leading to sagging of palatal arch. The uvula deviates towards opposite, healthy side.
- Loss of the gag-reflex due to interruption of the efferent limb.
- Unilateral loss of cough-reflex due to anaesthesia of pharynx and larynx.
- Hoarseness of the voice due to unilateral paralysis of laryngeal muscles.

XI Accessory Nerve

Functional components

The functional components of this nerve (Fig. 9.17) as follows:

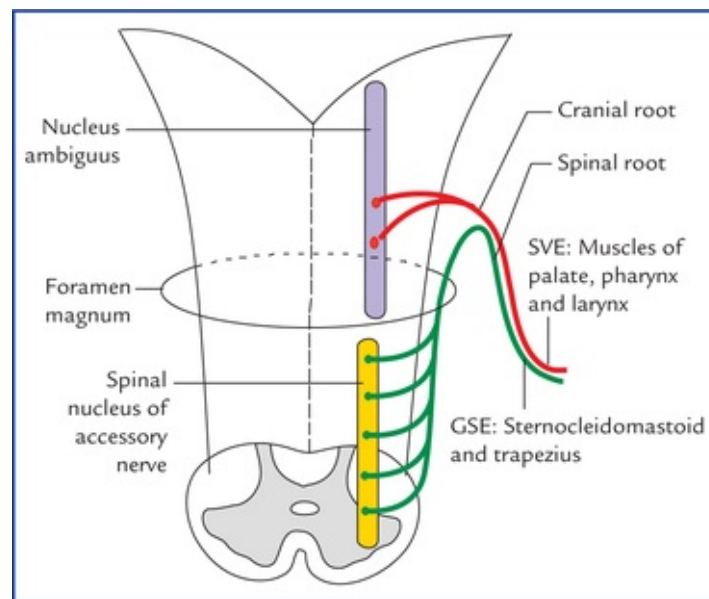


FIG. 9.17 Functional components and nuclei of the accessory nerve.

- **Special visceral efferent (SVE) fibres** form the *cranial root of the accessory nerve*. They arise from nucleus ambiguus and are distributed through the vagus nerve to supply:
 - all the muscles of palate except tensor palati which is supplied by the mandibular nerve through nerve to medial pterygoid,
 - all the muscles of pharynx except stylopharyngeus which is supplied by the glossopharyngeal nerve, and
 - all the muscles of larynx.

- **General somatic efferent (GSE) fibres** form the *spinal root of accessory nerve*. They arise from elongated column of cells (*spinal nucleus of accessory nerve*) whose cell bodies lie in the lateral part of the anterior grey column of the upper five cervical spinal segments. These fibres supply trapezius and sternocleidomastoid muscles.

Course and distribution (Fig. 9.18)

The **cranial root** emerges from medulla as 4 to 6 rootlets posterior to olive immediately below to these of the vagus nerve. They soon fuse to form a single nerve. It passes out of posterior cranial fossa through the middle compartment of the jugular foramen. Below the foramen it fuses through this nerve.

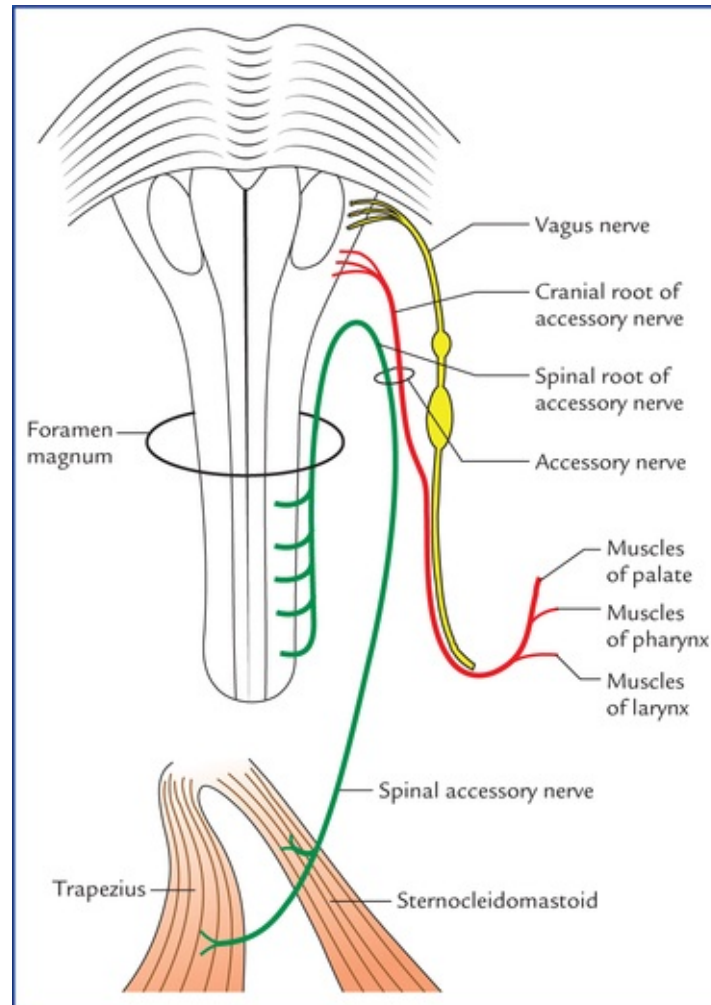


FIG. 9.18 Course and distribution of the accessory nerve.

The **spinal root** arises by a series of rootlets from the lateral aspect of the upper five cranial segments, between the dorsal and ventral roots of the spinal nerves. These rootlets unite to form a single nerve which ascends up posterior to ligamenta denticulate and enters the cranial cavity through the foramen magnum behind the vertebral artery. It briefly adheres to the cranial root as it leaves through the jugular foramen. Leave the cranial root descends posterolaterally usually posterior to internal jugular vein, crosses over the lateral mass of the atlas (C1) to enter the deep surface of the sternocleidomastoid. It then emerges from the middle of the posterior border of sternocleidomastoid, crosses the posterior triangle to enter the trapezius about 5 cm above the clavicle where it terminates.

N.B. The motor neurons to sternocleidomastoid and trapezius muscles differentiate in the embryo near the cells that are destined to form the nucleus ambiguus but migrate into the spinal cord (segments C1 to C5) and take up position in the lateral part of the anterior grey horn forming spinal nucleus of accessory nerve, in line with the nucleus ambiguus. Therefore, spinal root is also said to consist of special visceral (branchial) efferent fibres.

Clinical Correlation

The unilateral peripheral lesions of spinal root (**spinal accessory nerve**) lead to paralysis of sternocleido-mastoid and trapezius muscles.

- The paralysis of sternocleidomastoid will result in turning of the face towards the same side and bending of the head to the opposite side due to unopposed action of opposite healthy muscle.
- The paralysis of trapezius results in drooping of the shoulder and inability to shrug the shoulder towards the side of injury.

XII Hypoglossal Nerve

Functional components (Fig. 9.19)

Hypoglossal nerve consists of **general somatic efferent (GSE) fibres** which take origin from the hypoglossal nucleus (Fig. 9.19) and supply all the intrinsic and extrinsic muscles of the tongue except the palatoglossus which is supplied by the cranial root of the accessory via vagus nerve.

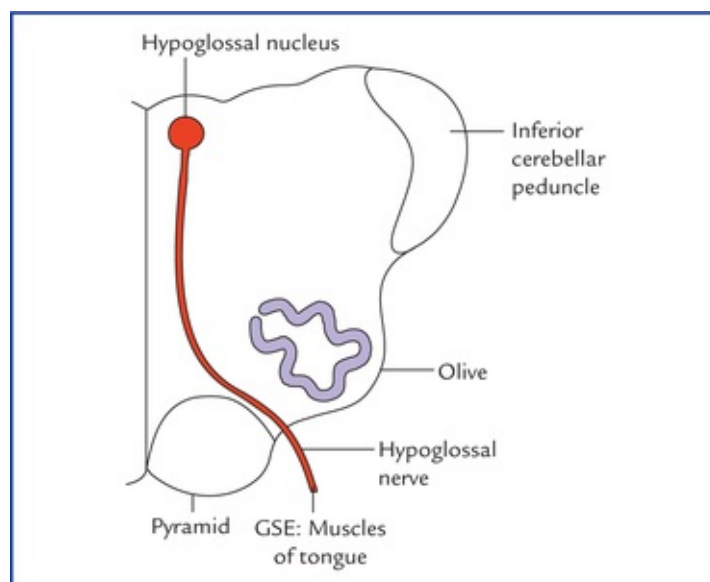


FIG. 9.19 The functional component and nucleus of the hypo-glossal nerve.

Course and distribution (Fig. 9.20)

The hypoglossal nerve arises from anterolateral aspect of the medulla between olive and pyramid as a

series of 10 to 15 rootlets. The rootlets soon fuse to form two roots which enter the hypoglossal canal, where they themselves fuse to form a single nerve and comes out of cranial cavity through this foramen laterally behind the vagus and glos-sopharyngeal nerves, passing forwards between the internal jugular vein and the internal carotid artery. Finally it runs forward superficial to internal and external carotid arteries and loop of lingual artery to reach above the hyoid bone. Here it supplies all the intrinsic and extrinsic muscles of the tongue except palatoglossus.

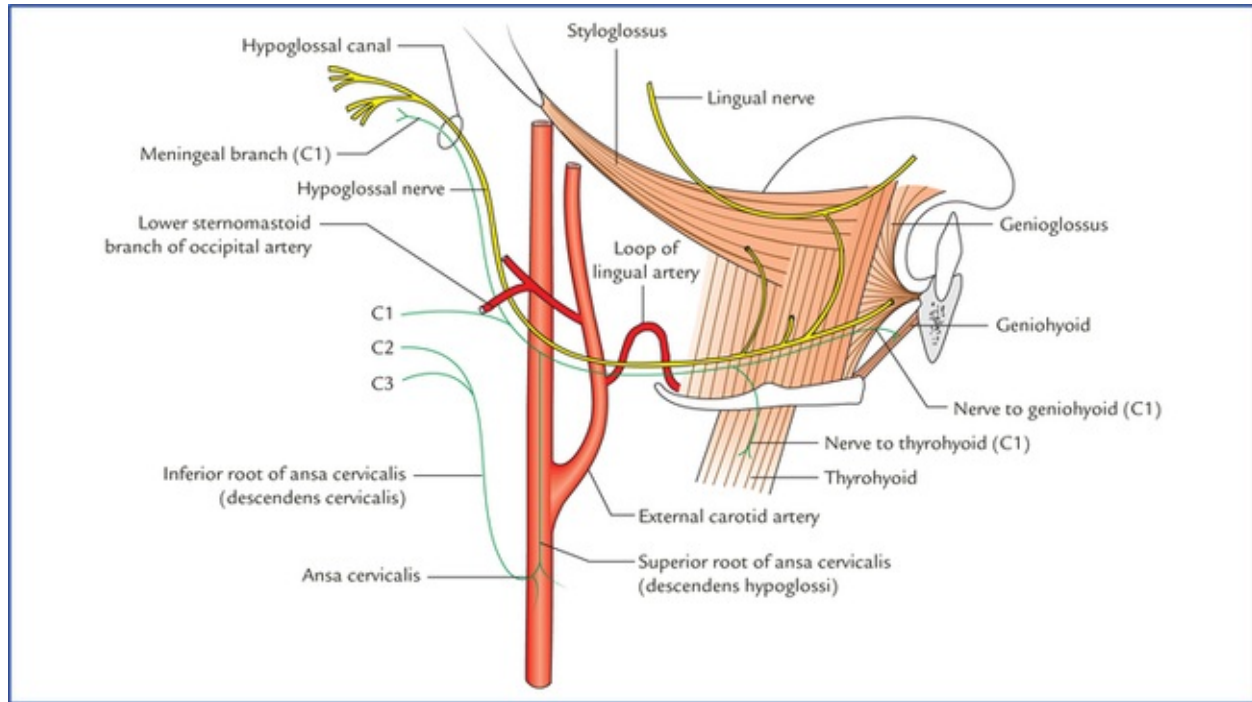


FIG. 9.20 Course and distribution of the hypoglossal nerve.

It is joined by a communication from the anterior primary ramus of C1 spinal nerve, the fibres of which the hypo-glossal nerve distributes to the geniohyoid and thyrohyoid muscles. The descending C1 fibres constitute the superior root of the ansa cervicalis (of the C2 and C3 fibres constitute the inferior root of the ansa cervicalis).

Clinical Correlation

• Upper motor neuron lesions of the hypoglossal nerve

Since the hypoglossal nucleus receives corticonuclear fibres only from the contralateral hemisphere, the supranuclear (UMN) lesions cause weakness of the opposite half of the tongue, and on protrusion, the tongue deviates to the side opposite to that of lesion.

- **Lower motor neuron (nuclear and infranuclear) Lesions of the hypoglossal nerve** result in paralysis of the ipsilateral half of the tongue and on protrusion the tongue deviates towards the side of lesion due to unopposed action of genioglossus of the healthy side.

The functional components, associated nuclei, distribution and functions of cranial nerves are

summarized in [Table 9.4](#).

Table 9.4

Functional components, nuclei, distribution and functions of cranial nerves

Cranial nerve	Functional components	Nuclei	Distribution	Functions
I	SSA	–	Olfactory epithelium	Smell
II	SSA	–	Retina of eyeball	Sight (vision)
III	SE	Oculomotor nucleus	All extrinsic muscles of eyeball except lateral rectus and superior oblique	Movements of eyeball
	GVE	Edinger-Westphal n.	Sphincter pupillae and ciliary muscle	Constriction of pupil and accommodation
IV	SE	Trochlear nucleus	Superior oblique muscle of eyeball	Movement of eyeball
V	SVE	Motor nucleus	Muscles of mastication	Movements of mandible
	GSA	(a) Chief sensory n.	Skin of face and mucous membrane of mouth and nose	Touch
		(b) Spinal nucleus	Skin of face and mucous membrane of mouth and nose	Pain and temperature
		(c) Mesencephalic nucleus	Muscles of mastication	Proprioceptive sensations
VI	SE	Abducent nucleus	Lateral rectus of eyeball	Abduction of eyeball
VII	GVE	Superior salivatory nucleus	Submandibular and sublingual salivary glands	Secretomotor
	SVE	Motor nucleus	Muscles of facial expression stylohyoid, posterior belly of digastric, platysma and stapedius	Facial expressions, elevation of hyoid, etc.
	SVA	Nucleus of tractus solitarius	Taste buds in the anterior 2/3rd of tongue except vallate papillae	Taste sensations from anterior 2/3rd of tongue except vallate papillae
	GSA	Spinal nucleus of Vth nerve	Part of skin of external ear	Exteroceptive sensations
VIII	SSA	Cochlear nuclei	Organ of corti in the cochlea of internal ear	Hearing
		Vestibular nuclei	Vestibular receptors in the semicircular ducts, utricle and saccule of internal ear	Equilibrium and balance

IX	SVE	Nucleus ambiguus	Stylopharyngeus muscle	Elevation of larynx
	GVE	Inferior salivatory nucleus	Parotid gland	Secretomotor
	GVA	Nucleus tractus solitarius (lower part)	Pharynx, posterior 1/3rd of tongue	Touch, pain and temperature from pharynx and posterior 1/3rd of tongue
	SVA	Nucleus tractus solitarius (upper part)	Taste buds in posterior 1/3rd of tongue and vallate papillae	Taste sensations from posterior 1/3rd of tongue and vallate papillae
X	SVE	Nucleus ambiguus	Muscles of palate, pharynx and larynx	Movements of palate, pharynx and larynx
	GVE	Dorsal nucleus of vagus	Smooth muscles and glands of thoracic and abdominal viscera	Motor and secretomotor to bronchial tree and gut; inhibitory to heart
	GVA	Nucleus tractus solitarius	Thoracic and abdominal viscera	General sensations from thoracic and abdominal viscera
	SVA	Nucleus tractus solitarius	Taste buds in posteriormost part of tongue and epiglottis	Taste sensations from posteriormost part of tongue and epiglottis
	GSA	Spinal nucleus of Vth nerve	Part of skin of external ear	General sensations from skin of external ear
XI	SVE	Nucleus ambiguus	Muscles of palate, pharynx and larynx	Movements of palate, pharynx and larynx
	GSE	Spinal nucleus of accessory nerve (anterior grey column of upper 5 cervical spinal segments)	Trapezius and sternocleidomastoid muscles	Movements of head and shoulder
XII	SE	Hypoglossal nucleus	All intrinsic and extrinsic muscles of tongue except palatoglossus	Movements of tongue

SE = somatic efferent, SVE = special visceral efferent, GVE = general visceral efferent, GVA = general visceral afferent, SVA = special visceral afferent, GSA = general somatic afferent, SSA = special somatic afferent.

Cortical Control of Cranial Nerves

All the motor cranial nerve nuclei are under the control of cerebral cortex through the corticonuclear fibres. Each nucleus is controlled by both the cerebral hemispheres with following exceptions:

- Part of **hypoglossal nucleus** innervating genioglossus is controlled by opposite cerebral cortex only.
- Part of **facial nerve nucleus** supplying lower part of the face is controlled by opposite cerebral cortex only.
- The **trochlear nerve nucleus** is controlled by the cerebral cortex of the same side only.

Reflexes Mediated by Cranial Nerves

The important reflexes mediated by cranial nerve/nerves as follows:

Corneal reflex: When cornea is touched with cotton wool, the person blinks due to contraction of palpebral part of orbicularis oculi.

Conjunctival reflex: When conjunctiva is touched with cotton wool the eye is closed rapidly due to contraction of orbicularis oculi.

Lacrimation reflex: Irritation of conjunctiva and cornea results in reflex lacrimation.

Oculocardiac reflex: Pressure on the eyeball slows the heart rate (bradycardia).

Gag reflex: Tickling of the oropharynx either with finger or with swab stick results in reflex contraction of pharyngeal muscles, causing gagging and retching.

Carotid sinus reflex: Pressure on carotid sinus slows heart rate (bradycardia).

Sneezing reflex: When nasal mucosa is irritated, after a sharp inhalation, explosive exhalation occurs with closure of the oropharyngeal-isthmus by the action of palatoglossus, which diverts air through nasal cavity and thus expels the irritant.

Jaw jerk: If the muscles that closes the jaw (masseter, medial pterygoid and temporalis) are rapidly stretched, the jaw is reflexly closed.

The afferent and efferent limbs of these reflexes are summarized in the [Table 9.5](#).

Table 9.5

Important cranial nerve reflexes

Reflex	Afferent limb	Efferent limb
Corneal reflex	Ophthalmic nerve	Facial nerve
Conjunctival reflex	Ophthalmic nerve	Facial nerve
Lacrimation (tearing) reflex	Ophthalmic nerve	Facial nerve
Oculocardiac reflex	Ophthalmic nerve	Vagus nerve
Gag reflex	Glossopharyngeal nerve	Vagus nerve
Carotid sinus reflex	Glossopharyngeal nerve	Vagus nerve
Sneezing reflex	Ophthalmic/maxillary nerve	Vagus nerve
Jaw-jerk (masseteric) reflexes*	Mandibular nerve	Mandibular nerve
Pupillary reflexes (Refer to Chapter 18)		
– Light reflex		
– Accommodation reflex		

***Jaw-jerk reflex** is the only **monosynaptic reflex** mediated by the cranial nerves.

Clinical Problems

1. A 50-year-old patient complained of double vision. On physical examination, the ophthalmologist found that his right eye, when at rest, was turned medially and when he was asked to turn it laterally, he failed to do so. Identify which cranial nerve is involved and also explain what is **double vision** and discuss, how it occurs.
2. Explain ‘**internal** and **external ophthalmoplegias**’ in relation to the third nerve lesions?
3. Explain, why in upper motor neuron type of facial palsy, the muscles of the upper part of the face are spared.
4. When a physician presses the tongue with a spatula to examine oropharynx, the patient often gags. Give its anatomical basis.
5. In upper motor neuron lesions of the hypoglossal nerve the tongue deviates towards the opposite side while in case of lower motor neuron lesions the tongue deviates towards the side of the lesion. Why?

Clinical Problem Solving

1. The patient is suffering from **medial squint** (also called **medial strabismus**) in the right

eye due to lesion of *right abducent nerve* (see [page 99](#)). In double vision (diplopia) the patient sees two images of the same object. The mechanism is as follows:

When the eyes look at an object, the image of an object falls on the macula of the retina of the both eyes. If there is faulty movement of one eye, the image of object will fall on the peripheral part of the retina of that eye. As a result two images will be seen, one **true image** located on the macula of the normal eye and the second **false image** seen by the peripheral retina of the abnormal eye.

2. The incomplete lesions of oculomotor nerve are common and may spare either the extraocular muscles or the intraocular muscles.

The oculomotor nerve consists of somatic motor fibres which supply extraocular muscles and parasympathetic motor fibres which supply intraocular muscles.

The parasympathetic autonomic fibres are superficially placed within the oculomotor nerve and are likely to be first affected by compression, viz. lateral tentorial herniation, resulting into internal ophthalmoplegia.

In diabetic neuropathy with impaired nerve conduction, the autonomic fibres remain unaffected whereas the somatic motor fibres are affected producing external ophthalmoplegia.

3. See Clinical correlation on [page 103](#).

4. When physician presses the tongue with spatula, the sensory receptors in the mucous membrane of the oropharynx are stimulated producing *gag-reflex*. The afferent impulses of the reflex run through the glosso-pharyngeal nerve, and the efferent impulses travel through the glossopharyngeal and vagus nerves to the muscles pharynx.

5. See Clinical correlation on [page 109](#).

Cerebellum and Fourth Ventricle

Cerebellum

The cerebellum (L. *cerebellum* = *little brain*) is the largest part of the hindbrain and second largest part of the brain as a whole. It weighs about 150 g. It is located in the posterior cranial fossa underneath the tentorium cerebelli and behind the pons and medulla oblongata. It is separated from the pons and medulla by a cavity of the fourth ventricle (Fig. 10.1). Its surface bears numerous fissures separating narrow folia which are mostly transverse.

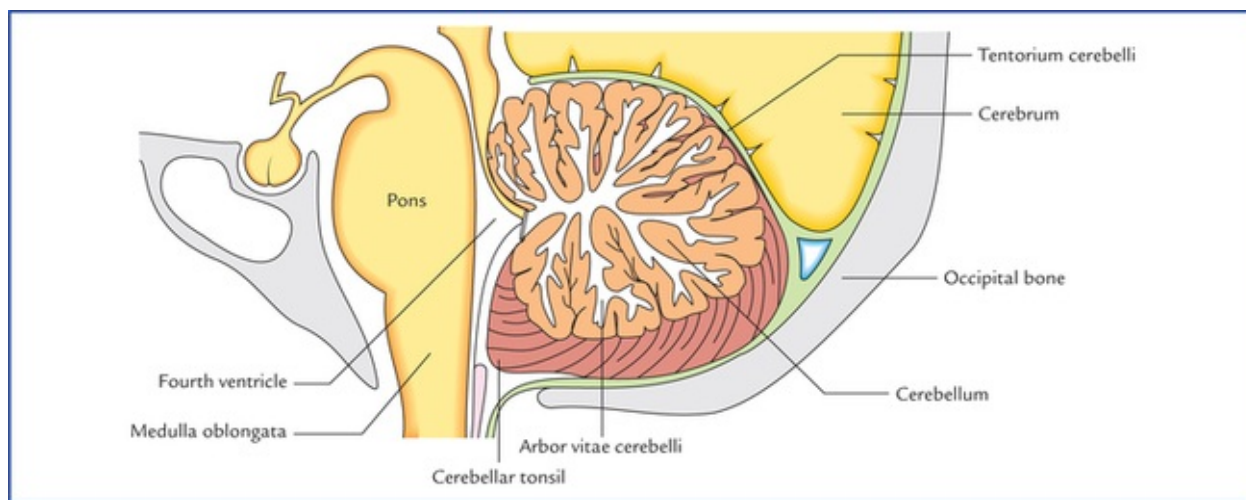


FIG. 10.1 Median sagittal section through brainstem and cerebellum.

The cerebellum is connected to the brainstem by these three pairs of large fibre tracts called cerebellar peduncles.

The three primary functions of the cerebellum are:

1. Maintenance of posture.
2. Maintenance of muscle tone.
3. Coordination of voluntary motor activity.

In addition to above, it also adjusts coordination of skilful volitional movements by perfect timing among the contracting groups of agonist and antagonist muscles. This is achieved through the use of somatic sensory information (proprioceptive sensations from muscles and joints) in modulating the motor output from the cerebrum and brainstem (see comparator function of cerebellum on [page 119](#)). Sherrington regarded the cerebellum as the head ganglion of the proprioceptive system.

The cerebellar disease manifests the following triad of motor dysfunctions:

- **Dysequilibrium**, i.e. loss of balance characterized by gait and trunkal ataxia.
- **Hypotonia**, i.e. loss of the resistance normally offered by muscles on palpation.
- **Dyssynergia**, i.e. loss of coordinated muscular activity.

External Features

The external features of the cerebellum comprise three parts, two surfaces, two notches, and three well-marked fissures (Figs 10.2–10.4).

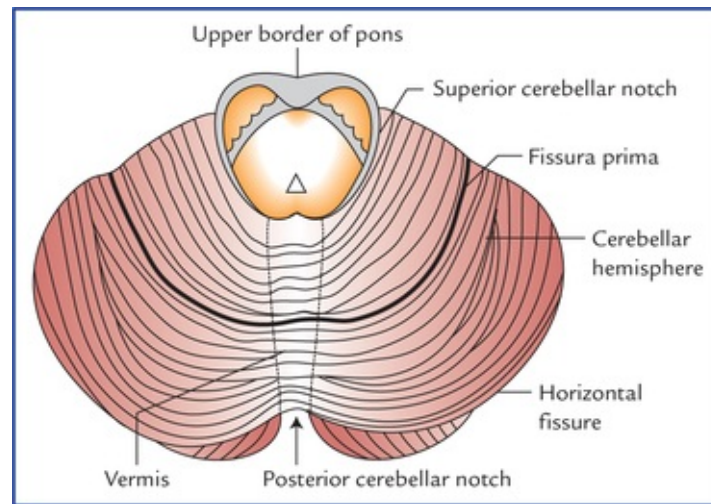


FIG. 10.2 Superior view of the cerebellum. Note the presence of fissures and folia on the surface of the cerebellum.

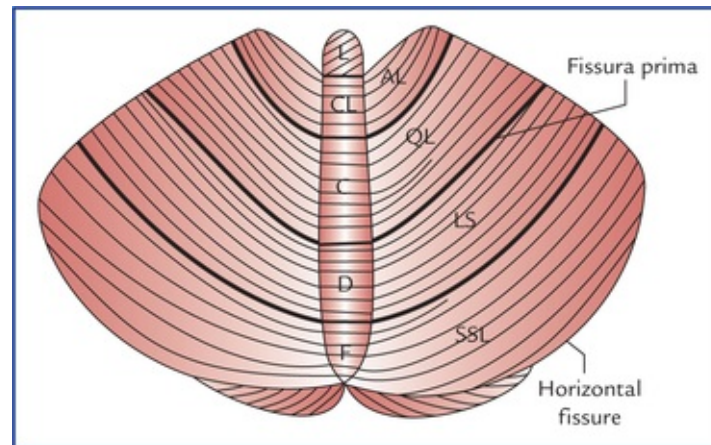


FIG. 10.3 Schematic diagram to show the various subdivisions of the cerebellum as seen on the superior surface. (L = lingula, CL = central lobule, C = culmen, D = declive, F = folium, AL = ala, QL = quadrate lobule, LS = lobulus simplex, SSL = superior semilunar lobule.)

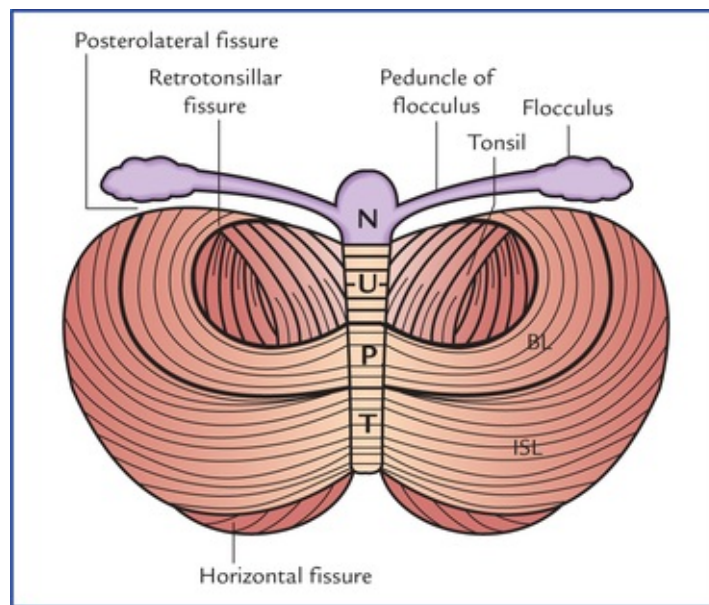


FIG. 10.4 Schematic diagram to show the various subdivisions of the cerebellum as seen on the inferior surface. (N = nodule, U = uvula, P = pyramid, T = tuber, BI = biventral lobule, ISL = inferior semilunar lobule.)

Parts

The cerebellum consists of two large lateral hemispherical lobes, the **cerebellar hemispheres** which are united to each other by a narrow median worm-like portion, called **vermis**. The superior and inferior aspects of vermis are termed **superior** and **inferior vermis** respectively. The ridge-like superior vermis is continuous on either side with the superior surface of cerebellar hemisphere imperceptibly. The inferior vermis is more clearly demarcated from the hemispheres in the floor of **vallecula cerebelli**.

Surfaces

The **superior surface** of the cerebellum is convex. The two cerebellar hemispheres are continuous with each other on this surface. The **inferior surface** presents a deep median notch called *vallecula* which separates the two cerebellar hemispheres. The floor of the vallecula is formed by inferior vermis and is limited on each side by *sulcus valleculae*.

Notches

The anterior aspect of cerebellum is marked by a wide shallow **anterior cerebellar notch** which accommodates pons and medulla. The **posterior cerebellar notch** is deep and narrow, and lodges the falx cerebelli.

Fissures

- The **horizontal fissure** is most conspicuous and runs along the lateral and posterior margins of the cerebellum. It marks the junction between the superior and inferior surfaces of the cerebellum.
- The **posterolateral fissure** lies on the inferior surface of the cerebellum and separates the *flocculonodular lobe* from the rest of the cerebellum (*corpus cerebelli*).
- The V-shaped **fissura prima** on the superior surface cuts the superior vermis at the junction of its anterior two-third and posterior one-third. It divides the corpus cerebelli into *anterior* and *posterior (middle) lobes*.

N.B. There are several other fissures which subdivide the vermis and cerebellar hemispheres into lobules and given fanciful names (Table 10.1).

Table 10.1

Various subdivisions (lobules) of vermis and cerebellar hemisphere

Lobes	Subdivisions of vermis	Subdivisions of cerebellar hemisphere
Anterior lobe	Lingula Central lobule Culmen	No lateral projection Alae Quadrangular lobule
Posterior lobe	Declive Folium Tuber Pyramid Uvula	Lobulus simplex Superior semilunar lobule Inferior semilunar lobule Biventral lobule Tonsil
Flocculonodular lobe	Nodule	Flocculus

It is advisable for the student not to burden his memory with all these names, and should remember only those which have a functional or descriptive value.

Subdivisions of Cerebellum

Anatomical subdivisions

Anatomically the cerebellum is divided into three lobes (Fig. 10.5), viz. anterior, posterior and flocculonodular.

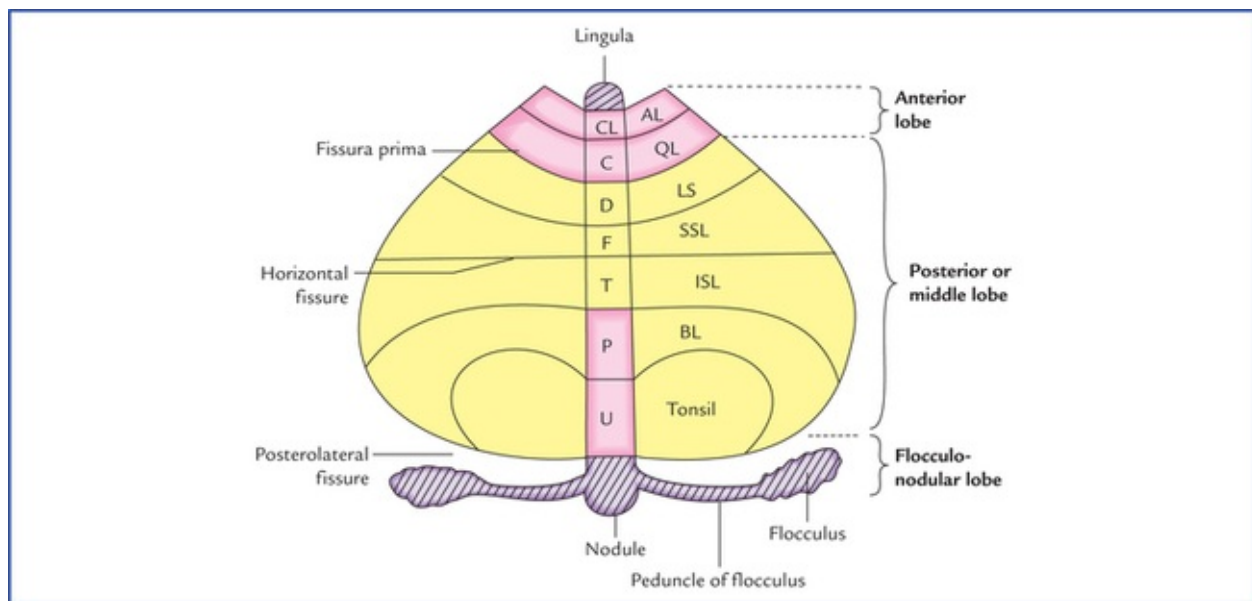


FIG. 10.5 Morphological and functional subdivisions of the cerebellum. The organ is being opened out (schematically) to show both superior and inferior surfaces together. The parts seen above the horizontal fissure form the superior surface and those below the fissure inferior surface of the cerebellum. (CL = culmen, C = central lobule, D = declive, F = folium, T = tuber, P = pyramid, U = uvula, AL = ala, QL = quadrate lobule, LS = lobulus simplex, SSL = superior semilunar lobule, ISL = inferior semilunar lobule, BL = biventral lobule.)

- The **anterior lobe** lies on the superior surface anterior to the fissura prima.

- The **posterior/middle lobe** lies between the fissure prima on the superior surface and posterolateral fissure on the inferior surface.
- The **flocculonodular lobe** is smallest of all and lies on the inferior surface in front of the posterolateral fissure.

The subdivisions (lobules) of the vermis and cerebellar hemispheres which constitute these lobes are listed in [Table 10.1](#).

Morphological subdivisions (Fig. 10.5)

Based on phylogenetic and functional criteria the cerebellum is divided into three parts, archicerebellum, paleocer-ebellum, and neocerebellum.

Archicerebellum (vestibular cerebellum)

Phylogenetically it is the oldest part of the cerebellum. The fishes and lower amphibians possess only this component of the cerebellum. It consists of flocculonodular lobe and lingula.

The archicerebellum is chiefly vestibular in connections and *concerned with the maintenance of equilibrium, tone and posture of trunk muscles.*

Paleocerebellum (spinal cerebellum)

Phylogenetically it is next part of the cerebellum to appear in terrestrial vertebrates with the appearance of limbs, *viz.* reptiles and birds. It consists of anterior lobe (except lin-gula) and pyramid and uvula of inferior vermis.

The paleocerebellum is chiefly spinocerebellar in connections and concerned with *the tone, posture and crude movements of the limbs.*

Neocerebellum (cerebral cerebellum)

Phylogenetically it is the most recent part of the cerebellum to develop. It develops in primates in association with the enlargement of the telencephalon and the cerebral cortex. It is prominent in higher mammals. It is made up of middle lobe, the largest part of the cerebellum (except the pyramid and the uvula of inferior vermis).

The neocerebellum is chiefly corticoponto-cerebellar in connections and is *concerned with smooth performance of skilled voluntary movements.*

The features of three morphological subdivisions of the cerebellum are enumerated in [Table 10.2](#).

Table 10.2

Components, nuclei, connections and functions of three morphological subdivisions of the cerebellum

Subdivisions	Components	Nucleus	Chief connections	Functions
Archicerebellum (oldest part)	Flocculonodular lobe + lingula	Nucleus fastigii	Vestibulocerebellar	Maintenance of equilibrium (responsible for maintaining the position of body in space)
Paleocerebellum (in between, i.e. neither oldest nor newest)	Whole of anterior lobe except lingula Pyramid Uvula	Nucleus interpositus consisting of nucleus globosus and nucleus emboliformis	Spinocerebellar	Controls crude movements of the limbs
Neocerebellum (most recent part)	Whole of posterior lobe except pyramid and uvula	Nucleus dentatus	Corticoponto-cerebellar	Smooth performance of highly skilled voluntary movements of precision

Internal Structure

The cerebellum is made up of a thin surface layer of grey matter, the **cerebellar cortex** and a central core of white matter. Embedded within the central core of white matter are masses of grey matter called **intracerebellar nuclei**.

The cerebellar cortex is folded in such a way that the surface of cerebellum presents a series of parallel transverse **fissures** and intervening narrow leaf-like bands called **folia**. Each folium consists of a slender branched lamina of central core of white matter covered by a thin layer of grey matter. *The central core of white matter being arranged in the form of the branching pattern of a tree, is called **arbor vitae cerebelli** (arbor vitae = tree of life).*

Grey matter

The grey matter of the cerebellum is represented by: (a) the cerebellar cortex, and (b) the intracerebellar nuclei.

Structure of cerebellar cortex (Fig. 10.6)

The structure of the cerebellar cortex is uniform throughout (homotypical).

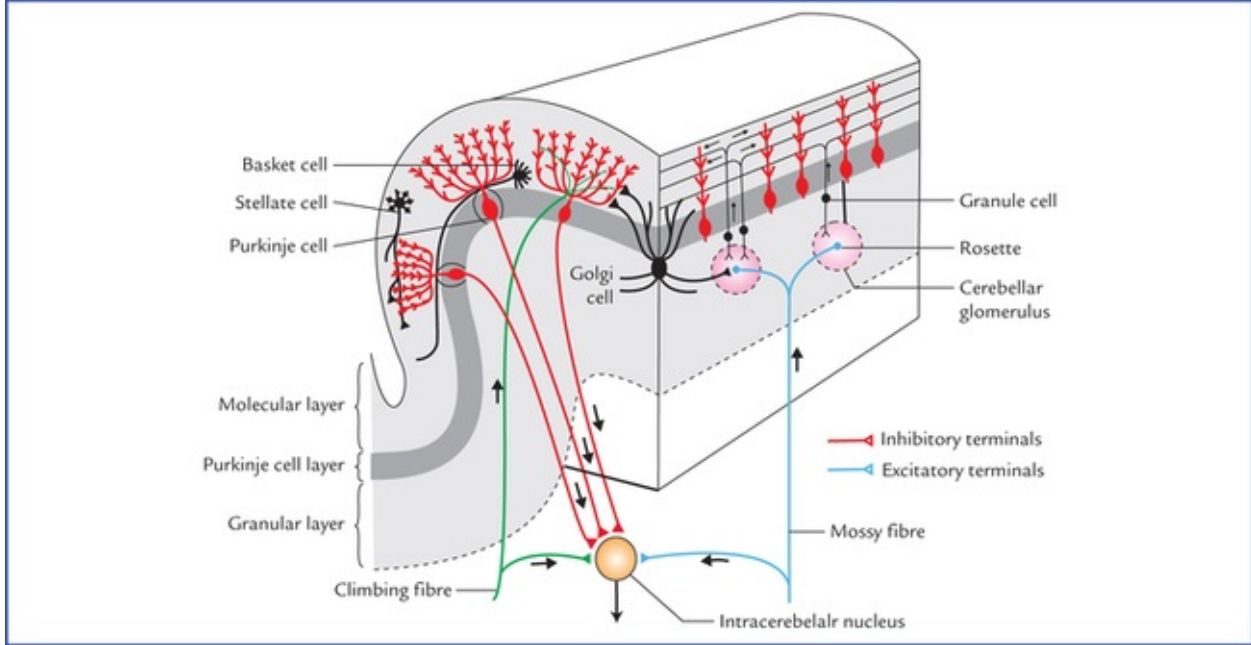


FIG. 10.6 Structure of cerebellar cortex, showing intrinsic neurons and their processes. A single folium is shown cut longitudinally (right) and transversely (left). Note that **cerebellar glomerulus** is a synaptic complex involving four types of neurites: the mossy fibre terminal, the dendrites of granule and Golgi cells, and the Golgi cell axon terminal.

Cerebellar cortex consists of three distinct layers: (a) an outer molecular layer, (b) an intermediate Purkinje cell layer, and (c) an inner granular layer.

Molecular (plexiform) layer

Molecular layer mainly consists of numerous dendritic arborizations of Purkinje cells and relatively few nerve cells which are widely spaced.

The nerve cells are of two types: (a) the basket cells, and (b) the stellate cells.

The **basket cells** are small in size with little cytoplasm and extensive processes. The longest of these processes (axon) of each cell assumes a transverse course parallel to the cortical surface and at right angle to the longitudinal axis of the folia. The transverse axons, synapse through numerous basket-like nets of collaterals with dendrites of many (about 500) Purkinje cells.

The **stellate cells** with characteristically short processes are scattered near the surface. Their axons arborise with dendritic spines of the Purkinje cells.

Purkinje cell layer

Purkinje cells layer consists of a single row of large flask-shaped cells, the **Purkinje cells**. A dendrite arises from the neck of the flask, passes upwards into the molecular layer, where it undergoes profuse branching to form an elaborate dendritic tree. The dendrites of Purkinje cells synapse with: (a) the collaterals from the basket cells, (b) the axons of the granule cells (parallel fibres), and (c) the climbing fibres. The axons of the Purkinje cells arise from their deeper poles and pass through the granular layer into the white matter, where they relay into the intracerebellar nuclei (except those from the flocculonodular lobe which pass directly to the vestibular nuclei).

The outgoing Purkinje axons constitute the sole output from the cerebellar cortex and exert an inhibitory influence on the intracerebellar nuclei.

Granular layer

The inner granular layer consists of numerous closely packed small **granule cells**. This layer also contains few large **Golgi cells**.

Each granule cell gives rise to four or five short dendrites, which make claw-like endings which synapse with the terminals of the mossy fibres. The axon of each granule cell passes into the molecular layer where it bifurcates at a T junction, and its branches run parallel to the long axis of the cerebellar folium. These fibres are known as **parallel fibres**. They run at right angle to the dendritic processes of the Purkinje cells and make synaptic contacts with them.

The Golgi cells are large and prominent but scanty. Their dendrites ramify in the molecular layer.

Intrinsic neurons of the cerebellar cortex

There are five types of intrinsic neurons in the cerebellar cortex, viz. (a) Purkinje cells, (b) granule cells, (c) stellate cells, (d) basket cells, and (e) Golgi cells.

All the intrinsic neurons of cerebellar cortex are inhibitory except granule cells. Such a collection of inhibitory neurons is not found anywhere else in the CNS except in the cerebellum.

Intracerebellar nuclei

The intracerebellar nuclei (also called central nuclei) are masses of grey matter embedded in the white matter of the cerebellum. On each side of the midline they are four in number. From lateral to medial side these are: (a) dentate nucleus, (b) emboliform nucleus, (c) globose nucleus, and (d) fastigial nucleus (Fig. 10.7).

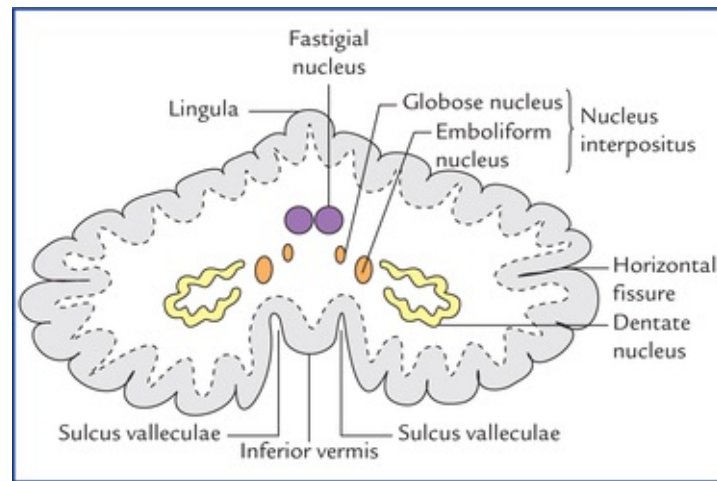


FIG. 10.7 Horizontal section of the cerebellum showing intracerebellar nuclei (also called central nuclei of the cerebellum).

The **dentate nucleus** is the most prominent of the intracerebellar nuclei and largest in primates, especially in humans. It is the nucleus of *neocerebellum* and therefore receives afferent fibres from it. In sections, it has a shape, like a crumpled-bag with its hilum facing anter-omedially. The interior of the nucleus is filled with white matter made up of efferent fibres that leave the nucleus through the hilum, forming most of the *superior cerebellar peduncle*. These fibres include *dentorubral* and *dentothalamic fibres* relaying in the red nucleus and ventral lateral nucleus of the thalamus respectively. Fibres from red nucleus and thalamus project to the spinal cord and cerebral cortex respectively.

The **emboliform nucleus** is oval in shape and situated medial to the dentate nucleus, partially covering its hilum. It is the nucleus of *paleocerebellum*, hence receives afferent fibres from it and gives fibres to the red nucleus *via superior cerebellar peduncle*. The red nucleus projects to the spinal cord through *rubrospinal tract*, which facilitates the flexor muscle tone.

The **globose nucleus** is rounded in shape and lies between the emboliform and fastigial nuclei. It has similar connections to that of emboliform nucleus. The globose and emboliform nuclei together are sometimes referred to as **nucleus interpositus**.

The **fastigial nucleus** lies near the midline in the vermis and close to the roof of the fourth ventricle. It is smaller than the dentate but larger than the emboliform or globose nuclei. It is nucleus of archi-cerebellum, hence receives afferent fibres from flocculonodular lobe (archicerebellum) and conveys efferent fibres to the vestibular and reticular nuclei. The fastigial connections influence the extensor muscle tone.

White matter

The white matter of cerebellum is made up of three types of fibres: (a) intrinsic, (b) afferent, and (c) efferent.

The **intrinsic fibres** remain confined within the cerebellum. They connect different regions of the cerebellum either in the same hemisphere or of the two cerebellar hemispheres. Through **afferent** and

efferent fibres the cerebellum is connected with the other parts of the CNS.

Connections of Cerebellum

Afferent fibres

The cerebellum receives input through afferent fibres mainly from cerebral cortex, spinal cord, and vestibular apparatus (sacculae, utricle and semicircular canals). In addition it also receives input from red nucleus and tectum of the midbrain.

The *cerebral cortex* sends information to the cerebellum, through **cortico-ponto-cerebellar**, **cerebro-olivo-cerebellar**, and **cerebro-reticulo-cerebellar pathways**.

The *spinal cord* sends subconscious proprioceptive information to the cerebellum by posterior spinocerebellar, anterior spinocerebellar, and cuneocerebellar tracts.

The spinocerebellar tracts form the major sensory input.

The afferent fibres from vestibular apparatus pass to the cerebellum either directly or after relay in the vestibular nuclei.

The afferent fibres enter the cerebellum mainly through the inferior and middle cerebellar peduncles. They are classified into two types: (a) climbing fibres, and (b) mossy fibres.

- The **climbing fibres** mostly, originate in the inferior olivary nucleus. Each fibre after giving a collateral to the intracerebellar nucleus, makes a monosynaptic contact with the Purkinje cell.
- The **mossy fibres** constitute the bulk of the afferent fibres of the cerebellum. Each mossy fibre ends by forming 30 to 40 terminal swellings called **rosette**. Each rosette forms a synaptic contacts with dendrites of granule cells and axons of few Golgi cells. The rosette and its synaptic contacts with dendrites of granule cells and axons of Golgi cells form what is called **cerebellar glomerulus** (Fig. 10.6).

Each glomerulus is surrounded by a capsule of neuroglial cells and appears spherical or ovoid in shape.

The climbing fibre synapses directly with a single Purkinje cell while mossy fibre synapses with thousands of Purkinje cells through granule cells.

(One mossy fibre synapses with several granule cells, then each granule cell synapses with thousands of Purkinje cells through parallel fibres.) Therefore, one climbing fibre specifically influences only one Purkinje cell, whereas the influence of a mossy fibre is far more diffuse. The influences of both climbing, and mossy fibres are excitatory to the Purkinje cells.

***N.B.** All the afferent fibres of the cerebellum are mossy fibres except olivocerebellar (from inferior olivary nucleus) and parolivocerebellar fibres (from accessory olivary nuclei) which are climbing fibres.*

The cerebellum receives all kinds of sensory impulses but has nothing to do with the conscious appreciation of these, a function of the cerebral cortex.

Efferent fibres

The efferent fibres from cerebellum pass to the red nucleus, thalamus, vestibular complex, and reticular formation. The entire output of the cerebellar cortex is through the axons of the Purkinje cells.

Most of the axons of Purkinje cells end by synapsing with the neurons of intracerebellar nuclei. The axons of neurons of intracerebellar nuclei in turn project to the other parts of the nervous system.

However, a few Purkinje cell neurons from flocculonodular lobe and vermis pass directly out of cerebellum to end in the lateral vestibular nucleus.

The fibres from dentate, emboliform and globose nuclei leave the cerebellum through the superior cerebellar peduncle. The fibres from the fastigial nucleus leave the cerebellum through inferior cerebellar peduncle.

The main connections of the cerebellum are shown in [Figure 10.8](#).

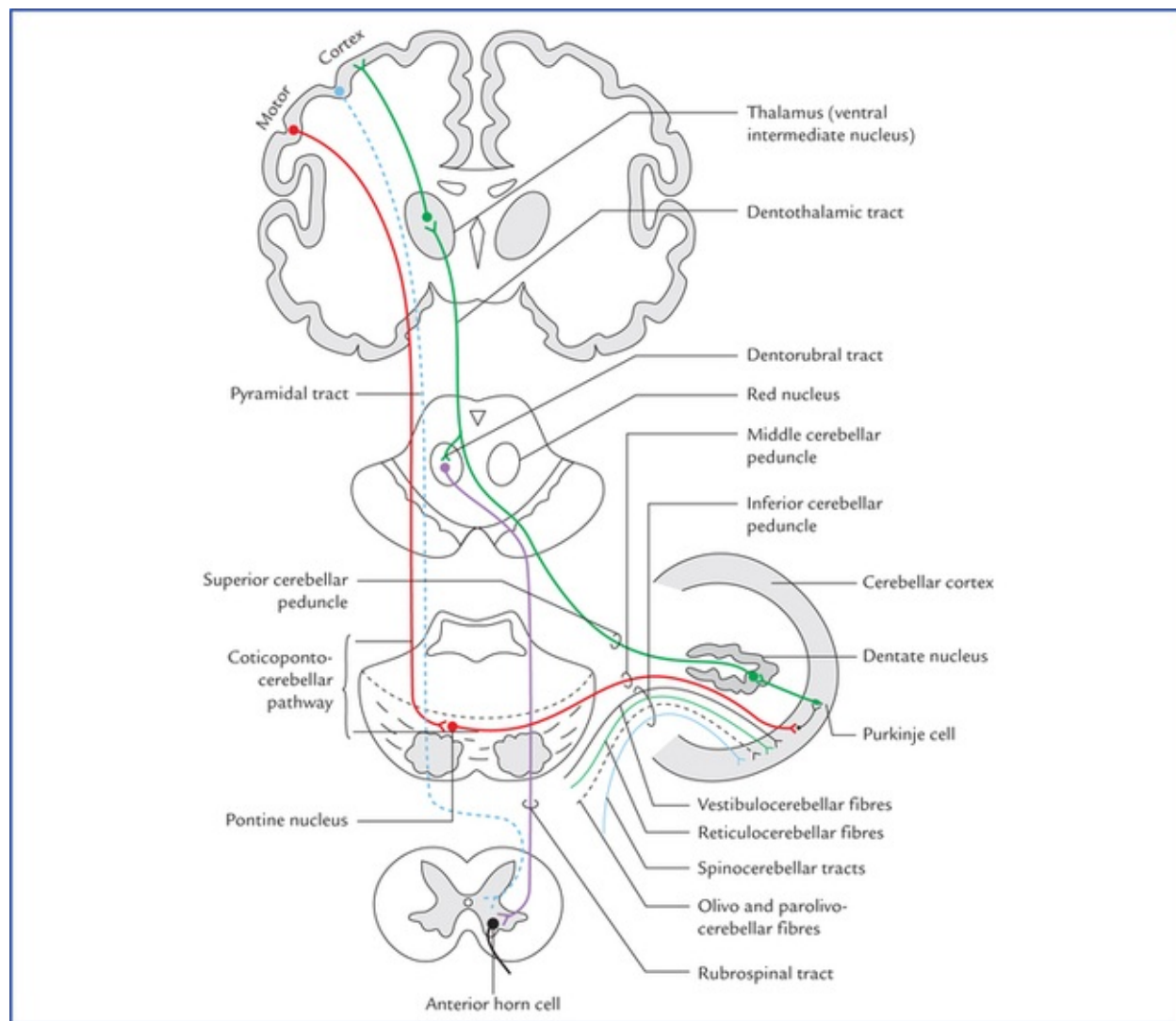


FIG. 10.8 Main connections of the cerebellum.

Intrinsic Neuronal Circuitry in The Cerebellum

The complex neuronal circuitry in cerebellum is illustrated in [Figure 10.9](#). All the afferent fibres to the cerebellum (i.e. mossy and climbing fibres) are excitatory to the cells of cerebellar cortex and their collaterals are excitatory to the intracerebellar nuclei. The climbing fibres excite Purkinje cells directly, on the other hand mossy fibres excite the Purkinje cells indirectly through the granule cells. The granule cells in addition to Purkinje cells also excite the flanking basket and stellate cells which inhibit the Purkinje cells—a *neural sharpening mechanism*. The mossy fibres also excite the Golgi cells which provide the feedback inhibition to the granule cells.

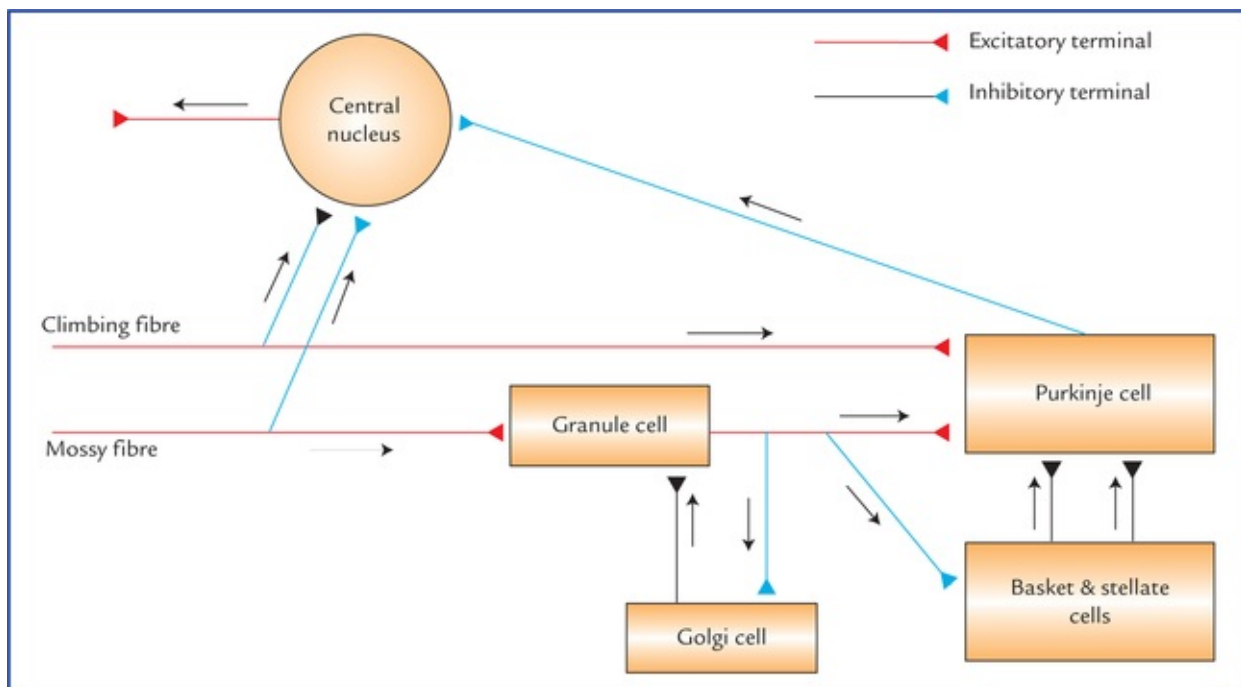


FIG. 10.9 Intrinsic neuronal circuitry in the cerebellum.

The Purkinje cells exert an inhibitory influence on the neurons of the intracerebellar nuclei which in turn modify the muscular activity through the motor control areas of the brainstem and cerebral cortex.

N.B.

- All the cells in the cerebellar cortex are inhibitory except the granule cells which are excitatory.
- The Purkinje cells are the only neurons in the cerebellar cortex which are capable of transmitting efferent impulses.

Cerebellar Peduncles

The afferent and efferent fibres of the cerebellum are grouped together on each side into three large bundles called **cere-bellar peduncles**.

The *superior cerebellar peduncles* connect the cerebellum to the midbrain, the *middle cerebellar peduncles* to the pons, and the *inferior cerebellar peduncles* to the medulla oblongata.

- Each **inferior cerebellar peduncle** is formed on the posterolateral aspect of the upper half of the medulla oblongata. The two peduncles diverge as they ascend and pass into their respective cerebellar hemispheres.

Cerebellar peduncle consists mainly of afferent fibres to the cerebellum from the spinal cord, the olivary nuclei, the reticular formation of the medulla and the vestibular nuclei and nerve. It also transmits efferent fibres from cerebellum to the medulla, principally to the vestibular nuclei, and the reticular formation.

- The **middle cerebellar peduncle** is the largest of the three peduncles. It arises from the posterolateral region of the pons and becomes continuous with the white matter of the cerebellar hemisphere.

Middle cerebellar peduncle consists of only afferent fibres which transmit the impulses from pontine nuclei to the opposite cerebellar hemisphere (pontocerebellar fibres). The pon-tine nuclei receive the impulses from ipsilateral cerebral cortex (Fig. 10.8).

- The **superior cerebellar peduncle** emerges from the anterior cerebellar notch and runs superiorly,

lateral to the upper half of the fourth ventricle, to enter the lower part of the midbrain. *It is the principal efferent pathway from the cerebellum and its fibres arise mainly in the dentate nucleus (Fig. 10.8).*

The details of constituent fibres of the three cerebellar peduncles are described below.

Inferior cerebellar peduncle (Fig. 10.10)

Afferent fibres

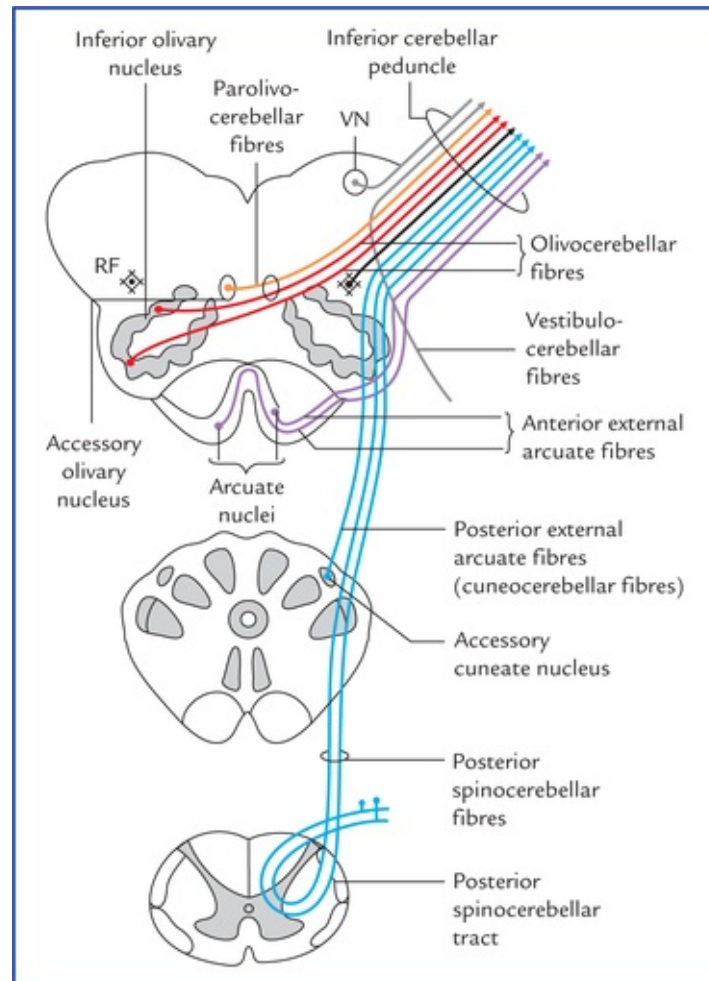


FIG. 10.10 Components of the inferior cerebellar peduncle. Afferent components are not shown. (RF = reticular formation, VN = vestibular nucleus.)

- **Posterior spinocerebellar fibres:** arise from ipsilateral thoracic nucleus (Clarke's column).
- **Olivocerebellar fibres:** arise from opposite inferior olivary nucleus.
- **Parolivocerebellar fibres:** arise from opposite medial and dorsal accessory olivary nuclei.
- **Cuneocerebellar fibres (posterior external arcuate fibres):** arise from ipsilateral accessory cuneate nucleus.
- **Anterior external arcuate fibres:** arise from arcuate nuclei of both the sides.
- **Vestibulocerebellar fibres:** primarily arise from vestibular nerve and secondary from medial and inferior vestibular nuclei. These fibres from **juxtarestiform body**.
- **Reticulocerebellar fibres:** arise from lateral and paramedian reticular nuclei of the medulla oblongata.

Efferent fibres

- **Cerebellovestibular fibres:** arise from ipsilateral flocculonodular lobe and fastigial nuclei of both sides. These fibres pass through juxtarestiform body.
- **Cerebelloreticular fibres:** arise from fastigial nuclei of both sides to the pontine and medullary reticular formation.
- **Cerebello-olivary fibres** of uncertain origin: connect the cerebellum with the inferior olivary nucleus.

Middle cerebellar peduncle

Afferent fibres

- **Pontocerebellar fibres:** form the bulk of this peduncle. These fibres arise from pontine nuclei, run transversely, cross the midline and enter the opposite cerebellar hemisphere (neocerebellum). The pontine nuclei receive input from the cerebral cortex, thus forming **cortico-ponto-cerebellar pathway**.
- **Reticulocerebellar fibres:** arise from reticular formation of brainstem of the same side are projected to the ver-mal region of the cerebellum.
- **Seratogenic fibres:** arise from raphe nuclei of the pons.

Efferent fibres

No efferent fibres pass through the middle cerebellar peduncle.

Superior cerebellar peduncle

Afferent fibres

- **Anterior spinocerebellar tract** (*see page 65*): is major afferent pathway.
- **Tectocerebellar fibres:** arise from tectum of midbrain (superior and inferior colliculi of both sides).
- **Trigemocerebellar fibres:** arise from superior sensory and spinal nuclei of trigeminal nerve (Peele, T.L. 1977). According to Gray's Anatomy (38th Ed.) these fibres pass through inferior cerebellar peduncle.
- **Ceruleocerebellar fibres:** are noradrenergic fibres from locus ceruleus.
- **Hypothalamocerebellar fibres:** are cholinergic fibres from hypothalamus (few in number).

Efferent fibres

- **Cerebellorubral fibres:** arise mainly from globose and emboliform nuclei and project to the contralateral red nucleus.
- **Dentatorubral and dentatohalamic fibres:** arise from dentate nucleus and project to the opposite red nucleus and thalamus respectively.
- **Cerebello-olivary fibres:** arise from dentate nucleus and pass to the opposite inferior olivary nucleus.
- **Cerebelloreticular fibres:** arise from nucleus fastigius and pass to the reticular nuclei.

Comparator Function of the Cerebellum

The cerebellum plays a key role in accomplishing a smooth and coordinated movements by means of its **comparator function**.

If the cerebral cortex decides on a movement to do, the impulses from motor cortex stimulate the anterior horn cells (LMNs) of the spinal cord to initiate voluntary movement, and at the same time, the motor cortex tell to the cerebellum about the intended movement, the cerebellum also receives proprioceptive information from muscles and joints, telling it what movement is actually occurring.

The cerebellum compares the intended movement with the actual movement occurring, and if a difference is detected, the cerebellum sends the information to the motor cortex and lower motor neurons to correct the discrepancy. The result is smooth and coordinated movements (i.e. movements produced are accurate in time, rate, range, force, and direction). With training, a person can develop highly skilled and rapid movements. The cerebellum thus plays an important role in **learning of motor skills**.

Arterial Supply of the Cerebellum

The cerebellum is supplied by three pairs of cerebellar arteries:

- **Superior cerebellar artery**, a branch of basilar artery supplies the superior surface of the cerebellum.
- **Anterior inferior cerebellar artery**, a branch of basilar artery supplies the anterior part of the inferior surface of the cerebellum.
- **Posterior inferior cerebellar artery**, a branch of vertebral artery supplies the posterior part of the inferior surface of the cerebellum.

Clinical Correlation

- The cerebellar lesions due to trauma, vascular occlusion, tumours, etc. produce a number of signs and symptoms, which together constitute the **cerebellar syndrome**.

The signs and symptoms produced by cerebellar lesions are as follows:

– The involvement of archicerebellum will lead to:

- (a) **Trunkal ataxia and staggering gait**: The patient is unsteady while standing, and staggering while walking [he walks with legs well apart (i.e. on a wide base) and sways from side to side].
- (b) **Nystagmus**: The involuntary, to and fro, oscillatory movements of the eyeballs while looking to either side.

*N.B. The patient is unable to maintain balance while standing upright, and falls on closing the eyes (**Romberg's sign**).*

– The involvement of paleocerebellum will lead to diminished muscle tone (**hypotonia asthenia**) of limb muscles. This manifests in the form of:

- (a) lack of stability of joints (**flail joints**).
- (b) **Disturbances of tendon reflexes**, viz. tapping of patellar tendon produces oscillating movements of the leg (i.e. leg swings backwards and forward) called **pendular knee jerk**.
- (c) inability to maintain balance while walking (**ataxia**).

– The involvement of neocerebellum leads to muscular incoordination called **asynergia**. This manifests in the form of:

- (a) **Dysmetria**, i.e. inability to measure the distance correctly for reaching an intended

target, described as **past-pointing**. Clinically this is tested by the **finger-nose test**. If the patient is asked to touch the tip of his nose by his finger, he either undershoots or overshoots the tip of his nose. When patient tries to correct the mistake, it results in, to and fro movements.

- (b) **Intention tremors probably due to dysmetria**: The tremors occur during purposeful movements and disappear with rest.
 - (c) **Adiadochokinesis/dysdiadochokinesis**, i.e. inability to execute alternate movements in rapid succession, e.g. pronation and supination of the forearm.
 - (d) **Dysarthria or scanning speech**: The speech is slurred, prolonged, explosive and with pauses in wrong places.
 - (e) **Rebound phenomenon**: The patient is unable to check the action of agonist muscles by the corresponding antagonist muscles. If the patient is asked to push the palm of a doctor by his palm, the force that the patient can develop slowly rises and now if the doctor suddenly removes his hand the limb of patient flies back (i.e. rebounds) and hits against his chest because he is not able to stop his pushing act immediately.
- The lesions of cerebellar hemisphere give rise to signs and symptoms on the side of lesion as each cerebellar hemisphere is connected by nervous pathways with the same side of the body.
 - It is important to know that the cerebellum and basal ganglia both control motor functions but have opposite effects, and many signs and symptoms associated with their dysfunction are also opposite. For example, cerebellar dysfunction results in **decreased muscle tone** and an **intentional tremor**, whereas the dysfunction of basal ganglia results in **increased muscle tone** and **resting tremor**.

Fourth Ventricle

The fourth ventricle is a tent-like cavity of hindbrain lined with ependyma and filled with cerebrospinal fluid. It is situated in the posterior cranial fossa in front of the cerebellum and behind the pons and the upper part of medulla oblongata. The cavity of the ventricle presents a triangular outline in sagittal section and appears rhomboidal in shape (lozenge-shaped) in horizontal section. It is continuous inferiorly with the central canal of medulla oblongata and superiorly with the cerebral aqueduct of midbrain (Fig. 10.11).

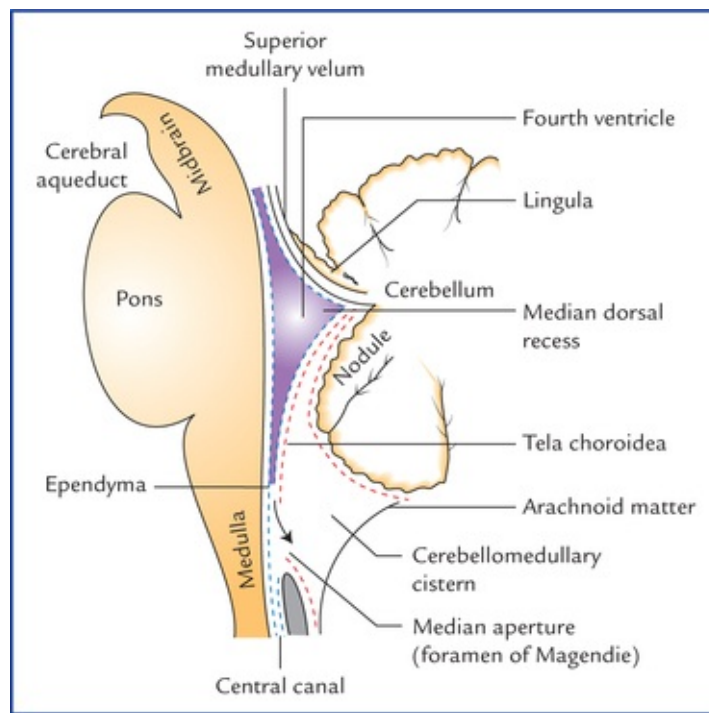


FIG. 10.11 The fourth ventricle and related structures as seen in midsagittal section.

The understanding of fourth ventricle is essential, firstly because, it is strategically placed in the midst of **vital structures** present in the medulla, pons and cerebellum, and secondly because its roof possesses three important openings which permit the CSF to escape from the ventricular system of the brain to the subarachnoid space.

Features of Fourth Ventricle

The fourth ventricle possesses a number of important features like recesses, angles, boundaries, tela choroidea and choroid plexus.

Recesses of the fourth ventricle (Fig. 10.12)

Five in number, the recesses are extensions from the cavity of the fourth ventricle:

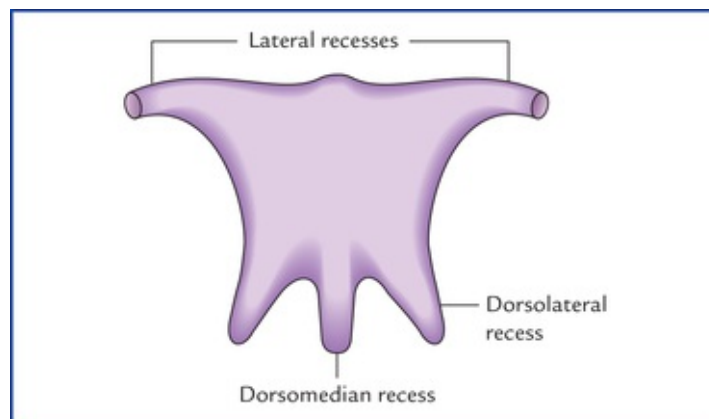


FIG. 10.12 Schematic diagram to show the five recesses of the cavity of the fourth ventricle.

- **Two lateral recesses**, one on each side extends laterally in the interval between the inferior cerebellar

peduncle ventrally and the peduncle of flocculus dorsally. The lateral extremity of the recess reaches up to the flocculus and opens into the subarachnoid space of cerebellopontine angle as the lateral aperture (**foramen of Luschka**) through which part of choroid plexus bulges out.

- A **median dorsal recess** extends into the white core of the cerebellum and lies just above (cranial) to the nodule.
- **Two lateral dorsal recesses**, one on each side of median dorsal recess, project dorsally above the inferior medullary velum, immediately lateral to the nodule.

Angles of the fourth ventricle

The cavity of fourth ventricle has four angles, superior, inferior and two lateral angles.

- The **superior angle** is continuous above with the cerebral aqueduct of midbrain.
- The **inferior angle** is continuous below with the central canal of the closed part of the medulla oblongata.
- The **two lateral angles**, one on each side is carried outwards across the dorsal surface of the inferior cerebellar peduncle as tubular pouches called *lateral recess*.

Boundaries of the fourth ventricle

Lateral boundaries (lateral walls)

On each side, the fourth ventricle is bounded,

- **inferolaterally** by inferior cerebellar peduncle, supplemented by gracile and cuneate tubercles, and
- **superolaterally**, by superior cerebellar peduncle (Fig. 10.14).

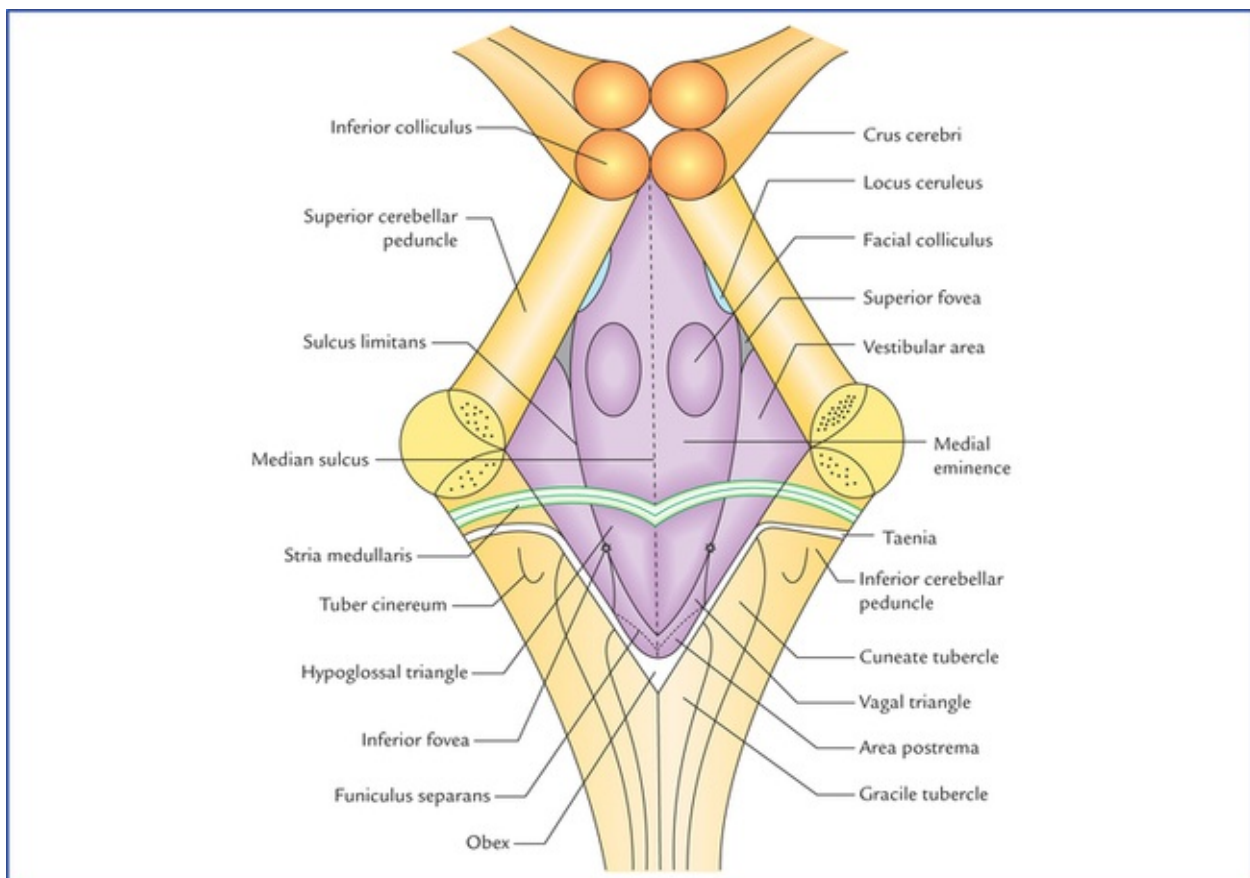


FIG. 10.14 The rhomboid fossa or floor of the fourth ventricle.

Roof (posterior wall) (Fig. 10.13)

The roof of fourth ventricle is tent-shaped and has upper and lower sloping surfaces. The apex of the tent extends posteriorly into the white core of the cerebellum.

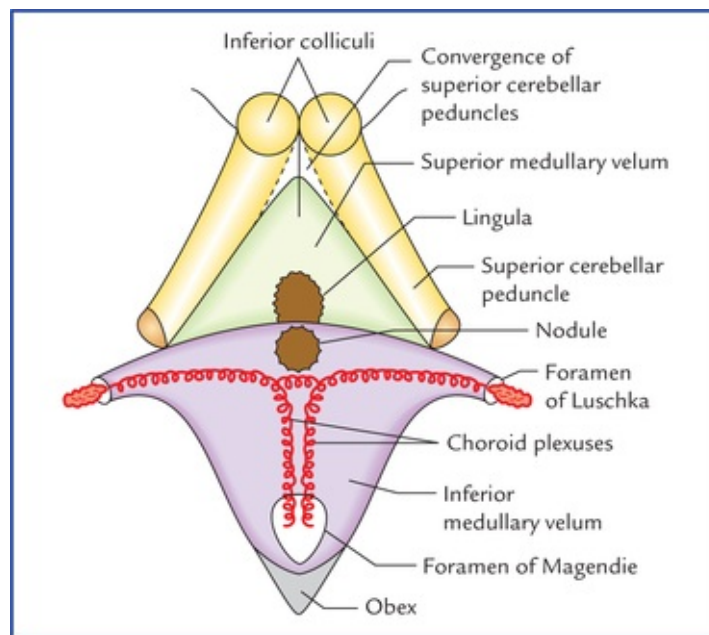


FIG. 10.13 Roof of the fourth ventricle. Note that the uppermost part of the roof is formed by the convergence of two superior cerebellar peduncles.

The *upper part of the roof* is formed by the convergence of two superior cerebellar peduncles and a thin sheet of white matter, the **superior medullary velum** that bridges the triangular gap between the two superior cerebellar peduncles. On it lies the lingula of the superior vermis of the cerebellum.

The *lower part of the roof* is formed by a thin sheet of non-nervous tissue, the **inferior medullary velum** which is formed conjointly by the ventricular ependyma and the pia mater (of tela choroidea) that covers it posteriorly. It is intimately related to the nodule of the inferior vermis of the cerebellum.

The lower part of the inferior medullary velum has a large aperture in the median plane, the **foramen of Magendie** through which the cavity of fourth ventricle communicates with the subarachnoid space of the *cerebellomedullary cistern (cisterna magna)*.

Tela choroidea of the fourth ventricle

Tela choroidea of the fourth ventricle is a double layered fold of pia mater between the inferior vermis of the cerebellum and lower part of the roof of the fourth ventricle. Its dorsal layer lines the inferior vermis which on reaching the nodule is reflected upon itself to form its ventral layer. When traced laterally, the dorsal layer is continuous with the pia mater covering the cerebellar hemisphere. The ventral layer lies over the roof of lower part of fourth ventricle and is continuous with the pia mater covering the dorsal aspect of medulla oblongata.

Choroid plexuses of the fourth ventricle

The capillary plexus of blood vessels between the two layers of tela choroidea form the rich vascular fringe that projects through the lower part of the roof of the fourth ventricle to form the **choroid plexus**. It

is derived from the branches of posterior inferior cerebellar arteries.

The plexus projects into the cavity through the lower part of the roof. The entire plexus is 'T'-shaped, where vertical limb of 'T' is double with foramen of Magendie intervening between the two limbs. The horizontal limb of plexus on either side extends into the lateral recess and protrudes through the lateral aperture, the **foramen of Luschka** into the subarachnoid space and can be seen on the surface of brain, near the flocculus.

Floor (rhomboid fossa)

The floor of the fourth ventricle is formed by posterior surfaces of the pons and the upper part of the medulla. It is rhomboid in shape (diamond-shaped) and because of its shape, the floor of fourth ventricle is often called **rhomboid fossa**. It is divisible into three parts:

- The *upper triangular part*, is formed by the posterior surface of the pons.
- The *lower triangular part*, is formed by the upper part of the posterior surface of the medulla.
- The *intermediate part* at the junction of the medulla and pons is prolonged laterally on either side over the inferior cerebellar peduncle as the floor of lateral recess. This part is bounded above by base of upper triangular part of the floor and below by a line joining the horizontal parts of the taenia. The surface of intermediate part is marked by the presence of delicate bundles of transversely arranged fibres, the **striae medullaris**.

Features of the floor of fourth ventricle (rhomboid fossa)

The floor of fourth ventricle exhibits following features (Fig. 10.14):

- The entire floor is divided into right and left symmetrical halves by a **median sulcus**.
 - On either side of median sulcus there is a longitudinal elevation called **medial eminence**.
 - Medial eminence is bounded laterally by **sulcus limitans**.
 - The region, lateral to sulcus limitans overlies the vestibular nuclei, hence it is termed **vestibular area**. This area lies partly in the pons and partly in the medulla oblongata.
 - The upper end of sulcus limitans widens into a triangular depression called **superior fovea**. Above the superior fovea the sulcus limitans flattens out and presents a bluish grey area called **locus ceruleus**. The colour is imparted by the underlying group of nerve cells containing melanin pigment which constitute the **substantia ferruginea**. The neurons of locus ceruleus contain large quantities of norepinephrine (noradrenaline).
 - The lowermost part of sulcus limitans presents a small depression called **inferior fovea**.
 - On either side, the medial eminence shows an oval swelling in the pontine part of floor at the level of superior fovea, the **facial colliculus**. The swelling is produced by the fibres from the motor nucleus of facial nerve hooking around the abducent nucleus (**internal genu of facial nerve**).
 - From inferior fovea the sulcus limitans descends obliquely towards the median sulcus. This sulcus divides the medial eminence in the medullary part of the floor into two triangles, the hypoglossal triangle above and the vagal triangle below.
1. The **hypoglossal triangle** is divided by a faint oblique furrow into a medial part which overlies the *nucleus of hypoglossal nerve* and a lateral part overlying the *nucleus intercalatus*.
 2. The **vagal triangle** overlies the nuclei of vagus, glossopharyngeal and cranial accessory nerves.
 3. The **vagal triangle** is crossed by a narrow translucent ridge called **funiculus separans**. A small area between the funiculus separans above and the gracile tubercle below is called **area postrema**. This area consists of highly vascular neuroglial tissue.

N.B. The features of the lower part of the floor of fourth ventricle resemble with that of a pen-nib, hence it is called **calamus scriptorius**.

- The inferolateral margins of the fourth ventricle are marked by a narrow white ridge called **taenia**. The two taeneae meet at the inferior angle of the ventricle to form a small fold called **obex**. The obex forms the roof of the inferior angle of the fourth ventricle. The term obex is often used to denote the inferior angle of the fourth ventricle.

The important structures that lie beneath the floor of the fourth ventricle are listed in the [Table 10.3](#).

Table 10.3

Structures underneath the floor of fourth ventricle

Part of the floor	Structures
Beneath the superior half of the floor	<ul style="list-style-type: none">• Abducent nucleus surrounded by internal genu of facial nerve• Vestibular nuclei
Beneath the inferior half of the floor	<ul style="list-style-type: none">• Vestibular nuclei• Dorsal nucleus of vagus• Nucleus intercalatus• True vomiting centre• Vital centres

Openings in the Fourth Ventricle

There are five openings in the fourth ventricle through which cerebrospinal fluid can leave the cavity of fourth ventricle:

- Central aperture in the roof (foramen of Magendie).
- Two lateral apertures in the roof (foramina of Luschka).
- Central canal of medulla oblongata.
- Cerebral aqueduct of midbrain.

Out of these five openings the CSF can pass from the cavity of fourth ventricle into the subarachnoid space only through three openings in the roof, viz. foramen of Magendie and foramina of Luschka.

Clinical Correlation

- The tumours in the region of fourth ventricle are not uncommon. The most common tumour in this region is **medulloblastoma**. It arises from poorly differentiated primitive neuroectodermal cells of cerebellar vermis and occur mostly in children.

The medulloblastoma is highly malignant and produces the signs and symptoms of cerebellar lesions, or it may press upon the vital centres located beneath the floor of the ventricle causing cardiac irregularities, tachycardia, irregular respiration, and vasomotor disturbances.

- If the openings in the roof of fourth ventricle are blocked by the growing tumour, or as a result of formation of fibrous adhesions in the subarachnoid space during meningitis. The

CSF cannot escape from the ventricular system into the subarachnoid space. This will lead to excessive accumulation of CSF within the ventricular system producing **internal hydrocephalus**.

Clinical Problems

1. What is the cause of **vermis syndrome** in children and what are its effects?
2. What is **nystagmus** and why does it occur in a cerebellar lesion?
3. A middle-aged woman complained that her right-hand tremors when she attempts to insert a thread in the eye of sewing needle; and her body sways towards the right side while walking. On physical examination the Physician found that: (a) there is flaccidity of limb muscles on the right side, (b) the patient swayed over to the right side when she was asked to walk on heel to toe along a straight line on the floor, and (c) when she was asked to touch the tip of her nose with her right index finger, the finger tended to overshoot the target. MRI of brain revealed a tumour in the right cerebellar hemisphere (Fig 10.15). The Physician told the patient that she was suffering from a cerebellar disease. Explain whether a **lesion of cerebellum** is likely to be in the vermis or in the cerebellar hemisphere.

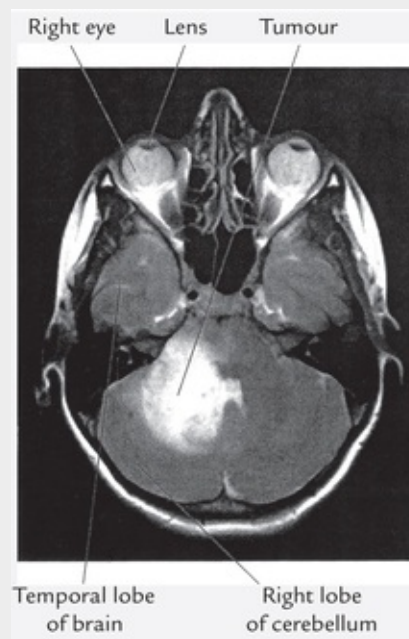


FIG.10.15 MR image of a right-sided tumour in the cerebellum. Source: Heylings, David JA, Spence, Roj AJ, Kelly, Barry E. *Integrated Anatomy*. Oxford: Elsevier Science Ltd, 2007.

4. What is **area postrema** and why it is clinically important?

Clinical Problem Solving

1. The most common cause of this syndrome is a **medulloblastoma** of the vermis in

children. The damage of midline structures of cerebellum, viz. vermis (and flocculonodular lobe) results in disturbance of equilibrium with difficulty in holding the head steady in upright position, and holding the trunk erect, and tendency to fall backward or forward (trunkal ataxia). Consequently the patient tends to stand with his legs well apart, i.e. broad-based.

Since the tumour is in the region of the roof of the fourth ventricle, the **internal hydrocephalus** may occur due to failure of escape of CSF from fourth ventricle as the foramina in the roof of fourth ventricle becomes distorted and closed by the tumour. The papilloedema in both the eyes may also occur due to increased intracranial CSF pressure.

2. The **nystagmus** is an involuntary oscillation of the eyeball. In a cerebellar lesion, the nystagmus occurs due to ataxia of the muscles moving the eyeball, i.e. lack of coordination between the agonist and antagonist muscles involved in the movement of the eyeball.
3. She is suffering from a lesion tumour of right cerebellar hemisphere because all the signs and symptoms are confined on to the right side. *Note that unlike cerebral hemisphere, each cerebellar hemisphere controls the same side of the body, hence damage to hemispheric structures always produces signs and symptoms ipsilateral to the side of the lesion.* [Figure 10.14](#) shows right-sided humour in the cerebellum.
4. The area postrema is a small area in the floor of the fourth ventricle near its inferior angle, interposed between the vagal triangle and the gracile tubercle. A highly vascular neuroglial tissue lies beneath the ependyma of this area and there is no blood-brain barrier, at this site.

Clinically the area postrema is important because the *true vomiting centre*, the **chemoreceptor trigger zone (CTZ)** is located in or near the area postrema. The CTZ contains chemoreceptor cells which initiate vomiting when they are stimulated by certain circulating toxins or drugs like apomorphine, and digitalis (*central emetics*).

Diencephalon and Third Ventricle

Diencephalon

The diencephalon is the part of brain between the cerebrum and the brainstem. The cavity within it is termed **third ventricle**.

The diencephalon comprises two major subdivisions: *pars dorsalis* and *pars ventralis*. These subdivisions are seen on midsagittal view of the brain, and are separated from each other by a shallow groove, the *hypothalamic sulcus* which extends from interventricular foramen to the rostral end of the cerebral aqueduct of midbrain (Fig. 11.10).

- **Pars dorsalis** lies above (dorsal) to the hypothalamic sulcus and consists of: (a) thalamus, (b) metathalamus which includes the medial and lateral geniculate bodies, and (c) epithalamus which consists of pineal body (gland), habenular nuclei and commissure, posterior commissure and the stria medullaris thalami.
- **Pars ventralis** lies below (ventral) to the hypothalamic sulcus and consists of: (a) subthalamus, and (b) hypothalamus.

The main divisions and subdivisions of diencephalon are listed in Table 11.1.

Table 11.1

Divisions and subdivisions of the diencephalon

Divisions	Subdivisions
Pars dorsalis	
• Thalamus (dorsal thalamus)	
• Metathalamus	Medial and lateral geniculate bodies
• Epithalamus	Pineal gland (body), habenular nuclei and commissure, and posterior commissure
Pars ventralis	
• Subthalamus (ventral thalamus)	Subthalamic nucleus, and zona inserta
• Hypothalamus	

Thalamus

Anatomically the *thalamus* is a large ovoid mass of grey matter laying above the midbrain, from which it is separated by a small amount of neural tissue, the *subthalamus*. There are two thalami situated one on each side of a slitlike cavity, the *third ventricle* (Fig. 11.1).

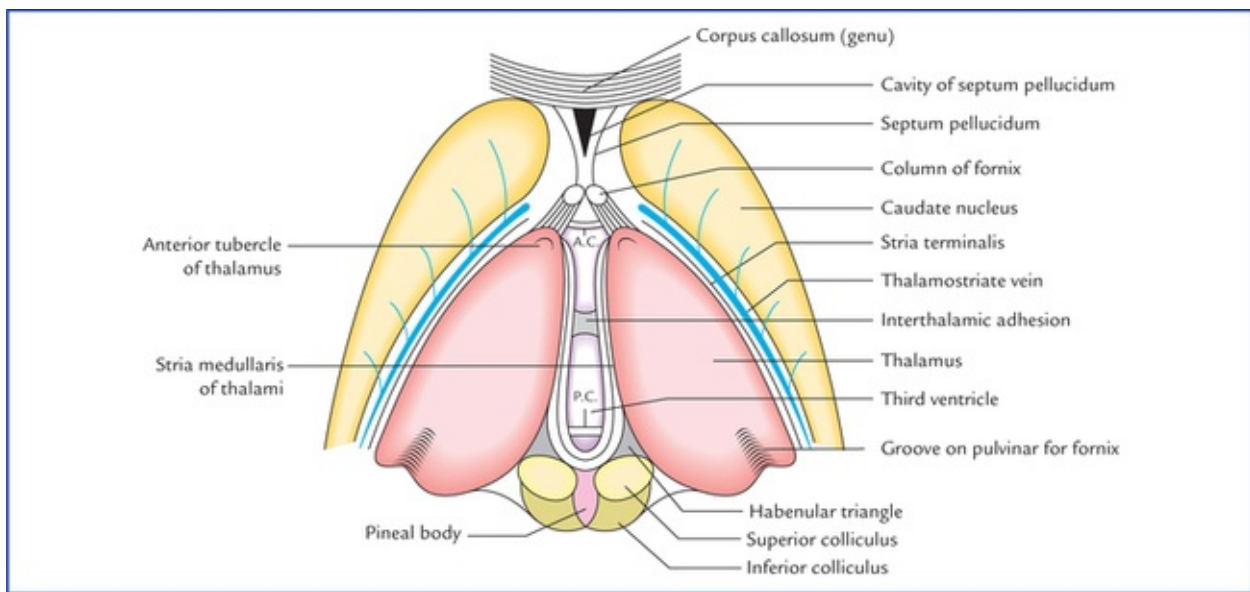


FIG. 11.1 The thalami and third ventricle as seen from above, after removal of overlying tela choroidea. (AC = anterior commissure, PC = posterior commissure.)

Each thalamus is 3.5 cm in length and 1.5 cm in breadth.

The long axes of the thalami are set obliquely running backwards and laterally. The pointed anterior ends are nearer to the median plane whereas the wider posterior ends are separated from each other by pineal body, superior colliculi and habenular triangles. The thalami are usually attached across the median plane by a narrow *interthalamic connexus* of grey matter (also called *interthalamic adhesion*). Each thalamus forms most of the lateral wall of the third ventricle and floor of the central part of the lateral ventricle.

Functionally, the thalamus is generally considered as the great sensory gateway to the cerebral cortex. It receives impulses from the opposite half of the body and transmits most of them to the sensory area of the cerebral cortex (Brodmann areas 3, 2, and 1).

External features

Each thalamus has two ends and four surfaces.

Ends

- The **anterior end** is narrow and constitutes the **tubercle of thalamus**. It forms the posterior boundary of the interventricular foramen.
- The **posterior end** is expanded and is known as **pulvinar**. It overhangs the medial and lateral geniculate bodies, and superior colliculi with their brachia.

Surfaces (Fig. 11.2)

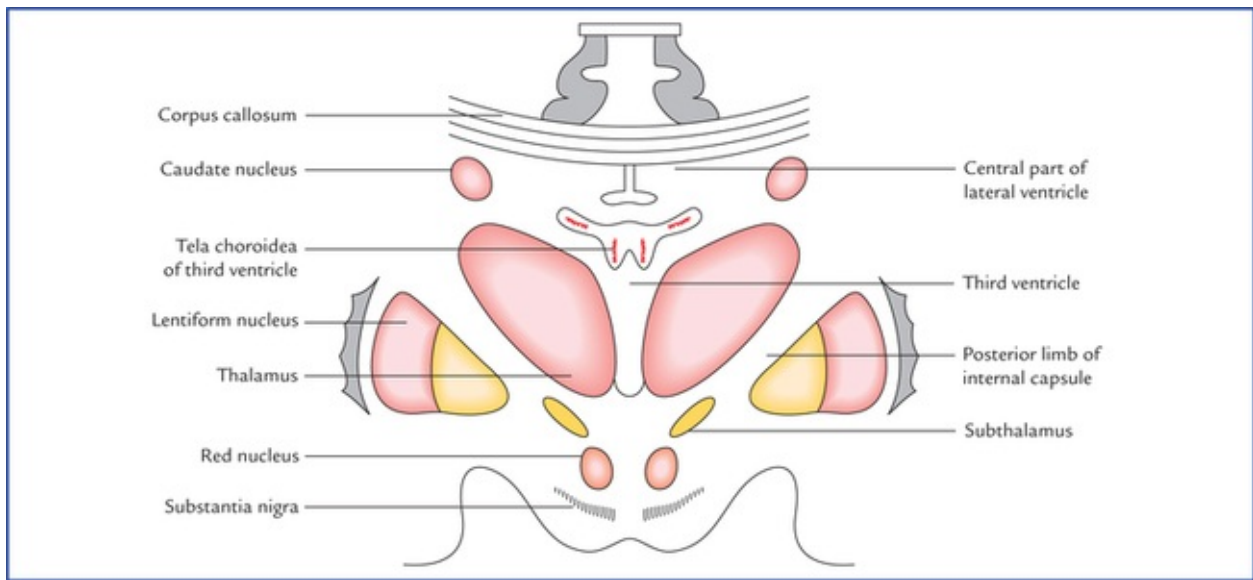


FIG. 11.2 A coronal section of the brain showing relations of the thalamus.

- **Superior surface.** Its lateral part forms the floor of the central part of the lateral ventricle and its medial part is covered by the tela choroidea of the third ventricle.
- **Inferior surface.** Its anterior part is fused with the sub-thalamus while its posterior part is free, forming the inferior aspect of the pulvinar.
- **Medial surface.** It forms the greater part of the lateral wall of the third ventricle.
- **Lateral surface.** It forms the medial boundary of the posterior limb of internal capsule.

N.B. A linear ridge of white fibres along the junction of medial and super surfaces is termed *stria medullaris thalami* or *habenular stria*.

A line of reflection of ependyma of third ventricle from its medial wall to its roof is termed *taenia thalami*.

Internal structure (Fig. 11.3)

The thalamus consists mainly of grey matter and only a small amount of white matter.

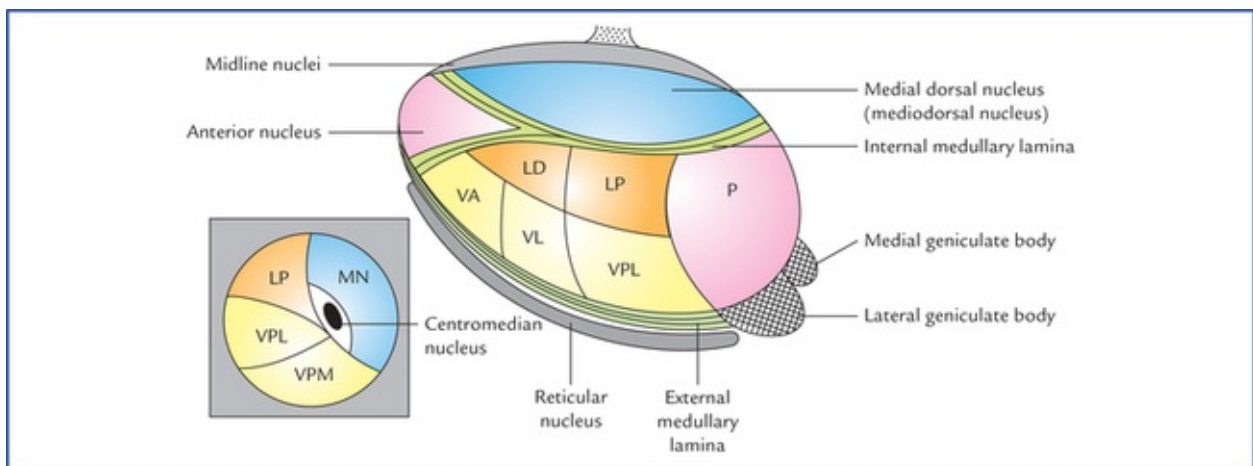


FIG. 11.3 Horizontal section of the thalamus (schematic) to show the location of various thalamic nuclei. The diagram in the inset is the coronal section of thalamus passing in front of pulvinar showing ventral posteromedial (VPM), ventral posterolateral (VPL) nuclei, and centromedian nucleus. (P = pulvinar, LD = lateral dorsal nucleus, LP = lateral posterior

nucleus, VA = ventral anterior nucleus, VL = ventral lateral nucleus, VPL = ventral posterolateral nucleus, MN = Mediodorsal nucleus.)

White matter

The lateral surface of the thalamus is covered by a thin layer of white matter called *external medullary lamina* and its superior surface by a similar layer of white matter called *stratum zonale*.

A vertical Y-shaped sheet of white matter within the thalamus is called *internal medullary lamina*.

Grey matter

The thalamic grey matter consists of number of nuclei (Fig. 11.3).

The grey matter of the thalamus is traversed anteroposteriorly by a vertical sheet of white fibres, the **internal medullary lamina** which bifurcates anteriorly to assume a Y-shaped configuration. This Y-shaped internal medullary lamina divides the thalamus into three main parts: anterior, medial, and lateral.

The *anterior part* includes the anterior tubercle and lies between the 'limbs' of the Y, the *medial and lateral parts* lie on either side of the 'stem' of the Y. Each of these parts consists of number of nuclei.

Thalamic nuclei (Fig. 11.3)

Nuclei in the anterior part

The nuclei in this part are collectively referred to as *anterior nucleus*.

Nuclei in the medial part

Nuclei in medial part consist of a large *medial dorsal nucleus* and a small *medial ventral nucleus*.

Nuclei in the lateral part

Nuclei in the lateral part are divided into dorsal and ventral parts.

The dorsal part is subdivided craniocaudally into 3 nuclei: (1) *lateral dorsal* (LD), (2) *lateral posterior* (LP), and (3) a large caudal nuclear mass, the *pulvinar* (P). These nuclei are termed as **dorsal tier of nuclei**.

The ventral part is also subdivided craniocaudally into 3 nuclei: (1) *ventral anterior* (VA), (2) *ventral lateral* (VL) or *ventral intermediate* (VI), and (3) *ventral posterior* (VP). These nuclei are termed as **ventral tier of nuclei**.

The *ventral posterior nucleus* (VP) is further subdivided into a lateral part, the *ventral posterolateral nucleus* (VPL) and a medial part, the *ventral posteromedial nucleus* (VPM).

Other thalamic nuclei

In addition to the above mentioned nuclei, the thalamus consists of following other nuclei:

- **Intralaminar nuclei.** They are several in numbers and are embedded in the internal medullary lamina. The largest and most important of these is termed *centromedian nucleus*.
- **Midline (paraventricular) nuclei.** They consist of scattered cells that lie between the medial part of the thalamus and the ependyma of the third ventricle.
- **Reticular nucleus.** It is a thin curved sheet of grey matter on the lateral aspect of the thalamus from which it is separated by the external medullary lamina.
- **Medial and lateral geniculate bodies.** These are located posteroventral to the pulvinar.

Conventionally these nuclei are described under metathalamus, but nowadays they are considered as thalamic nuclei.

The thalamic nuclei are summarized in [Table 11.2](#).

Table 11.2
Nuclei in different parts of the thalamus

Part	Nuclei
Anterior part	Anterior nucleus
Medial part	Medial dorsal nucleus, medial ventral nucleus
Lateral part	
• Dorsal tier nuclei	Lateral dorsal, lateral posterior, pulvinar
• Ventral tier nuclei	Ventral anterior (VA), ventral lateral (VL), ventral posterior—(a) ventral posterolateral (VPL), (b) ventral posteromedial (VPM)
Other parts	Intralaminar nuclei, reticular nucleus, medial and lateral geniculate bodies

The thalamic nuclei are classified into three main functional groups: *specific*, *nonspecific*, and *reticular*.

Connections of thalamic nuclei (Figs 11.4, 11.5)

Connections of the specific nuclei

These nuclei receive input from certain ascending tracts and project it to the specific (primary) cortical areas. Nuclei of this group comprise ventral tier nuclei and medial and lateral geniculate bodies. Their connections are enumerated in [Table 11.3](#).

Table 11.3
Connections of the specific thalamic nuclei

Nucleus	Afferents	Efferents	Functions
Ventral posterior (VP)			
• Ventral posteromedial (VPM)	Trigeminal lemniscus Solitariothalamic tract	To postcentral gyrus (area 3, 1, and 2)	Relay station for impulses from face and head, and taste buds
• Ventral posterolateral (VPL)	Medial lemniscus Spinal lemniscus	To postcentral gyrus (area 3, 1, and 2)	Relay station for exteroceptive (pain, touch, and temperature) and proprioceptive sensations from whole of body except face and head
Ventral anterior (VA)	From globus pallidus through subthalamic fasciculus	To premotor cortex (area 6 and 8)	Relay station for striatal impulses
Ventral lateral (VL) (also called ventral intermediate (VI))	From cerebellum (dentatorubrothalamic fibres and dentatothalamic fibres)	To motor and premotor areas of cerebral cortex (area 4 and 6)	Relay station for cerebellar impulses
Medial geniculate body	Auditory fibres from inferior colliculus	To primary auditory area (area 41 and 42)	Relay station for auditory impulses
Lateral geniculate body	Optic tract	To primary visual cortex (area 17)	Relay station for visual impulses

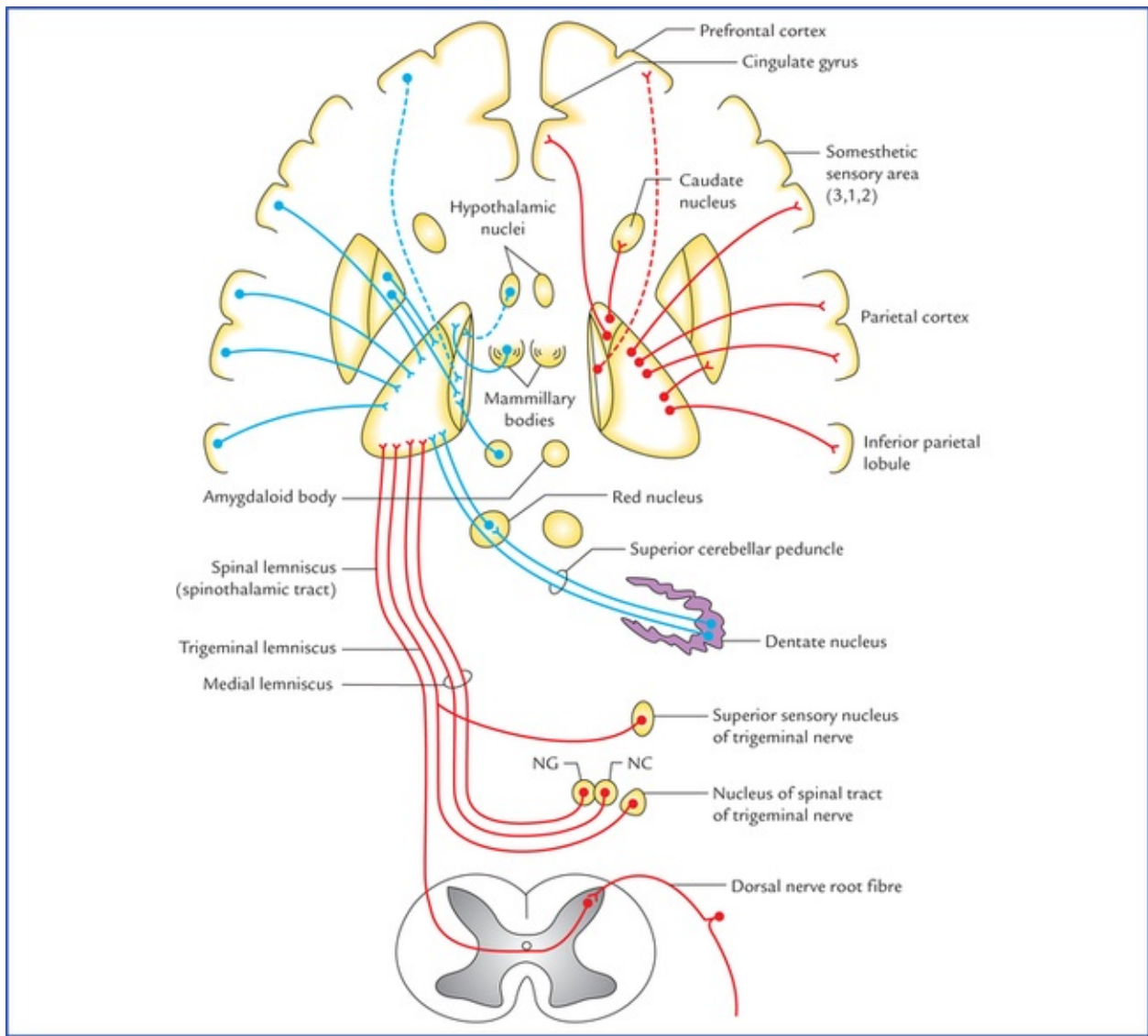


FIG. 11.4 Main connections of the thalamus. The afferent fibres are shown on the left side and the efferent, fibres on the right side. (NG = nucleus gracilis, NC = nucleus cuneatus.)

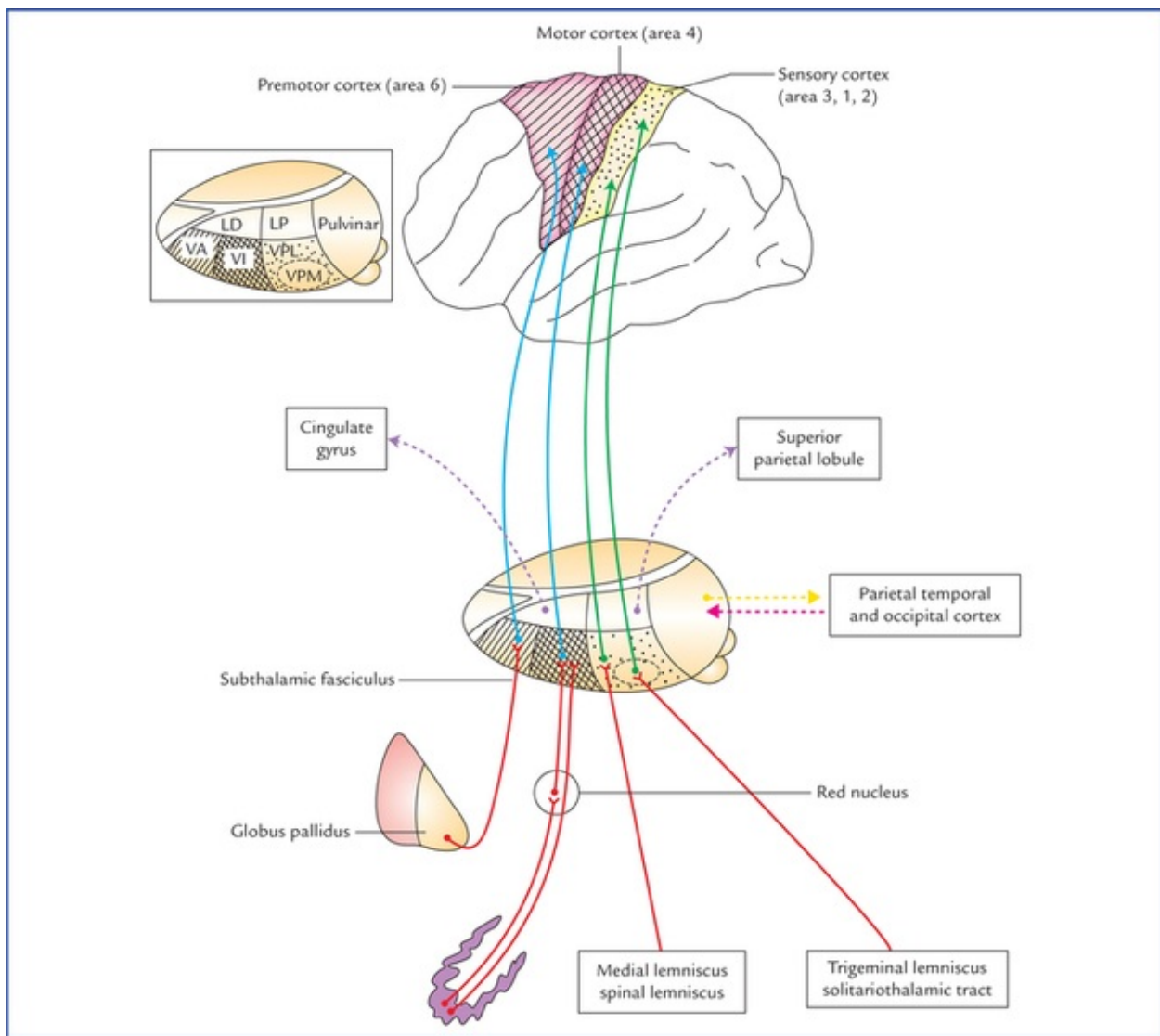


FIG. 11.5 Scheme to show connections of ventral and lateral groups of thalamic nuclei. The figure inset on left upper corner shows the dorsolateral view of thalamus and its major subdivisions. (LD = lateral dorsal nucleus, LP = lateral posterior nucleus, VA = ventral anterior nucleus, VI = ventral intermediate N, VPL = ventral posterolateral n. VPM = ventral posteromedial n.)

Clinical Correlation

- From a clinical point of view the connections of ventral posterior nucleus are most important because its smaller medial portion, the **ventral posteromedial nucleus (VPM)** receives general sensory modalities from the head and face through *trigeminal lemniscus* and taste sensations from taste buds through *solitariothalamic tract*; and its larger lateral portion, the **ventral posterolateral nucleus (VPL)** receives exteroceptive sensations (pain, touch and temperature) through *spinal lemniscus* and proprioceptive sensations (muscle and joint sense, vibration, two point discrimination) through *medial lemniscus*, from rest of the body except face and head.

All the sensations reaching the ventral posterior nucleus are carried to the primary sensory area of the cerebral cortex by fibres passing through the posterior limb of the internal capsule (superior thalamic radiation). The vascular lesions involving posterior limb of internal capsule, which are not uncommon cause impairment of all forms of sensibility on

the opposite side of the body.

- The integrity of anterior nucleus and its connections is necessary for attention and recent memory, therefore a lesion involving them can lead to **loss of recent memory**.
- Since the medial dorsal nucleus is associated with “moods” (“feeling tone”) and emotional balance, depending on the nature of the present sensory input and past experience, the mood may be that of well-being or malaise, or of euphoria or mild depression.

Connections of the nonspecific nuclei

Nonspecific nuclei do not receive afferents from ascending tracts, but have abundant connections with other diencephalic nuclei. They mostly project to the cortical ‘association areas’ in the frontal and parietal lobes. Nuclei of this group comprise anterior nucleus, dorsal medial nucleus and dorsal tier nuclei of thalamus. Their connections are enumerated in [Table 11.4](#).

Table 11.4

Connections of the nonspecific thalamic nuclei

Nucleus	Afferents	Efferents	Functions
Anterior nucleus	Mammillothalamic tract from mammillary body	To cingulate gyrus	Attention and recent memory
Medial dorsal nucleus	From other thalamic nuclei and hypothalamus	To prefrontal area	Associated with mood and emotional balance
Lateral dorsal nucleus	From ventral tier of thalamic nuclei	To precuneus and cingulate gyrus	Integrate sensory information
Lateral posterior nucleus	From ventral tier of thalamic nuclei	Superior parietal lobule	Integrate sensory information
Pulvinar	From ventral tier of thalamic nuclei	To association areas in parietal, occipital and temporal lobes	Correlates visual and auditory information with other sensations

Connections of the reticular nuclei

The reticular nuclei of thalamus include reticular nucleus, intralaminar nuclei and median nuclei. These nuclei are connected with the reticular formation. Their connections are given in [Table 11.5](#).

Table 11.5

Connections of the reticular nuclei of thalamus

Nucleus	Afferents	Efferents	Functions
Reticular nucleus	From brainstem reticular formation	To whole of cerebral cortex	Forms part of reticular activating system (RAS)
Intralaminar nuclei including centromedian nucleus	From brainstem reticular formation	To other thalamic nuclei and corpus striatum	Involved in awareness of painful stimuli at thalamic level

Functions of thalamus

- It is a sensory integration and relay station of all the sensory pathways except for the olfactory pathway, which is projected directly to the cerebral cortex without being relayed in the thalamus.
- It is capable of recognition, though poorly of the pain, thermal and some tactile sensations at its own level.
- It influences voluntary movements by receiving impulses from basal ganglia and cerebellum and relaying them to the motor cortex, which in turn influences lower motor neurons through corticonuclear and corticospinal pathways.
- Through ascending reticular activating system, the thalamic reticular component participates in the maintenance of the state of wakefulness and alertness.
- By receiving impulses from hypothalamus and projecting them to the prefrontal and cingulate gyri, it participates in *affective reactions*, viz. determination of mood.
- It is thought to have role in recent memory and emotions.
- It influences the electrical activity of the cerebral cortex, i.e. it plays a role in synchronization or desynchronization of EEG waves.

Clinical Correlation

• Thalamic syndrome

It usually occurs subsequent to a vascular lesion of the thalamus (viz. thrombosis of thalamogeniculate artery). when the patient is recovering from a thalamic infarct.

Characteristic features

The threshold for pain, touch and temperature is decreased on the opposite side of the body (**thalamic overreaction**) but, when the threshold is reached, the sensations are exaggerated, perverted and disagreeable. For example, the prick of a pin may be felt as a severe burning sensation, and even music that is ordinarily pleasing may be disagreeable. Sometimes even light touch may produce excruciating pain. The spontaneous pain may occur in some instances that may become intractable and fail to respond to powerful analgesics (pain relieving) drugs.

There may be emotional instability, with spontaneous (or forced) laughing and crying.

• Thalamic hand

It is sometimes seen in thalamic lesions. The opposite hand is held in an abnormal posture. The forearm is pronated, wrist flexed, metacarpophalangeal joints flexed and interphalangeal joints extended. The fingers can be moved but slowly, due to altered muscle tone in the different muscle groups.

Metathalamus

The metathalamus consists of the medial and lateral geniculate bodies (Fig. 11.6). These are small rounded elevations on the inferior aspect of the posterior part of thalamus, lateral to each side of the midbrain. The medial and lateral geniculate bodies are relay stations for the auditory and visual pathways respectively.

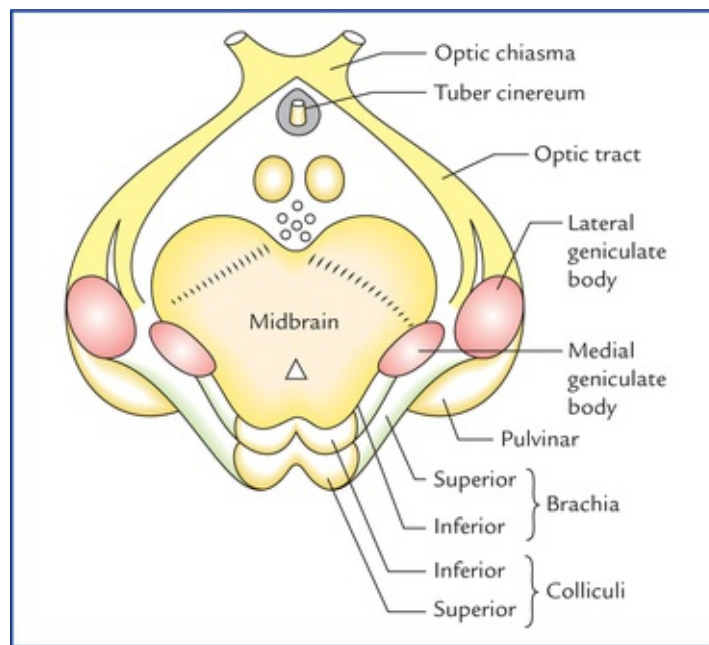


FIG. 11.6 Schematic diagram showing the location of the medial and lateral geniculate bodies.

Medial geniculate body

Medial geniculate body is an oval elevation on the inferior aspect of the pulvinar of the thalamus, lateral to the superior colliculus. It is more prominent than the lateral geniculate body. The inferior brachium runs upwards, laterally and forwards from inferior colliculus to the medial geniculate body.

Connections

Afferents: Auditory pathways through lateral lemniscus either directly or after relay in the inferior colliculus. These fibres pass through brachium of inferior colliculus (inferior brachium).

Efferents: Geniculocortical fibres project as **auditory radiation** through sublentiform part of internal capsule to the primary auditory area in the temporal lobe (area 41, 42).

Lateral geniculate body

Lateral geniculate body is a small ovoid prominence visible at the terminal end of the optic tract. It is situated on the inferior surface of the pulvinar, anterolateral to the medial geniculate body. It is smaller than the medial geniculate body and connected to the superior colliculus by the superior brachium.

Structure

The grey matter of lateral geniculate body consists of six layers (or laminae) separated by nerve fibres. These layers are numbered 1 to 6 from ventral to dorsal side. Laminae 1, 4, and 6 receive fibres from the retina of opposite side and laminae 2, 3, and 5 from the retina of the same side (Fig. 11.7).

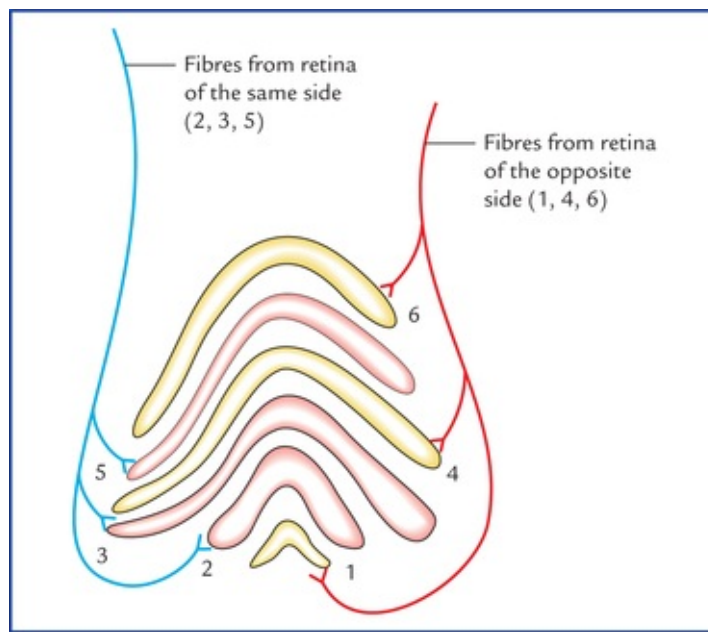


FIG. 11.7 Six layers (laminae) of the lateral geniculate body and their afferent connections.

Connections

Afferents: Lateral root of the optic tract consisting of most of the retinal fibres of both the eyes (temporal fibres of the same side and nasal fibres of the opposite side).

Efferents: Geniculocalcarine fibres project as the **optic radiation** through retrolentiform part of internal capsule to the visual cortex of the occipital lobe (areas 17, 18, and 19).

Functions

The lateral geniculate body is the last relay station on the visual pathway.

***N.B.** Not all retinal fibres synapse in the lateral geniculate body. These uninterrupted retinal fibres terminate in the pretectal area and superior colliculus of midbrain to serve light reflexes.*

The comparison between the medial and lateral geniculate bodies is provided in [Table 11.6](#).

Table 11.6

Comparison between the medial and lateral geniculate bodies

Medial geniculate body	Lateral geniculate body
Oval-shaped collection of grey matter on the inferior aspect of the pulvinar	Bean-shaped collection of grey matter on the inferior aspect of inferior aspect of the pulvinar
Hilum absent	Hilum present
No lamination	Consists of 6 laminae, numbered 1 to 6 from ventral surface to dorsal surface
Destruction of medial geniculate on one side has little or no effect on hearing	Destruction of lateral geniculate body on one side produces blindness in the opposite half of the field of vision
Last relay station on the auditory pathway	Last relay station on the optic pathway
Sends auditory impulse through auditory radiation to the auditory area of the temporal lobe	Sends visual impulses through optic radiation to the visual radiation to the cortex of the occipital lobe

Epithalamus

Pineal gland (epiphysis cerebri)

Pineal gland is a midline cone-shaped reddish grey structure (only 3 mm × 5 mm in size) occupying the vertical groove between the two superior colliculi below the splenium of corpus callosum. It has a stalk which divides into two laminae. The ventral (or inferior) lamina is continuous with the **posterior commissure**, and the dorsal (or superior) lamina is continuous with the **habenular commissure** (Fig. 11.8). The extension of the cavity of third ventricle between the two laminae is termed **pineal recess**.

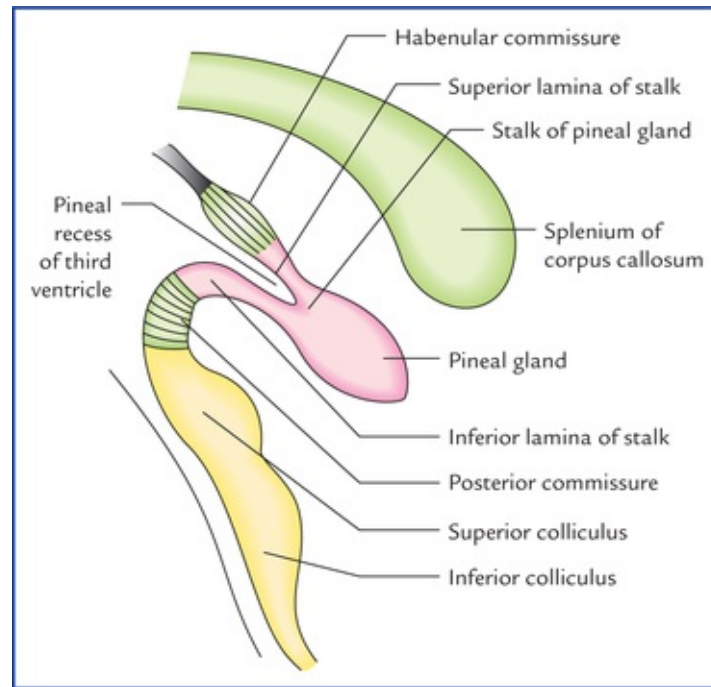


FIG. 11.8 The pineal gland in relation to the third ventricle and habenular and posterior commissures.

The pineal gland is supplied by a nerve called **nervus con-arii**, which consists of postganglionic sympathetic fibres arising from superior cervical sympathetic ganglion.

Structure

The pineal gland is a neuroendocrine gland and consists of parenchymal cells, called **pinealocytes**, and **neuroglial cells**. The pinealocytes secrete a hormone called **melatonin**. The calcium phosphates and carbonates are deposited in the gland with age in the form of multilaminar corpuscles called **corpora arenacea** (or **brain sand**).

Functions

Descartes described the pineal gland as the **seat of soul**. It is not for sure, a functionless vestigial organ representing dorsal **third eye** (found in some types of fishes and amphibians) as was assumed in the recent past. At present, it is considered to be the most highly evolved gland of the body and has following known functions:

- It has a neuroendocrine activity in regulation and modulation of the pituitary and all other endocrine organs, mostly inhibitory.
- It acts as **biological clock** for physiological and behavioural control.

- It secretes a hormone, **melatonin** which inhibits secretion of gonadotrophins (GnRH) from hypothalamus. Thus, it has inhibitory effect on the reproductive system (sexual maturity). The melatonin is produced at night and its production falls during day time. *Melatonin probably holds back the reproductive development until a suitable age has reached by inhibiting the secretion of gonadotrophic hormones.*
The neural pathway for pineal secretion is as follows: Retina → optic tract → brainstem → superior cervical sympathetic ganglion → nervus conarii → pineal gland.

Unique features

- Pineal gland is the only part of the brain, which has no nerve cells in it.
- It is the only part of the brain which is supplied by a nerve (nervus conarii) which arises from outside the brain.

Clinical Correlation

- The lesions of the pineal gland are associated with **precocious puberty**.
- The **calcification of the pineal gland** is demonstrable radiologically in more than 50% of normal adults. It lies in midline or midsagittal plane of the skull, and is about 5 cm above the external auditory meatus, in lateral view of the X-ray skull (However, sometimes, the shadow of pineal gland is seen slightly to the left, as at this level the right cerebral hemisphere is slightly wider than the left). It may serve as a useful landmark to detect any shift of the brain from the midline due to some space occupying lesions within the brain. The displacement of pineal shadow indicates towards the site of the intracranial space occupying lesion.

Habenular Nucleus

Habenular nucleus lies beneath the habenular triangle, which is a small triangular area above the superior colliculus and medial to the pulvinar of thalamus. Medially the triangle is bounded by stria medullaris thalami and stalk of pituitary gland (Fig. 11.1).

Habenular nucleus together with its connections forms the part of the limbic system.

Habenular Commissure

Habenular commissure connects the habenular nuclei of the two sides and crosses the midline by passing through the superior lamina of the stalk of pineal gland (Fig. 11.8).

Posterior Commissure

Posterior commissure is composite bundle of fibres which connect the medial longitudinal fasciculi, interstitial nuclei, superior colliculi, pretectal nuclei and posterior thalamic nuclei of the two sides. It crosses the midline by passing through the inferior lamina of the stalk of the pineal gland (Fig. 11.8).

Subthalamus

Subthalamus is described in detail on [page 158](#).

Hypothalamus

The hypothalamus is a part of diencephalon which lies below the thalamus. It forms the floor and the lower parts of lateral walls of the third ventricle. Anatomically the hypothalamus is small in size weighing only 4 g and forming only 0.3% of the total brain mass but physiologically there is hardly any activity in the body that is not influenced by it. Thus, the functional significance of the hypothalamus is disproportionate to its size. The hypothalamus controls three systems: (a) autonomic nervous system, (b) endocrine system, and (c) limbic system. The hypothalamus helps to maintain the homeostasis.

N.B. Being the principal autonomic centre of the brain, it has been regarded as the head ganglion of the autonomic nervous system by Sherrington.

Boundaries of the hypothalamus

Strategically the hypothalamus is placed close to the limbic system, thalamus and hypophysis cerebri. Its boundaries are as follows:

Anteriorly: Lamina terminalis (lamina terminalis extends from the optic chiasma to the anterior commissure). **Posteriorly:** Subthalamus.

Inferiorly: Structures in the floor of third ventricle, viz. tuber cinereum, infundibulum, and mammillary bodies. (These structures are actually the parts of hypothalamus.)

Superiorly: Thalamus.

Laterally: Internal capsule.

Medially: Cavity of third ventricle.

Subdivisions of the hypothalamus

For the sake of convenience of description, the hypothalamus is divided into number of regions/zones.

The hypothalamus is divided into two lateral halves by the cavity of third ventricle (above) and an imaginary median plane (below). As per conventional teaching, the hypothalamus is considered as a single structure but strictly speaking, it is a **bilateral structure**.

The anterior column of fornix traverses the hypothalamus to reach the mammillary body and serves as a point of reference for a sagittal plane that divides the hypothalamus into **medial** and **lateral** zones. The **mammillothalamic tract** and **fasciculus retroflexus** also lie in this plane ([Fig. 11.9](#)).

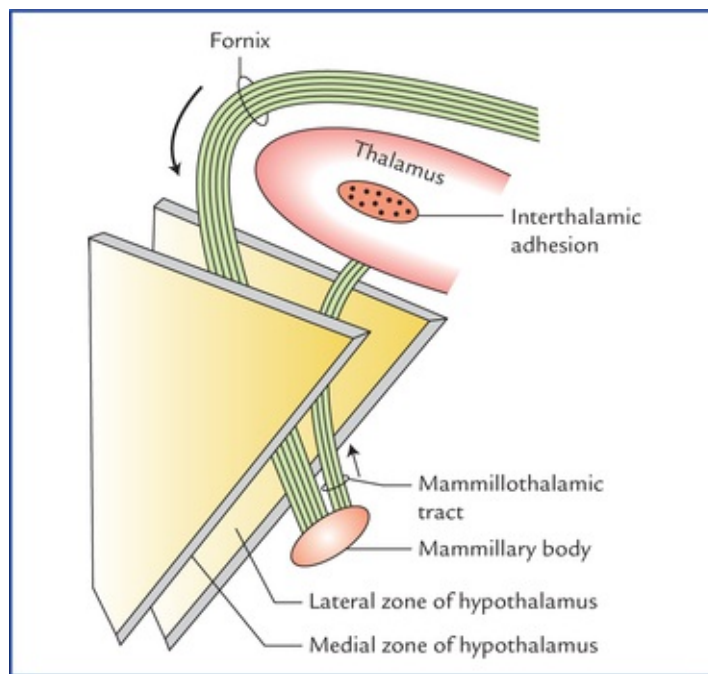


FIG. 11.9 Schematic diagram to show medial and lateral zones of the hypothalamus with fornix and mammillothalamic tract lying in the plane between the two zones.

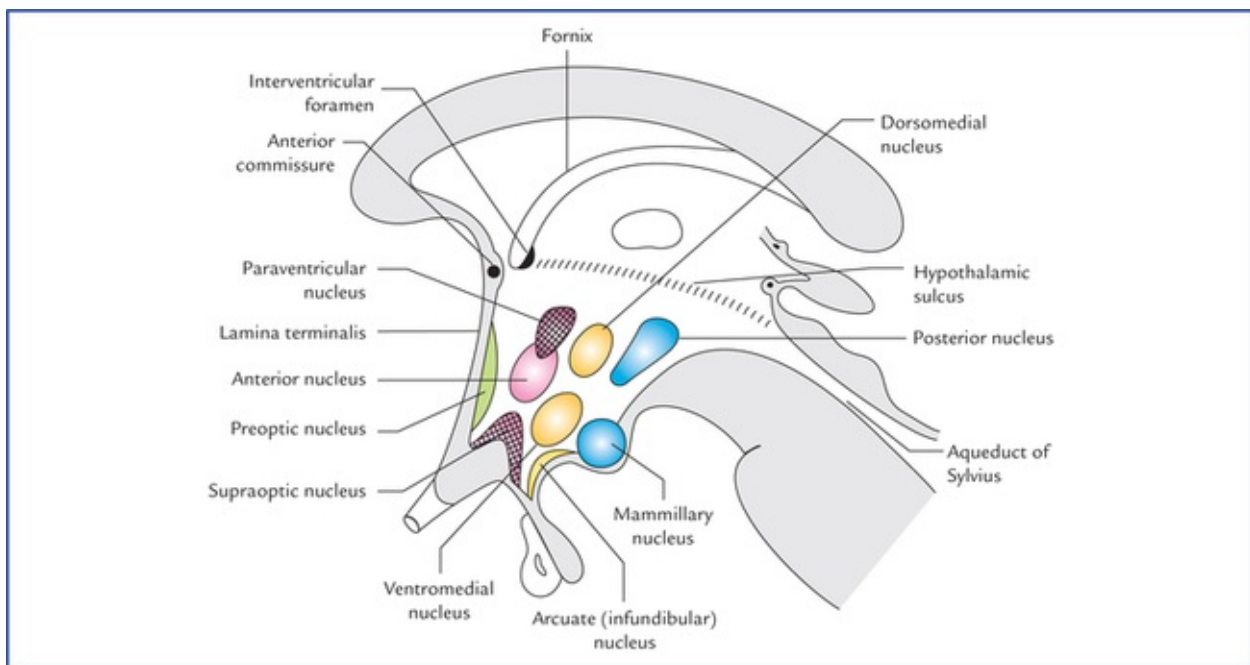


FIG. 11.10 Different nuclei of hypothalamus in sagittal section. The lateral nucleus of the hypothalamus is not shown.

The medial zone is again divided into a thin subependymal or periventricular zone and a thicker intermediate zone.

Thus, the hypothalamus is divided, from medial to lateral side into the following three zones:

1. Periventricular zone
 2. Intermediate zone
 3. Lateral zone.
- } Medial zone

The hypothalamus is also subdivided anteroposteriorly into the following four regions:

1. *Preoptic region* adjoining the lamina terminalis.
2. *Supraoptic region* above the optic chiasma.
3. *Tuberal region* includes the tuber cinereum, infundibulum and area around it.
4. *Mammillary region* includes the mammillary bodies and area around it.

The *preoptic region* lies anterior to the hypothalamus between the optic chiasma and anterior commissure. Anatomically it belongs to the telencephalon but functionally to the hypothalamus.

The *tuber cinereum* is the region bounded, caudally by mammillary bodies and rostrally by optic chiasma. The *infundibulum* connects the posterior lobe of the hypophysis cerebri with the tuber cinereum. The tuber cinereum around the base of the infundibulum is raised to form a **median eminence**.

Hypothalamic nuclei

The hypothalamus is made up of numerous small nuclear masses, called **hypothalamic nuclei**. The nuclei present in different regions of the hypothalamus are listed in [Table 11.7](#) and shown in [Figure 11.10](#).

Table 11.7

Hypothalamic regions and nuclei in them

Region	Nucleus/nuclei
Preoptic region	Preoptic nucleus
Supraoptic region	<ul style="list-style-type: none">• Supraoptic nucleus• Anterior nucleus• Paraventricular nucleus
Tuberal region	<ul style="list-style-type: none">• Arcuate (infundibular) nucleus• Ventromedial nucleus• Dorsomedial nucleus
Mammillary region	<ul style="list-style-type: none">• Posterior nucleus• Mammillary nuclei

In general, the hypothalamic nuclei are divided into four groups – preoptic, supraoptic, tuberal, and mammillary.

***N.B.** The large nerve cells throughout the lateral zone are relatively sparse and collectively constitute the **lateral nucleus**. Since this nucleus occupies the whole anteroposterior extent of the hypothalamus, it could not be included in above-mentioned four groups.*

The major hypothalamic nuclei and their functions are enumerated in [Table 11.8](#).

Table 11.8

Major hypothalamic nuclei and their functions

Nucleus/nuclei	Functions
Prebiotic nucleus	Regulates release of gonadotrophic hormones
Supraoptic and paraventricular nuclei	– Produce antidiuretic hormone (ADH) and oxytocin – Regulate water balance
Anterior nucleus	– Regulates body temperature by dissipation of heat – Stimulates parasympathetic nervous system
Arcuate (infundibular) nucleus	Produces hypothalamic releasing factors
Ventromedial nucleus	It is considered as a 'satiety centre'. Its stimulation inhibits the urge to eat.
Dorsomedial nucleus	Its stimulation causes obesity and results in savage behaviour
Posterior nuclei	– Regulates body temperature by conservation of heat – Stimulates sympathetic nervous system
Mammillary nuclei	Receives input from hippocampal formation through fornix
Lateral nucleus	Its stimulation induces eating

Connections of the hypothalamus

The connections of hypothalamus (afferents and efferents) are numerous and complex, therefore, only main connections are described here.

Afferent connections

- **Fornix** connects the hippocampus to the mammillary bodies.
- **Stria terminalis** connects the amygdaloid body to the preoptic and anterior hypothalamic nuclei.
- **Mammillary peduncle** conveys sensory impulses from the spinal cord and the brainstem to the lateral hypothalamic nucleus.
- **Medial forebrain bundle** connects the autonomic and limbic structures of the forebrain to the hypothalamus.
- **Thalamohypothalamic, pallidohypothalamic and sub-thalamohypothalamic pathways** connect the thalamus, corpus striatum and subthalamus to the hypothalamus respectively.
- **Direct physical and chemical receptors.** The circulating blood is constantly monitored by the hypothalamic cells, which function as thermoreceptors, osmoreceptors or chemoreceptors.

Efferent connections

- **Mammillothalamic tract** connects the mammillary body to the anterior nucleus of the thalamus, which in turn projects to the cingulate gyrus.
- **Mammillotegmental tract** connects the mammillary body to the reticular formation of the brainstem.
- **Descending fibres to the brainstem and spinal cord** influence the peripheral neurons of the autonomic nervous system.

Through reticular formation, the hypothalamus is connected to the parasympathetic nuclei of oculomotor, facial, glossopharyngeal, and vagus nerves in the brainstem.

Similarly, the hypothalamus is also connected to the preganglionic sympathetic neurons in the lateral horns of T1 to L2 spinal segments and to the preganglionic para-sympathetic neurons in the lateral horns of S2, 3, and 4 spinal segments.

- **Hypothalamus is connected to the neurohypophysis and adenohypophysis** of the hypophysis cerebri through *supraopticohypophyseal* and *tuberoinfundibular tracts* respectively.

In view of their greater clinical significance, the connections of hypothalamus with the hypophysis cerebri are discussed in detail in the following text.

Connections of the hypothalamus with the hypophysis cerebri (pituitary gland)

Connections with the neurohypophysis (Fig. 11.11)

The fibres arising from *supraoptic* and *paraventricular nuclei* project to the posterior lobe of pituitary gland (neuro-hypophysis) as the **hypothalamo-hypophyseal tract** (also called *supraoptico-hypophyseal tract*). The hormones *vasopressin* and *oxytocin* are synthesized in the nerve cells of the supraoptic and paraventricular nuclei, respectively and are transported to the posterior pituitary along the fibres of this tract (by axoplasmic flow). The neuro-secretory axons terminate as small expansions on the capillary blood vessels in the neurohypophysis. Here these hormones are absorbed into the blood stream in the capillaries.

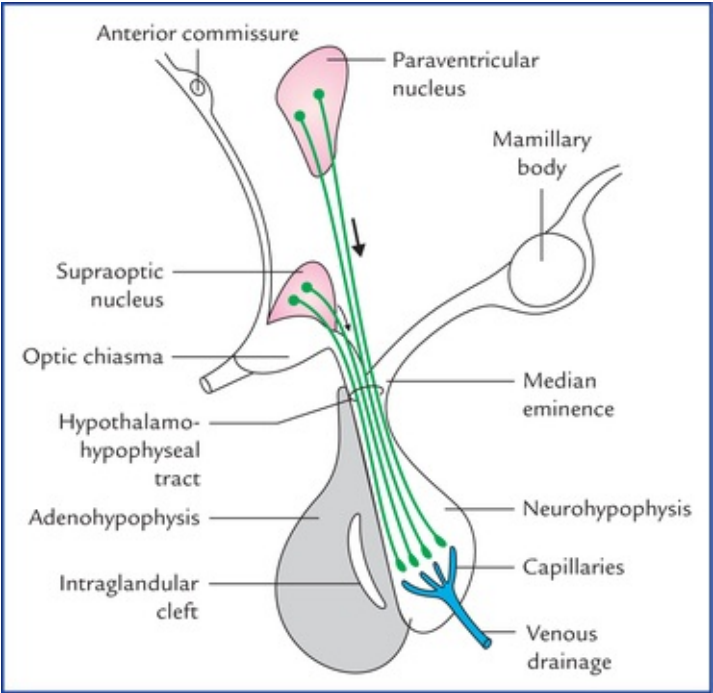


FIG. 11.11 The origin and distribution of the fibres of supra-opticohypophyseal (*hypothalamohypophyseal*) tract.

The **vasopressin (antidiuretic hormone)** is vasoconstrictor and causes an increased absorption of water in the distal convoluted tubules and collecting tubules of the kidney (*antidiuretic effect*).

The **oxytocin** causes contraction of the uterine muscle and myoepithelial cells that surround the alveoli of the mammary gland.

Diabetes insipidus

It develops due to impaired secretion of antidiuretic hormone (vasopressin) following lesions of— supraoptic and paraventricular nuclei or supraoptico-hypophyseal tract. The characteristic features are: (a) **polyuria** (urine volume is very large with low specific gravity), and (b) **polydipsia** (increased water intake). It is the best known **hypothalamic syndrome**.

N.B. The absence of glycosuria differentiates it from diabetes mellitus.

Connections with adenohypophysis (Fig. 11.12)

The **releasing hormones** and **release-inhibiting hormones** are produced in the cells of tuberal and infundibular nuclei and are transported to the median eminence along the **tubero-infundibular tract**. From here, these hormones are carried by the **hypothalamohypophyseal portal system** to the secretory cells of the anterior lobe of the hypophysis cerebri (adenohypophysis).

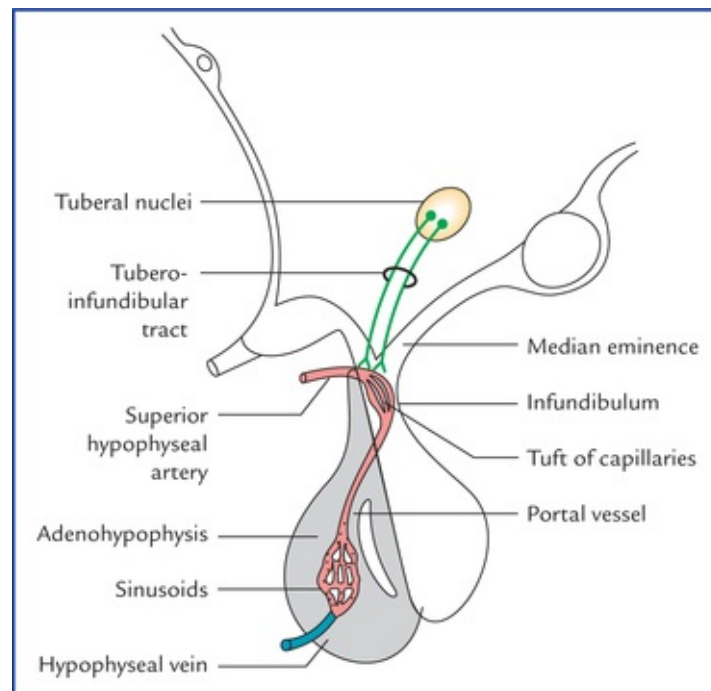


FIG. 11.12 The connections of hypothalamus with adenohypophysis through tuberoinfundibular tract and hypothalamo-hypophyseal portal system.

The *releasing hormones* stimulate the production and release of adrenocorticotropic hormone (ACTH), follicle stimulating hormone (FSH), luteinizing hormone (LH), thyroid stimulating hormone (TSH), and growth hormone (GH).

The *release-inhibiting hormones* inhibit the release of the melanocyte stimulating hormone (MSH) and luteotropic hormone (LTH). The LTH is also called lactogenic hormone or prolactin.

The *hypophyseal portal system* is formed by the hypophyseal branches of the internal carotid artery. After entering the median eminence these branches divide into tuft of capillaries drain into descending vessels (*hypophyseal portal veins*) that end in the anterior lobe of the hypophysis by dividing into

vascular sinusoids between the secretory cells of the anterior lobe and then drained by a hypophyseal vein.

Functions of hypothalamus

- **Autonomic control.** The anterior part of the hypothalamus controls the parasympathetic nervous system while posterior part controls the sympathetic nervous system.
- **Endocrine control.** The hypothalamic centres are sensitive to circulating hormonal levels, providing negative or positive feedback. The hypothalamus regulates the hormonal secretion of anterior pituitary by forming the releasing factors or release inhibiting factors, which in turn controls the endocrine activities of the body.
- **Neurosecretion.** The hypothalamus secretes oxytocin and vasopressin.
- **Regulation of food and water intake.** The lateral part of the hypothalamus acts as a **hunger centre** while the medial part acts as a **satiety centre**. A **thirst centre** in the lateral part regulates the water intake.
- **Emotional expression.** The autonomic emotions like laughing, crying, sweating or blushing are expressed by the integrated activity of the ANS and somatic efferent system.
- **Regulates the sexual behaviour and reproduction.** This is done by influencing the secretion of gonadotrophic hormones by the pituitary gland.
- **Temperature regulation.** The cold and heat sensors located in the hypothalamus respond appropriately to maintain the body temperature at optimum level in diverse conditions. The anterior portion of the hypothalamus prevents the rise in body temperature while posterior portion promotes heat conservation and heat production.
- **Biological clock.** It regulates the cyclic activities of the body (*circadian rhythm*), viz. sleeping and waking cycle but itself affected by diurnal rhythms. The circadian rhythm for many body functions is of about 24 hours.

Clinical Correlation

Craniopharyngioma

It is congenital tumour which develops from remnants of the Rathke's pouch. It is the most common supratentorial tumour in children and is the most common cause of hypopituitarism in them. It is often a benign tumour which is often cystic and/or calcifies (Fig. 11.13). It compresses optic chiasma and hypothalamus. Clinically it presents as: (a) bitemporal hemianopia, due to pressure on optic chiasma, and (b) hypothalamic syndrome (i.e. diabetes insipidus, adiposities, relentless weight gain, disturbance of temperature regulation, etc.) due to pressure on the hypothalamus.

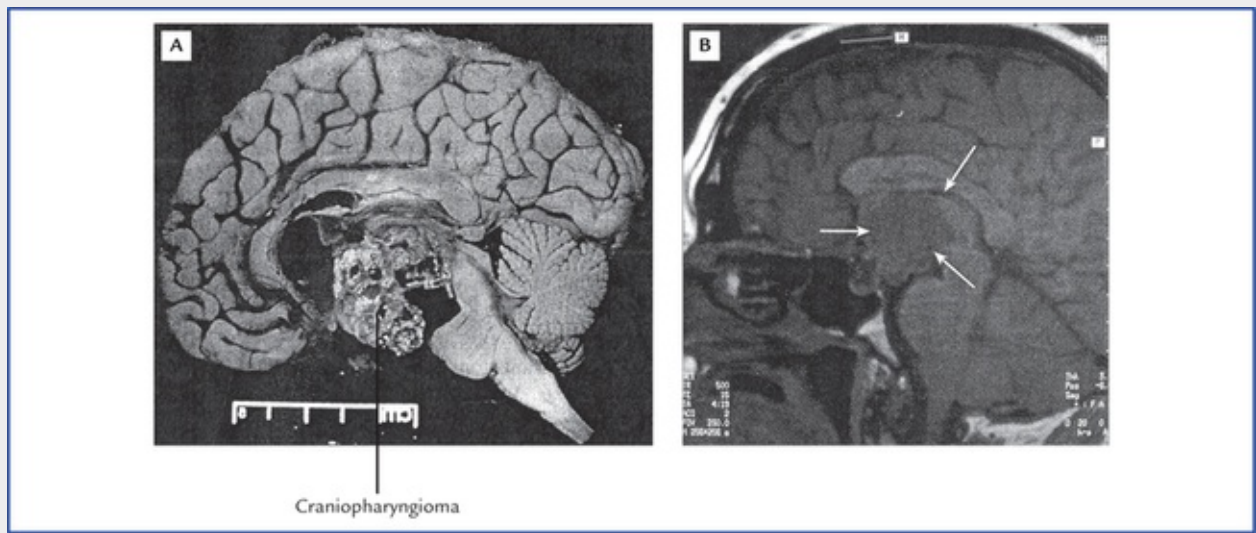


FIG. 11.13 The craniopharyngioma. (A) Pathology specimen showing cystic changes and calcification. (B) MRI—midsagittal section of the brainstem and diencephalon (arrows). *Source: Haslet Christopher, Chilvers, Edwin R, Boon, Nicholas, A, et al. Davidson's Principles and Practice of Medicine. 19th edition. Oxford: Elsevier Science Ltd., 2002*

Third Ventricle

The third ventricle is the cavity of diencephalon. It is a midline slit-like cavity situated between the two thalami and the part of hypothalamus. It extends from the lamina terminalis anteriorly to the superior end of the cerebral aqueduct of midbrain posteriorly. The cavity of third ventricle is lined by a ciliated columnar epithelium, the *ependyma*, and traversed by a mass of grey matter, the *interthalamic adhesion*, connecting the two thalami. The outline of the cavity is very irregular due to the presence of several diverticula or recesses.

Communications

Anteriorly on each side, the third ventricle communicates with the lateral ventricle through *interventricular foramen (of Monro)*, and posteriorly with the fourth ventricle through *cerebral aqueduct (of Sylvius)*. It receives cerebrospinal fluid (CSF) from the lateral ventricles through interventricular foramina and transports it to the fourth ventricle through cerebral aqueduct.

Boundaries (Fig. 11.14)

The third ventricle has anterior wall, posterior wall, roof, floor, and two lateral walls.

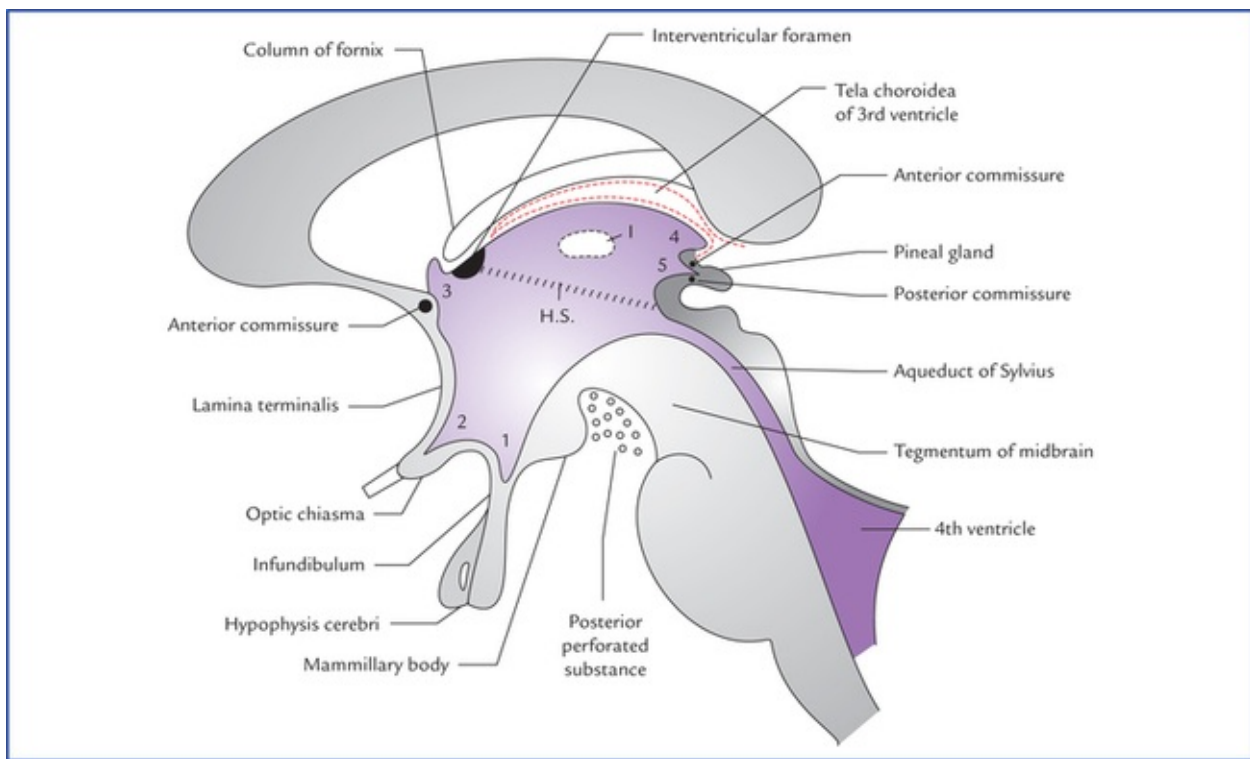


FIG. 11.14 Boundaries and recesses of third ventricle as seen in sagittal section. (HS = hypothalamic sulcus, I = interthalamic adhesion, 1. infundibular recess, 2. optic recess, 3. anterior recess, 4. suprapineal recess, 5. pineal recess.)

Anterior wall is formed from above downwards by,

- anterior column of fornix,
- anterior commissure, and
- lamina terminalis.

Posterior wall is formed from above downwards by,

- pineal gland,
- posterior commissure, and
- commencement of cerebral aqueduct.

Roof is formed by the ependyma that stretches across the upper limits of two thalami. Exactly speaking

the ependyma is reflected from one thalamus to the other at the site of *stria medullaris thalami*. Anteroposteriorly the roof extends from *interventricular foramen* to the *habenular commissure*.

Floor is formed from before backwards by,

- optic chiasma,
- tuber cinereum and infundibulum (pituitary stalk),
- mammillary bodies,
- posterior perforated substance, and
- tegmentum of the midbrain.

N.B. All above structures are the structures of *interpeduncular fossa* except the *optic chiasma* and *tegmentum of the midbrain*.

Lateral wall is marked by a curved sulcus, the *hypothalamic sulcus* extending from the *interventricular foramen* to the cerebral aqueduct. The sulcus divides the lateral wall into a larger upper part and smaller lower part.

- The larger *upper part of the lateral wall* is formed by the medial surface of anterior two-third of the

thalamus.

- The smaller *lower part of the lateral wall* is formed by the hypothalamus and it is continuous with the ventricular floor.

N.B. The two lateral walls of the third ventricle are normally closely approximated, hence in coronal section of the brain, the cavity of the third ventricle appears as a median vertical slit.

Recesses of the Ventricle (Fig. 11.14)

The cavity of third ventricle extends into the surrounding structures as a pocket-like protrusion called recesses. These are as follows:

- **Infundibular recess.** It is a deep tunnel-shaped recess extending downwards through the tuber cinereum into the infundibulum, i.e. the stalk of the pituitary gland.
- **Optic (or chiasmatic) recess.** It is angular recess situated at the junction the anterior wall and the floor of the ventricle just above the optic chiasma.
- **Anterior recess (vulva of ventricle).** It is a triangular recess which extends anteriorly in front of interventricular foramen and behind anterior commissure between the diverging anterior columns of the fornix.
- **Suprapineal recess.** It is a fairly capacious blind diverticulum which extends posteriorly above the stalk of pineal gland and below the tela choroidea.
- **Pineal recess.** It is a small diverticulum, which extends posteriorly between the superior and inferior laminae of the stalk of the pineal gland.

Choroid Plexus and Tela Choroidea of the Third Ventricle

The tela choroidea in the roof of the third ventricle is triangular in shape. The choroid plexus of the third ventricle hangs downwards from the tela choroidea as two longitudinal anteroposterior vascular fringes. The blood vessels contributing to its formation are derived from the anterior choroidal arteries.

Clinical Correlation

- The third ventricle being a narrow slit-like space is easily obstructed by the local brain tumours or congenital defects. The obstruction results in excessive accumulation of CSF inside the brain resulting in an **increased intracranial pressure** in adults and in a **hydrocephalus** in children.
The site of obstruction can be found out by *ventriculography*.
- Tumours in the floor of third ventricle give rise to **hypothalamic syndrome**, consisting of diabetes insipidus, obesity, etc.
- The narrow cavity of the ventricle and its recesses are important in localizing lesions in the central parts of the hemispheres since they manifest as slight deviations from the midline.
- It is important not to interpret the interthalamic adhesion (connexus) as an abnormal mass in transverse CT scans.

Clinical Problems

1. A 55-year-old patient was admitted in the hospital with the complaint of loss of sensation on the left side of the body. A few days later, the patient appeared to be improving and there was an evidence of return of sensation to the left side of his body, but he suddenly started to complain of agonizing pain in his left arm and leg. The pain would start spontaneously or be initiated even by the light touch of the bed sheet or by little exposure to cold. The pain failed to respond even to powerful analgesic drugs. What is the diagnosis and give the cause of the symptoms?
2. A 60-year-old man was admitted in the hospital as a suspected case of cerebral tumour. The neurosurgeon advised X-ray skull AP and lateral views to see for any lateral displacement of the brain within the skull. Name the radiological finding that would indicate the neurosurgeon in detecting lateral displacement.
3. Explain, why the lesions which destroy the pineal gland, lead to precocious puberty.
4. What is the basic difference between **diabetes insipidus** and **diabetes mellitus** and mention the causative factors for these two clinical conditions.
5. Explain, how a tumour or pressure from third ventricle can produce a **central temporal hemianopic scotoma**.

Clinical Problem Solving

1. This patient is suffering from what is called **thalamic syndrome**. It occurs as the patient is recovering from infarction of the thalamus secondary to thrombosis of thalamogeniculate branch of the right posterior cerebral artery. It is characterized by thalamic overreaction particularly to tactile stimuli (also see Clinical correlation on [page 130](#)).
2. The lateral displacement of the shadow of calcified pineal gland will indicate the shift in the position of the brain (for details see Clinical correlation on [page 133](#)).
3. The pineal gland secretes a hormone called **melatonin** which regulates the onset of puberty. It probably holds back the development of gonads until a suitable age has been reached by inhibiting the release of gonadotrophic hormones or their releasing factors. For this reason, the lesions which destroy the pineal gland, lead to precocious puberty.
4. Both in diabetes insipidus and diabetes mellitus there is *polyuria* (that the patient passes excess volume of urine). The basic difference between these two clinical conditions is that, in diabetes mellitus there is glycosuria (i.e. presence of glucose in the urine).
The diabetes insipidus occurs due to impaired secretion of ADH (vasopressin) and diabetes mellitus due to impaired secretion of insulin.
5. Since the decussating macular fibres in the optic chiasma are located just below the supraoptic recess of third ventricle. Therefore, a tumour or pressure from the ventricle pressing on the optic chiasma will produce *central temporal hemianopic scotomas*.

Cerebrum

The cerebrum is the largest part of the human brain that fills most of the cranial cavity. Its large size is the result of a progressive (telencephalization) centralization of the various higher sensory and motor centres of the brain during evolution.

The cerebrum is a heavily, convoluted bilobed structure (Fig. 12.1). The two lateral halves are called **cerebral hemispheres**. When the two cerebral, hemispheres are viewed together from above, they assume the shape of an ovoid mass, which is broader behind than in front. The widest transverse diameter corresponds with a line connecting the two parietal tuberosities.

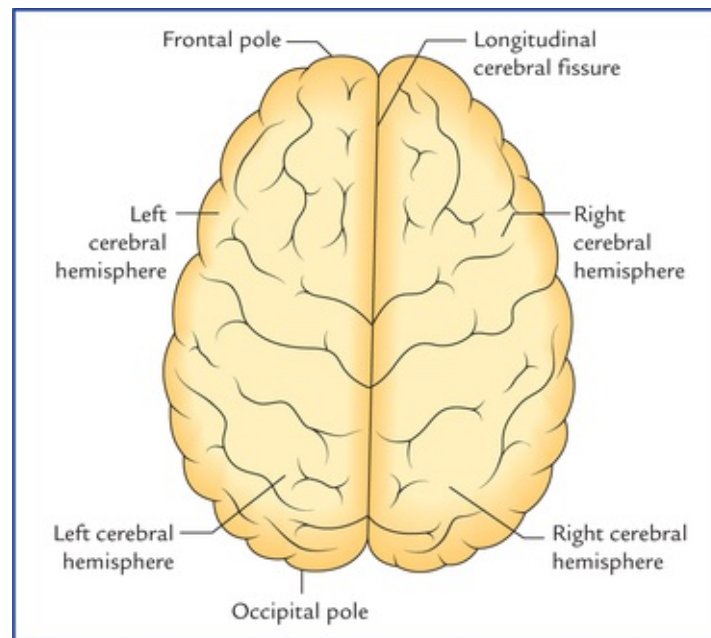


FIG. 12.1 Superior view of the cerebrum.

A deep median cleft, the **longitudinal cerebral fissure**, incompletely separates the two cerebral hemispheres. Both in front and behind, the cleft is complete, but in the central part the cleft extends downwards up to the *corpus callosum* which is a large mass of white fibres joining the two cerebral hemispheres across the median plane.

The longitudinal cerebral fissure is occupied by the following structures:

1. Falx cerebri (a sickle-shaped fold of dura mater).
2. Fold of arachnoid that follows the surfaces of the falx cerebri.
3. Pia mater covering the medial surface of the falx cerebri.
4. Anterior cerebral arteries and veins (which lie in the subarachnoid space between the arachnoid and the pia).

Each cerebral hemisphere consists of: (a) an outer layer of grey matter called **cerebral cortex**, (b) an inner mass of **white matter**, (c) large masses of grey matter embedded in the basal part of the white

matter called **basal ganglia/basal nuclei**, and (d) a cavity within it called **lateral ventricle** (Fig. 12.2).

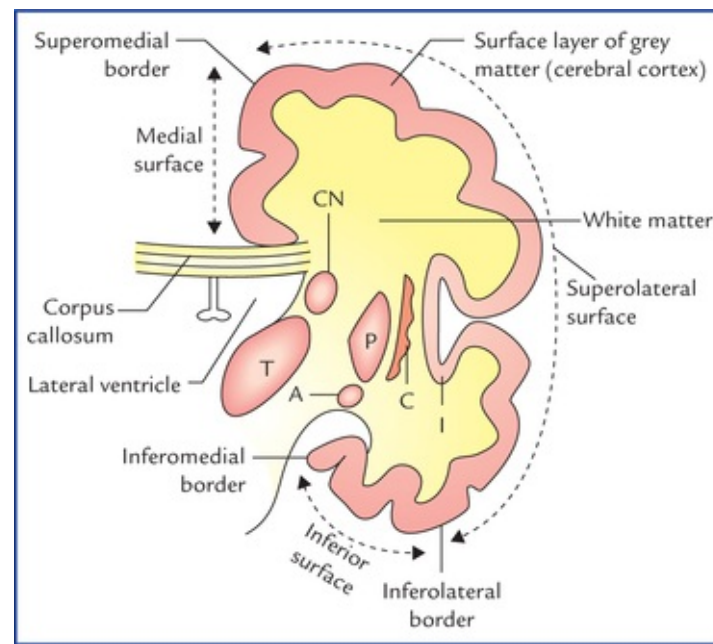


FIG. 12.2 Coronal section of the cerebral hemisphere showing its structure. Also note the borders and surfaces of the cerebral hemisphere. (CN = caudate nucleus, T = thalamus, P = putamen, C = claustrum, A = amygdaloid body.)

External Features of the Cerebral Hemisphere

The **external features of the cerebral hemisphere** include poles, surfaces, borders, sulci, and gyri.

Poles (Figs 12.2 and 12.3)

Each cerebral hemisphere presents three poles – frontal, occipital, and temporal. The anterior end of the hemisphere is the *frontal pole* and the posterior end the *occipital pole*. The *temporal pole* is below and in front at the junction of orbital and tentorial surfaces.

- The **frontal pole** at the anterior end of the hemisphere is more rounded than the occipital pole. It lies opposite the medial part of the superciliary arch.
- The **occipital pole** at the posterior end of the hemisphere is more pointed than the frontal pole. It lies at a short distance superolateral to the external occipital protuberance.
- The **temporal pole** between frontal and temporal poles points forwards. It fits into the anterior part of the middle cranial fossa and is overhung by the lesser wing of the sphenoid.

N.B. The temporal pole is the primitive posterior pole that has curved ventrocaudally for better accommodation during the growth of the cerebrum.

Surfaces

Each cerebral hemisphere has three surfaces – superolateral, medial, and inferior (Fig. 12.2).

1. The **superolateral surface** is most convex and most extensive. It faces upwards and laterally and conforms to the corresponding half of the cranial vault.

- The **medial surface** is flat and vertical. It presents a thick C-shaped cut surface of the *corpus callosum*.
- The **inferior surface** is irregular to adopt the floors of anterior and middle cranial fossae. It is divided into two parts by a deep horizontal groove or sulcus, the *stem of lateral sulcus*, viz. (a) a small anterior part, the *orbital surface*, and (b) a large posterior part, the *tentorial surface*.

Borders

Each cerebral hemisphere presents six borders (Figs 12.2 and 12.3), viz. superomedial, superciliary, inferolateral, medial orbital, medial occipital and inferomedial.

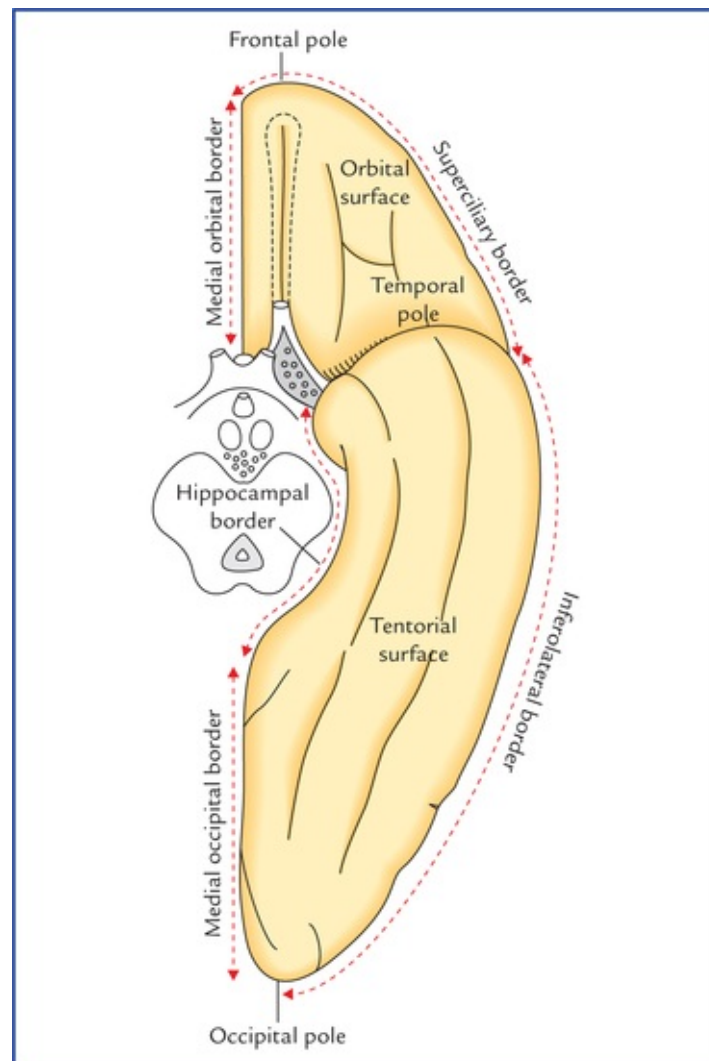


FIG. 12.3 Inferior aspect of cerebral hemisphere showing borders, surfaces, and poles.

- The **superomedial border** separates the superolateral surface from the medial surface.
- The **superciliary border** is at the junction of superolateral and orbital surfaces. It lies just behind the superciliary arch hence its name strictly speaking, it is the orbital part of the inferolateral border.
- The **inferolateral border** separates the superolateral surface from the tentorial surface. Posteriorly this border exhibits a notch, the *preoccipital notch* about 3 cm in front of the occipital pole. This notch is used as a useful surface landmark.
- The **medial orbital border** (Fig. 12.3) separates the medial surface from the orbital surface.
- The **inferomedial/hippocampal border** (Fig. 12.3) surrounds the cerebral peduncle. It is formed by the

medial aspect of the uncus and parahippocampal gyrus.

6. The **medial occipital border** (Fig. 12.3) separates the medial surface from the tentorial surface.

Sulci and Gyri

The **cerebral cortex** (the surface layer of grey matter) is highly extensive in man. To accommodate it in the limited space available within the rigid cranial cavity, the surface of cerebral hemisphere becomes folded, producing numerous **convolutions** separated by **fissures**. These convolutions and fissures are termed **gyri** and **sulci** respectively. In human brain the total surface area of cerebral hemisphere is about 2000 cm but approximately two-third of this is hidden from the surface view within the walls of the sulci.

A brain with convoluted cerebral cortex is termed **gyrencephalic** while the one with smooth cortex, **lissencephalic** (Gk. *lissos* = smooth).

In general, man and other higher mammals have gyrencephalic brain while the reptiles, birds and lower mammals have lissencephalic brain.

The **sulci** vary in depth from slight grooves to deep fissures and some of them are sufficiently deep to indent the wall of the lateral ventricle in the depth of the hemisphere.

The **gyri** consist of a *central core* of white matter (nerve fibres running to and from the overlying cortex) covered by a layer of grey matter, the *cerebral cortex*.

There is a great deal of individual variations in the details of sulci and gyri. Therefore, the following account deals with only some important sulci and gyri.

Main cerebral sulci

Main cerebral sulci are fairly constant in position and shape and include lateral, central, parieto-occipital and calcarine sulci.

Lateral sulcus (of Sylvius) (Figs 12.4, 12.6)

Lateral sulcus is the most conspicuous of all the cerebral sulci and has a *stem* and *three rami*. The stem of the sulcus begins as a deep cleft on the inferior surface of the cerebral hemisphere at the anterior perforated substance and extends laterally between the temporal pole and the posterior part of the orbital surface of the hemisphere. On reaching the superolateral surface it divides into three rami: (a) *anterior horizontal*, (b) *anterior ascending*, and (c) *posterior*.

The *anterior horizontal ramus* is about 2.5 cm long and passes forwards into the inferior frontal gyrus. The *anterior ascending ramus* runs upwards for about 2.5 cm in the same gyrus. The *posterior ramus* (the main part of the sulcus) is about 7.5 cm long and runs posteriorly and slightly upwards across the lateral surface and ends in the inferior parietal lobule by an upturned posterior end.

N.B. The three rami of lateral sulcus diverge from each other at a point called **Sylvian point**.

Central sulcus (of Rolando) (Fig. 12.4)

Central sulcus begins by cutting the superomedial border of the hemisphere about 1 cm behind the midpoint between the frontal and occipital poles, runs sinuously downwards and forwards at an angle of 70° and ends just above the posterior ramus of the lateral sulcus. Its upper end usually extends into the medial surface. The central sulcus forms the boundary between the motor area of the cerebral hemisphere in front and the sensory area behind.

N.B. It is the only sulcus of any length that indents the superomedial border of the hemisphere. This sulcus serves as a key to localize the other sulci and gyri for the pathologist while performing an autopsy.

Calcarine sulcus

Calcarine sulcus is present on the medial surface of the cerebral hemisphere. It begins as a deep fissure, a little below the posterior end of the corpus callosum, the *sple-nium* and follows an arched course with a convexity upwards to the occipital pole and may extend slightly on to the superolateral surface.

Parieto-occipital sulcus

Parieto-occipital sulcus is present on the medial surface of the hemisphere. It begins at the midpoint of the calcarine sulcus and courses upwards and slightly backwards to cut the superomedial border of the hemisphere about 5 cm in front of the occipital pole, and may extend slightly on to the superolateral surface.

Lobes of Cerebral Hemisphere (Fig. 12.4)

To discuss further about sulci and gyri and other aspects of the cerebral hemisphere, the superolateral surface of the hemisphere is arbitrarily divided into four lobes – frontal, parietal, temporal and occipital with the help of: (a) three main sulci, central, lateral and parieto-occipital, and (b) two imaginary lines. The first imaginary line is a vertical line joining the parieto-occipital sulcus to the preoccipital notch, and the second line is a backward continuation of the horizontal part of the posterior ramus of the lateral sulcus till it joins the first line (Fig. 12.4).

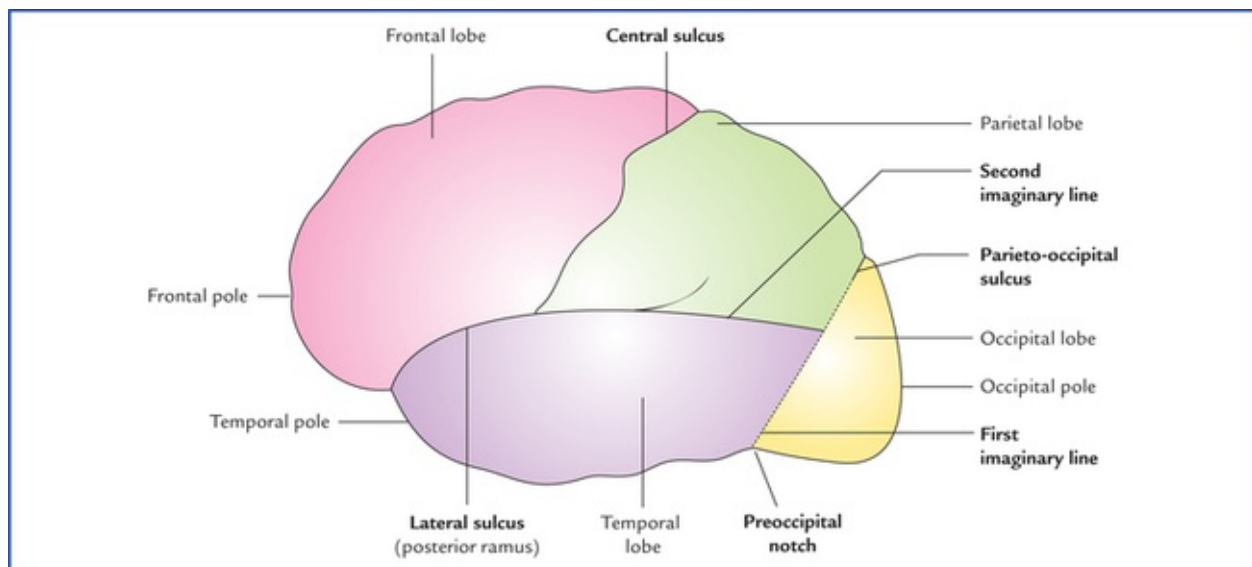


FIG. 12.4 Division of superolateral surface of the left cerebral hemisphere into four lobes.

The **frontal lobe** lies anterior to the central sulcus, and above the posterior ramus of the lateral sulcus.

The **parietal lobe** lies behind the central sulcus and in front of the upper part of the first imaginary line. Below it is bounded by the posterior ramus of lateral sulcus and the second imaginary line.

The **temporal lobe** lies below the posterior ramus of lateral sulcus and second imaginary line. It is separated from the **occipital lobe** by the lower part of the first imaginary line.

The **occipital lobe** lies behind the vertical line joining the parieto-occipital sulcus and preoccipital notch.

Insula/island of Reil (also called central lobe)

It is customary to consider the insula separately from the four main lobes (vide supra) of the cerebral hemisphere.

The insula is the submerged (hidden) portion of the cerebral cortex in the floor of the lateral sulcus (Fig. 12.5). It has been submerged from the surface during development of brain due to the overgrowth of the surrounding cortical areas and can be seen only when the lips of the lateral sulcus are widely pulled apart. It is triangular in shape and surrounded all around by a sulcus, the *circular sulcus* except anteroinferiorly at its apex called *limen insulae* which is continuous with the anterior perforated substance.

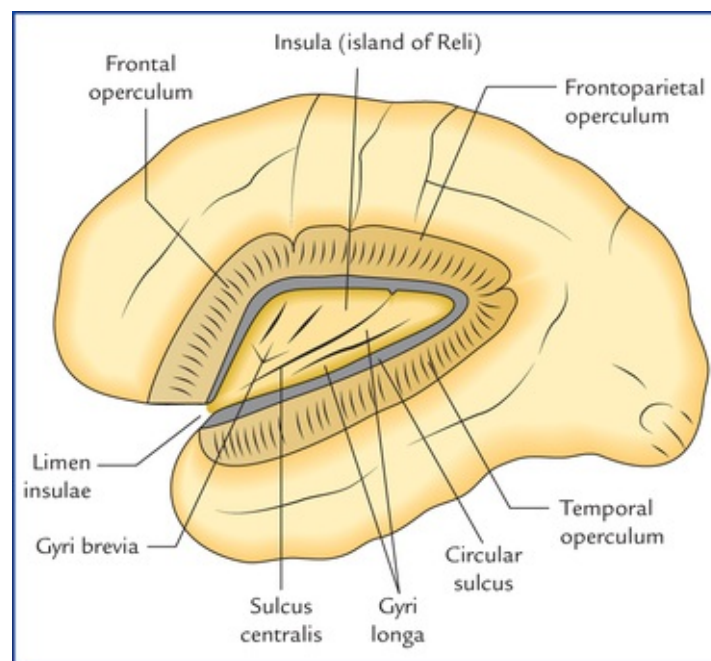


FIG. 12.5 The insula (island of Reil) exposed by removing the opercula. Note: Insula is also called 'central lobe.'

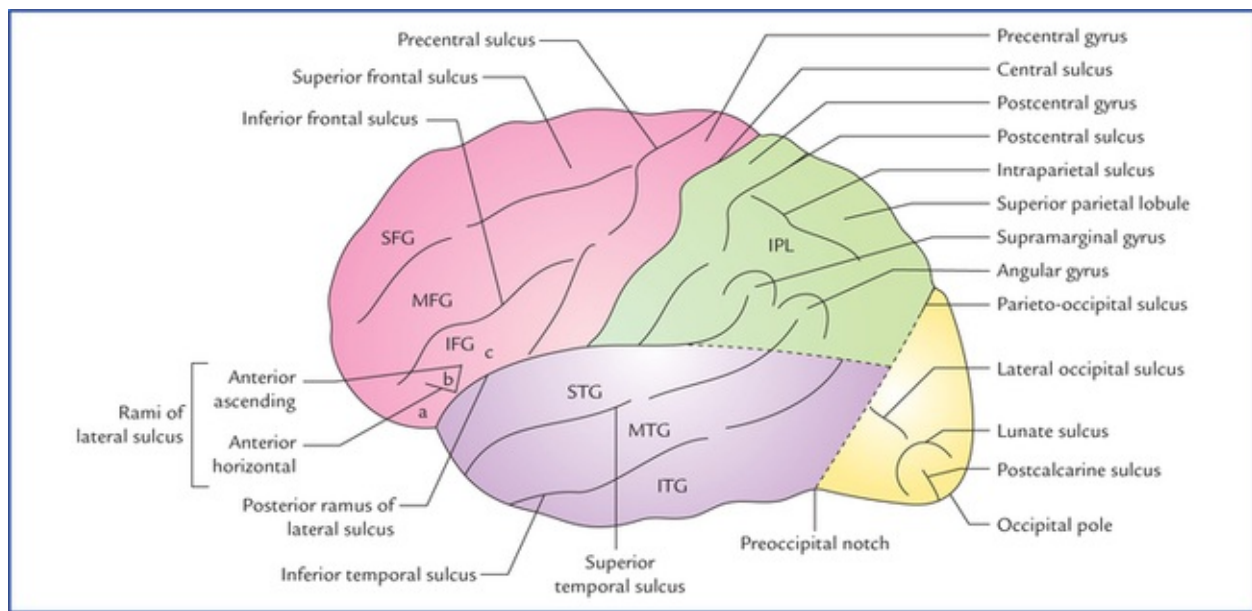


FIG. 12.6 Superolateral surface of the left cerebral hemisphere showing lobes, sulci and gyri. (SFG = superior frontal gyrus, MFG = middle frontal gyrus, IFG = inferior frontal gyrus (a. pars orbitalis, b. pars triangularis, c. pars opercularis), STG = superior temporal gyrus, MTG = middle temporal gyrus, ITG = inferior temporal gyrus, IPL = inferior parietal lobule.)

The insula is divided into two regions – anterior and posterior by a *central sulcus*. The anterior region presents 3 or 4 short gyri called **gyri brevia** and the posterior region presents 1 or 2 long gyri called **gyri longa**.

The insula is hidden from the surface view by the overgrown cortical areas of frontal, parietal and temporal lobes. These areas are termed **frontal, frontoparietal and temporal opercula** (operculum = lid). The superior surface of the temporal operculum presents **anterior and posterior transverse temporal gyri**.

The middle cerebral artery and deep middle cerebral vein lie on the surface of the insula.

Sulci and Gyri on the Superolateral Surface of the Cerebral Hemisphere (Fig. 12.6)

In the frontal lobe

- The *prefrontal sulcus* often broken into two or three parts, runs downwards and forwards parallel and little anterior to the central sulcus. The area between the central and precentral sulci is called *precentral gyrus*.
- Anterior to the precentral sulcus there are two sulci called *superior and inferior frontal sulci* which run horizontally. These sulci divide the region of frontal lobe in front of precentral sulcus into superior, middle, and inferior frontal gyri.
- The *anterior and ascending rami of lateral sulcus* divide the inferior frontal gyrus into three parts. The part below the anterior ramus is called *pars orbitalis*, the part between the anterior and ascending rami the *pars triangularis* and the part posterior to the ascending ramus, the *pars opercularis*.

In the parietal lobe

- The *postcentral sulcus* runs downwards and forwards, a little behind and parallel to the central sulcus.

The area between these two sulci is called the *postcentral gyrus*.

- The rest of the parietal lobe is divided into a *superior* and *inferior parietal lobules* by an *intraparietal sulcus* which runs horizontally backwards from the postcentral sulcus.
- The upturned posterior end of the posterior ramus of lateral sulcus, and the posterior ends of superior and inferior temporal sulci extends into the inferior parietal lobule to divide it into three parts: (a) the part that surrounds the posterior ramus of lateral sulcus is called *supra marginal gyrus*, (b) the part surrounding the superior temporal sulcus, the *angular gyrus*, and (c) the part surrounding the inferior temporal sulcus, the *arcus temporo-occipitalis*.

In the temporal lobe

There are two sulci in this lobe that run parallel to the posterior ramus of the lateral sulcus. These are termed *superior* and *inferior temporal sulci*, and divide the temporal lobe into *superior*, *middle* and *inferior temporal gyri*.

The superior surface of superior temporal gyrus presents two *transverse temporal gyri*. The anterior transverse temporal gyrus also called **Heschl's gyrus** forms the primary auditory area of the cortex.

In the occipital lobe

The occipital lobe possesses rather three short sulci, lateral and transverse occipital sulci and lunate sulcus.

1. *Lateral occipital sulcus* runs horizontally and divides this lobe into superior and inferior occipital gyri.
2. *Lunate sulcus* is C-shaped sulcus with forward convexity just in front of the occipital pole.
3. *Transverse occipital sulcus* runs downwards into the uppermost part of the occipital lobe from the supero-medial border of hemisphere, a little behind the parieto-occipital sulcus.

N.B. The cortex surrounding the parieto-occipital sulcus on the superolateral surface is termed *arcus parieto-occipitalis*. It lies in both parietal and occipital lobes.

Sulci and Gyri on the Medial Surface of the Cerebral Hemisphere (Fig. 12.7)

The presence of *corpus callosum* is the most conspicuous feature seen on the medial surface of the cerebral hemisphere. It is C-shaped thick bundle of commissural fibres. It consists of a *central part*, the *trunk*, a thick posterior end, the *splenium* and curved anterior end, the *genu*.

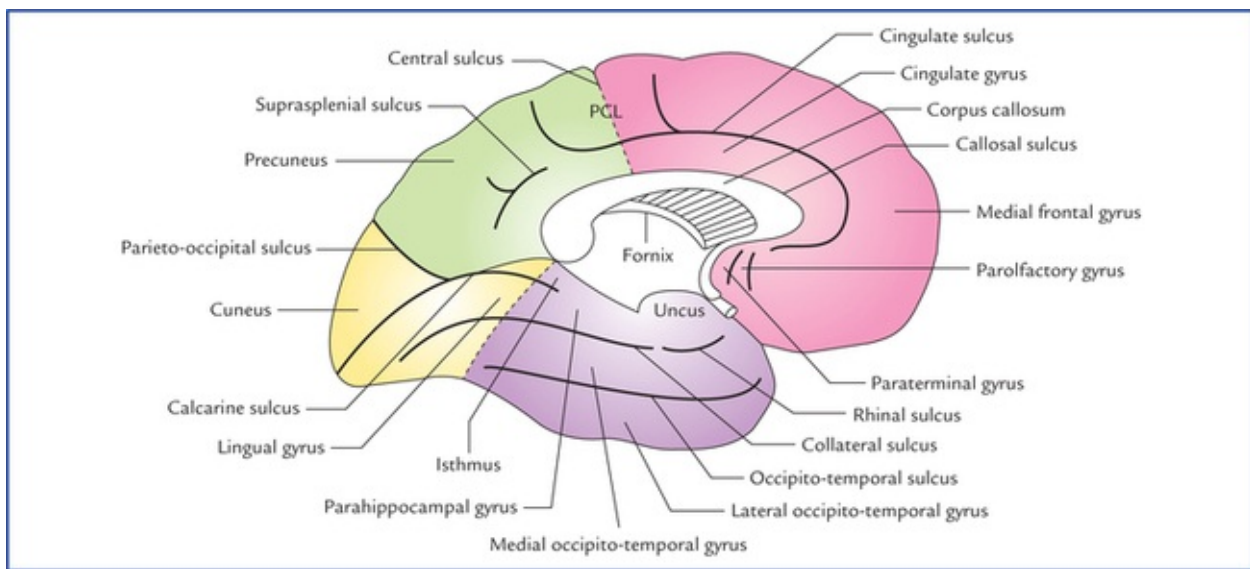


FIG. 12.7 Medial surface of the left cerebral hemisphere showing lobes, sulci and gyri. (Note: In this figure tentorial surface of hemisphere is also seen.) The interrupted lines indicate the approximate boundaries of the lobes. (PCL = paracentral lobule.)

The sulci and gyri on the medial surface are located above, in front and behind the corpus callosum. These are as follows:

- **Cingulate sulcus:** It is the most prominent sulcus which follows a curved course about 1 cm above and parallel to the upper convex margin of the corpus callosum. Anteriorly it ends below the genu of corpus callosum, posteriorly it turns upwards to reach the superomedial border of the hemisphere a little behind the upper end of the central sulcus.

The area between the cingulate sulcus and the corpus callosum is termed *cingulate gyrus*.

- Just in front of lamina terminalis, there are paraterminal and parolfactory gyri and anterior and posterior parol-factory sulci.
- **Callosal sulcus.** It separates the cingulate gyrus from the corpus callosum.
- The part of medial surface between the cingulate sulcus and the superomedial border of hemisphere is divided by a short offshoot sulcus ascending from the cingulate sulcus above the middle of the trunk of corpus callosum into two parts:
 - a small part around the upper part of the central sulcus, the *paracentral lobule*, and
 - a larger medial part the *medial frontal gyrus*.

The boundaries of **paracentral lobule** needs to be elaborated, as it is the **cortical (highest) centre of micturition and defecation**. The paracentral lobule is bounded above, by the superomedial border of the hemisphere, below by the cingulate sulcus, and posteriorly by the upturned posterior end of the cingulate sulcus. The paracentral lobule is invaded by the downturned upper end of the central sulcus.

- The posterior part of medial surface behind the para-central lobule has two main sulci: the calcarine sulcus, and the parieto-occipital sulcus.

(a) **Calcarine sulcus.** It is already described on [page 142](#). A small region between the splenium and calcarine sulcus is termed *isthmus*.

(b) **Parieto-occipital sulcus.** It is already described on [page 142](#).

The triangular area between the posterior part of the cal-carine sulcus (also called **postcalcarine sulcus**) and the *parieto-occipital sulcus* is called *cuneus*.

The quadrangular area between the parieto-occipital sul-cus and paracentral lobule is termed *precuneus*.

A small sulcus a little above and parallel to the splenium is called *suprasplenic sulcus*. It separates the precuneus from the cingulate gyrus.

Sulci and Gyri on the Inferior Surface of the Cerebral Hemisphere (Fig. 12.8)

On the orbital part of inferior surface (orbital surface)

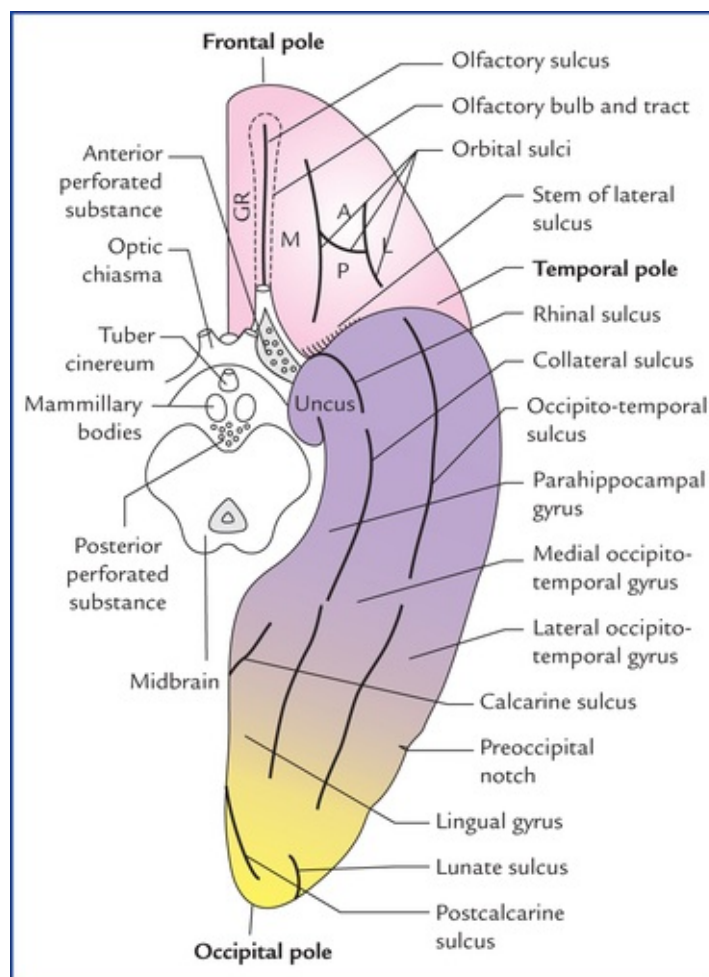


FIG. 12.8 Inferior surface of the left cerebral hemisphere showing various sulci and gyri. Note: Inferior surface is divided into small anterior part, the orbital surface and large posterior part, the tentorial surface. The midbrain has been cut across.

- *Olfactory sulcus*: It is a straight sulcus which runs antero-posteriorly close to the medial border of the orbital surface. It is called olfactory sulcus because it lodges the olfactory bulb and tract. The area medial to this sulcus is called *gyrus rectus*.
- *Orbital sulcus*: It is an irregular H-shaped sulcus and divides the rest of the orbital surface into *anterior*, *posterior*, *medial* and *lateral orbital gyri*.

On the tentorial part of inferior surface (tentorial surface)

The tentorial surface is marked by two major sulci that run anteroposteriorly. The medial one is called *collateral sulcus* and the lateral one, the *occipito-temporal sulcus*. The latter is continuous around the inferolateral margin with the inferior temporal gyrus.

Posteriorly the collateral sulcus is parallel to the calcarine sulcus and here the area between these two sulci is termed *lingual gyrus*. Anteriorly the lingual gyrus is continuous with the **parahippocampal gyrus**. Anterior end of parahippocampal gyrus hooks sharply backwards and is limited laterally by a short *rhinal sulcus*. This hook-like anterior end of parahippocampal gyrus is called **uncus**.

Posteriorly the parahippocampal gyrus is continuous with the cingulate gyrus through the isthmus.

The area between the *occipito-temporal sulcus* laterally and the *collateral* and *rhinal* sulci medially is known as *medial occipito-temporal gyrus*. The area lateral to the occipito-temporal sulcus is termed *lateral occipito-temporal gyrus*. This gyrus is continuous around the infero-lateral margin of the hemisphere with the inferior temporal gyrus.

The Cerebral Cortex

The cerebral cortex is the surface layer of grey matter covering the cerebral hemisphere. The cortex represents the highest degree of evolutionary development of the human brain both in its relative size to other parts of the brain and its range of functions. It is principally responsible for three basic brain functions, viz. perception, adaptation responses, and movement which are common in all animals. In addition it is the site for various types of mental activities like memory, learning, speech and language abilities, intelligence and creative thinking.

In general each cerebral hemisphere controls the opposite half of the body, i.e. it sends motor commands to, and receives sensory information from, the contralateral half of the body. The cortex is highly folded into intricate convexities and grooves to increase its surface area in order to accommodate the large volume of grey matter in the limited space within the cranium which provides for the wide range of mental activities (vide supra) and forms the basis for man's superiority over other animals.

Types of Cerebral Cortex

The cortical areas vary in their phylogenetic scale. The oldest parts form *archicortex*, the recent parts *neocortex*, and those of intermediate origin *paleocortex*.

The archicortex and paleocortex together constitute the **allocortex** (= other cortex).

- **Archicortex:** Phylogenetically it is the oldest and constitutes the sizeable portion of the cerebrum of lower vertebrates. In man this rather primitive cortex is represented by the hippocampus and parts of rhinencephalic regions. Structurally it is simple and made up of three layers.
- **Paleocortex:** Phylogenetically it is intermediate in development and in man it is represented by the cingulate gyrus.
- **Neocortex:** Phylogenetically it is most recent in development and in man it comprises about 90% of the total area of the cerebral cortex. Structurally it is thick and consists of six layers.

Structure of Cerebral Cortex

The cerebral cortex mainly consists of nerve cells, synapses, and neuroglia. The human cerebral cortex contains enormous number (about 14000 millions) of neurons.

Types of Neurons in the Cerebral Cortex

The following five most conspicuous types of neurons present in the cerebral cortex are: (a) pyramidal cells, (b) stellate/granule cells, (c) horizontal cells of Cajal, (d) cells of Martinotti, and (e) fusiform cells (Fig. 12.9). The first two types of cells are the main ones.

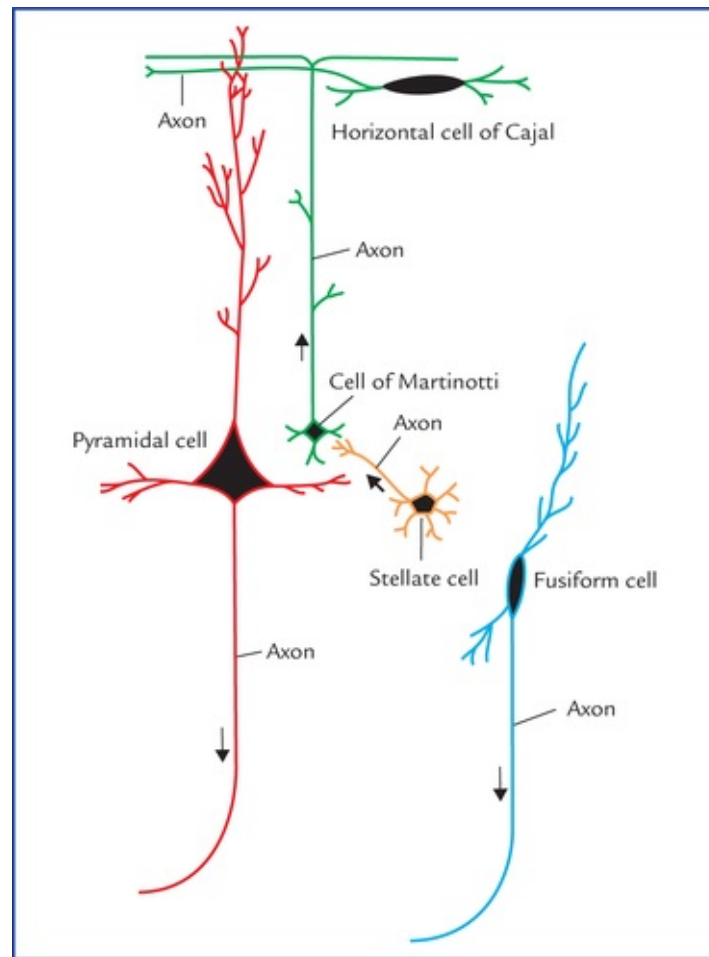


FIG. 12.9 Five main types of neurons in the cerebral cortex.

1. The **pyramidal cells** are pyramidal in shape with their apices directed towards the surface. The axon arises from the base of the cell body while dendrites arise from its apex and basal angles. The axons enter the white matter as *projection fibres*.
According to the size of their cell bodies, they are called small (10 (μm), medium (50 (μm) and large (100–125 (μm) pyramidal cells. The latter are also termed large **pyramidal cells of Betz** (or only **Betz cells**).
2. The **stellate/granule cells** are much smaller than pyramidal cells and their cell bodies measure about 8 μm in diameter. They have star-shaped bodies with short axons and many dendrites. These cells are so small that they appear like granules in Nissl-stained material, hence the name, granule cells. In certain areas of the cerebral cortex, they are so numerous that they resemble a cloud of dust particles and cerebral cortex in these areas is called **koniocortex** (Gk. *Konios* = cloud).
3. The **fusiform cells** have fusiform cell body with their long axis being vertical to the surface. They are concentrated in the deepest cortical layers.
4. The **horizontal cells of Cajal** are fusiform and oriented horizontally. They are found in the most superficial layer of the cortex.
5. The **cells of Martinotti** are small multipolar cells that are present throughout the layers of cerebral cortex.

The cortical neurons connect with other neurons in following three ways:

1. **Projection neurons** transmit impulses to the subcortical centres, viz. corpus striatum, thalamus, brainstem, or spinal cord.
2. **Association neurons** establish connections with the cortical nerve cells elsewhere in the same cerebral hemisphere.
3. **Commissural neurons** proceed to the cortex of the opposite cerebral hemisphere and establish connections between the cortical nerve cells of two cerebral hemispheres.

Layers of the Cerebral Cortex (Fig. 12.10)

The **neocortex** consists of six layers or laminae. From superficial to deep these are as follows:

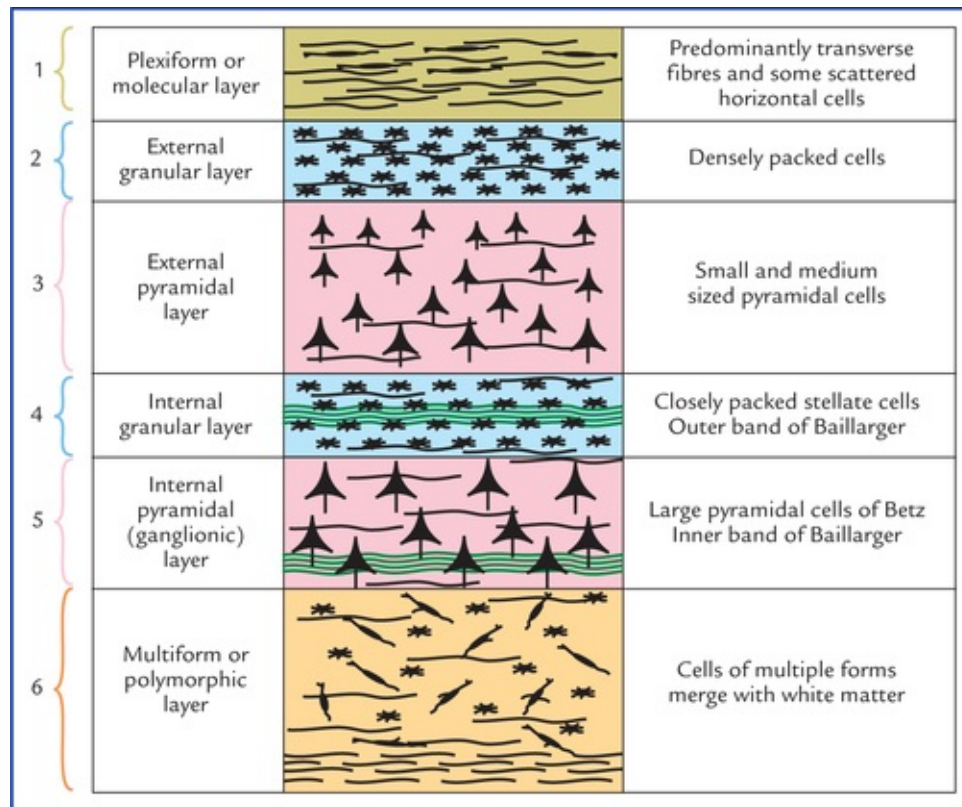


FIG. 12.10 The six layers of the cerebral cortex.

1. **Molecular (plexiform) layer** is made up predominantly of nerve fibres and few scattered horizontal cells of Cajal.
2. **External granular layer** is made up mainly of densely packed stellate (granule) cells.
3. **External pyramidal layer** is made up of small and medium sized pyramidal cells. The sizes of cells increase from superficial to deeper borders of the layer.
4. **Internal granular layer** is made up of closely packed stellate (granule) cells. In the middle of this layer there is a band of horizontally arranged white fibres called **white stria** or *external band of Baillarger*. **The white stria is most marked in the visual cortex, hence visual cortex is also called striate cortex.**
5. **Internal pyramidal (ganglionic) layer** is made up mainly of large pyramidal cells (of Betz). The basal part of this layer contains a thin band of horizontally arranged fibres called *inner band of Baillarger*. These cells account for about 3% of the projection fibres of the *corticospinal (pyramidal) tract*.

6. **Multiform layer (or layer of polymorphic cells)** is made up of cells of multiple forms (i.e. neurons of various sizes and shapes). This layer fuses with the white matter.

Variations in the Cortical Structure

The cerebral cortex shows considerable variation in its structure from region to region both in terms of thickness and prominence of various layers described above. Based on structural variation, the cerebral cortex is classified into following types:

1. **Homotypical cortex:** In this type, all the six layers of cortex are well defined.
2. **Heterotypical cortex:** In this type, all the six layers are not well defined (i.e. there are less than six layers). The heterotypical cortex is further divided into following two types:
 - (a) *Granular cortex:* In this type, the granular layers are well developed while the pyramidal layers are poorly developed. Since the density of granule cells is very high, it is termed granular cortex. **The granular cortex is the characteristic feature of the sensory areas, viz. primary sensory, acoustic, and visual areas.**
 - (b) *Agranular cortex:* In this type, the granular layers are poorly developed while pyramidal layers are well developed with densely packed pyramidal cells. **The agranular cortex is the characteristic feature of the motor areas, viz. primary motor and other areas of the frontal lobe.** The cortex is named agranular due to paucity or absence of granule cells.

Functional Areas of the Cerebral Cortex

The cerebral cortex is demarcated into large number of areas which differ from each other in structure as well as in function. Brodmann (1909) had divided the cerebral cortex into 47 such areas and indicated each of them by a number.

Types of cortical areas: According to the classical teaching, the cerebral cortex possesses three types of functional areas.

1. **Motor areas:** These areas are primarily concerned with the motor functions and give origin to the projection fibres which form corticospinal and corticonuclear tracts.
2. **Sensory areas:** These areas are primarily concerned with the sensory functions and receive afferent fibres from the thalamic nuclei in which major sensory pathways terminate.
3. **Association areas:** These areas are not concerned with primary motor or sensory functions but have more important associative, integrative and cognitive functions. Association areas occupy over 75% of the total surface area of the cerebral cortex in man.

Functional areas in the frontal lobe (Figs 12.11 and 12.12)

Primary motor area (area 4 of Brodmann)

Primary motor area is located in the precentral gyrus on the superolateral surface and extends to the anterior part of paracentral lobule on the medial surface of the cerebral hemisphere. It contains large number of pyramidal cells including large pyramidal cells (of Betz). *About 40% pyramidal (corticospinal and corticonuclear) fibres arise from this area.*

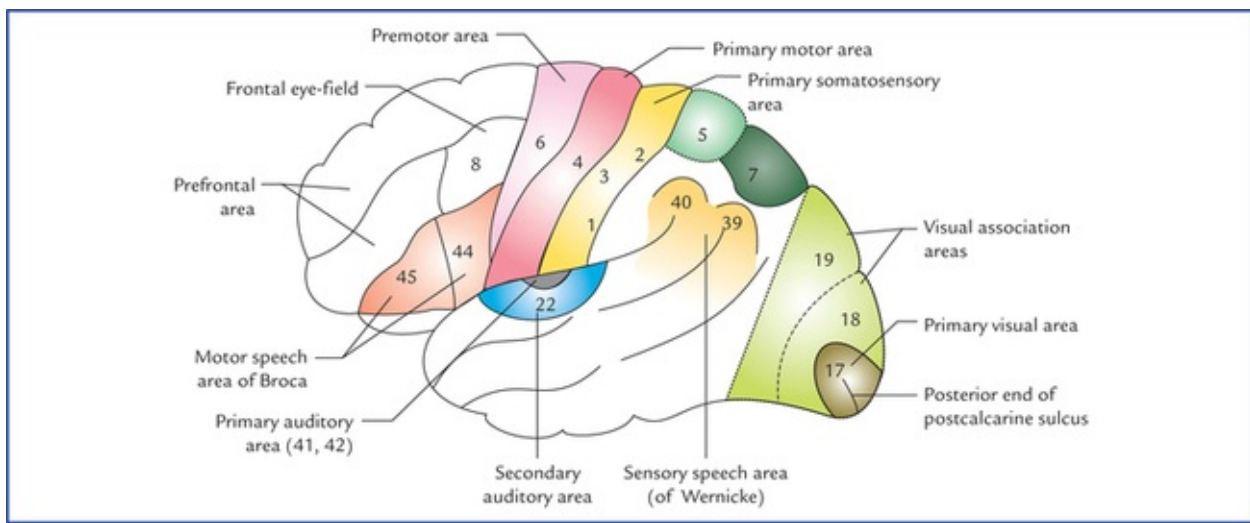


FIG. 12.11 The functional areas on the superolateral surface of the left cerebral hemisphere.

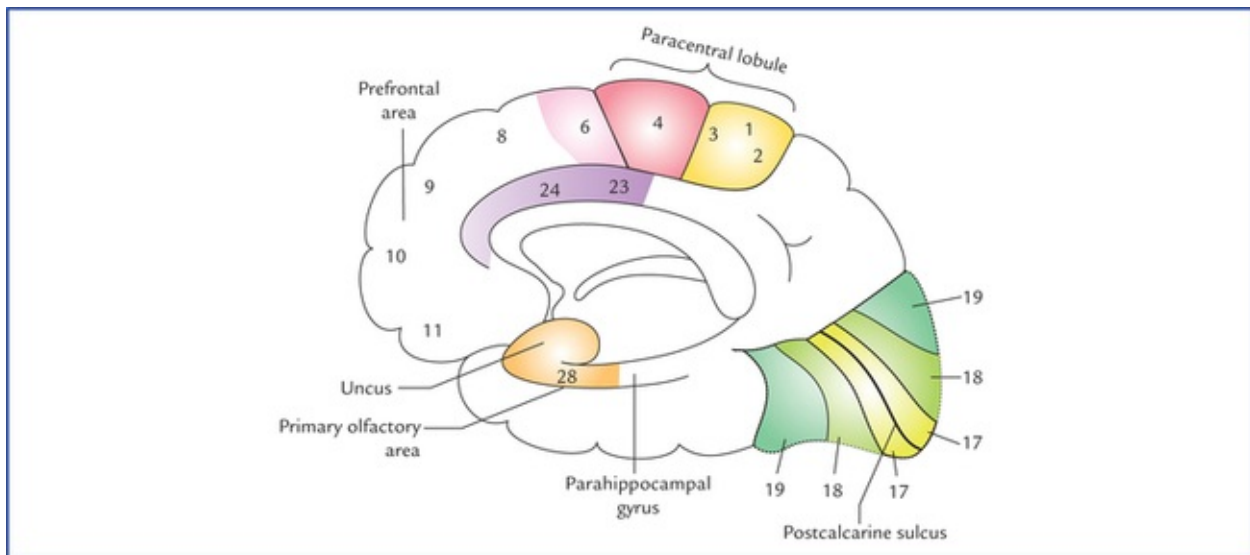


FIG. 12.12 The functional areas on the inferomedial surface of the right cerebral hemisphere.

The electrical stimulation of primary motor area produces contraction of muscles of (mainly) opposite half of the body, i.e. it controls voluntary motor activities of the opposite half of the body.

Although the cortical control of musculature of body is mainly contralateral, there is significant bilateral control of the muscles of the upper part of the face, tongue (genio-glossus), mandible, larynx, pharynx and axial musculature.

Specific regions within the area are responsible for movements in the specific parts of the body. Only movements are represented in this area and not the muscles.

The human body is represented in an upside down manner in the precentral gyrus (**inverted homunculus**) as shown in Figure 12.13. The pharyngeal region and tongue are represented in the lowermost part, followed by face, hand, trunk and thigh. The legs, feet and perineum are represented on the medial surface of the hemisphere in the paracentral lobule.

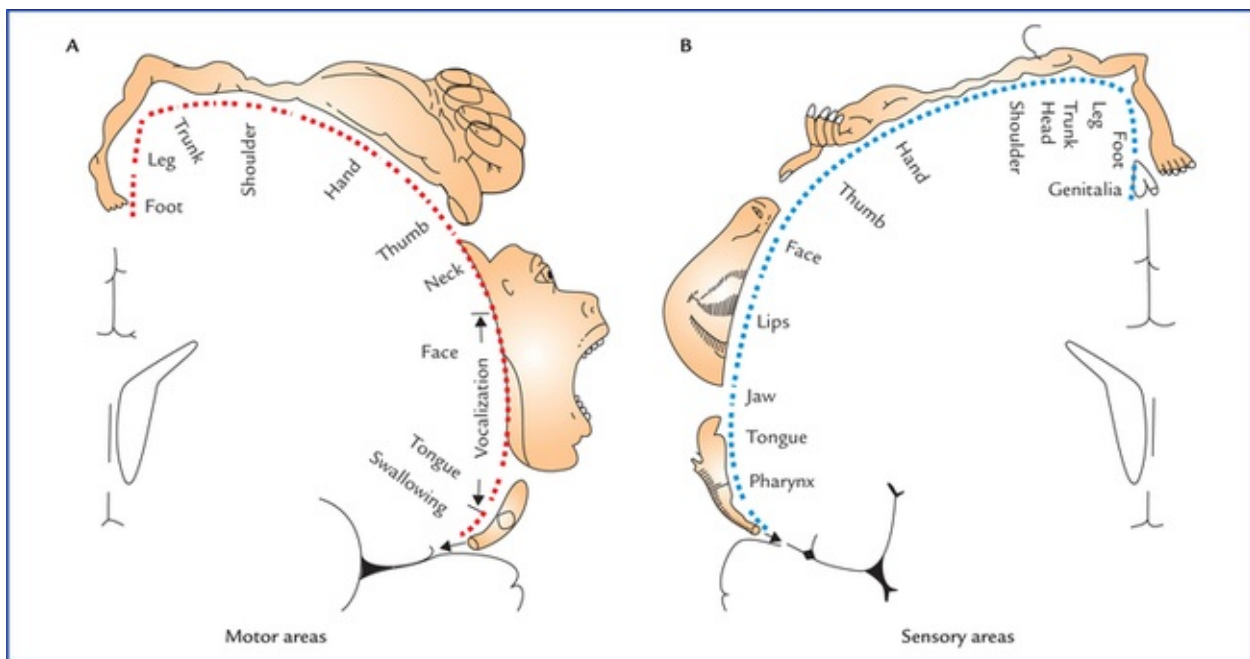


FIG. 12.13 The motor (A) and sensory (B) homunculi showing proportional somatotopical representation in the main motor and sensory cortex (after W. Penfield and T. Rasmussen, 1950).

Further, there is disproportionate registration of the individual parts. The area of cortex controlling a particular movement is proportional to the skill involved in performing that movement and not to the bulk of muscle participating in the movement. Thus, face especially the lips, tongue, larynx and hand have disproportionately larger areas while the trunk and lower limb have smaller areas.

Clinical Correlation

The lesions of primary motor area in one hemisphere produce flaccid paralysis of the extremities of the opposite half of the body (**hemiplegia**). The masticatory, laryngeal, pharyngeal, upper facial and extraocular muscles are spared for being represented bilaterally.

Premotor area (area 6 of Brodmann)

Premotor area is located anterior to the primary motor area in the posterior parts of superior, middle and inferior frontal gyri and extends on to the medial surface of the hemisphere. The premotor area is wider above than below and lacks the giant pyramidal cells (of Betz). *It is the main site for the cortical origin of extrapyramidal (corticorubral, cortico-olivary, corticonigral, etc.) fibres.*

The premotor area is responsible for successful performance of the voluntary motor activities. In fact, the primary motor area receives numerous inputs from the sensory cortex, the thalamus and the basal ganglia. It stores the programmes of motor activity assembled as a result of past experience. The premotor area thus appears to be responsible for programming the intended movements of the primary motor area, and controlling the movements in progress.

Clinical Correlation

The lesions of premotor (secondary motor) area produce difficulty in the performance of skilled movements.

N.B. The premotor and primary motor areas together are referred to as the primary somatomotor area (MsI) (Fig. 12.14).

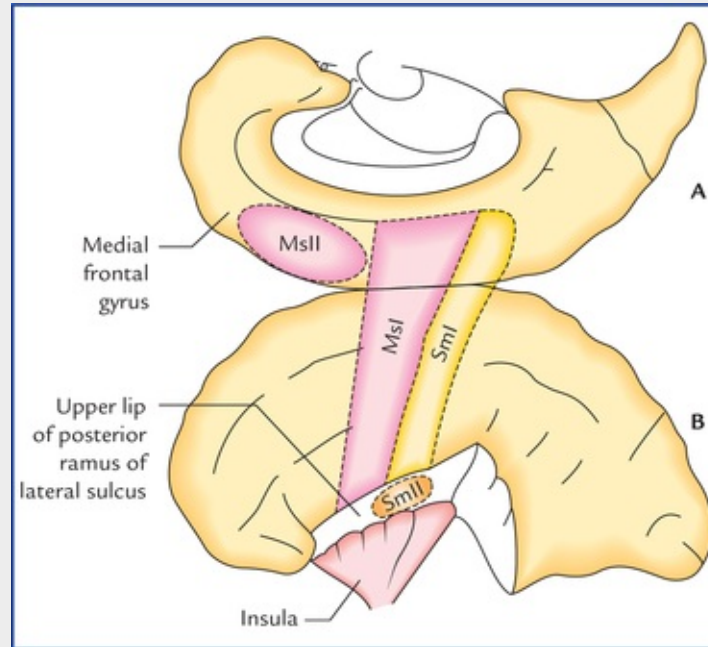


FIG. 12.14 The main sensorimotor areas are projected diagram-matically upon the superolateral (**B**) and medial (**A**) surfaces of the cerebral hemisphere. Note: Primary (or first) somatomotor area includes both primary motor area and premotor area (MsI), the supplementary motor area is located in the medial frontal gyrus on the medial surface (MsII). Primary somatosensory area is located in postcentral gyrus (SmI) and second somatosensory area is located in the upper lip of the posterior ramus of lateral sulcus (SmII).

Supplementary motor area (MsII)

Supplementary motor area is located in the medial frontal gyrus on the medial surface of the hemisphere anterior to the paracentral lobule (Fig. 12.14). The body is represented from before backwards in craniocaudal order.

The stimulation of supplementary motor area produces complex movements, some are described as 'assumption of posture' with bilateral effects, including turning the head, assuming positions of trunk and lower limb, etc.

Clinical Correlation

Lesions of supplementary motor area produce bilateral flexor hypotonia with no paresis or paralysis.

Frontal eye field (area 8 of Brodmann)

The frontal eye field is located in the posterior part of the middle frontal gyrus just anterior to the facial area of the precentral gyrus. The electrical stimulation of this region causes deviation of both the eyes especially to the opposite side (**conjugate movements of the eyes**). *The frontal eye field controls voluntary scanning movements of the eyes and is independent of the visual stimuli.* The frontal eye field is connected to the visual area of occipital cortex by association fibres.

N.B. The involuntary following of moving objects by the eyes involves the visual area of the occipital cortex.

Clinical Correlation

Lesions of the frontal eye field of one hemisphere cause the two eyes to deviate to the side of lesion and an inability to turn the eyes to the opposite side. The involuntary tracking movement of the eyes when following moving objects is unaffected since the lesion does not involve the visual cortex of the occipital lobe.

Motor speech area of Broca (areas 44 and 45 of Brodmann)

The motor speech area of Broca is located in the pars triangularis (area 45) and pars opercularis (area 44) of inferior frontal gyrus of frontal lobe of left hemisphere (**dominant hemisphere**) in most of the individuals, and the persons are right handed. However, in 30% cases it is present in the right hemisphere and persons are left handed. Broca's area is responsible for the production of expressive speech/vocalization. It brings about the formation of words by its connections with the adjacent primary motor area, which in turn appropriately stimulate the muscles of the larynx, mouth, tongue, soft palate, and the respiratory muscles.

Clinical Correlation

The lesions of motor speech area of Broca result in loss of ability to produce speech, i.e. **expressive aphasia** (also called **motor aphasia**). The patients, however, retain the ability to think about the words they wish to say, they can write the words, and they can understand their meaning when they see or hear them.

Thus, although the language is understood, it cannot be expressed in speech even though there is no paralysis of muscles of lips, tongue, and vocal cords, etc.

Prefrontal area

The part of the frontal lobe rostral to the motor and pre-motor areas is referred to as *prefrontal area*. *This area is concerned with the individual's personality.* It exerts its influence in determining the initiative and judgement of an individual. *It is also concerned with depth of emotions, social, moral and ethical awareness, concentration, orientation, and foresightedness.*

It is an area of the cerebral cortex that is capable of associating experiences that are necessary for the production of abstract ideas.

Clinical Correlation

Bilateral destruction of prefrontal areas due to trauma or tumours results in profound change in personality. There is loss of concentration, initiative and judgement. The individual no longer conforms to the accepted mode of social behaviour and becomes careless about his dress and appearance (i.e. inappropriate social behaviour), e.g. use of obscene language, urinating in public.

Functional areas in the parietal lobe

Primary sensory area (areas 3, 1 and 2 of Brodmann)

Primary sensory area is located in the postcentral gyrus and extends into the posterior part of the paracentral lobule on the medial surface of the hemisphere. The opposite half of the body is represented up-side down exactly in same fashion as in the primary motor area (Fig. 12.13). Similarly, the area of cortex assigned for a particular part is not proportional to the size of that part but to its functional significance (i.e. to the intricacies of sensations received from it). Thus, the thumb, fingers, lips and tongue have a disproportionately large representation. *The primary sensory area is concerned with the perception of extero-ceptive (pain, touch and temperature) and proprioceptive (vibration, muscle and joint sense) sensations from the opposite half of the body.* However, sensations from pharynx, larynx and perineum go to both sides.

The primary sensory area receives projection fibres from ventral posterolateral (VPL) and ventral posteromedial (VPM) nuclei of the thalamus.

Clinical Correlation

Lesions of primary sensory area lead to the loss of appreciation of exteroceptive and proprioceptive sensations from the opposite half of the body. The crude pain, temperature and touch sensations often return, but this is believed to be due to functions of the thalamus.

Secondary sensory area (S_{II})

Secondary sensory area is located in the upper lip of the posterior ramus of the lateral sulcus. The face area lies most anterior and the leg area is posterior. The whole body is represented bilaterally. This area relates more to the pain perception.

The ablation of this area may relieve intractable pain.

Sensory association area (Fig. 12.11)

Sensory association area occupies the superior parietal lobule corresponding to the Areas 5 and 7 of

Brodmann. *It is concerned with the perception of shape, size, roughness, and texture of the objects.* Thus, it enables the individual to recognize the objects placed in his/her hand without seeing. Such ability is referred to as *stereognosis*.

Clinical Correlation

Lesions of this area result in inability to recognize or identify an object by its feel. This condition is called **tactile agnosia** or **astereognosis**.

Sensory speech area of Wernicke (Fig. 12.11)

Sensory speech area is located in the left dominant hemisphere occupying the posterior part of the superior temporal gyrus of temporal lobe and angular (area 39) and supramarginal (area 40) gyri of the inferior parietal lobule.

The Wernicke's area is concerned with the interpretation of language through visual and auditory input. It is also an essential zone for constant availability of the learned word patterns.

N.B. *The sensory and motor speech areas exist together in one hemisphere only. The Wernicke's area is connected to the Broca's area by a bundle of nerve fibres called **arcuate fasciculus**.*

Clinical Correlation

Lesions of Wernicke's area in the dominant hemisphere produce loss of ability to understand the spoken and written speech. This condition is called **receptive sensory aphasia**. Since Broca's area is unaffected, the expressive speech is unimpaired and the individual can produce a fluent speech. However, he is unaware of the meaning of the words he uses consequently he uses, incorrect words or even non-existent words. The person is unaware of his mistakes. To the others his speech sounds like an incomprehensible foreign language.

The angular and supramarginal gyri are essential for the process of learning such as reading, writing, and computing. The lesions of these areas produce wide variety of aphasic disorders, like disabilities in reading (*alexia*), writing (*agraphia*), computing (*acalculia*), and recognition of names of the objects (*anomia*).

Lesions involving both Broca's and Wernicke's speech areas result in loss of the production of speech as well as loss of understanding of the spoken and written speech. This condition is called **global aphasia**.

The motor and sensory aphasias are compared in the [Table 12.1](#).

Table 12.1
Comparison between motor and sensory aphasias

	Motor (Broca's) aphasia	Sensory (Wernicke's) aphasia
Site of lesion	Posterior part of inferior frontal gyrus (areas 44, 45)	Posterior part of superior temporal gyrus and adjoining part of inferior parietal lobule (areas 22, 39, and 40)
Speech	Effortful, dysarthric, telegraphic, and nonfluent	Fluent
Comprehension of spoken speech	Good	Poor
Ability to read, write, and calculate	Intact	Lost
World blindness (inability to comprehend written speech)	Absent	Present

Further Consideration of Motor and Sensory Areas

Recently it has been found that both motor and sensory areas are not exclusively motor or sensory but sensorimotor in nature. The motor areas are predominantly motor while the sensory areas are predominantly sensory, and they are abbreviated as **Ms** and **Sm** respectively, according to *relative* significance of their functional attributes. Thus, primary somatomotor area is abbreviated as MsI, supplementary motor area as MsII, first somatosensory area as SmI and second somatosensory area as SmII (Fig. 12.11).

Functional areas in the temporal lobe

Primary auditory area (Brodmann's areas 41 and 42)

Primary auditory area is located in the inferior wall of the lateral sulcus, and to be very specific on the superior surface of the superior temporal gyrus occupying the anterior transverse temporal gyrus (**Heschl's gyrus**) and extends slightly to the adjacent part of the superior temporal gyrus (Fig. 12.11).

The primary auditory area receives input from the medial geniculate body through auditory radiations. The medial geniculate body receives input from organ of Corti in the cochlea of inner ear of both the sides but mainly from the opposite side. This area is concerned with the reception of isolated impressions of loudness, quality and pitch of the sound. In addition it also picks up the source of the sound.

Clinical Correlation

Unilateral lesions of the primary auditory area result in slight loss of hearing because it receives auditory input from the cochleae of both sides, but loss will be greater in the opposite ear. Bilateral lesions of the primary auditory areas cause complete cortical deafness.

Secondary auditory area/auditory association area (Brodmann's area 22)

Secondary auditory area is situated on the lateral surface of the superior temporal gyrus slightly posterior to the primary auditory area which it surrounds (Fig. 12.9). It receives auditory impulses from primary auditory area and correlates them with the past auditory experiences. Thus, this area is necessary for the interpretation of the sound heard.

Clinical Correlation

The lesions of secondary auditory area result in an inability to interpret the meaning of the sounds heard, and the patient may experience **word deafness (auditory verbal agnosia)**.

Functional areas in the occipital lobe

Primary visual area/striate area (Brodmann's area 17)

Primary visual area is situated in the walls and floor of the posterior part of the calcarine sulcus (postcalcarine sulcus) and may extend around the occipital pole on to the superolateral surface of the hemisphere.

*The most marked structural feature of the visual cortex is the presence of white stria (**visual stria of Gennari**), hence the name, the striate area.* The visual cortex is relatively thin and contains huge amount of granule cells.

The visual cortex receives afferent fibres from lateral geniculate body via geniculocalcarine tract/optic radiations. The visual cortex receives fibres from temporal half of the ipsilateral retina and the nasal half of the contralateral retina. Thus, right half of the field of vision is represented in the visual cortex of the left cerebral hemisphere and vice versa. It is also important to note that impulses from the superior retinal quadrants (inferior field of vision) pass to the superior wall of the calcarine sulcus, while the inferior retinal quadrants (superior field of vision) pass to the inferior wall of the calcarine sulcus.

The **macular area** which is the central area of retina and responsible for maximum visual acuity (**keenest vision**) has extensive cortical representation, occupying approximately posterior one-third of the visual cortex.

The primary visual area is concerned with reception and perception of isolated visual impressions like colour, size, form, motion, illumination and transparency.

Clinical Correlation

Lesions of the primary visual area result in the loss of vision in the opposite visual field (*crossed homonymous hemianopia*). The unilateral lesions of superior wall of postcalcarine sulcus result in **inferior quadrantic hemianopia**, whereas lesions involving inferior wall of postcalcarine sulcus result in **superior quadrantic hemianopia**.

The most common causes of these lesions are vascular accidents, tumours and injuries from gunshot wounds.

***N.B.** A common finding with most of the lesions of occipital cortex is loss of peripheral vision with normal macular vision, called **macular sparing**. This is because:*

- The macular representation in the occipital cortex is separate and far greater than the peripheral part of the retina (the peripheral part of retina is represented anteriorly and macula posteriorly in the occipital cortex (mainly in the occipital pole). Therefore, occipital lesions must extend for a considerable distances to destroy macular as well as

peripheral vision.

- The lesions of visual cortex usually occur due to thrombosis of posterior cerebral artery (calcarine branch). The visual cortex representing macula is spared because this is the site where the areas of distribution of posterior and middle cerebral arteries meet, hence this area may receive blood supply from middle cerebral artery even if the posterior cerebral artery is blocked.
- Patient's shifting of the eyes very slightly while the visual fields are being tested by an ophthalmologist.

Secondary visual area/visual association area (Brodmann's areas 18 and 19)

The secondary visual area surrounds the primary visual area and occupies most of the remaining visual cortex on the medial and superolateral surfaces of the cerebral hemisphere (Figs 12.11 and 12.12).

This area receives afferent fibres from primary visual area. It relates the visual information received from primary visual area to the past visual experiences, thus enabling the individual to recognize and appreciate what he is seeing. In other words, the secondary visual area is responsible for recognition of the objects seen.

Clinical Correlation

Lesions of the secondary visual area result in a loss of ability to recognize objects (**visual agnosia**) seen in the opposite field of vision.

Other functional areas in the cerebral cortex

- **Taste area** (gustatory area) is located in the inferior part of the parietal lobe, posterior to the *general sensory* area for the mouth or in the lower end of the postcentral gyrus in the superior wall of the lateral sulcus or in the adjoining area of the insula (**Brodmann's area 43**).
- **Vestibular area** is probably located near that part of the postcentral gyrus which is concerned with the sensations of the face.
- **Olfactory area (Brodmann's area 28)** is located in the anterior part of the parahippocampal gyrus and uncus.

Cerebral Hemispheric Dominance

In spite of an apparent congruity in size, shape and features of the left and right cerebral hemispheres, they are not 'mirror images' as far as certain neuronal activities are concerned. There are certain established functional differences between the two hemispheres (certain brain functions are lateralized. Each hemisphere has its own contributions, none is more important than the other).

The left hemisphere is more efficient as far as handed-ness, perception of language, speech, writing and calculation (numerical skills) are concerned. The right hemisphere is more efficient with spatial

perception (geometrical and spatial relationships), recognition of faces, creative acts of arts and music, and non-verbal ideation (Fig. 12.15).

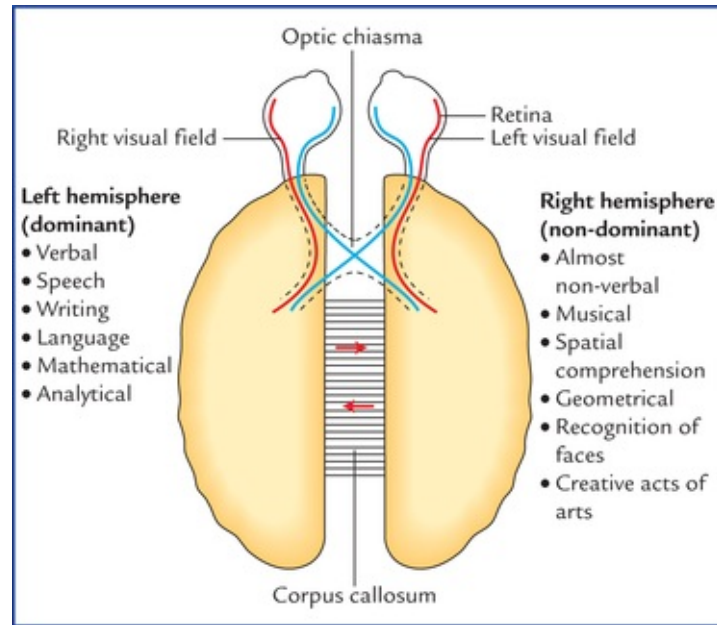


FIG. 12.15 Lateralization of functions in the dominant and non-dominant hemispheres.

The term **dominant hemisphere** refers to the side concerned with the perception and production of language/ speech. According to this concept, the left hemisphere is dominant in over 90% of people, in whom the right hemisphere is described as the **minor** or **non-dominant hemisphere**.

The left hemisphere controls the right side of the body, including the skilful right hand. Consequently over 90% of the adult population is right-handed.

During childhood, one hemisphere slowly comes to dominate over the other, and it is only after the first decade that the dominance becomes fixed.

Clinical Problems

1. What do you understand by cerebral hemispheric dominance? Mention its anatomical basis.
2. Explain why a 5-year-old child with damage in his dominant hemisphere can easily learn to become left handed and speak well, whereas in the case of an adult this is difficult.
3. A 55-year-old Dean of a medical institute received a severe blow on his head that caused a depressed fracture of his frontal bone. He was admitted in the hospital and discharged after 72 hours of observation. He joined his duty but in a few days the faculty members and students noticed that dean's social behaviour has changed dramatically. He no more dresses himself properly and lacks initiative and drive. He also lacked inhibition and one day he was seen urinating in the dustbin of his office. Explain the cause of his altered behaviour and personality?
4. A 62-year-old man on recovering from a cerebral stroke found that he has difficulty in understanding the spoken speech, although he understands written speech well. Mention which area of the cerebral cortex is involved?

5. An elderly patient has difficulty in understanding the written speech but he can easily understand the spoken speech. Mention which area of cerebral cortex is damaged?
6. Trace the neural pathway needed for a blind folded person to name an object placed in his right hand.

Clinical Problem Solving

1. See [page 153](#).
2. In newborns both the hemispheres have equal potential to perceive and produce speech. But as they grow, one hemisphere slowly comes to dominate the other due to continuous learned behavioural stimulus to the left hemisphere, and it is only after the first decade that the dominance becomes fixed.
3. The abnormal behaviour and personality changes noticed in dean were due to a severe lesion involving the prefrontal areas of both frontal lobes of cerebrum secondary to the depressed fracture of the frontal bone (also see [page 151](#)).
4. *Secondary auditory area (Brodmann's area 22)*, because this area receives auditory impulses from primary auditory area and correlates them with the past experience, then this information is passed on to the *sensory speech area of the Wernicke* which permits the understanding of the spoken speech (see also [pages 150](#) and [151](#)).
5. Secondary visual area, because this area correlates the visual impulses received from the primary visual area to the past experiences. Then this information is passed on to the Wernicke's area for understanding the written speech.
6. Right hand → Spinal cord → Primary sensory area of dominant hemisphere → Wernicke's area (object is given name) → Broca's area → Premotor and motor areas → muscles involved in production of speech.

Basal Nuclei (Basal Ganglia)

The basal ganglia are the large masses of grey matter situated within the white core of each cerebral hemisphere and form essential constituents of the extrapyramidal system. The basal ganglia are now recognized as basal nuclei, but the former term is still commonly used.

Anatomically, the term basal ganglia include:

- Corpus striatum,
- Claustrum, and
- Amygdaloid body.

Functionally, the term basal ganglia also include substantia nigra and subthalamus. Some workers also include red nucleus.

The basal nuclei are important in organizing and coordinating somatic motor activities especially willed movements. They are also involved in automatic stereotyped postural and reflex motor activities such as normal individuals swing their arms when they walk.

Corpus Striatum

The corpus striatum is situated lateral to the thalamus. Topographically it is almost completely divided into the **caudate nucleus** and the **lentiform nucleus** by a band of nerve fibres, the *internal capsule*. However, anteroinferior ends of these nuclei remain connected by a few bands of grey matter across the anterior limb of internal capsule. These bands give it a striated appearance, hence the name corpus striatum (Figs 13.1–13.3).

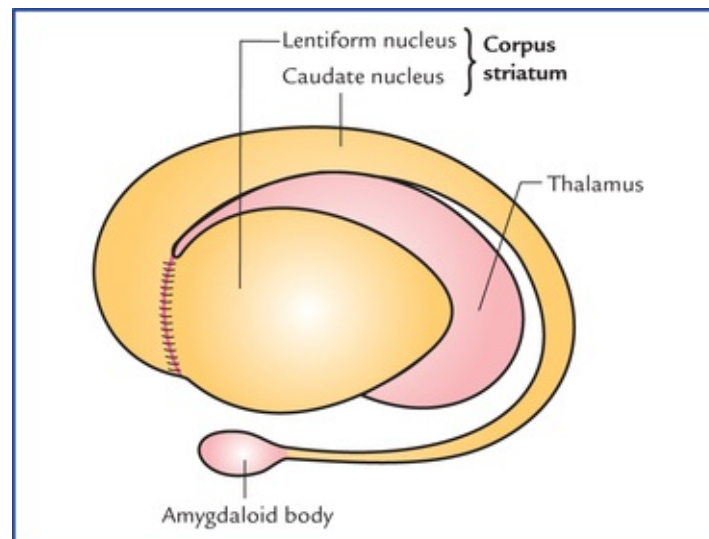


FIG. 13.1 Lateral aspect of the left corpus striatum.

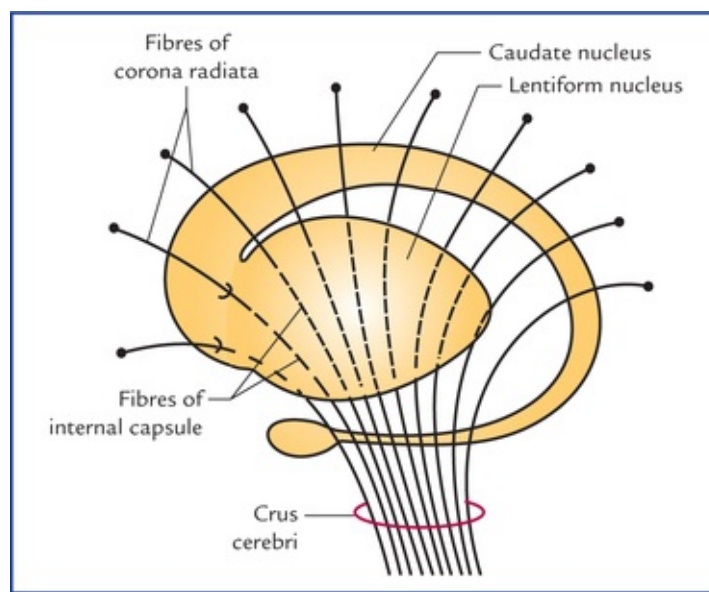


FIG. 13.2 Relationship of the corpus striatum to the internal capsule.

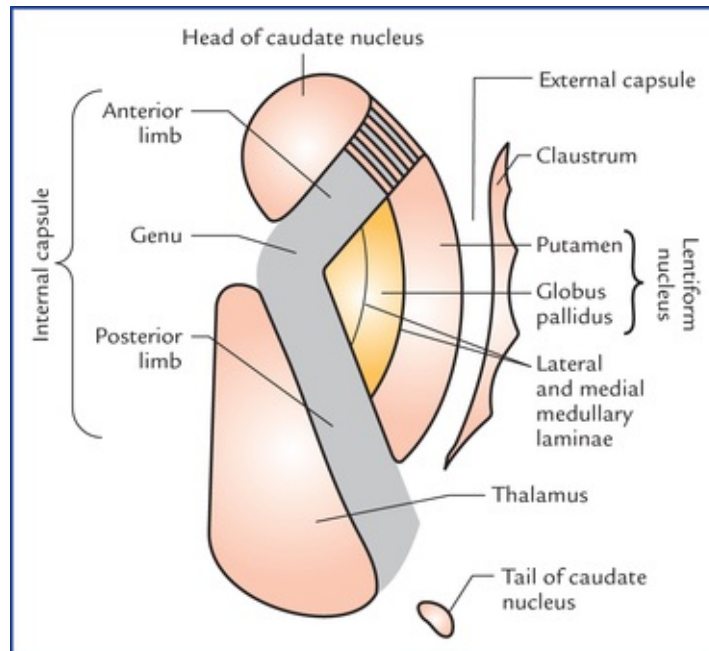


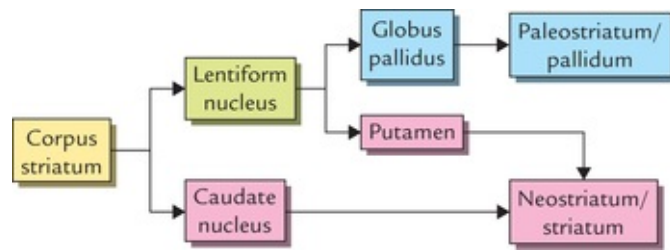
FIG. 13.3 Corpus striatum, thalamus, claustrum and internal capsule as seen in horizontal section of the cerebral hemisphere.

The lentiform nucleus consists of two parts: a darker lateral part *putamen* and a medial paler part *globus pallidus*.

Phylogenetically corpus striatum forms two distinct functional units, the **paleostriatum** and the **neostriatum**.

The globus pallidus is relatively ancient and termed *paleostriatum/pallidum*. The caudate nucleus and putamen being recent in development, together form the *neostriatum/ striatum*. The striatum is largely afferent whereas pallidum is largely efferent structure.

These features of corpus striatum may be summarized as follows:



Caudate Nucleus

Caudate nucleus is a large comma-shaped mass of grey matter, which surrounds the thalamus and is itself surrounded by the lateral ventricle (Fig. 13.4). Its whole length of convexity projects into the cavity of lateral ventricle.

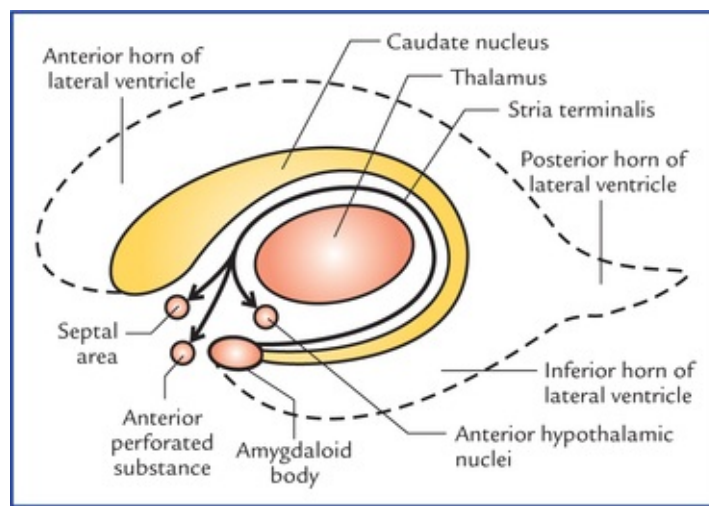


FIG. 13.4 Relationship of caudate nucleus with the cavity of the fourth ventricle and thalamus. Note that the *stria terminalis*, the main efferent tract of amygdaloid body projects to the septal area, anterior perforated substance, and anterior hypothalamus.

Its rounded anterior part in front of interventricular foramen is called its *head*. The head gradually and imperceptibly tapers caudally into the body and then into a tail which merges at its anterior extremity with an almond-shaped mass of grey matter called *amygdaloid body* (Fig. 13.2).

The **head** is large and rounded, and forms the floor and lateral wall of the anterior horn of lateral ventricle. The bands of grey matter connect it to the putamen across the anterior limb of internal capsule (Fig. 13.3).

The **body** is long and narrow, and forms the floor of the central part of lateral ventricle. It is separated from thalamus by stria terminalis and thalamostriate vein.

The **tail** is long and slender, and forms the roof of inferior horn of lateral ventricle. It terminates anteriorly (topographically) in the amygdaloid body.

Lentiform Nucleus

Lentiform nucleus is a large lens-shaped (biconvex) mass of grey matter beneath the insula forming the lateral boundary of internal capsule. In horizontal section of cerebrum, it appears wedge-shaped with broad convex base directed laterally.

It has three surfaces and divides into two parts:

Surfaces

- The **lateral surface** is convex and related to thin sheet of white matter, the **external capsule**. It is grooved by lateral striate arteries (the central branches of middle cerebral artery).
- **Medial surface** is more convex and related to internal capsule (limbs and genu). In transverse sections, the medial surface is angulated at the genu.
- **Inferior surface** is related to sublentiform part of internal capsule and lies close to the anterior perforated substance.

Parts

A vertical plate of white matter (*external medullary lamina*) divides the lentiform nucleus into two parts, the *putamen* and the *globus pallidus*. These are clearly seen on a cut section.

The **putamen** is larger lateral part and consists of densely packed small cells. It is darker in colour, and structurally similar to the caudate nucleus.

The **globus pallidus** is smaller medial part. It is lighter in colour and consists of large (motor) cells. It is also known as *pallidum* as it appears pale in section (pallid = pale). The globus pallidus is further subdivided by an *internal medullary lamina of white matter* into outer and inner segments (Fig. 13.3).

Connections of corpus striatum (Fig. 13.5)

The striatum (caudate nucleus and putamen) is the receptive part while globus pallidus is the efferent part (outflow centre) of the corpus striatum.

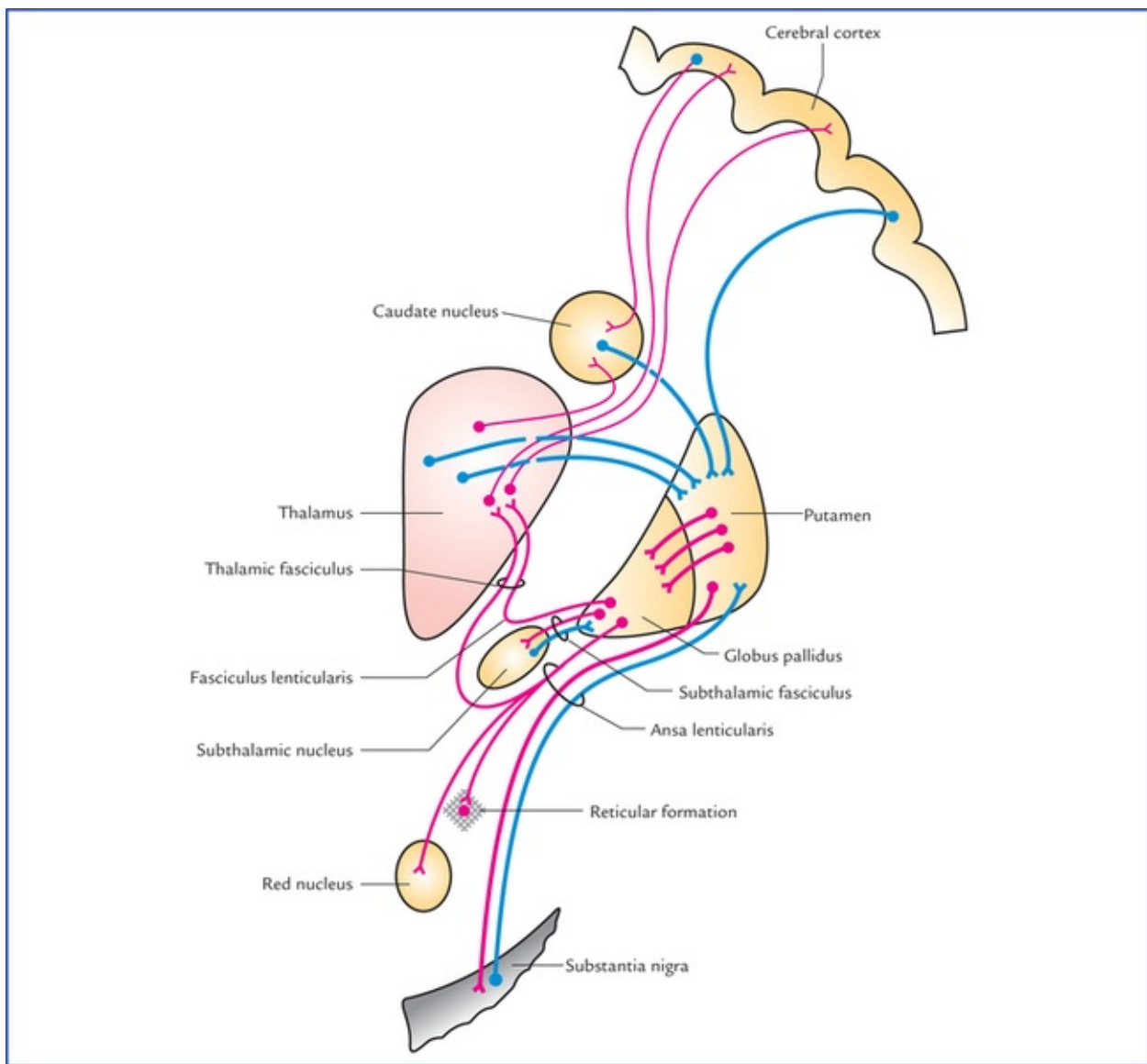


FIG. 13.5 Chief afferent and efferent connections of corpus striatum.

Afferent connections

The striatum receives afferents chiefly from cerebral cortex, thalamus and substantia nigra.

- *Corticostriate fibres* arise from a wide area of the ipsilateral cerebral cortex and reach the striatum through both internal and external capsules.
- *Thalamostriate fibres* arise from mediodorsal, intralaminar and midline nuclei of the thalamus. The majority of these fibres end in the caudate nucleus, the remaining pass through the internal capsule to reach the putamen.
- *Nigrostriate fibres* arise from substantia nigra and ascend up to terminate in the corpus striatum, mainly in putamen and caudate nucleus.

The nigrostriate fibres carry dopamine synthesized by nerve cells of substantia nigra to striatum (melanin normally present in the substantia nigra is a byproduct of dopamine metabolism). It is believed that these fibres have an inhibitory effect on corpus striatum.

Efferent connections

Most of the output of striatum goes to the globus pallidus, however, some efferents also go to substantia nigra.

The globus pallidus is the main efferent component of corpus striatum.

The outflow from globus pallidus goes mainly to the thalamus (ventrolateral and ventroanterior nuclei) (Figs 13.5, 13.6). This occurs by way of two fasciculi: (a) *ansa lenticularis* looping round the posterior limb of internal capsule, and (b) *fasciculus lenticularis* traversing the internal capsule.

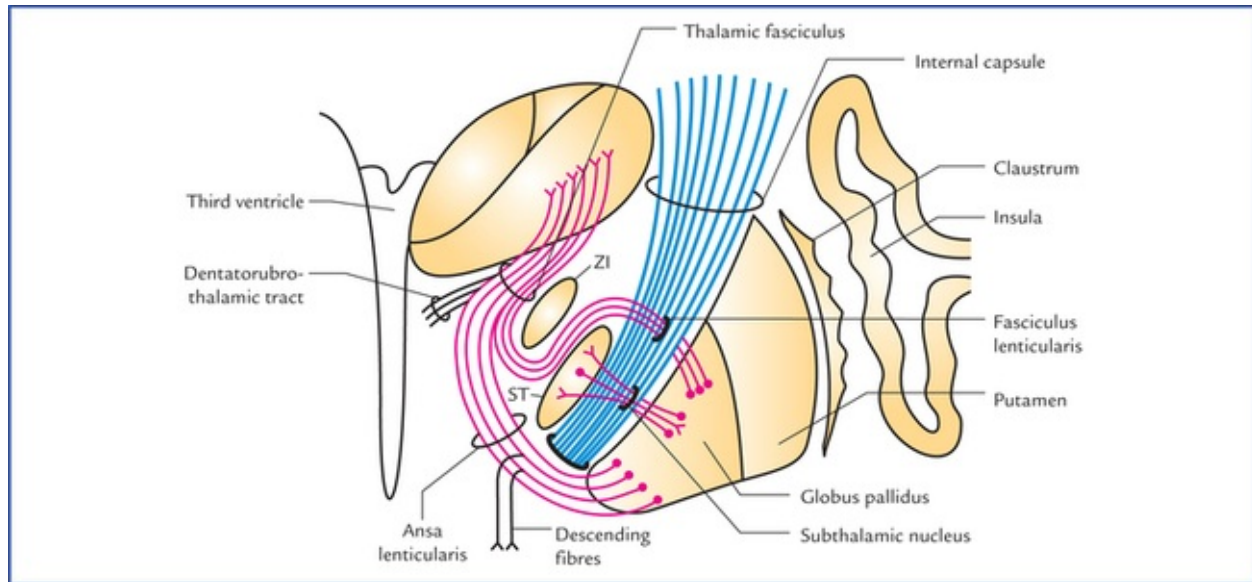


FIG. 13.6 Outflow tracts from globus pallidus (paleostriatum). Also, note the interconnection between subthalamic nucleus and globus pallidus.

These fasciculi enter the region between the red nucleus and thalamus, where they unite with the *dentatorubro-thalamic tract* to form the *thalamic fasciculus*, which ends in the ventrolateral and ventroanterior nuclei of thalamus which in turn project to the motor and premotor areas of cerebral cortex.

The *subthalamic fasciculus* passes through the internal capsule and forms direct reciprocal connections between subthalamic nucleus and globus pallidus.

Some fibres from globus pallidus also pass to the substantia nigra (*pallidonigral fibres*).

Functions of corpus striatum

In submammalian vertebrates, the corpus striatum is the sensory and motor integrating and control centre. In later evolution, the activity of corpus striatum has become subordinate to those of cerebral cortex but remain essential for muscle tone, quality of movement, posture and locomotion.

- Corpus striatum controls the automatic associated movements like, swinging of arms during walking.
- It helps in smoothening the voluntary motor activity of the body.

Clastrum

Clastrum is a thin saucer-shaped mass of grey matter situated between the putamen and insula. It is considered as a detached part of the insula (Fig. 13.6).

Its connections and functions are not known.

Amygdaloid Body

Amygdaloid body is an almond-shaped mass of grey matter in the temporal lobe, lying anterosuperior to the tip of inferior horn of lateral ventricle. It is situated deep to uncus which serves as a surface landmark for its location.

Developmentally it is related to basal nuclei but functionally it is included in the limbic system and therefore shares its functions. For details see limbic system ([page 229](#)).

Substantia Nigra

Substantia nigra is described in detail in [Chapter 8](#).

Subthalamus (Subthalamic Nucleus)

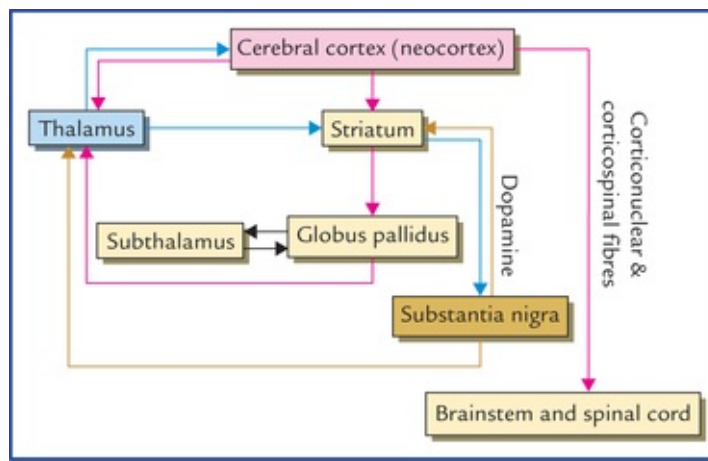
This small nucleus in the ventral part of the diencephalon looks like a biconvex lens in coronal section. It is located caudal to the lateral half of the thalamus and inferomedial to the globus pallidus. It is separated from thalamus by a smaller nucleus, called *zona inserta*. The subthalamic nucleus and globus pallidus are interconnected by the *subthalamic fasciculus* which traverses the internal capsule ([Fig. 13.6](#)).

Functions of Basal Nuclei

- Concerned with planning and programming of voluntary movements.
- Determine how rapidly a movement is to be performed and how large the movement must be.
- Decrease muscle tone and inhibit unwanted muscular activity.
- Regulate the muscle tone and thus helps in smoothening the voluntary motor activities of the body.
- Control automatic associated movements, like swinging of arms during walking.
- Control group of movements for emotional expression.
- Control reflex muscular activity.

Neural Circuitry Involved in Functioning of Basal Nuclei (Flowchart 13.1)

The striatum receives information from three major sources: (a) the cerebral cortex, (b) the thalamus, and (c) the substantia nigra. The striatum projects to the globus pallidus and substantia nigra. The globus pallidus (the outflow nucleus of striatum) projects to the thalamus and subthalamic nucleus. The substantia nigra also projects to the thalamus. The thalamus projects to the cerebral cortex. This information is integrated within the corpus striatum and outflow passes back to the above areas. This circular pathway functions as follows:



FLOWCHART 13.1 Neural circuitry of basal nuclei.

The activity of the basal ganglia is initiated by information received from the cerebral cortex, the thalamus, and the brainstem (substantia nigra and red nucleus). The outflow from the basal ganglia is channelled through the globus pallidus, which then influences the activities of the motor areas of the cerebral cortex. The motor cortex then controls the motor activities through corticospinal and corticonuclear fibres. Thus, basal ganglia can control muscular movements by influencing the cerebral cortex rather than through direct descending pathways to the brainstem and spinal cord.

Clinical Correlation

Disorders of the Basal Ganglia

The lesions of basal ganglia result in various forms of unwanted involuntary movements and disturbance in muscle tone. These disorders include parkinsonism, chorea, athetosis and ballismus.

• Parkinsonism (also called Parkinson's disease/paralysis agitans)

This disease usually occurs after 50 years of age due to deficiency of the neurotransmitter dopamine in the corpus striatum following a lesion in substantia nigra and/or its projections (i.e. nigrostriate fibres). Dopamine is synthesized in the melanin containing pigmented cells of substantia nigra and transported to the corpus striatum through nigrostriate fibres. Dopamine causes inhibition of cells within the corpus striatum. The neurological changes in the Parkinsonism appear to be a release phenomenon due to lack of inhibitory influences following dopamine deficiency.

Characteristic features of Parkinsonism (Fig. 13.7)

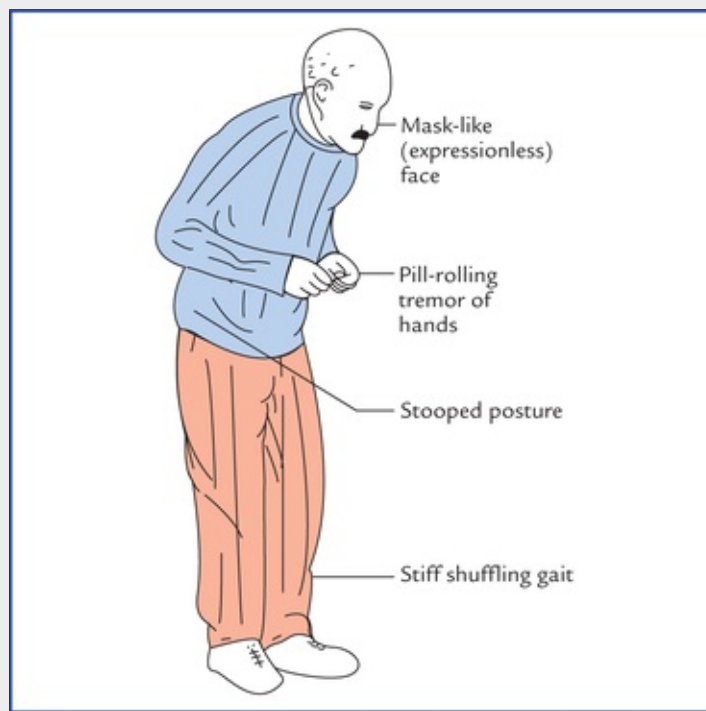


FIG. 13.7 Presenting features of patient suffering from Parkinsonism.

- *Resting tremors, i.e. a slight shaking of hands when person is not performing a task. The tremors are diminished with movement and exaggerated by emotional excitation.*
- *Lead-pipe or cogwheel type of muscular rigidity due to increased muscle tone (in contrast to clasp-knife rigidity of upper motor neuron lesions).*
- *Pill-rolling movements of hands, consisting of circular movements of the opposed thumb and index fingertips is a kind of resting tremor).*
- *Mask-like face or loss of facial expression, due to lack of control of group of muscles of movements for emotional expression.*
- *Stiff, shuffling gait due to rigidity of joints.*
- *Stooped-posture. The stance of the patient is affected by rigidity. The back is flexed, the arms adducted and flexed, and knees bent.*
- *General slowing-down of movements and absence of associated movements, such as arm-swinging during walking.*

To summarize the Parkinson's disease is characterized by a triad of symptoms, viz. tremor, rigidity, and akinesia.

Treatment

- The administration of L-dopa, a precursor of dopamine, or
- By placing small lesions (stereotactic surgery) in the globus pallidus and thalamus to diminish the cortical effects of abnormal discharges from corpus striatum, or
- By striatal implants of dopamine containing neurons of fetal origin.

• Chorea

This is characterized by quick, jerky, irregular purposeless involuntary movements, which involve primarily, the tongue, face and limbs. Swift grimaces and sudden movements of the head or limbs are good examples. The chorea is of two types: (a) Sydenham's chorea, and (b) Huntington's chorea ([Table 13.1](#)).

Table 13.1**Differences between Sydenham's chorea and Huntington's chorea**

	Sydenham's chorea (St. Vitus' dance)	Huntington's chorea
Age	Occurs in children (between the ages of 5 and 15 years) primarily affecting girls and is associated with rheumatic fever	Occurs in adults (between the ages of 30 and 45 years) and is an autosomal dominant inherited disease
Pathology	Antibodies produced by the antigens of streptococcal bacteria combine with the proteins of the membranes of neurons of striatum (caudate nucleus and putamen) producing inflammatory changes in the striatum	Degeneration of GABA secreting neurons of striatum (caudate nucleus and putamen). Thus, striatonigral pathway is not able to inhibit the dopamine/secreting neurons of the substantia nigra. As a result, there occurs an over activity of nigrostriate fibres
Involuntary movements	Relatively less rapid and jerky	Relatively more rapid and jerky
CT scan of brain	Shows no significant finding	Shows enlarged lateral ventricle due to degeneration of caudate nucleus
Recovery	Full recovery (as a rule)	No recovery

- **Athetosis**

This consists of slow, sinuous, writhing movements (called **athetoid movements**) that commonly involve distal segments of the limbs, i.e. movements occur more in the muscles of the fingers and toes than in the proximal muscles of the limbs. The athetosis results due to lesions in neo-striatum and globus pallidus, breaking neuronal circuitry involving basal nuclei and cerebral cortex.

- **Ballismus**

It usually results due to vascular lesion of the subthalamic nucleus where normal smooth movements of different parts of the body are integrated.

The ballismus is characterized by violent burst of irregular movements in the trunk, girdles and proximal extremities. It usually involves the proximal musculature of opposite extremity, and limb suddenly flies about in all directions out of control, **i.e. contralateral flinging (ballistic) movements of one or both extremities.**

The disease may be restricted to one limb (**monoballismus**), but usually involves both upper and lower limbs on the contralateral side of the lesion (**hemiballismus**). This is because the subthalamic nucleus of one side projects mainly to the ipsilateral cortex through globus pallidus and thalamus.

Clinical Problems

1. A patient aged 65, presents with unintentional or resting tremors of hands (i.e. tremors occur at rest and disappear during voluntary movement), and slow voluntary movements. On examination, the following signs are elicited:
 - (a) Pill-rolling movements of hands, (b) face is expressionless (mask-like), (c) speech is slurred and monotonous, (d) cannot stand upright (a stooped posture), (e) short, shuffling gait, (f) increased muscle tone, and (g) cogwheel rigidity of joints. Make the clinical diagnosis.

2. What do you understand by the term 'chorea' and tell the differences between the *Sydenham's chorea* and *Huntington's chorea*?
3. A patient aged 55 has suddenly developed involuntary movements in his trunk and the left upper limb. His limb abruptly, vigorously and aimlessly would be thrown about in all directions, knocking over anything that comes in its path. Make the clinical diagnosis.

Clinical Problem Solving

1. This is a typical case of Parkinsonism (see [page 159](#)).
2. The term chorea stands for a syndrome in which the patient exhibits involuntary, quick, jerky, irregular movements, which are non-repetitive, *viz.* swift grimaces (grimace = distortion of the face). The differences between Sydenham's chorea and Huntington's chorea are presented in [Table 13.1](#).
3. It is a typical case of left sided hemiballismus due to damage of right subthalamic nucleus (also see [page 160](#)).

White Matter of the Cerebrum and Lateral Ventricles

White Matter Of The Cerebrum

The cerebral white matter is a compact mass of a vast number of nerve fibres and associated neuroglia. It lies deep to the cerebral cortex and forms the large volume of each cerebral hemisphere.

Types of Fibres in the White Matter

The fibres of white matter connect the various parts of cerebral cortex with each other and to the other parts of the central nervous system. They are classified into following three types, on the basis of the types of connections they provide (Fig. 14.1):

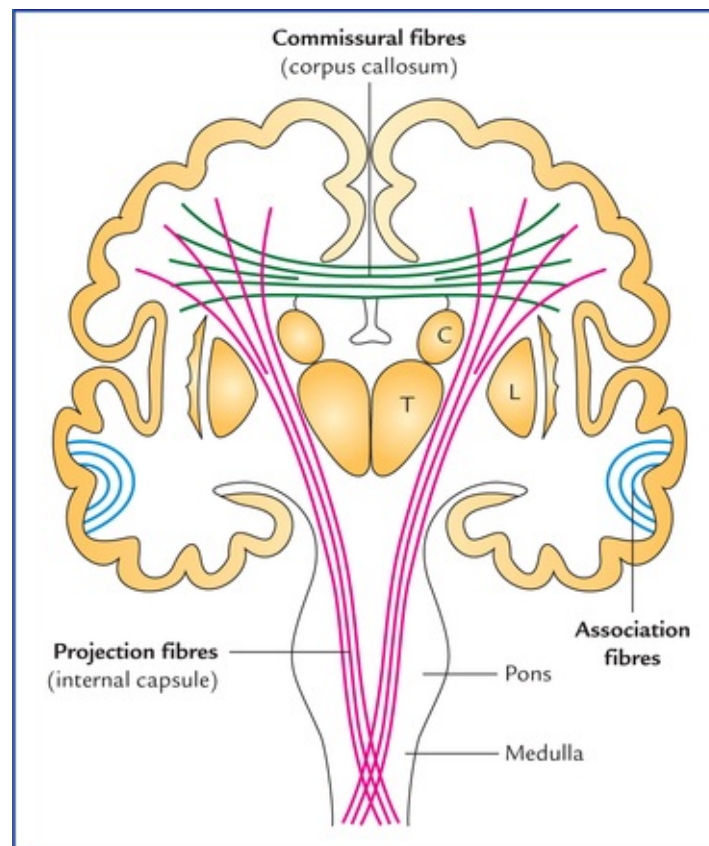


FIG. 14.1 Frontal view of coronal section of the brain showing association, commissural, and projection fibres. (C = caudate nucleus, T = thalamus, L = lentiform nucleus.)

1. Association fibres.
2. Commissural fibres.

3. Projection fibres.

Association fibres

The association fibres interconnect the different regions of the cerebral cortex in the same hemisphere (*intrahe-mi-spheric fibres*). These are of two types (Fig. 14.2):

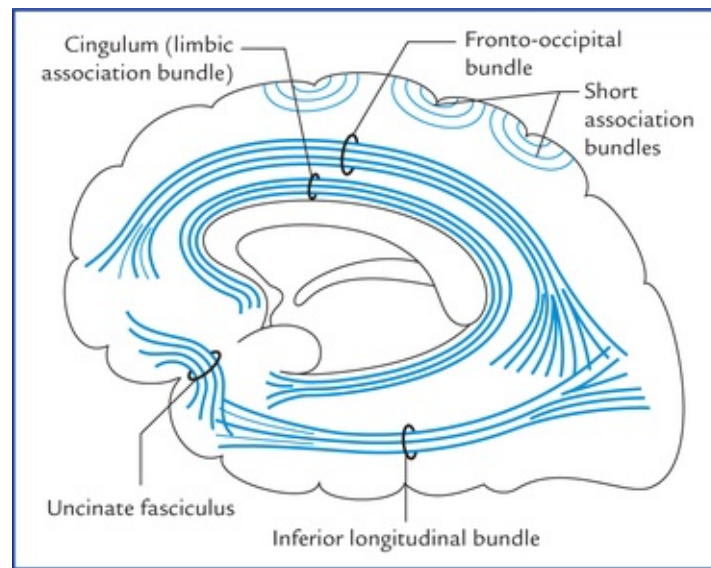


FIG. 14.2 Bundles of short and long association fibres within the cerebral hemisphere.

- **Short association fibres (arcuate or ‘U’ fibres)** which interconnect the adjacent gyri by hooking around the sulcus, hence they are also called *arcuate fibres*.
- **Long association fibres** travel for long distances and interconnect the widely separated gyri, viz. gyri of different lobes. The long association fibres are grouped into bundles. The examples of bundles of long association fibres are as follows:
 1. *Uncinate fasciculus* which connects the motor speech area and orbital cortex of frontal lobe with the cortex of temporal pole by hooking around the stem of lateral sulcus. It is narrow in the middle and fanned out at both ends.
 2. *Cingulum* (also called *limbic association bundle*): It is thick bundle of fibres occupying the cingulate and parahippocampal gyri. It extends from the parater-minal gyrus to the uncus forming almost a circle like a girdle (cingulum = girdle) hence its name.
 3. *Superior longitudinal bundle*: It is the longest association bundle which connects the frontal lobe to the occipital and temporal lobes.
 4. *Inferior longitudinal bundle*: It connects the visual association area of occipital lobe to the temporal lobe.
 5. *Fronto-occipital bundle*: It commences in the frontal pole, runs backwards to radiate into the occipital and temporal lobes. The fronto-occipital bundle pursues a similar course to that of superior longitudinal fasciculus. However, it lies deep to the *superior longitudinal bundle* and is separated from it by the fibres of the *corona radiata*.

Commissural fibres

The commissural fibres interconnect the identical/corresponding areas of the two cerebral hemispheres (*interhemispheric fibres*). The bundles of such fibres are termed **commissures**.

The important commissures of the brain are as follows:

1. Corpus callosum.
2. Anterior commissure.
3. Posterior commissure.
4. Hippocampal commissure (commissure of fornix).
5. Habenular commissure.

N.B. The commissural fibres are essential for interhemi-spheric transfer of information for bilateral responses and learning processes.

The primary visual area and hand region of primary somato-sensory area of cortex have no known commissural fibres.

Corpus callosum (Figs 14.3-14.5)

The corpus callosum is the **largest commissure of the brain** connecting the cerebral cortex of the two cerebral hemispheres. Since it connects the neocortex (neopallium) of the two sides, it attains enormous size in man. It is 10 cm long, nearly half of the anteroposterior length of the hemispheres, and consists of about 300 million fibres.

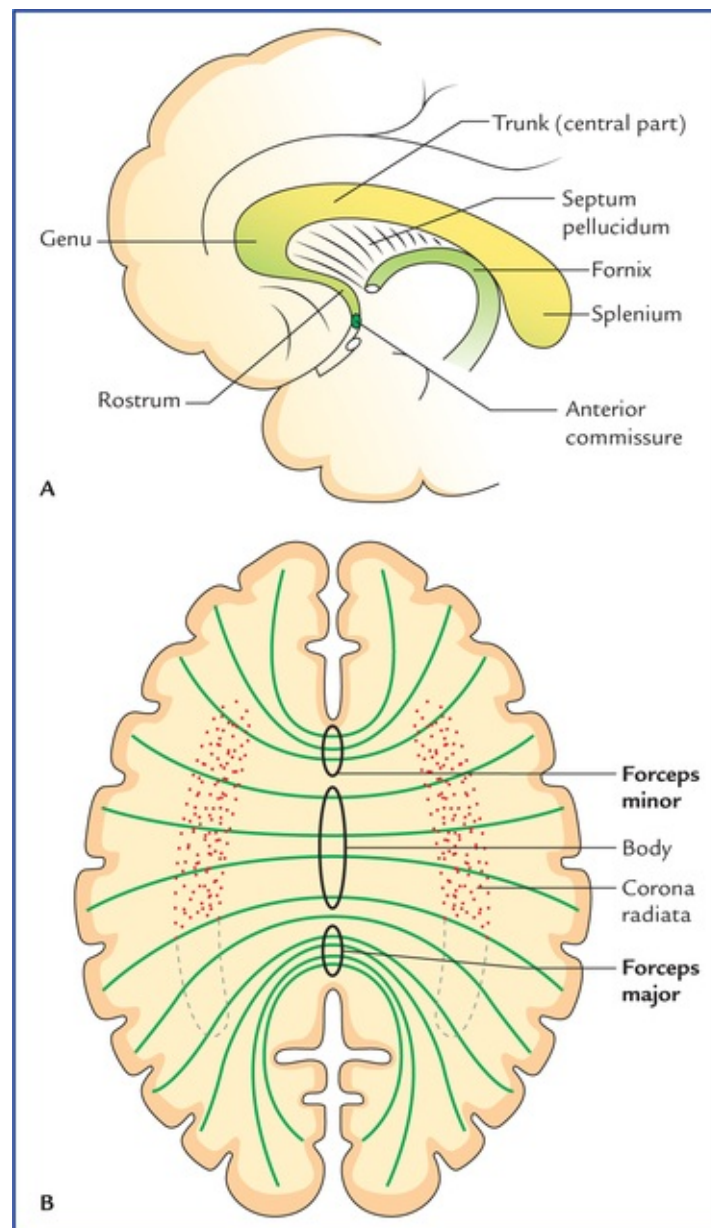


FIG. 14.3 Median sagittal section of the cerebrum showing shape and different parts of corpus callosum.

The corpus callosum connects all the parts of neocortex of two hemispheres except for the lower and anterior parts of temporal lobes which are connected by the anterior commissure.

External features and relations of corpus callosum

- Corpus callosum forms a massive arched interhemispheric bridge in the floor of the *median longitudinal cerebral fissure* connecting the medial surfaces of the two cerebral hemispheres.
- It forms massive, arched, interhemispheric bridge flooring the midline longitudinal fissure and roofing both the lateral ventricles.
- It lies nearer the anterior end (4 cm behind the frontal pole) of the hemisphere than the posterior end (6 cm in front of the occipital pole).
- In sagittal section of cerebrum it is seen as C-shaped mass of white fibres on the medial surface of the hemisphere forming the roof of the lateral ventricle (Fig. 14.4).

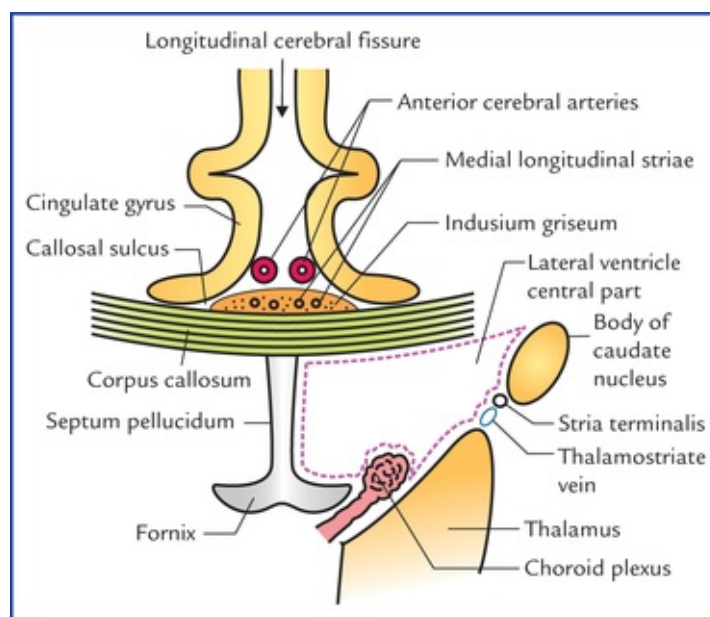


FIG. 14.4 Some of the relations of corpus callosum in the coronal section of the brain passing through the central parts of lateral ventricles parts.

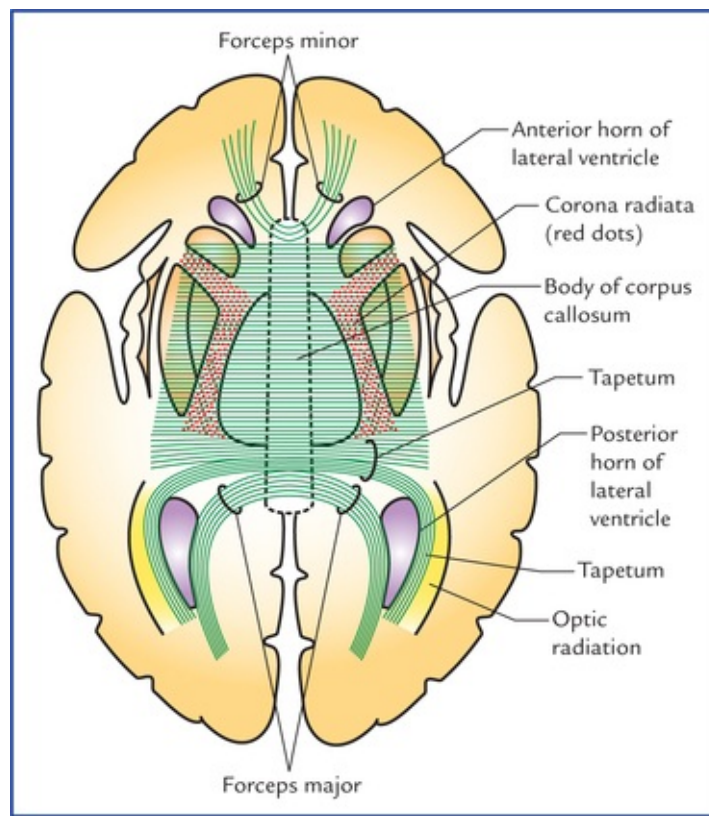


FIG. 14.5 Horizontal section of the cerebrum (schematic) to show the course and components of the fibres of corpus callosum. Note that the fibres of corona radiata are cut at right angle to their course.

- The concave inferior aspect of corpus callosum is attached with the convex superior aspect of the fornix by the *septum pellucidum* and its convex superior aspect is covered by a thin layer of grey matter, the **indusium griseum**, embedded in which are the fibre bundles of bilateral *medial and lateral longitudinal striae*.
- The anterior cerebral vessels often lie on the pia mater covering its superior aspect of corpus callosum.
- The superior aspect of corpus callosum is covered on each side by cingulate gyrus from which it is separated by a *callosal sulcus*.

Parts of the corpus callosum

The corpus callosum is divided from before backwards into four parts: (a) rostrum, (b) genu, (c) trunk/body, and (d) splenium (Fig. 14.3).

Genu: It is thick curved anterior extremity of corpus callosum which lies 4 cm behind the frontal pole. Genu forms the anterior boundary of the anterior horn of the lateral ventricle. The fibres of genu sweep (curve) forwards on either side into the anterior parts of the frontal lobes, forming a fork-like structure, the **forceps minor**.

Rostrum: The genu extends downwards and backwards as a thin prolongation to join the lamina terminalis forming, rostrum of corpus callosum. The rostrum forms the floor of the anterior horn of lateral ventricle and its fibres extends inferiorly to connect the orbital surfaces of the two frontal lobes.

Trunk: The trunk is main (middle) part of the corpus callosum between its thick anterior (genu) and posterior (splenium) extremities. Its fibres connect most of the frontal and anterior parts of the parietal lobes of the two cerebral hemispheres. The central part of the corpus callosum forms the roof of the central part of the lateral ventricle.

Splenium: The splenium is the massive posterior extremity of the corpus callosum, lying 6 cm in front

of the occipital pole. It overhangs the thalamic pulvinars, pineal gland and tectum of the midbrain. The transverse fissure containing tela choroidea of third ventricle, posterior choroidal arteries and great cerebral vein of Galen is located inferior to the splenium.

The fibres of the splenium connect the posterior parts of the parietal lobes, and temporal and occipital lobes of the two hemispheres. The fibres connecting the occipital lobes sweep backwards on either side above the calcarine sulcus forming a large fork-like structure, the **forceps major** (Fig. 14.5). The forceps major forms a swelling in the upper part of the medial wall of the posterior horn of lateral ventricle, the **bulb of the posterior horn**.

N.B. The **tapetum** is the thin lamina of white fibres (2 cm thick) which forms the roof and lateral wall of the posterior horn; and lateral wall of the inferior horn of the lateral ventricle.

The tapetum is formed by those fibres of the trunk and splenium of corpus callosum which are not intersected by the fibres of corona radiata. In the coronal section, the tapetum looks whiter than the surrounding white matter because section passes parallel to the fibres of the tapetum.

Functions of the corpus callosum

The corpus callosum is largely responsible for interhemi-spheric transfer of information which is essential for bilateral responses and in learning processes. However, its congenital absence or surgical division does not produce any change in personality or intelligence and patients remain completely unnoticed of any definite neurological disorder in day-to-day life. Only special tests of tactile and visual systems will reveal any abnormality.

Clinical Correlation

Split-brain (Split-brain syndrome)

If the corpus callosum is congenitally absent or sectioned surgically each cerebral hemisphere becomes isolated and patient responds as if he/she has two separate brains, a condition called **split-brain syndrome**.

The severance of corpus callosum in young monkeys produces **split-brain syndrome**, viz. if they are trained to perform a task with one hand, they are unable to repeat the same act with the other hand.

Lesions of anterior corpus callosum result in akinetic mutism and tactile anomia whereas lesions of posterior corpus callosum result in alexia without agraphia.

N.B. The section of corpus callosum in past has been attempted surgically to prevent the spread of severe epileptic seizures from one hemisphere to the other.

Anterior commissure

The anterior commissure is a small round bundle of white fibres which crosses the midline in the upper part of the lamina terminalis, immediately in front of the anterior column of the fornix and the interventricular foramen.

Anterior commissure consists of two components (Fig. 14.6):

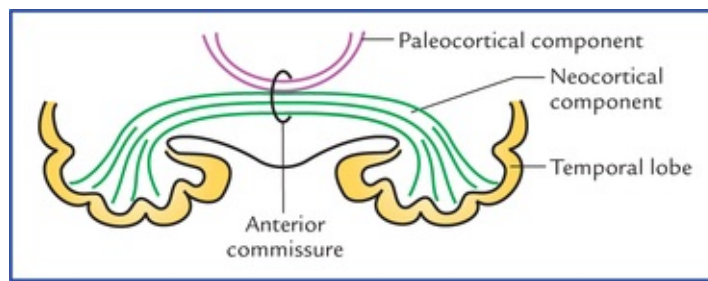


FIG. 14.6 Anterior commissure. The large neocortical component is shown in green and the small paleocortical component in maroon.

- A large **posterior neocortical component**, which interconnects the lower and anterior parts of the temporal lobes.
- A smaller **anterior paleocortical component**, which interconnects the olfactory regions (olfactory bulbs, olfactory tubercles, etc.) of the two hemispheres.

Seen from below the full extent of anterior commissure has the shape of a *cupid's bow*.

Posterior commissure

The posterior commissure is a slender bundle of white fibres which crosses the midline through the inferior lamina of the stalk of pineal gland.

It interconnects the superior colliculi, pretectal and interstitial nuclei of two sides.

Habenular commissure

The habenular commissure is a slender bundle of white fibres which crosses the midline through the superior lamina of the stalk of pineal gland. It interconnects the habenular nuclei of the two sides.

Hippocampal commissure (commissure of fornix)

Hippocampal commissure interconnects the crura of fornix and thus the hippocampal formations of the two sides (Fig. 19.10).

Projection fibres

The projection fibres connect the cerebral cortex to the subcortical centres (such as the corpus striatum, thalamus, brainstem) and spinal cord. These fibres are of two types:

- **Corticofugal fibres** go away from the cortex (cortical efferents) to centres in the other parts of the CNS.
- **Corticopetal fibres** come to the cerebral cortex from the other centres in the CNS.

The projection fibres of neocortex constitute the *corona radiata* and *internal capsule* while those of allocortex (i.e. archicortex and paleocortex) constitute the *fimbria* and *fornix*.

The most important bundles of projection fibres are: internal capsule and fornix.

Internal capsule

The internal capsule is a compact bundle of projection fibres between the thalamus and caudate nucleus medially and the lentiform nucleus laterally.

These fibres fan out rostrally to form the **corona radiata** and condense caudally to continue as the crus cerebri of the midbrain. The ascending (corticopetal/sensory) and descending (corticofugal/motor) fibres of internal capsule chiefly interconnect the cerebral cortex with the brainstem and spinal cord.

These fibres are mainly responsible for the sensory and motor innervation of the opposite half of the body.

N.B. Because of high concentration of motor and sensory nerve fibres within the internal capsule, even a small lesion may produce a widespread paralytic effects and sensory loss in the opposite half of the body.

Shape and boundaries of the internal capsule

In a horizontal section of the cerebral hemisphere, the internal capsule appears as a V-shaped compact bundle of white fibres with its concavity directed laterally (Fig. 14.7):

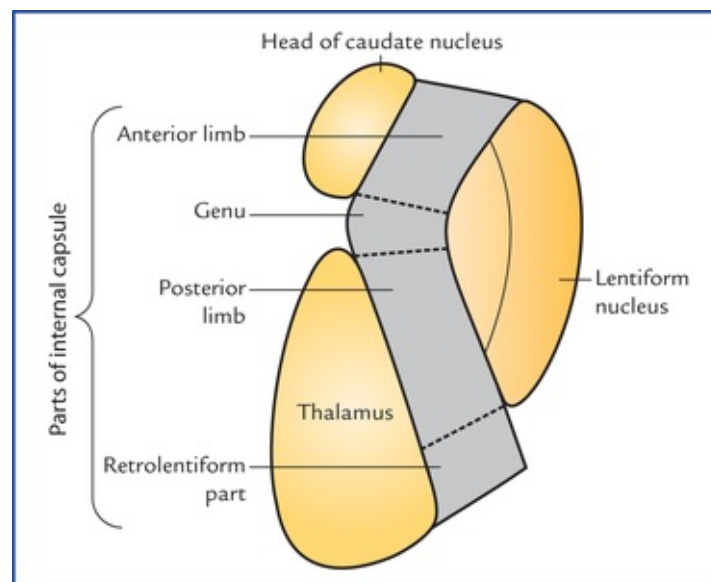


FIG. 14.7 Location, shape, boundaries and parts of the internal capsule.

It is bounded medially by the caudate nucleus and thalamus, and laterally by the lentiform nucleus.

Parts of the internal capsule

The internal capsule is divided into following five parts (Fig. 14.7)

- **Anterior limb**, lies between the head of caudate nucleus medially and the anterior part of the lentiform nucleus laterally.
- **Posterior limb**, lies between the thalamus medially and the posterior part of the lentiform nucleus laterally.
- **Genu**, is the bend between the anterior and posterior limbs with concavity of the bend facing laterally.
- **Retrolentiform part**, lies behind the lentiform nucleus.
- **Sublentiform part**, lies below the lentiform nucleus.

Constituent fibres of the internal capsule (Figs 14.8-14.10)

Motor fibres (Fig. 14.8)

- **Corticopontine fibres** originate from the cerebral cortex of all the lobes of the cerebral hemisphere and form the *largest single group of projection fibres* in the internal capsule (about 2/3rd of the total fibre component). They are named according to the lobe from which they arise, e.g. frontopontine, parietopontine, occipitopontine and temporopontine, arising from frontal, parietal, occipital and

temporal lobes respectively.

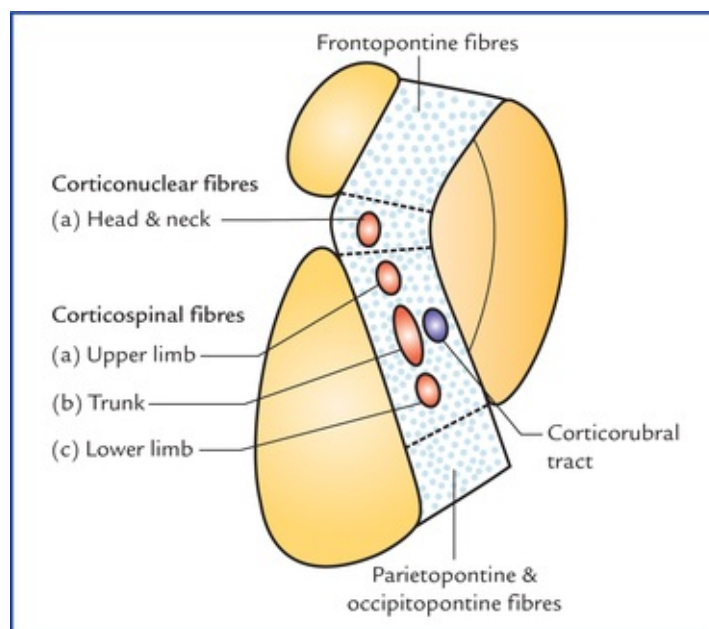


FIG. 14.8 The disposition of motor fibres passing through the internal capsule.

The *frontopontine fibres* are most numerous and pass through the anterior limb, genu, and posterior limb. The *parietopontine* and *occipitopontine fibres* pass through the retrolentiform part. The *temporopontine fibres* pass through the sublenticular part (Fig. 14.10).

The *corticopontine fibres* relay (synapse) in the ipsilateral pontine nuclei. The fibres arising from pontine nuclei cross the midline to relay in the cortex of the opposite cerebellar hemisphere, thus forming the **cortico-ponto-cerebellar pathway**. *The cortico-ponto-cerebellar pathway is most recent in development and best developed in man.*

- **Pyramidal fibres** arise in the cerebral cortex and relay in the lower motor neurons within the brainstem and spinal cord.

The pyramidal fibres are of two types:

- *Corticonuclear fibres* synapse with the contralateral motor nuclei of the cranial nerves which innervate the head and neck muscles. The corticonuclear fibres occupy the genu of the internal capsule.
- *Corticospinal fibres* synapse with the anterior horn cells of the opposite half of the spinal cord, which innervate the muscles of the upper limb, trunk and lower limb. The corticospinal fibres form several discrete bundles in the anterior two-thirds of the posterior limb. The fibres for the upper limb are most anterior, followed in that order, by the fibres for the trunk and the lower limb.
- **Extrapyramidal fibres** arise in the cerebral cortex and relay into the subcortical grey matter belonging to the extrapyramidal system, viz. red nucleus, corpus striatum, substantia nigra, etc. They are named according to their destinations, viz. corticorubral, corticostriate, corticonigral, etc. respectively. Most of the extrapyramidal fibres occupy the position near the corticospinal fibres in the internal capsule, and are therefore affected in the lesions of the posterior limb.

Sensory fibres (Fig. 14.9A,B)

Sensory fibres are mostly **thalamocortical fibres**, which radiate from thalamus in different directions to reach the widespread areas of the cerebral cortex and constitute most of **thalamic radiation**. Most of the

thalamocortical fibres, are the tertiary (3rd order) sensory neurons of various sensory pathways conveying somesthetic sensations to the cerebral cortex. The other fibres contributing the formation of thalamic radiation are **corticothalamic fibres**.

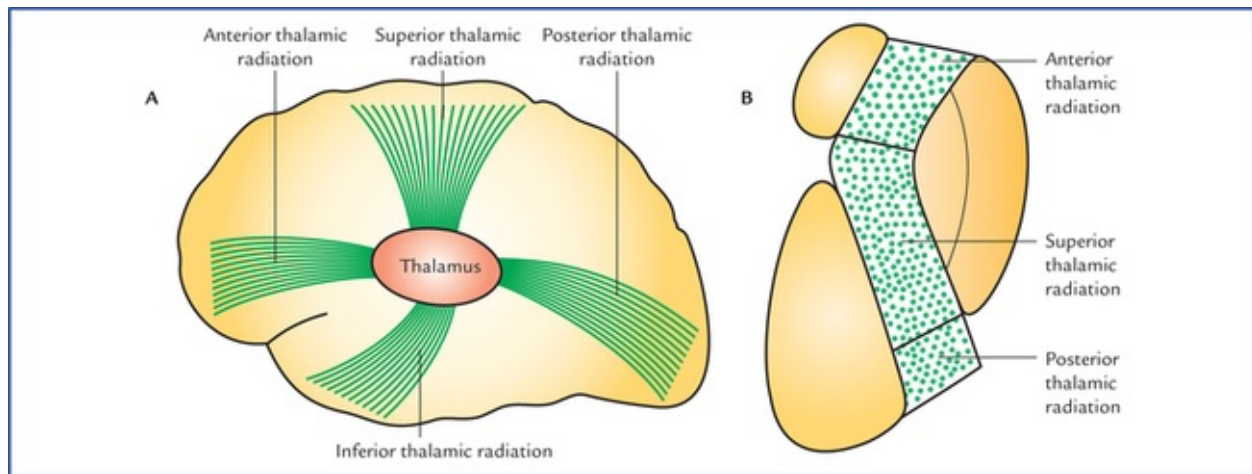


FIG. 14.9 (A) Direction of fibres of different groups of thalamic radiation. (B) Location of different groups of thalamic radiation in different parts of the internal capsule.

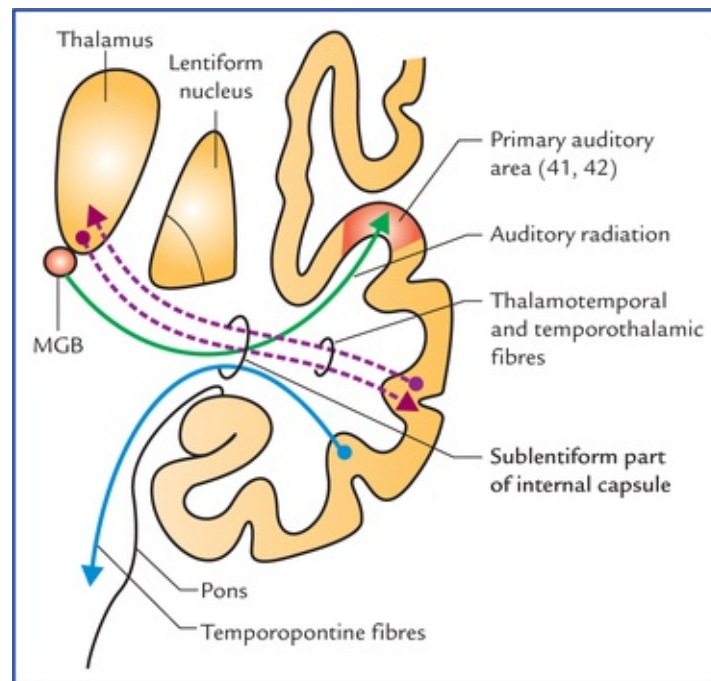


FIG. 14.10 Fibres passing through the sublenticular part of the internal capsule. (MGB = medial geniculate body.)

According to the direction of these fibres the thalamic radiation is divided into following subgroups:

- **Anterior thalamic radiation:** the fibres of anterior thal-amic radiation are directed anteriorly and connects the anterior and dorsomedial nuclei of thalamus to frontal lobe cortex.
- **Superior thalamic radiation** is directed superiorly. Its fibres pass through anterior limb of internal capsule and connect the ventral tier of thalamic nuclei with the sensory cortex of the frontal and parietal lobes.
- **Posterior thalamic radiation** is directed posteriorly. The fibres of posterior thalamic radiation pass

through the retrolentiform part of internal capsule and connect the lateral geniculate body to the primary visual cortex of the occipital lobe forming *optic radiation (geniculocalcarine tract)* (see Fig. 14.11).

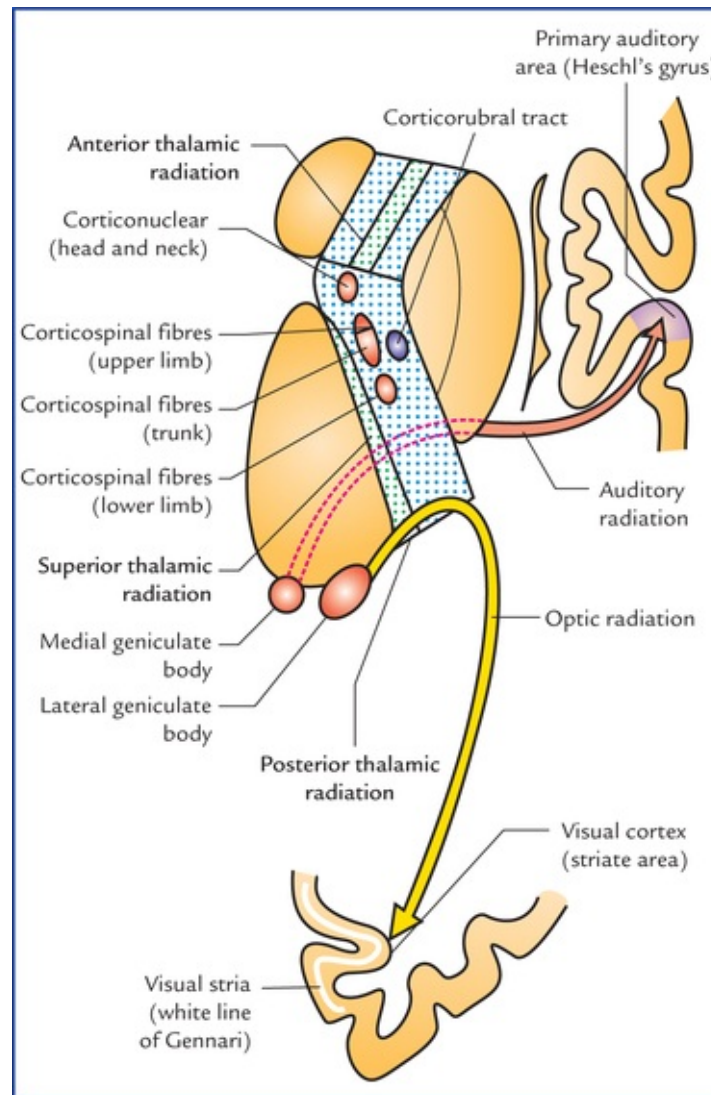


FIG. 14.11 Main parts of the internal capsule and fibres/tracts passing through them.

- **Inferior thalamic radiation** is directed inferiorly. Its fibres pass through sublenticular part of internal capsule and most of them connect the medial geniculate body with the primary auditory area of the temporal lobe forming *auditory radiation* (Fig. 14.11).

The constituent motor and sensory fibres in different parts of the internal capsule are summarized in Table 14.1 and shown in Figure 14.11.

Table 14.1

Constituent motor and sensory fibres in different parts of the internal capsule

Part	Motor fibres	Sensory fibres
Anterior limb	Frontopontine fibres	Anterior thalamic radiation
Genu	<ul style="list-style-type: none"> • Frontopontine fibres • Corticonuclear and corticospinal fibres for head and neck 	Superior thalamic radiation (anterior part only)
Posterior limb	<ul style="list-style-type: none"> • Frontopontine fibres • Corticospinal (pyramidal) fibres for upper limb, trunk and lower limb • Corticorubral (extrapyramidal) fibres 	Superior thalamic radiation
Retrolentiform part	Parietopontine and occipitopontine fibres	Posterior thalamic radiation (optic radiation)
Sublentiform part	Parietopontine and temporo-pontine fibres	Inferior thalamic radiation (auditory radiation)

Arterial supply of the internal capsule (Fig. 14.12)

The arterial supply of the internal capsule is of great clinical significance, due to high incidence of vascular lesions of internal capsule (called *capsular lesions*).

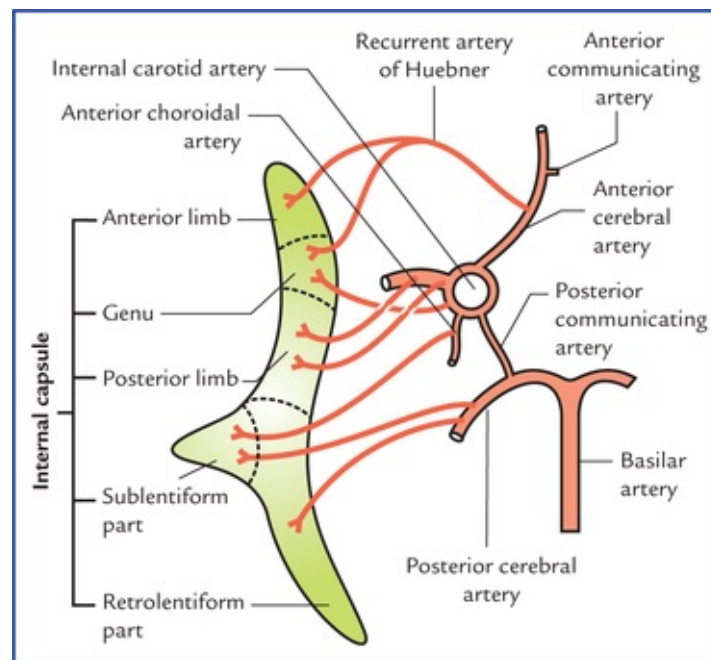


FIG. 14.12 Arteries supplying the internal capsule.

Various arteries supplying the internal capsule are:

- **Medial and lateral striate branches of the middle cerebral artery.** One of the lateral striate branches is larger and more frequently ruptured. It is often termed *Charcot's artery of cerebral haemorrhage*. It enters through the anterior perforated substance and supplies the posterior limb of the internal capsule.
- **Striate branches of anterior cerebral artery.** One of these branches is larger and takes a recurrent course. It is termed *recurrent artery of Huebner*. It arises just proximal to the anterior communicating artery, runs superior to the optic chiasma and penetrates the anterior perforated substance to supply the genu and anterior limb of the internal capsule.
- **Central branches of the anterior choroidal artery** supply the sublentiform part.
- **Some direct branches from the internal carotid artery** supply the genu.
- **Central branches of the posterior communicating artery.**

- **Posterolateral central branches of the posterior cerebral artery** supply the retrolentiform and sublenticular parts of the internal capsule.

Clinical Correlation

- Damage to the internal capsule, due to haemorrhage or infarction leads to loss of sensations and spastic paralysis of the opposite half of the body (**contralateral hemiplegia**).

The haemorrhage commonly occurs due to rupture of **artery of cerebral haemorrhage** (also called **Charcot's artery of cerebral haemorrhage**), which supplies the posterior limb of the internal capsule. The spastic paralysis of the opposite half of the body occurs due to the involvement of the pyramidal and extrapyramidal fibres for the upper limb, trunk and lower limb.

N.B. Rupture of Charcot's artery of cerebral haemorrhage is the most common cause of the hemiplegia.

- Involvement of **recurrent artery of Huebner** (due to thrombosis/rupture) results in paralysis of the face and upper limb on the opposite side (because of the involvement of corticonuclear fibres in genu and adjacent pyramidal fibres in the posterior limb for the upper limb).
- Lesions of the posterior one-third of the posterior limb, and sublenticular and retrolenticular parts of the internal capsule lead to visual (hemianopia) and auditory (loss of hearing) defects. These lesions usually occur due to thrombosis of the **anterior choroidal artery**, a branch of internal carotid artery.

Fornix

The fornix is described in detail on [page 231](#).

Lateral Ventricles

There are two lateral ventricles one in each cerebral hemisphere. Each lateral ventricle is a roughly C-shaped cavity situated within each cerebral hemisphere. The lateral ventricle wraps itself around the thalamus, the lentiform nucleus, and the caudate nucleus. It is lined with ependyma and filled with cerebrospinal fluid. It has a capacity of about 7–10 ml. The main parts of two ventricles are separated from each other by a septum extending between corpus callosum and fornix called **septum pellucidum**. The septum pellucidum is a thin vertical sheet of nervous tissue consisting of grey and white matter, and covered on either side by the ependyma.

Each lateral ventricle communicates with the third ventricle through the interventricular foramen (of Monro). Most of the CSF in the CNS is produced by the choroid plexuses of two lateral ventricles.

The projection of ventricles on the surface of the brain is shown in [Figure 14.13](#).

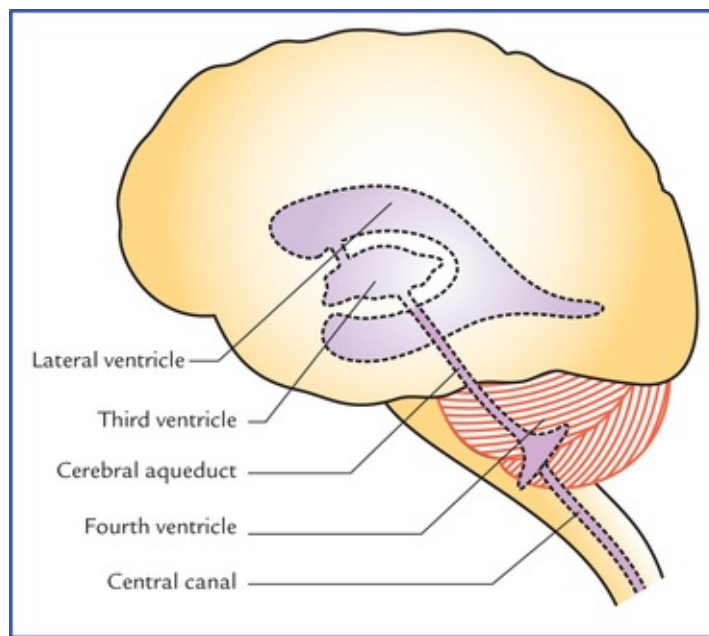


FIG. 14.13 Surface projection of ventricles on the left lateral aspect of the brain.

Parts of Lateral Ventricle (Fig. 14.14)

For descriptive purposes, each lateral ventricle is divided into four parts:

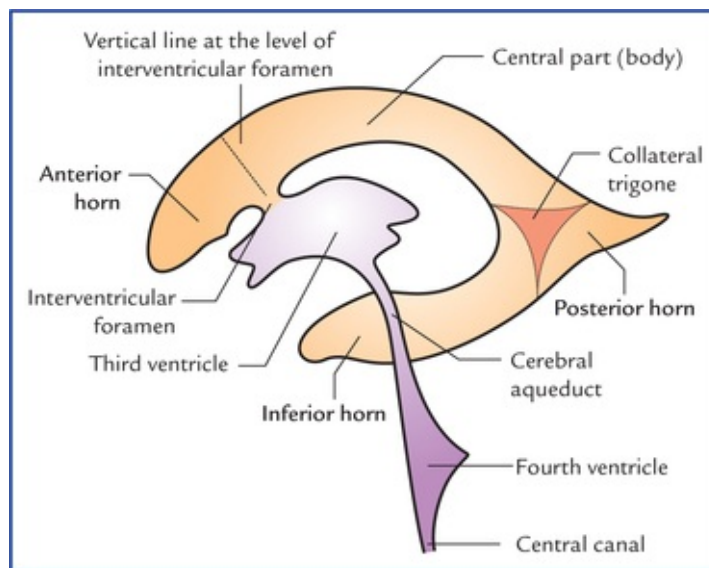


FIG. 14.14 Ventricular system of the brain; lateral view. Note the different parts of the lateral ventricle.

- **Central part or body** lies mostly within the parietal lobe and extends from interventricular foramen in front to the splenium of the corpus callosum behind.
- **Anterior horn** is the anterior extension from the central part into the frontal lobe and, lies in front of interven-tricular foramen and behind the posterior surface of the genu of corpus callosum.
- **Posterior horn** is the backward extension from the central part into the occipital lobe towards the occipital pole.
- **Inferior horn** is considered as the direct continuation of the main ventricular cavity into the temporal lobe. The inferior horn is the largest of the three horns. It begins where the central part and posterior

horn meet and curves round the pulvinar of thalamus into the temporal lobe to end about 2.5 cm behind the temporal pole.

N.B. The posterior horn is the most recent one in evolution scale amongst the three horns.

Boundaries of the Different Parts of Lateral Ventricle

Central part or body

Central part or body is triangular in shape in coronal section with a medial wall, a roof, and a floor (Fig. 14.15).

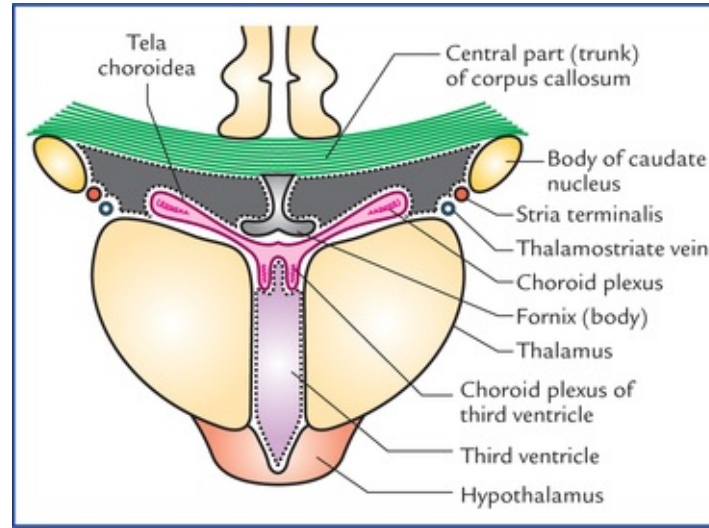


FIG. 14.15 Boundaries of the central part of the lateral ventricle.

The **roof** is formed by the under surface of the body (trunk) of the corpus callosum.

The **floor** slopes downwards from lateral to the medial side and is formed in that order by:

- Body of caudate nucleus.
- Stria terminalis and thalamostriate vein.
- Lateral part of the upper surface of the thalamus.
- Choroid plexus covering the medial part of the upper surface of the thalamus.
- Upper surface of the body of fornix.

The **medial wall** is formed by the septum pellucidum.

Anterior (frontal) horn

Anterior horn is roughly triangular in coronal section, and presents roof, floor, anterior, medial and lateral walls (Fig. 14.16).

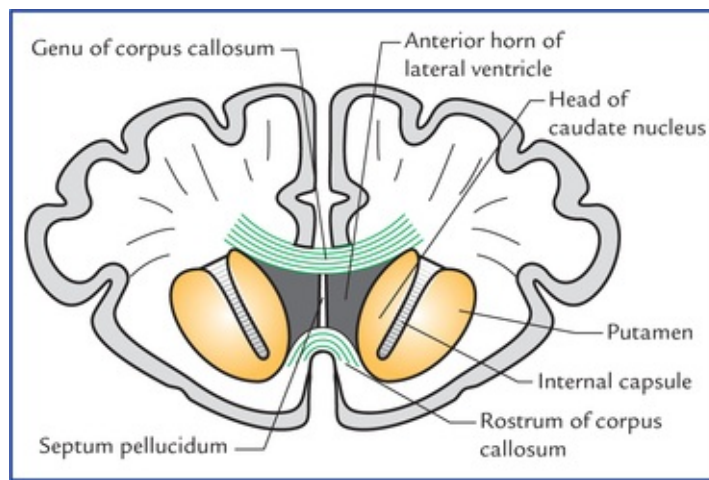


FIG. 14.16 Coronal section of brain at the level of rostrum of corpus callosum, showing boundaries of anterior horn of the lateral ventricle.

The **roof** is formed by the undersurface of the anterior part of the body of corpus callosum.

The narrow **floor** is formed by the upper surface of the rostrum of corpus callosum.

The **anterior wall** is formed by the genu of the corpus callosum.

The **medial wall** is formed by the septum pellucidum.

The **lateral wall** is formed by the bulging head of the caudate nucleus.

Posterior (occipital) horn

Posterior horn is quadrangular or diamond-shaped in coronal section and presents roof, lateral wall, floor, and medial wall (Fig. 14.17).

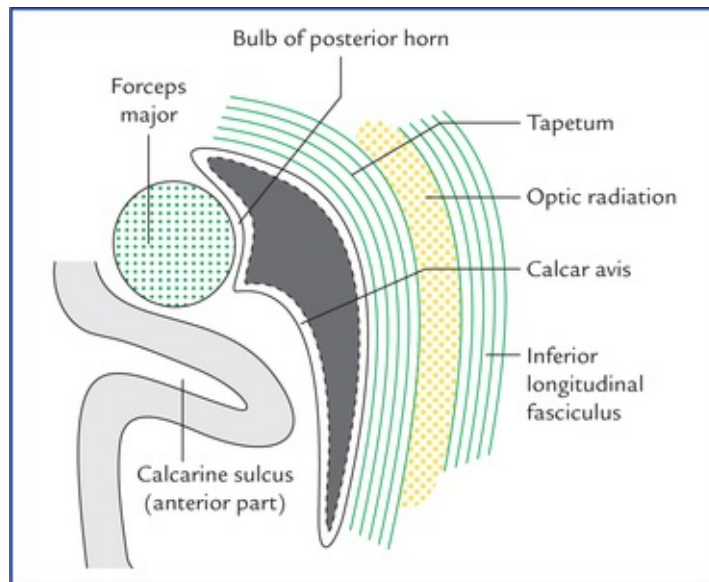


FIG. 14.17 Boundaries of posterior horn of the lateral ventricle.

The **roof**, **lateral wall**, and **floor** are formed by a sheet of fibres (*tapetum*) from the splenium of the corpus callosum. The posteriorly sweeping fibres of the *optic radiation* remain separated from the cavity of the posterior horn by the tapetum.

The **medial wall** is invaginated by two ridges; the upper of these, the *bulb of posterior horn* is formed by the fibres of forceps major and the lower one, the **calcar avis** is produced by the anterior part of the

calcarine sulcus.

Inferior (temporal) horn

The inferior horn is the largest and longest of the three horns. It begins where the central part and posterior horn meet. From here it curves ventrally downwards and forwards into the temporal lobe. The area where inferior horn and posterior horn diverge is called **collateral trigone** (Fig. 14.14). The inferior horn lies more or less parallel to the superior temporal sulcus and in coronal section appears as a transverse-slit presenting roof and floor (Fig. 14.18).

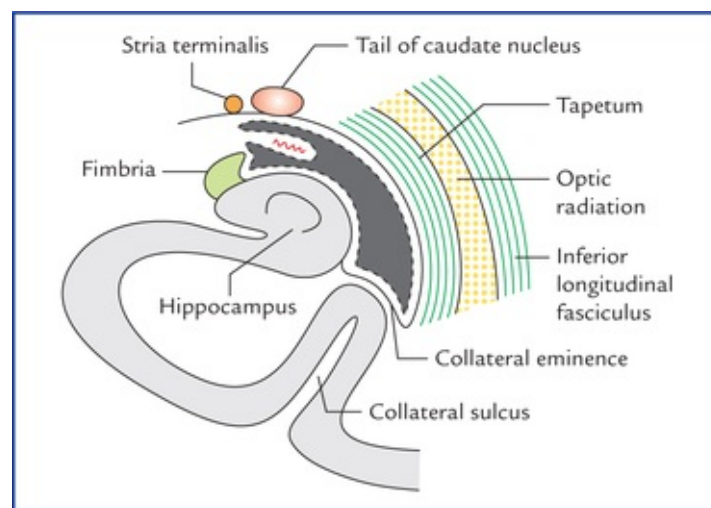


FIG. 14.18 Boundaries of inferior horn of lateral ventricle as seen in coronal section of brain.

The lateral part of the **roof** is formed by tapetum of corpus callosum, and the medial part by the *tail of caudate nucleus* and *stria terminalis*.

The **floor** presents following features from lateral to medial side:

- *Collateral eminence*, an elongated swelling in the lateral part of the floor, produced by the *collateral sulcus*, which is deep enough to produce this elevation.
- *Hippocampus*, an another longitudinal elevation lying parallel and medial to the collateral eminence. The fibres of hippocampus form a thin sheet of white matter called **alveus** that covers its ventricular surface. The fibres of alveus converge medially to form a ridge called **fimbria** (for detail see [page 232](#)).
- *Choroid plexus*: Most medially the floor is occupied by the choroid plexus that passes into the inferior horn through the *choroid fissure* lying between the fimbria below, and the stria terminalis and the tail of the caudate nucleus above.

Choroid plexus and choroid fissure

On the medial aspect of the cerebral hemisphere, along the C-shaped line between the diencephalon and hemisphere, the medial wall of the central part and inferior horn of the lateral ventricle is made up of only ependyma. The pia mater covering the ependyma along this C-shaped line is invaginated by the fringe-like tuft of blood vessels into the central part and inferior horn to form the **choroid plexus of the lateral ventricle**. The line of invagination of the choroid plexus into the lateral ventricle is called **choroid fissure**.

At the interventricular foramina, the choroid plexus of one lateral ventricle is continuous with its

counterpart of the other side across the third ventricle.

The choroid plexus of lateral ventricle is derived from *anterior choroidal artery*, a branch of internal carotid artery and the *posterior choroidal artery* a branch of posterior cerebral artery.

Clinical Correlation

- The general form of the ventricular system of the brain can be visualised by:
 - (a) *computerized axial tomography* (CT scanning), and magnetic resonance imaging (MRI), and
 - (b) *ventriculography*, a radiological technique in which a small quantity of air or oxygen is introduced via a needle into the lateral ventricle through a burr hole in the skull (in children below two years of age, the needle is inserted through the lateral angle of the anterior fontanelle).
- The outline of ventricles and cerebral gyri can be visualized by **air encephalography** (also called *pneu-moencephalography*) in which the air or oxygen is introduced into the subarachnoid space through lumbar puncture. The air readily replaces the CSF within the ventricles and subarachnoid space. The air or gas being less dense than the fluid or neural tissue, the ventricles and cerebral gyri are easily visualized.

Clinical Problems

1. Explain, why the congenital absence of corpus callosum goes unnoticed by an individual or even by the physician?
2. Explain, why a small lesion in the internal capsule has a widespread sensory and motor effect as compared to that in the corona radiata?
3. A 'CT scan' of skull of older individuals (transverse cuts) through the level of the anterior horns of the lateral ventricles often shows three small calcified shadows: one in the midline, and one on each side in the region of posterior horn of lateral ventricle. Name the structures of the brain which give rise to these shadows and why?

Clinical Problem Solving

1. The cortex of the right cerebral hemisphere controls the muscular activity of, and receives sensory input from the left half of the body; on the other hand, the left cerebral hemisphere controls the muscular activity of and receives the sensory input from the right half of the body. The two hemispheres thus can perform most of the day-to-day motor and sensory functions independently. Therefore, in day-to-day life the patient does not notice any definite neurological disorder and carry on his day-to-day activities perfectly well. For this reason, it goes unnoticed by an individual or even by the physician (also see [page 164](#)).
2. A small lesion in the internal capsule produces extensive motor and sensory effects

because the internal capsule consists of the huge number of motor and sensory fibres which are packed densely in a narrow space between the lentiform nuclei laterally, and the caudate nucleus and thalamus medially. A similar lesion in corona radiata may have little or no effects as here, the fibres are widely separated from each other.

3. The midline shadow indicates the calcified pineal gland while the lateral shadows are due to calcified deposits in the choroid plexuses of the lateral ventricles.

It is important to note that with age:

- (a) the calcium phosphates and carbonates get deposited in the pineal gland (*see page 133*), and
- (b) the choroid plexuses of lateral ventricles especially in their posterior horns show calcified deposits.

Blood Supply of the Brain

The continuous blood supply to the brain is of utmost importance because of its high metabolic demands for oxygen and glucose. It is highly sensitive to hypoxia (inadequate O_2) and hypoglycaemia (subnormal concentration of glucose in the blood). The consciousness is lost within 10 seconds of cessation of blood flow, and if the state continues, an irreversible brain damage starts to occur at about 4 minutes and is completed within 10 minutes.

The brain is one of the most metabolically active organs of the body as it depends on aerobic metabolism of glucose.

Although the brain constitutes only 2% (1/50) of the total body weight, it receives 20% (1/5) of the total cardiac output and consumes 20% of the total O_2 used by the body.

The cerebrovascular diseases (thrombosis, embolism and haemorrhage) are the third most common cause of death and the neurological signs depend on the site of lesion. Therefore an adequate knowledge of the blood supply of the brain is essential for proper diagnosis and treatment of these diseases.

N.B. The arterial occlusion by a thrombus which often leads to infarction of the portion of the brain supplied by the affected artery is the most common type of the cerebrovascular disease.

Arteries of The Brain

The brain is supplied by the paired internal carotid and vertebral arteries via an extensive system of branches ([Fig. 15.1](#)):

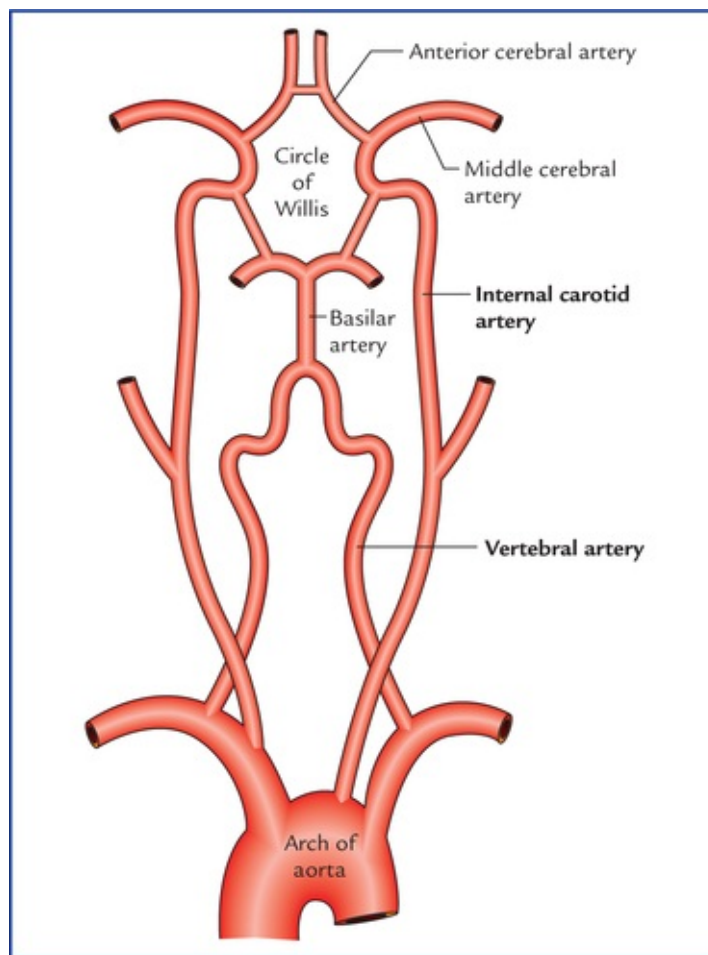


FIG. 15.1 Four arteries supplying the brain.

The **two vertebral arteries** unite at the lower border of the pons to form the *basilar artery* which ascends in the midline on the ventral surface of the pons and at its upper border terminates by dividing into right and left posterior cerebral arteries.

Each **internal carotid artery** ends in the region of anterior perforated substance by dividing into a larger middle cerebral artery, and a smaller anterior cerebral artery.

N.B. Thus the brain is supplied by two systems of arteries: (a) **vertebral system**, consisting of a pair of vertebral arteries, and (b) **carotid system**, consisting of a pair of internal carotid arteries.

Circle of Willis (circulus arteriosus)

The major arteries supplying the cerebrum (i.e. branches of basilar and internal carotid arteries) get interconnected to one another at the base of the brain to form a six-sided polygon of arteries called **circulus arteriosus** or **circle of Willis** (Figs. 15.2 and 15.3). The circle of Willis is formed around the interpeduncular fossa and lies in the *interpeduncular subarachnoid cistern*. It contributes most of the arterial blood supply to the brain.

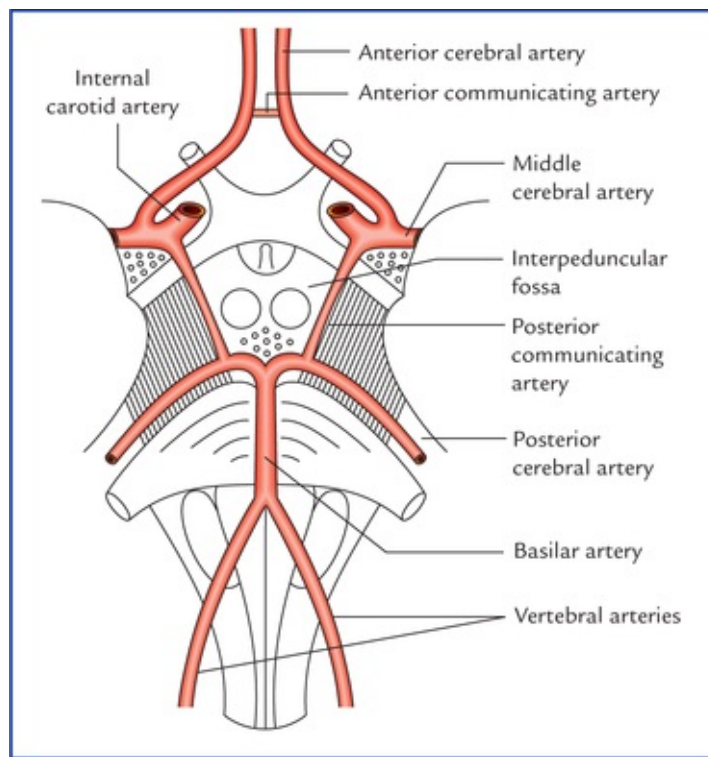


FIG. 15.2 Polygonal anastomoses between the branches of internal carotid and basilar arteries.

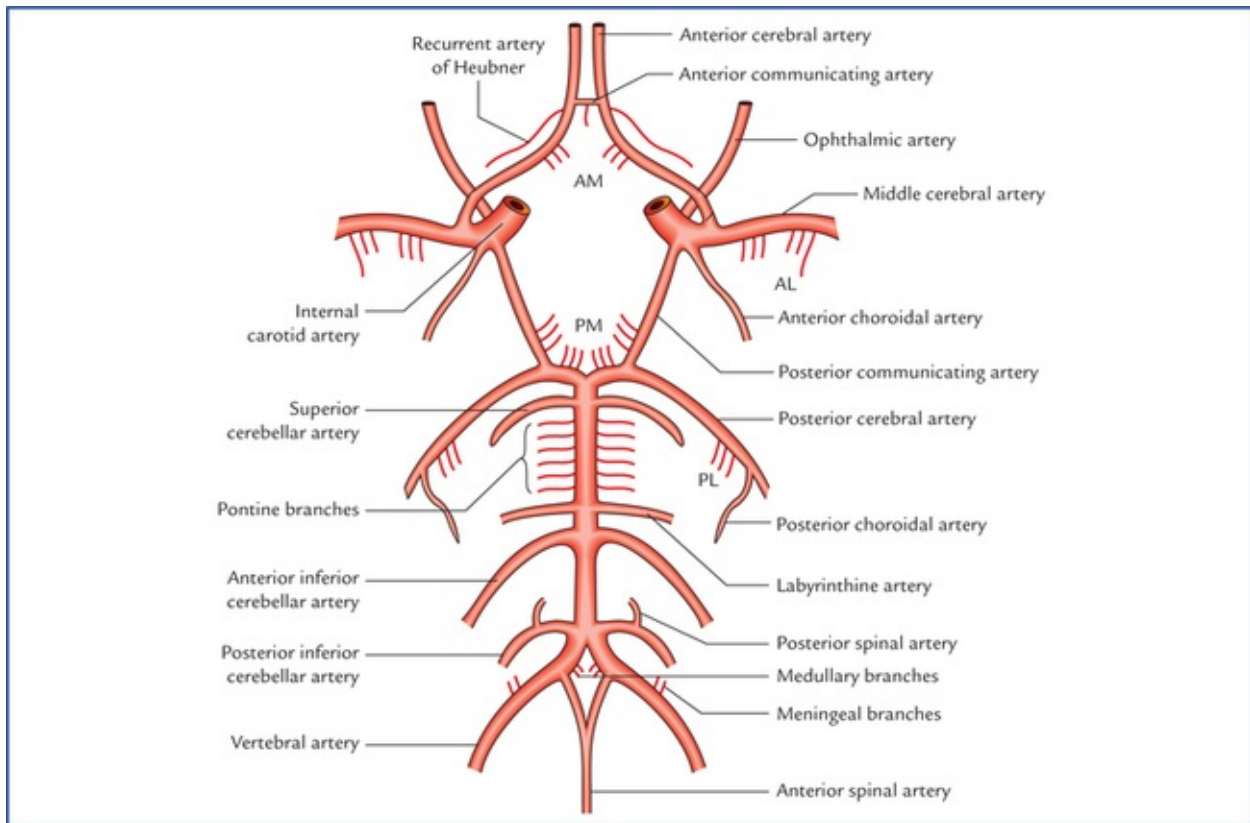


FIG. 15.3 Circle of Willis and the branches of arteries supplying the brain. The central branches of cerebral arteries are shown by abbreviations: AM = anteromedial group, PM = posteromedial group, AL = anterolateral group, PL = posterolateral group.

Circle of Willis is formed:

Anteriorly, by the anterior communicating and the anterior cerebral arteries.

Posteriorly, by the basilar artery dividing into two posterior cerebral arteries.

Laterally on each side, by the posterior communicating artery connecting the internal carotid artery with the posterior cerebral artery.

Functional significance of circle of Willis

Normally there is little or no mixing of blood streams: (a) of two vertebral arteries in the basilar artery, (b) of two anterior cerebral arteries in the anterior communicating artery, and (c) of internal carotid and posterior cerebral arteries in the posterior communicating artery. Therefore, right half of the brain is supplied by right vertebral and right internal carotid arteries and left half of the brain is supplied by left vertebral and left internal carotid arteries.

However, if one of the major arteries forming the circle of Willis is blocked, the circle of Willis provides the various alternative routes for **collateral circulation** like an **arterial traffic circle**.

Clinical Correlation

- **Congenital cerebral aneurysms**

These occur mostly at the sites where two arteries join in the formation of the circle of Willis. The basic abnormality at these points is the congenital deficiency of the tunica media (elastic tissue) in the arterial wall. The aneurysms are berry-shaped, hence they are generally termed **berry aneurysms**.

- **Subarachnoid haemorrhage**

The subarachnoid haemorrhage commonly but not exclusively results from rupture of congenital berry aneurysms in the interpeduncular cistern.

The subarachnoid haemorrhage produces a sudden severe pain in head followed by mental confusion. The death may quickly occur, or the patient may survive the first bleeding only to die few days or weeks later.

Vertebral System

Vertebral artery (Fig. 15.4)

The **vertebral artery**, a branch of subclavian artery, ascends in the foramina transversaria of upper six cervical vertebrae. On reaching the base of skull, it winds backwards and medially around the lateral mass of the atlas and pierces posterior atlanto-occipital membrane, to enter the posterior cranial fossa through the foramen magnum where it runs on the anterolateral aspect of the medulla. Here the two vertebral arteries converge, and unite at the lower border of the pons to form the **basilar artery** (Fig. 15.4).

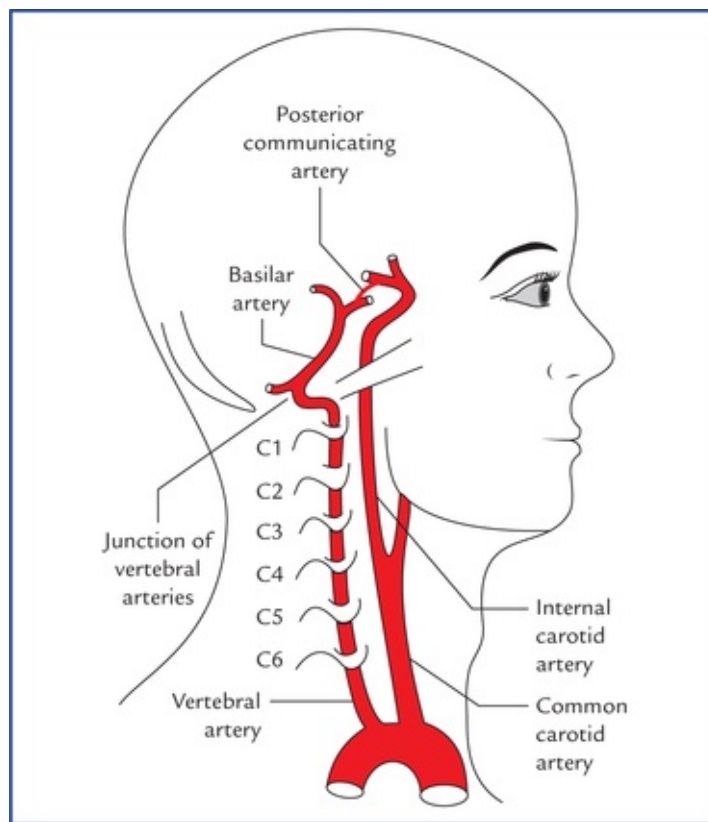


FIG. 15.4 Origin and course of internal carotid and vertebral arteries.

Clinical Correlation

The loop of vertebral artery around the lateral mass of atlas may damp down the arterial pulsations within the cranial cavity.

Branches of the cranial part of the vertebral artery (Fig. 15.3)

- **Anterior spinal artery** is a small branch arising near the termination of the vertebral artery. It descends in front of the medulla and unites with its fellow of the opposite side at the level of the lower end of the olive to form a single median trunk that descends along the anterior longitudinal fissure of the spinal cord.
- **Posterior spinal artery** arises from vertebral artery and sometimes from posterior inferior cerebellar artery. It passes downwards on the posterior surface of the spinal cord, after dividing into two branches; one along the medial side, and the other along the lateral side of the dorsal roots of the spinal nerves.
- **Posterior inferior cerebellar artery** is the largest branch of the cranial (4th) part of the vertebral artery. It arises near the lower end of the olive, winds backwards around the medulla oblongata, and then ascends to the pon-tomedullary junction.
- **Meningeal branches** are small and supply the dura mater of the posterior cranial fossa.
- **Medullary arteries** are several minute vessels which supply the medulla oblongata.

Basilar artery (Figs 15.1–15.3)

Basilar artery is formed by the union of two vertebral arteries at the lower border of the pons. It ascends in the basilar sulcus on the ventral aspect of the pons in the *cis-trema pontis* and terminates at the upper border of the pons by dividing into right and left *posterior cerebral arteries*.

Branches of basilar artery

- **Pontine branches** are numerous short slender paramedian vessels which pierce the pons to supply it.
- **Anterior inferior cerebellar artery** arises close to the lower border of the pons and runs backwards and laterally usually ventral to the VIIth and VIIIth cranial nerves. Then it forms a loop over the flocculus of the cerebellum and peeps into the internal acoustic meatus for a variable distance lying below the VIIth and VIIIth cranial nerves. After exit from the meatus it supplies the anterolateral portion of the inferior surface of the cerebellum.
- **Labyrinthine artery** is a long slender branch which arises either from basilar artery or from anterior inferior cerebellar artery. It accompanies the vestibulocochlear nerve and enters the internal auditory meatus to supply the internal ear. It is an end artery.
- **Superior cerebellar artery** arises close to the superior border of the pons, runs laterally below the oculomotor nerve (which is interposed between this artery and the posterior cerebral artery), and winds round the cerebral peduncle below the trochlear nerve to reach the superior surface of the cerebellum which it supplies.
- **Posterior cerebral artery** passes laterally parallel to the superior cerebellar artery, curves around the midbrain to reach the medial surface of the cerebral hemisphere, beneath the splenium of corpus callosum (Figs 15.5 and 15.6). The artery gives off **temporal branches** which ramify over the inferior surface of the temporal lobe, and calcarine and parieto-occipital branches which run along the corresponding sulci.

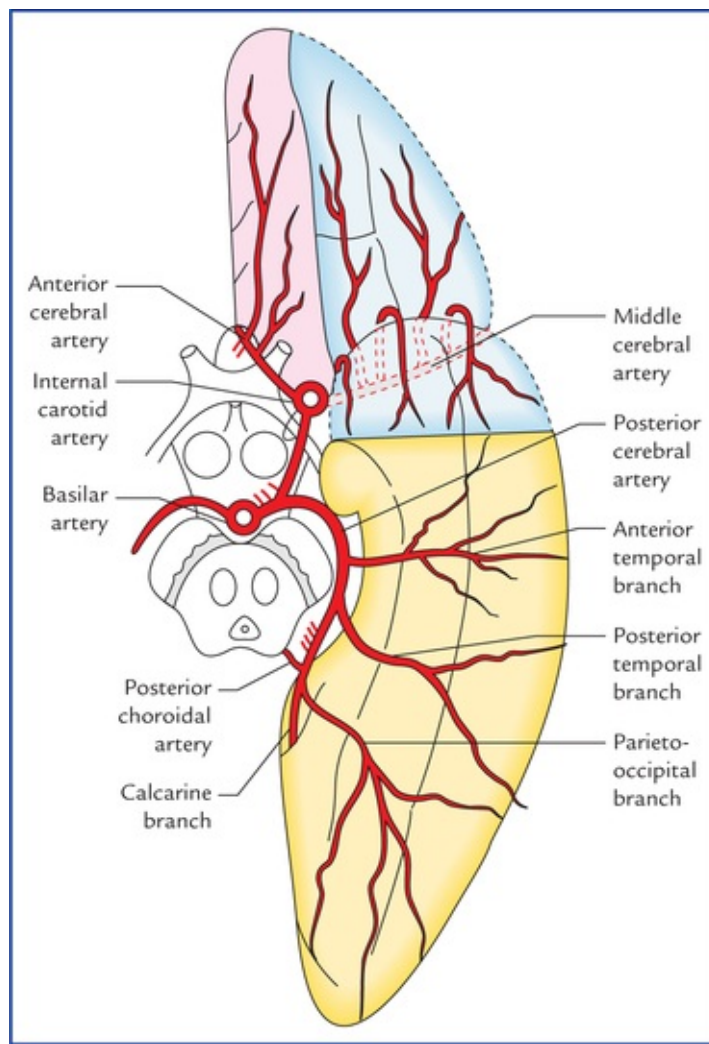


FIG. 15.5 Arteries on the inferior surface of the cerebral hemisphere.

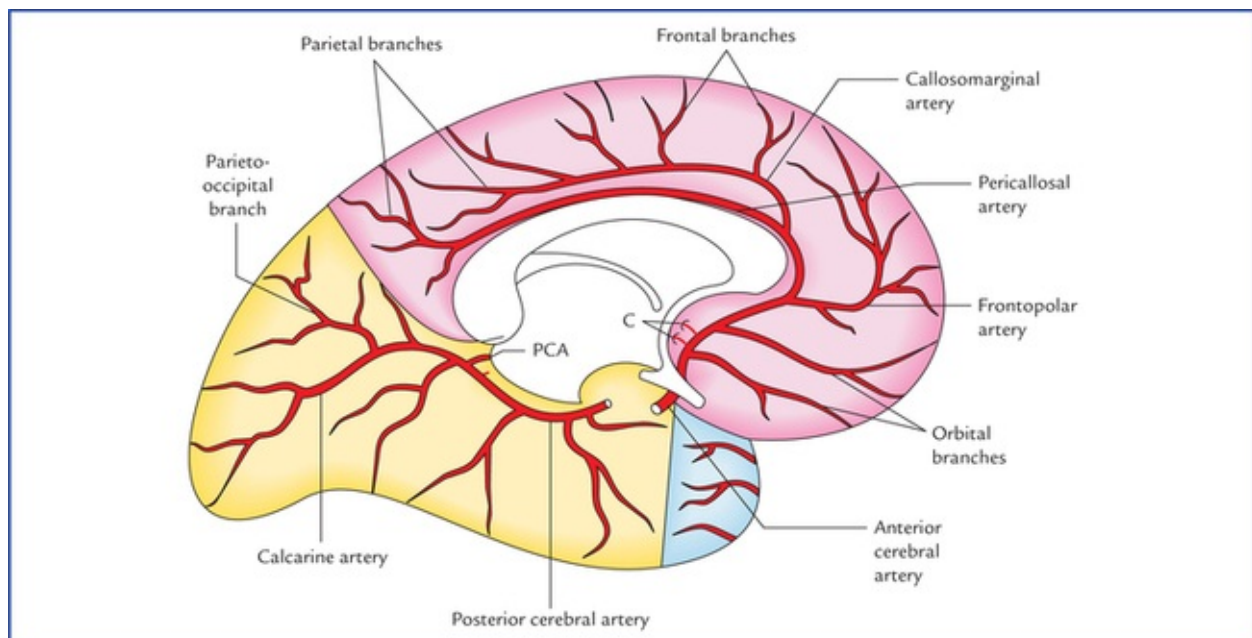


FIG. 15.6 Arteries on the inferomedial aspect of the cerebral hemisphere. (C = central branches, PCA = posterior choroidal artery.)

1. *Anterior temporal branch* passes forwards.
2. *Posterior temporal branch* passes posteriorly towards the occipital pole.
3. *Parieto-occipital branch* runs towards the parieto-occipital sulcus.
4. *Calcarine branch* (often called **calcarine artery**) passes posteriorly in the calcarine sulcus.

Carotid System

Internal carotid artery (Fig. 15.4)

The **internal carotid artery**, a terminal branch of the common carotid artery, traverses the carotid canal in the base of the skull and enters the middle cranial fossa beside the dorsum sellae of the sphenoid bone. Here it first runs forwards along the floor and medial wall of the cavernous sinus and then turns upwards on the medial side of the anterior clinoid process. At this point the artery pierces the dural roof of the cavernous sinus and also the arachnoid mater to enter the subarachnoid space. Now it first runs backwards and then upwards to come to lie lateral to the optic chiasma just underneath the anterior perforated substance of the brain, where it terminates by dividing into two branches, a larger **middle cerebral artery** and a smaller **anterior cerebral artery** (Figs 15.2 and 15.3).

Clinical Correlation

The intracavernous and supracavernous course of internal carotid artery forms a U-shaped bend (hair-pin bend) with convexity forward called **carotid siphon**. The siphon dampens the arterial pulsations to provide a more steady regular stream of blood flow to the brain.

The carotid siphon is an important part of the cerebral angiogram to inspect, for masses in the pituitary region will open out (widen) the curl in the artery.

Branches of the cerebral part of the internal carotid artery (Fig. 15.3)

- **Ophthalmic artery** arises from the ventral convexity of the carotid siphon and enters the optic canal to reach the orbital cavity to supply the structures of the orbit including eyeball.
- **Posterior communicating artery** arises close to the termination of the internal carotid artery. It runs backwards and anastomoses with the proximal part of the posterior cerebral artery.
- **Anterior choroidal artery** is a long slender branch, which arises just distal to the origin of the posterior communicating artery. It courses backwards above and along the optic tract, to enter the inferior horn of the lateral ventricle through the choroid fissure to end in the choroid plexus.

*Due to its long subarachnoid course and a relatively small lumen, the anterior choroidal artery is most susceptible to thrombosis and is often referred to as **artery of cerebral thrombosis**.*

- **Anterior cerebral artery** is a smaller terminal branch of the internal carotid artery. It runs forwards and medially above the optic nerve to the commencement of the median longitudinal cerebral fissure, where it comes very close to its fellow of the opposite side and gets joined with it by a short transverse *anterior communicating artery*. The anterior cerebral artery then curves around the genu of corpus callosum.

The branches given off just distal to the anterior communicating artery supply the medial part of the orbital surface of the frontal lobe.

The artery continues along the upper surface of the corpus callosum as the **pericallosal artery** and gives a large branch, the **callosomarginal artery** which runs in the cingulate sulcus. Near the splenium of corpus callosum, the artery ends by anastomosing with the branches of the posterior cerebral artery.

Clinical Correlation

The arched course of the anterior cerebral artery around the genu of corpus callosum makes it easy to identify it in a carotid angiogram.

- **Middle cerebral artery** is the larger terminal branch of the internal carotid artery. It appears to be the direct continuation of the internal carotid artery and carries about 30% of the carotid blood flow. The middle cerebral artery first runs laterally in the stem of the lateral sulcus (Fig. 15.5) and then turns backwards and upwards in the posterior ramus of the lateral sulcus, where it breaks up into frontal, parietal and temporal branches which emerge from the lateral sulcus and run towards the areas of their supply. Some of these branches are named (Fig. 15.7).

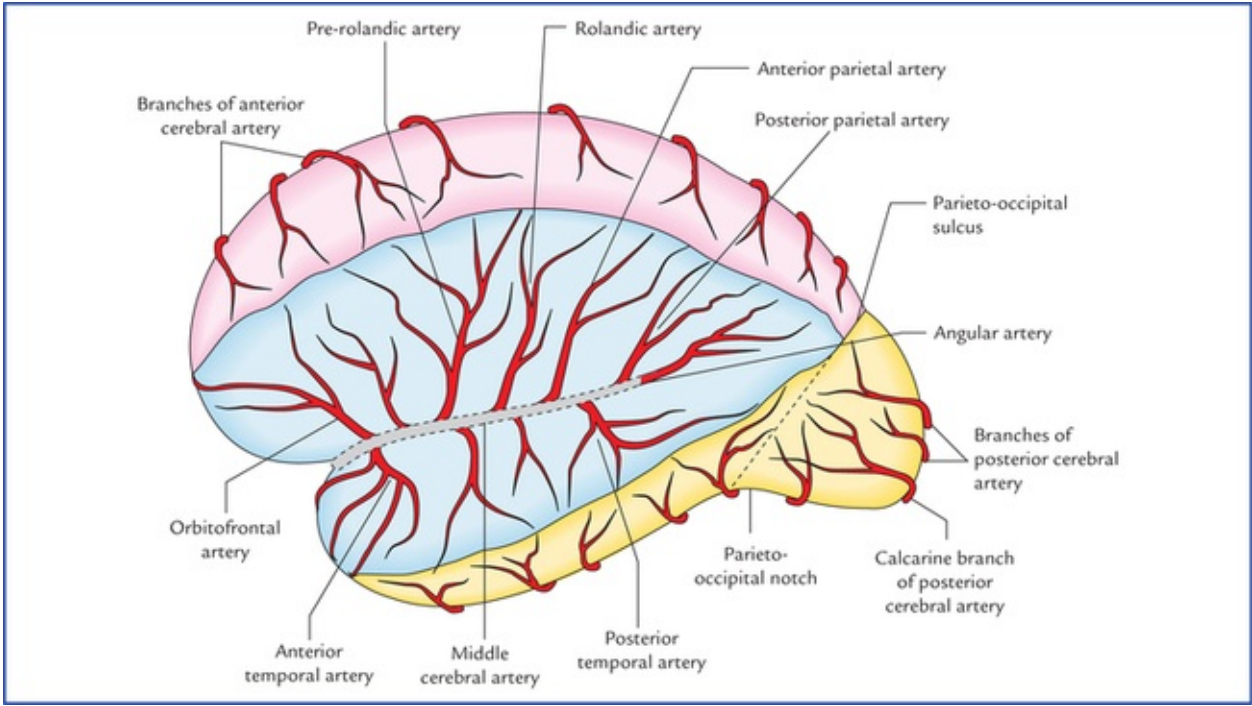


FIG. 15.7 Arteries on the superolateral surface of the left cerebral hemisphere.

The branches of main arteries supplying the brain are summarized in [Table 15.1](#)

Table 15.1
Branches of the main arteries of the brain

Cerebral part of internal carotid artery	Fourth part of vertebral artery	Basilar artery
• Ophthalmic artery	• Meningeal arteries	• Anterior inferior cerebellar artery

• Anterior cerebral artery	• Anterior spinal artery	• Labyrinthine artery
• Middle cerebral artery	• Posterior spinal artery	• Pontine arteries
• Posterior communicating artery	• Posterior inferior cerebellar artery	• Superior cerebellar artery
• Anterior choroidal artery	• Medullary arteries	• Posterior cerebral artery

It is interesting to note from [Table 15.1](#) that each main artery supplying the brain gives off **five sets of branches** thus making a total of **15 sets**. Out of which there are: **three pairs of cerebral arteries** (anterior, middle, and posterior) and **three pairs of cerebellar arteries** (posteroinferior, anteroinferior, and superior).

Clinical Correlation

The cerebral thrombosis most commonly affects middle cerebral artery or its main branches because it is a direct continuation of internal carotid artery.

Arterial Supply of the Cerebrum

The cerebrum is supplied by three pairs of cerebral arteries, viz. anterior, middle and posterior.

Branching pattern of the cerebral arteries

The cerebral arteries give three types of branches: (a) cortical, (b) central, and (c) choroidal.

Cortical branches

Cortical branches supply the outer portion of the cerebrum. The cortical vessels freely anastomose and form a network in the pia mater on the surface of the cerebral cortex. From this network branches arise and pierce the cortex at right angle. Once they enter the cortex, they become the *end arteries*. There are two types of these end arteries: (a) short, which confine themselves only to the cortex, and (b) long, which pass through the cortex and reach the outer portion of the white matter.

Central branches (Fig. 15.3)

Central branches are numerous slender thin-walled perforating branches which supply the centrally located parts of the cerebrum, viz. corpus striatum, internal capsule, etc. They are *end arteries*. The central arteries arise in the region of arterial circle of Willis, and are arranged into following four groups:

- **Anteromedial group:** They arise from anterior cerebral and anterior communicating arteries, enter the anterior perforated substance to supply the anterior limb of internal capsule, the corpus striatum and the anterior hypothalamus.
- **Anterolateral group (lateral striate arteries):** They arise from proximal part of the middle cerebral artery, pierce the anterior perforated substance to supply the anterior limb of the internal capsule, and the caudate and lenti-form nuclei. One of the larger lateral striate arteries which is most susceptible to rupture, is known as the **artery of cerebral haemorrhage** (also called **Charcot's artery of cerebral haemorrhage**).
- **Posteromedial group:** The arteries of this group arise from proximal part of the posterior cerebral artery and adjoining part of the posterior communicating artery. They enter the posterior perforated

substance to supply the thalamus, the subthalamus and the hypothalamus.

- **Posterolateral group:** These arteries arise from posterior cerebral artery after it has curved around the cerebral peduncle. They supply the thalamus including geniculate bodies.

Choroidal branches

Choroidal arteries form a network of capillaries which project into the ventricles after invaginating the layers of pia mater and ependyma forming **choroid plexuses**.

- **Anterior choroidal artery:** It arises from internal carotid artery, runs posteriorly near the optic tract, crosses the uncus to enter the choroidal plexus in the inferior horn of lateral ventricle.
- **Posterior choroidal artery:** It arises from the posterior cerebral artery, encircles around the midbrain to enter the choroidal plexus of the third and lateral ventricles, through transverse fissure.

Arterial Supply of the Different Surfaces of the Cerebral Hemisphere

Arterial supply of the superolateral surface (Fig. 15.8A)

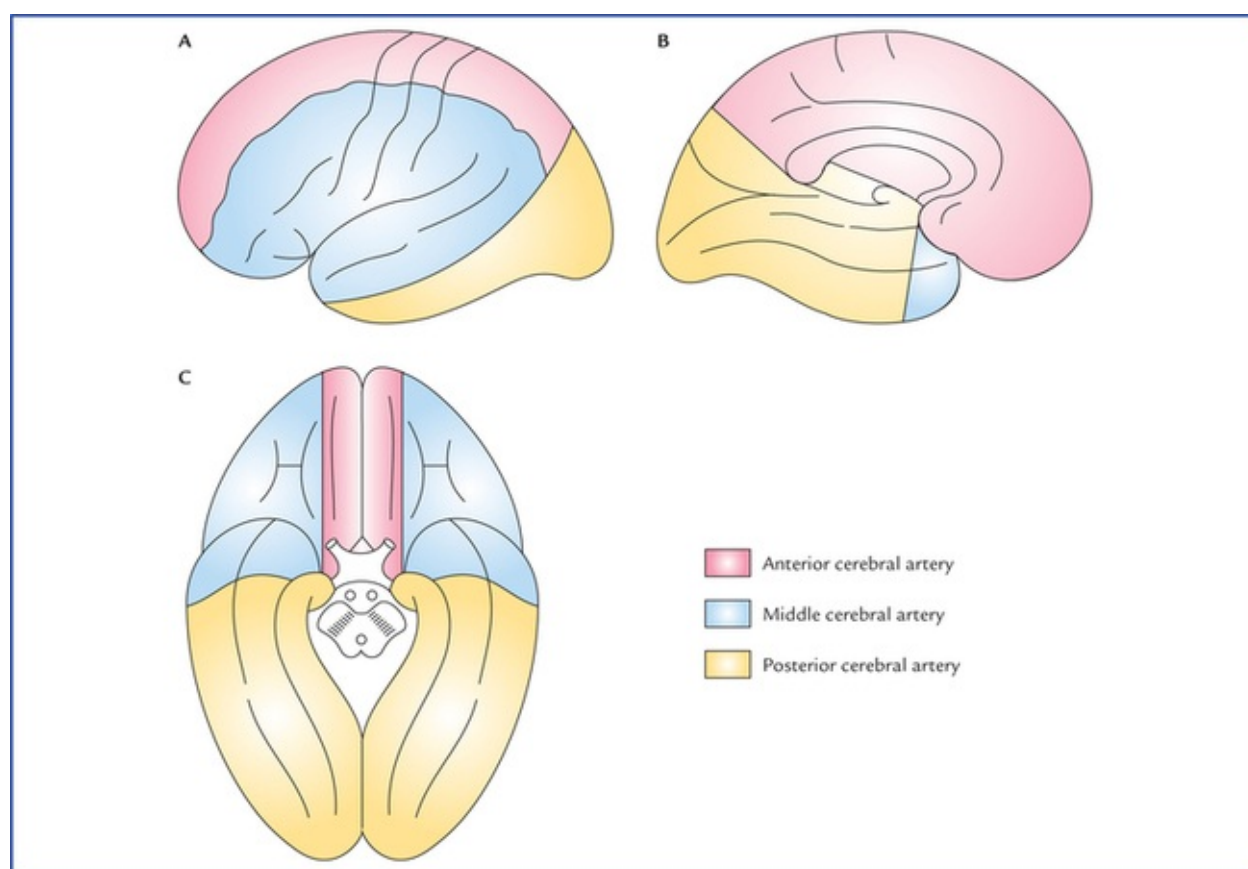


FIG. 15.8 Arterial supply of the superolateral (A), medial (B), and inferior (C) surfaces of the cerebral hemisphere.

- Most of the superolateral surface (about two-third) is supplied by the **middle cerebral artery**. The region of cerebral cortex supplied includes the greater parts of primary motor and sensory areas, and frontal eye field. In the left (dominant) hemisphere it includes the Broca's and Wernicke's speech areas.
- A narrow strip of cerebral cortex (about 2.5 cm in width) adjoining superomedial border up to the parieto-occipital sulcus is supplied by **anterior cerebral artery**. The upper parts of primary motor

and sensory areas lie in this region.

- A narrow strip along the lower border of temporal lobe (excluding temporal pole) and occipital lobe are supplied by **posterior cerebral artery**. The posterior parts of visual area fall in this area.

Arterial supply of the medial surface (Fig. 15.8B)

- Most of the medial surface (anterior two-third) is supplied by the **anterior cerebral artery**. The region of cerebral cortex supplied includes the parts of motor and sensory areas (paracentral lobule) concerned with perineum, leg, and foot.
- Temporal pole of the temporal lobe is supplied by the **middle cerebral artery**.
- Occipital lobe is supplied by **posterior cerebral artery**. The area supplied includes the visual cortex.

Arterial supply of the inferior surface (Fig. 15.8C)

- Most of the inferior surface except the temporal pole is supplied by the **posterior cerebral artery**.
- Lateral part of the orbital surface of the frontal lobe and temporal pole of the temporal lobe are supplied by the **middle cerebral artery**.
- Medial part of the orbital surface of the frontal lobe is supplied by the **anterior cerebral artery**.

Points to Note

Each surface of the cerebral hemisphere is supplied by three cerebral arteries, viz. anterior, middle and posterior.

Most of the superolateral surface is supplied by middle cerebral artery, most of medial surface by anterior cerebral artery, and most of the inferior surface by the posterior cerebral artery. Thus middle, anterior and posterior cerebral arteries are the principal arteries of the superolateral, medial and inferior surfaces of the cerebral hemisphere respectively.

Clinical Correlation

- The **occlusion of anterior cerebral artery** (distal to the anterior communicating artery) may produce following effects:
 - *Contralateral hemiparesis and hemianaesthesia involving mainly the leg and foot*, due to involvement of upper parts of primary motor and sensory areas, and paracentral lobule.
 - *Inability to identify the objects correctly*, due to involvement of superior parietal lobule.
 - *Apathy and personality changes*, due to involvement of part of frontal lobe.
- The **occlusion of middle cerebral artery** may produce following effects:
 - *Contralateral hemiplegia and hemianaesthesia*, involving mainly the face and arm, due to involvement of most of the primary motor and sensory areas.
 - *Aphasia* if left dominant hemisphere is involved, due to involvement of motor and sensory speech areas.
 - *Contralateral homonymous hemianopia*, due to involvement of optic radiation.
- The **occlusion of posterior cerebral artery** may produce following effects:
 - *Contralateral homonymous hemianopia*, due to involvement of visual cortex with some

degree of macular sparing. *The macular vision is spared because it is represented in the occipital pole which receives a collateral supply from the middle cerebral artery (anastomosis exists between the branches of middle and posterior cerebral arteries in the region of the occipital pole).*

Arterial Supply of the Other Parts of the Brain

- The **corpus striatum** and **internal capsule** are supplied mainly by central branches (medial and lateral striate arteries) of middle cerebral artery and to some extent by central branches of anterior cerebral artery (Fig. 15.9).

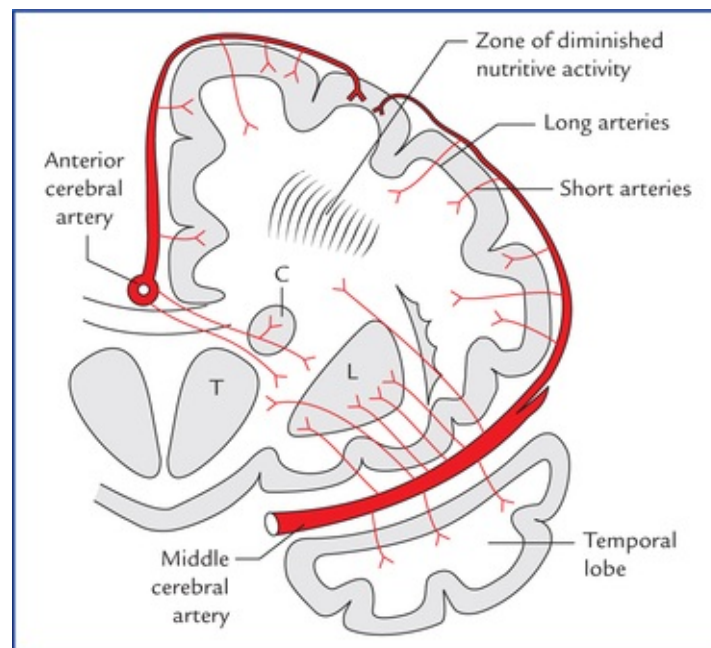


FIG. 15.9 Coronal section of cerebral hemisphere showing the arterial supply of the deep cerebral structures by middle and anterior cerebral arteries. (T = thalamus, C = caudate nucleus, L = lentiform nucleus. Also note the distribution of the cortical and central branches of the cerebral arteries, and zone of diminished nutrition.)

- The **thalamus** is supplied mainly by central branches of posterior communicating, posterior cerebral and basilar arteries.
 - The **midbrain** is supplied by posterior cerebral, superior cerebellar and basilar arteries.
 - The **pons** is supplied by basilar, superior cerebellar and anterior inferior cerebellar arteries.
 - The **cerebellum** is supplied by superior, anterior inferior, and posterior inferior cerebellar arteries.
- For details see the individual parts of the brain.

Clinical Correlation

- The **cerebral angiography** is a radiological technique to visualize the vessels of the brain. A radiopaque solution is injected into one of the major arteries supplying the brain, and serial radiographs of skull are taken at approximately 1 second intervals. The injection into the common carotid artery or the internal carotid artery (**carotid angiogram**) shows the

distribution of middle and anterior cerebral arteries; whereas the injection into the vertebral artery permits the visualization of vertebral, basilar and posterior cerebral arteries together with their branches. The cerebral angiography is valuable in identifying vascular malformations and aneurysms. It also provides useful information about occlusive vascular disease and space-occupying lesions.

- The cortical and central branches of cerebral arteries do not anastomose with each other. The short cortical arteries do not penetrate beyond the cerebral cortex while the long cortical arteries do traverse the cortex to supply the white matter up to a depth of 4 or 5 cm only. The deep portion of the white matter is supplied by the central branches. **There is however, a zone of diminished nutrition between the territories of cortical and central branches. The formation of cavities due to senile softening of brain mostly seen in this zone.**

Venous Drainage of The Brain

The veins of the brain drain into the intracranial dural venous sinuses, which eventually open into the internal jugular veins of the neck. The veins emerge from the brain, traverse the subarachnoid space, pierce the arachnoid mater and meningeal layer of dura mater to drain into the venous sinuses.

The characteristic features of venous drainage of the brain are:

- The venous return in the brain does not follow the arterial pattern.
- The veins of the brain are extremely thin-walled due to absence of muscular tissue in their walls.
- The veins of the brain possess no valves.
- The veins of the brain run mainly in the subarachnoid space.
- The cerebral veins, generally enter obliquely into the dural venous sinuses against the flow of blood in the sinuses to avoid their possible collapse following an increased intracranial pressure as they are thin walled.

The veins of the brain comprise, cerebral veins, cerebellar veins, and veins of the brainstem.

Cerebral Veins

The cerebral veins are divided into external and internal cerebral veins which drain the external surfaces and the internal regions of the cerebral hemisphere respectively.

External (superficial) cerebral veins

The external cerebral veins drain the surface (cortex) of the hemisphere and are divided into three groups: (a) superior, (b) middle, and (c) inferior.

Superior cerebral veins (Fig. 15.10)

Superior cerebral veins are about 8 to 12 in number and drain the upper parts of the superolateral and medial surfaces of the cerebral hemisphere. They ascend upwards, pierce the arachnoid mater and traverse the subdural space to enter the superior sagittal sinus.

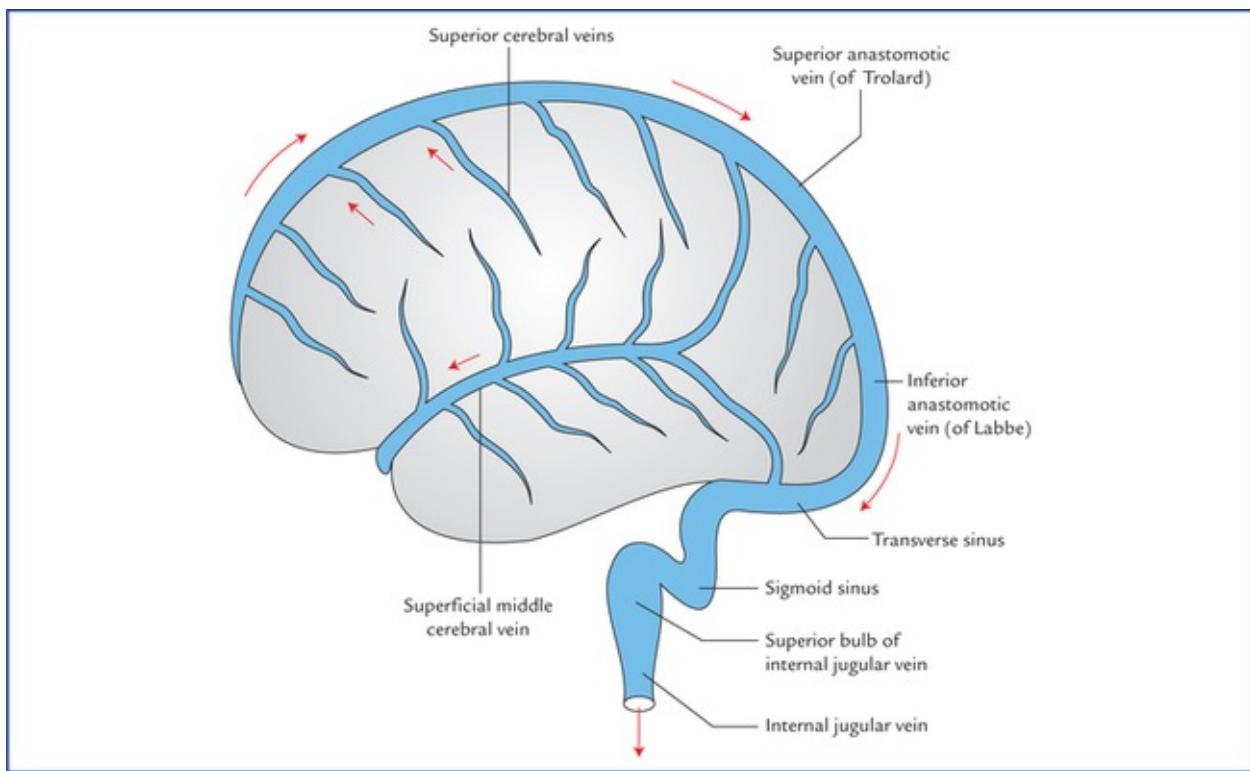


FIG. 15.10 Veins on the superolateral surface of the cerebral hemisphere.

The anterior veins open at right angle while the posterior open obliquely against the flow of blood stream in the superior sagittal sinus (*embryologically it is due to backward growth of the rapidly increasing cerebrum*), thereby preventing their collapse by increased CSF pressure.

Middle cerebral veins

Middle cerebral veins are four in number, two on each side: (a) superficial middle cerebral vein, and (b) deep middle cerebral vein.

- The **superficial middle cerebral vein** (Fig. 15.10) lies superficially in the lateral sulcus. Anteriorly it runs forwards to drain into the cavernous sinus while posteriorly it communicates with the superior sagittal sinus via **superior anastomotic vein (of Trolard)** and with the transverse sinus via **inferior anastomotic vein (of Labbe)**.
- The **deep middle cerebral vein** lies deep in the lateral sulcus on the insula along with middle cerebral artery. It runs downwards and forwards and joins the *anterior cerebral vein* to form the **basal vein**.

Inferior cerebral veins

Inferior cerebral veins are many in number but smaller in size. They drain the inferior surface and lower parts of medial and superolateral surfaces of the cerebral hemisphere into nearby intracranial dural venous sinuses, *viz.* transverse sinus, etc.

Other veins

Anterior cerebral vein (Fig. 15.11)

It accompanies the anterior cerebral artery around the corpus callosum and drains the parts of medial surface which cannot be drained into the superior and inferior sagittal sinuses.

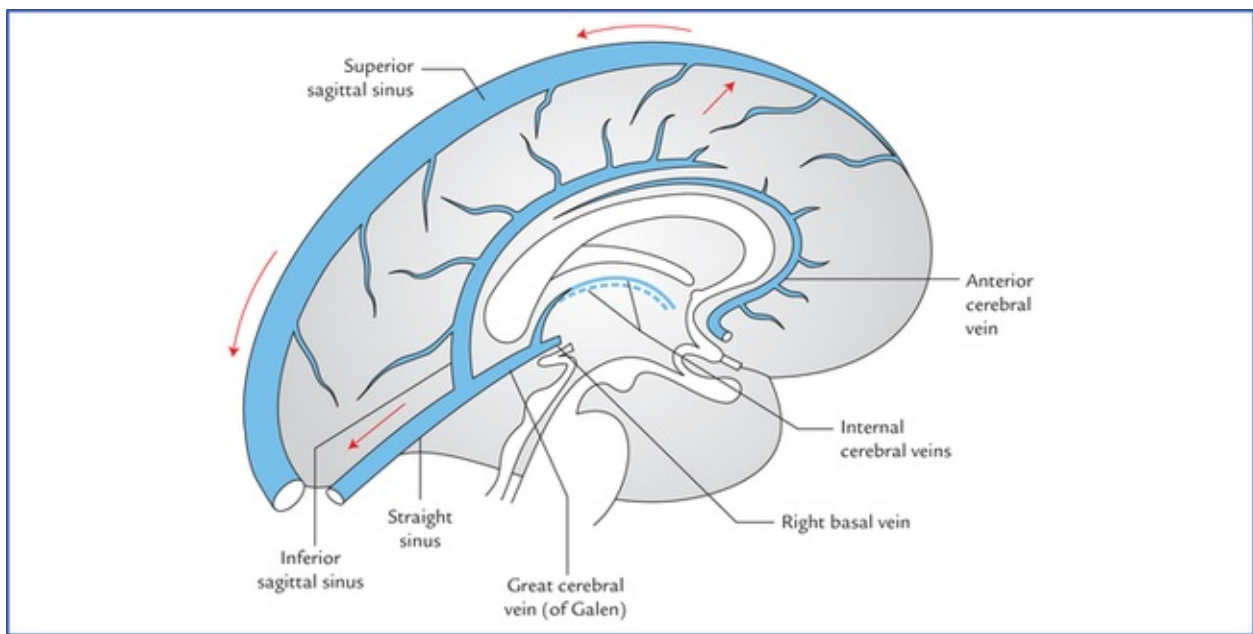


FIG. 15.11 Veins on the medial surface of the cerebral hemisphere.

N.B. The *anterior cerebral vein* is the only large vein of the brain which has a similar name and course as its companion artery (anterior cerebral artery).

Basal vein (of Rosenthal)

It is formed at the base of brain in the region of anterior perforated substance by the union of three veins: *anterior cerebral*, *deep middle cerebral* and *striate veins* (Fig. 15.12). The striate veins emerge from the anterior perforated substance.

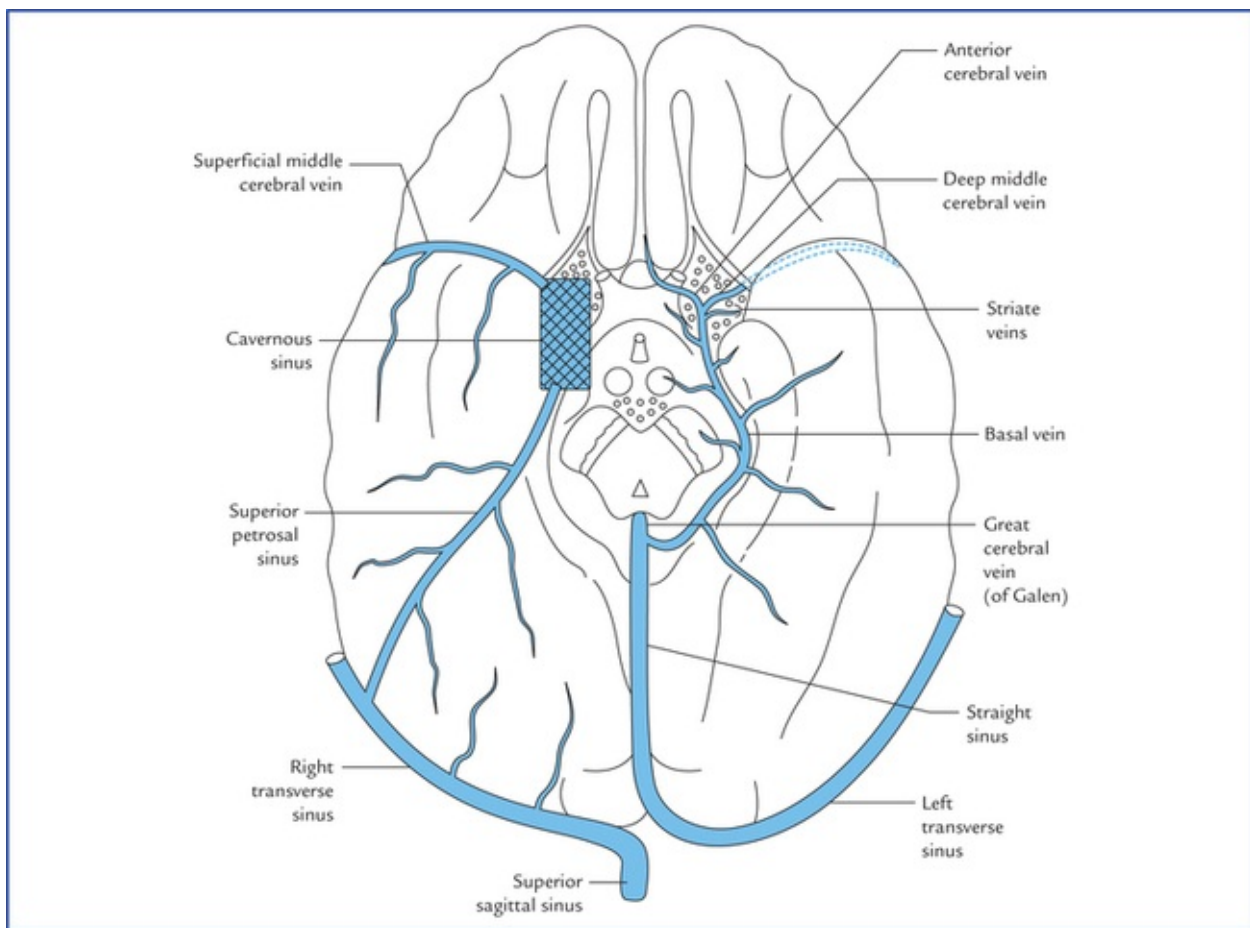


FIG. 15.12 Veins at the base of the brain. Note the formation, course and tributaries of the basal vein.

The basal vein runs posteriorly around the midbrain, medial to the uncus and parahippocampus and terminate into the **great cerebral vein (of Galen)** below the splenium of corpus callosum.

Tributaries

Besides the formative three veins, the basal vein receives the tributaries from:

- Cerebral peduncle
- Uncus and parahippocampus
- Structures of interpeduncular fossa
- Optic tract and olfactory trigone
- Inferior horn of the lateral ventricle.

Internal cerebral veins (Fig. 15.13)

There are two **internal cerebral veins** located one on either side of midline in the tela choroidea of the third ventricle.

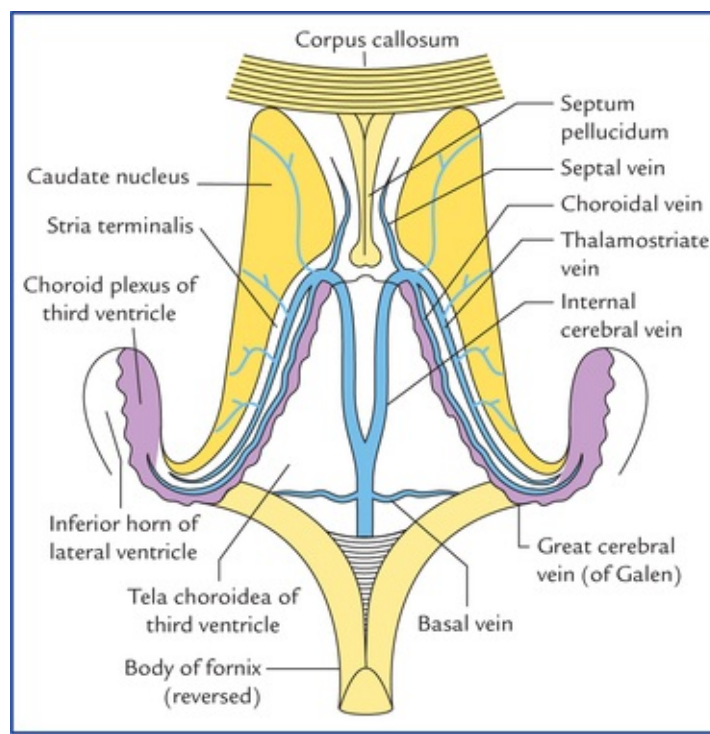


FIG. 15.13 Formation, course, and tributaries of the internal cerebral veins and the great cerebral vein of Galen.

Each internal cerebral vein is formed at the *interven-tricular foramen (of Monro)* by the union of three veins: thalamostriate, septal and choroidal. The two internal cerebral veins run posteriorly one on either side of mid-line, between the two layers of tela choroidea of third ventricle and unite together beneath the splenium of corpus callosum to form the **great cerebral vein (of Galen)** which empties into the straight sinus.

The *thalamostriate, septal and choroidal veins* are the most important deep veins of the cerebrum. As their names imply, the thalamostriate (striothalamic) vein drains the thalamus and basal ganglia; the septal vein drains the septum pellucidum, and the choroidal vein drains the choroid plexus.

Great cerebral vein (of Galen)

Great cerebral vein is a single vein (about 2 cm in length). It is formed by the union of two internal cerebral veins below and behind the splenium of corpus callosum. It immediately receives the two basal veins and after a short backward course it joins the inferior sagittal sinus to form the **straight sinus**.

Tributaries

- Internal cerebral veins
- Basal veins
- Veins from colliculi (tectum of midbrain)
- Veins from cerebellum and adjoining parts of the occipital lobes of the cerebrum.

Venous Drainage of the Different Surfaces of the Cerebral Hemisphere

Venous drainage of the superolateral surface

Superolateral surface is drained by the following veins:

- *Superior cerebral veins* drain the upper part into the *superior sagittal sinus*.

- *Inferior cerebral veins* drain the lower part into the *superficial middle cerebral vein*, however some from the pos-teroinferior part drain into the *transverse sinus*.

Venous drainage of the inferior surface

Inferior surface is drained by the inferior cerebral veins:

- *Inferior cerebral veins*, from the orbital part drains into the superficial, middle cerebral and anterior cerebral veins
- *Inferior cerebral veins*, from the tentorial part drains into:
 1. Venous sinuses at the base of skull, viz. cavernous, superior petrosal, straight and transverse sinuses;
 2. Superficial middle cerebral vein which drains into cavernous sinus and basal vein which drains into the straight sinus.

Venous drainage of the medial surface

Medial surface is drained by the following veins:

- Superior cerebral veins drain the upper part into superior sagittal sinus.
- Inferior cerebral veins drain the lower part into the inferior sagittal sinus.
- Some of the veins from the posterior part drain into the great cerebral vein.
- Anterior cerebral vein drains the anterior part.

N.B. From the above description, it is clear that the superficial veins drain mainly into the superior sagittal sinus, which ultimately drain into the right internal jugular vein. On the other hand the deep veins drain mainly into the great cerebral vein, which ultimately drain into left internal jugular vein.

Clinical Correlation

Subdural haemorrhage

It occurs due to rupture of cerebral veins in the sub-dural space. The cerebral veins while traversing the subdural space en route to drain into the dural venous sinuses have little support and are torn following moderate trauma on head. The superior cerebral veins are most commonly torn, where they enter the superior sagittal sinus. The cause is usually a blow on the front or back of the head, resulting in excessive anteroposterior displacement of the brain within the skull. Consequently the cerebral veins in the sub-dural space (called **bridging veins**) are unduly stretched and torn. The subdural haemorrhage is generally extensive because of the loose attachment between the dura and arachnoid.

the types of intracranial haemorrhage and vessels most commonly involved are summarized in [Table 15.2](#).

Table 15.2

Types of intracranial haemorrhage

Type of haemorrhage	Vessels/vessels most commonly involved
Extradural haemorrhage	Rupture of anterior division of middle meningeal artery
Subdural haemorrhage	Tearing of superior cerebral (bridging) veins
Subarachnoid haemorrhage	Leakage or rupture of congenital berry aneurysms on the arterial circle of Willis
Intracerebral (cerebral) haemorrhage	Rupture of thin-walled lenticulostriate artery (Charcot's artery of cerebral haemorrhage), a branch of the middle cerebral artery

Various types of intracranial haemorrhages can be easily detected by CT scan of brain [Figures 15.14 to 15.17](#), shows extradural, subdural, subarachnoid and intracerebral haemorrhage respectively.

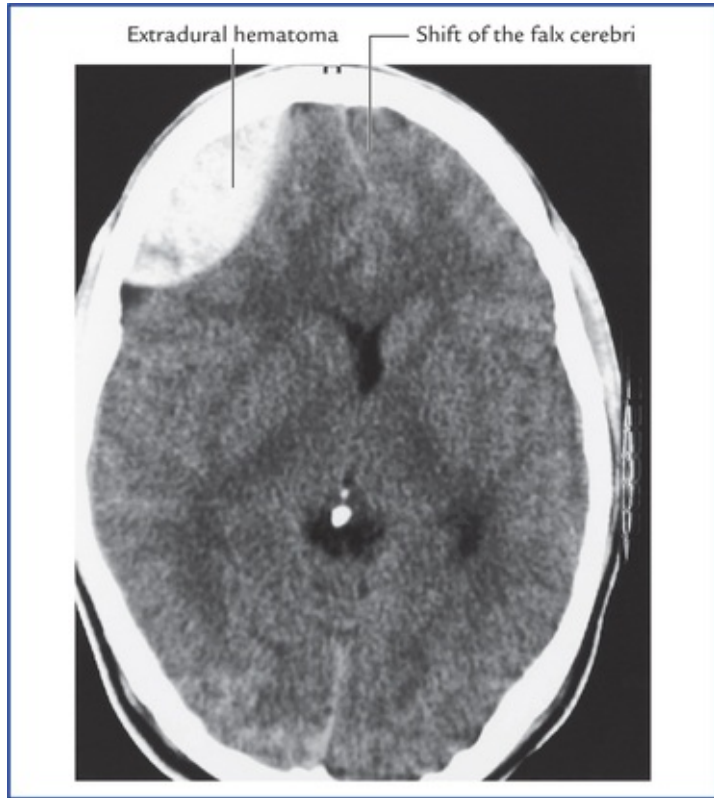


FIG. 15.14 CT scan of brain showing extradural haemorrhage/ haematoma. Source: Drake, Richard L, Vogl, Mitchell, Adam WM. *Grays Anatomy for Students*. Philadelphia: Elsevier, Inc., 2005

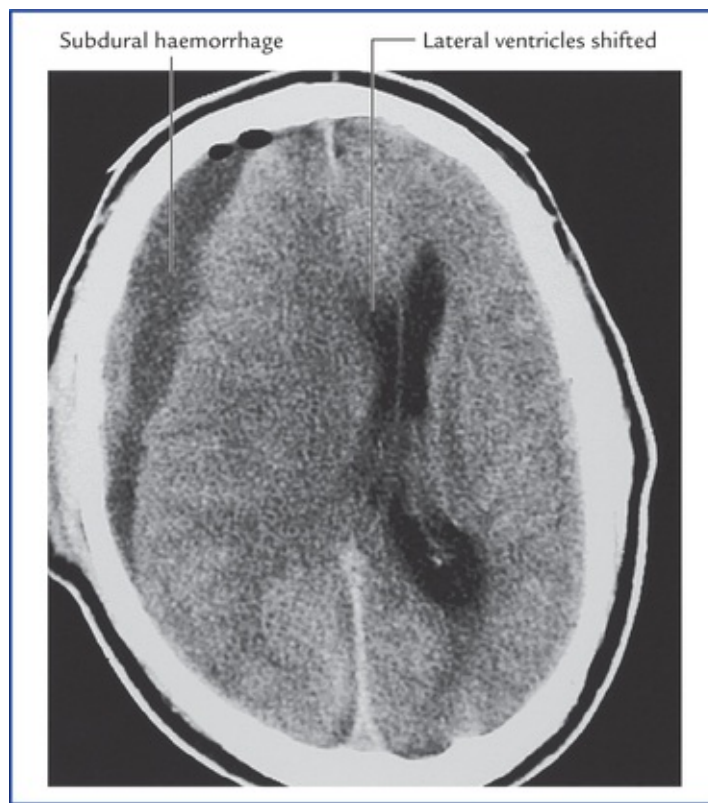


FIG. 15.15 CT scan of brain showing subdural haemorrhage/ haematoma. Source: Drake, Richard L, Vogl, Mitchell, Adam WM. *Grays Anatomy for Students*. Philadelphia: Elsevier, Inc., 2005

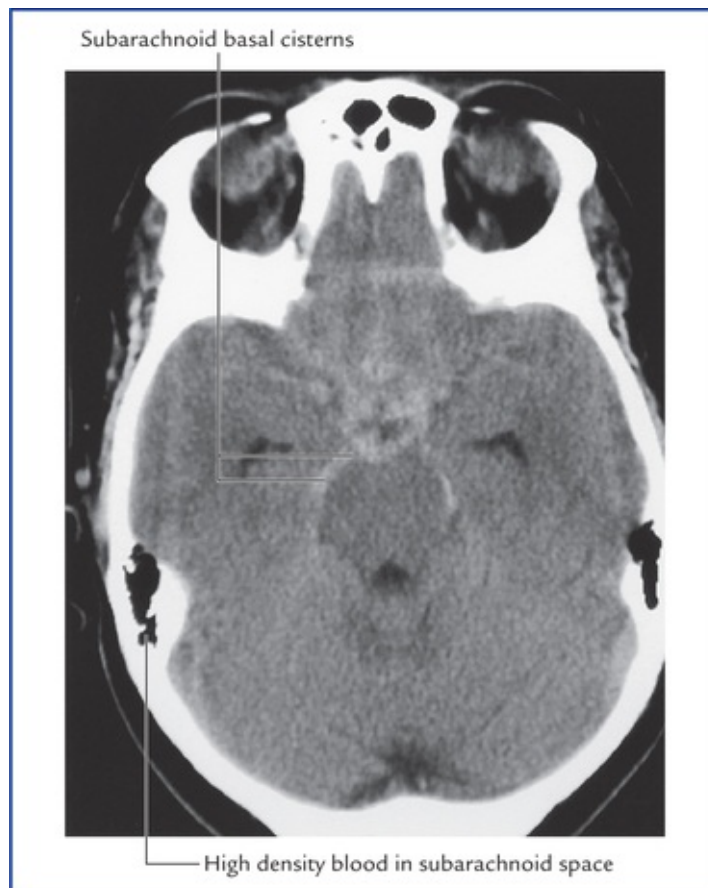

FIG. 15.16 CT scan of brain showing subarachnoid haemorrhage (arrows). Source: Drake, Richard L, Vogl, Mitchell, Adam WM. *Grays Anatomy for Students*. Philadelphia: Elsevier, Inc., 2005

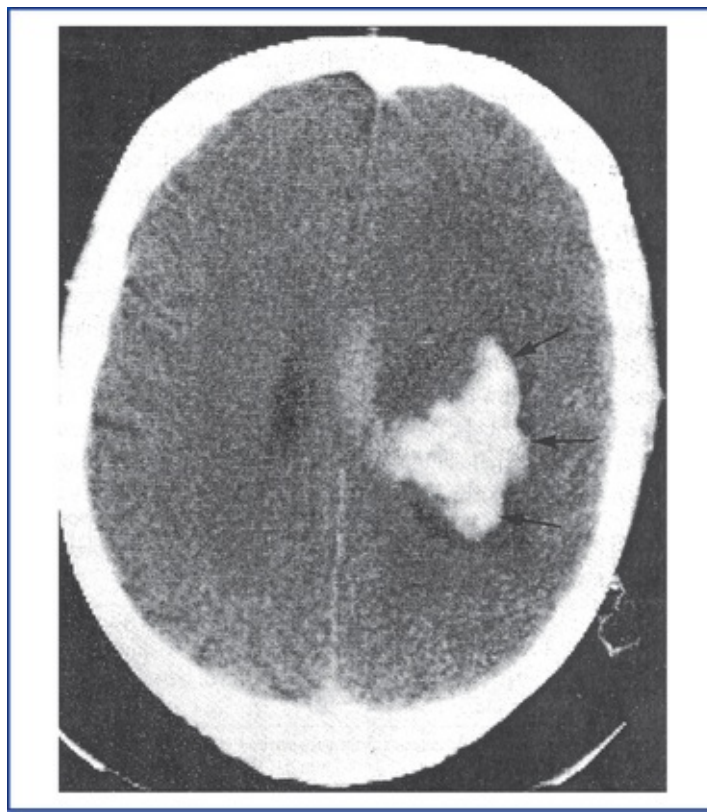


FIG. 15.17 CT scan of brain showing intracerebral haemorrhage. (arrows) Source: Haslet, Christopher, Chilvers, Edwin R, Boon, Nicholas A, et al., editors. *Davidson's Principles and Practice of Medicine*. 19th edn. Oxford: Elsevier Science Ltd., 2002

Blood-Brain Barrier (BBB)

The brain and spinal cord need a stable environment to function normally. This is provided by the presence of a semipermeable barrier, called *blood-brain barrier* (the term blood-brain-spinal cord barrier would be more accurate name). This barrier protects the brain and spinal cord from potentially harmful substances (toxic drugs and other exogenous materials) while allowing the gases and nutrients to enter the nervous tissue.

Structure of Blood-Brain Barrier

The BBB consists of following structures (Fig. 15.18) which intervene between the blood in the capillaries and the extracellular spaces surrounding the neurons and neuroglia in the brain:

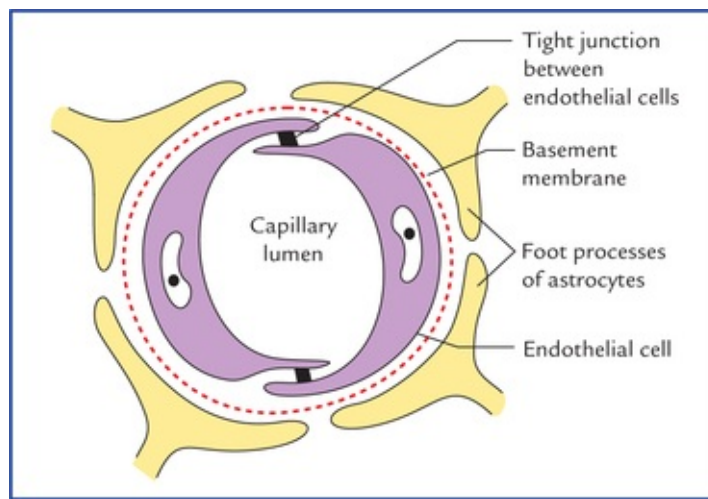


FIG. 15.18 Structure of blood-brain barrier (BBB).

- capillary endothelial cells and tight junctions between them.
- a basement membrane on which the capillary endothelial cells are arranged, and
- the foot processes of the astrocytes that adhere to the outer surface of the capillary wall.

N.B. The tight junctions between the endothelial cells of the blood capillaries form the most important component of blood-brain barrier.

Areas of the Brain Devoid of Blood-Brain Barrier

The following areas of the brain are devoid of blood-brain barrier:

- Pineal gland
- Posterior lobe of the pituitary gland ^ Tuber cinereum
- Wall of the supraoptic recess of the third ventricle
- Area postrema at the lower end of the floor of fourth ventricle.

In fact in these areas, the capillary endothelium has fenestrations, across which protein and small organic molecules may pass from blood to the nervous tissue. These are the sites where the neuronal receptors may sample the chemical contents of the plasma directly. The hypothalamus which is involved in the regulation of the metabolic activities of the body might react suitably and modify the activities thereby protecting the nervous tissue.

Clinical Correlation

- Any injury to the brain by trauma, chemical toxins or inflammation causes a breakdown of the blood-brain barrier allowing free diffusion of larger molecules into the nervous tissue. For example, normally when penicillin is administered systemically, only a small amount of it enters the CNS because penicillin in high concentration is toxic to the nervous tissue. In the presence of **meningitis** the meninges become more permeable at the site of inflammation thus permitting sufficient antibiotic to reach the site to check the infection.
- The drugs like, chloramphenicol, tetracyclines, sulphonamides, thiopental (lipid soluble), atropine (lipid soluble) easily pass through the blood-brain barrier. The drugs like, phenylbutazone, and neuro-transmitters like exogenous epinephrine and dopamine cannot cross the blood-brain barrier.

- In Parkinson's disease, there is deficiency of neurotransmitter dopamine in the corpus striatum.

Unfortunately dopamine cannot be used for the treatment, as it will not cross the blood-brain barrier. Instead levodopa (L-dopa) a precursor of dopamine is used which readily crosses the blood-brain barrier. The L-dopa is converted into dopamine by the neurons within CNS.

In infants, the blood-brain barrier is not fully developed, therefore if the serum bilirubin level is high, the bilirubin readily enters the brain tissue producing **bilirubin encephalopathy** (syn. **kernicterus**) a severe form of jaundice seen only in newborn babies.

Blood-Csf Barrier

Similar to BBB, there is barrier between the blood in the capillaries of choroid plexus and the cerebrospinal fluid (CSF) within the ventricles of the brain. It allows the free passage of water, gases and lipid soluble substances from the blood to the CSF, but prevents the entry of macromolecules such as proteins and most hexoses other than glucose.

Structure of Blood-CSF Barrier

The blood in the lumen of blood capillary (within the vil-lus of choroid plexus) is separated from the CSF in the cavity of the ventricle by the following structures which constitute the blood-CSF barrier:

- The endothelial cells, which are fenestrated (the fenestrations are not true perforations but are filled with thin diaphragms).
- The basement membrane of the capillary endothelial cells.
- The basement membrane of the choroidal epithelial cells.
- The tight junctions between the choroidal epithelial cells.
- The scattered pale cells with their flattened processes between the two basement membranes.

Clinical Problems

1. The **resuscitation** (a device to restore circulation and respiration) should be done within 4 minutes of cardiorespiratory arrest. Why?
2. On examining a **carotid angiogram** it is commonly noted that the contrast medium fills the anterior and middle cerebral arteries but fails to fill the posterior communicating artery beyond a certain point. Mention its anatomical basis.
3. The **subarachnoid haemorrhage** usually occurs at the base of the brain.
4. A 50-year-old hypertensive patient suddenly complained of severe headache. A few movements later he lost his consciousness and developed the following neurological defects: (a) loss of speech (aphasia), (b) right sided hemiplegia, and hemianaesthesia. Make the clinical diagnosis and mention the anatomical basis.
5. Why do the patients suffering from **chronic subdural haematoma** complain of headache, drowsiness and mental confusion and they are relieved of these symptoms

Clinical Problem Solving

1. This is because the irreversible brain damage starts to occur at about 4 minutes.
2. This is because, in the posterior communicating artery the streams of blood from internal carotid and vertebral arteries do not mix (also see [page 172](#)).
3. The **subarachnoid haemorrhage** commonly occurs due to rupture of **congenital berry aneurysms** which develop in the arteries of circle of Willis. Since the circle of Willis is located at the base of brain, the suba-rachnoid haemorrhage commonly occurs at the base of brain.
4. It is a typical case of **brain stroke/cerebral stroke**. The **brain stroke** is clinically defined as sudden development of neurological deficits due to cerebrovascular accident. A sudden severe headache followed by a loss of consciousness is a common clinical finding in patient with a blockage or rupture of cerebral artery. The neurological deficits noticed in this patient suggest the involvement of left middle cerebral artery.
N.B. The cerebral haemorrhage usually occurs due to rupture of an **atheromatous* artery** and is most common in middle-aged patients suffering from hypertension.
5. The **subdural haemorrhage** occurs in the subdural space, usually due to tearing of superior cerebral veins. (Also see [page 183](#)) The headache, drowsiness and mental confusion occur due to raised intracranial pressure caused by the presence of subdural haematoma, consequently when subdural haematoma (blood clot) is removed the symptoms disappear.

*Atheroma = A disease of arterial wall due to degenerative changes characterised by the formation of a tumour containing porridge-like matter (matter like a gruel). The affected artery is called **atheromatous artery**.

Meninges And Cerebrospinal Fluid

Meninges

The brain and spinal cord are enclosed in three protective membranes called *meninges*. From without inwards these are: (a) dura mater, (b) arachnoid mater, and (c) pia mater.

The dura mater is mesodermal in origin while arachnoid and pia mater are ectodermal in origin (derived from neural crests).

The **dura mater** is the thick outermost covering of the brain and spinal cord. The part enclosing the brain is called *cranial/cerebral dura*, and the part around the spinal cord, *the spinal dura*. It is very tough opaque inelastic membrane of fibrous tissue (Gk. *dura* = tough, *mater* = mother). It is also called *pachymeninx* (pachy = thick).

The **arachnoid mater** (Gk. *arachnoid* = cobweb like, *mater* = mother) is a delicate avascular membrane deep to dura mater. Many thread-like trabeculae extend from it to the pia mater.

The **pia mater** (Gk. *pia* = tender, *mater* = mother) is a thin transparent vascular membrane closely adherent to the surface of the brain and spinal cord.

The arachnoid mater and pia mater together are termed *leptomeninges* (Gk. *lepto* = thin).

The intracranial arrangement of these membranes differs from that in the vertebral canal and are therefore described separately.

The **spinal meninges** are described in [Chapter 7](#)).

Intracranial Meninges

Dura mater

The dura mater in the cranium (**cranial dura**) consists of two layers: an outer *endosteal layer* and an inner *meningeal layer*. These two layers are firmly adherent to each other everywhere except, (a) where they split to enclose the venous sinuses, and (b) where the inner layer is folded to form the dural septa.

The **endosteal layer** is attached to the inner surfaces of the cranial bones and is continuous through the sutural ligaments, and around the margins of the foramina with the periosteum on the external surface of the cranium.

Clinical Correlation

The cranial dura is more firmly adherent to the base of skull than on the vault, hence, usually torn in fractures of the skull base. It also forms the part of the wall of the basal venous sinuses, hence **the fractures of skull base are often associated with bleeding from ear, nose, or into the pharynx**. Cerebral dura is usually stripped off from the cranial vault, when an extradural haematoma is formed between the bone and dura.

The **meningeal layer** is a strong fibrous membrane and becomes continuous with the spinal dura at the foramen magnum. It ensheathes the cranial nerves in their osseous foramina and fuses externally with epineurium; the sheaths of the optic nerves fuse with the ocular sclera.

Dura! septa or folds (Figs 16.1, 16.2)

The meningeal layer gets reduplicated (infolded) along certain lines and forms septa or folds between the parts of the brain.

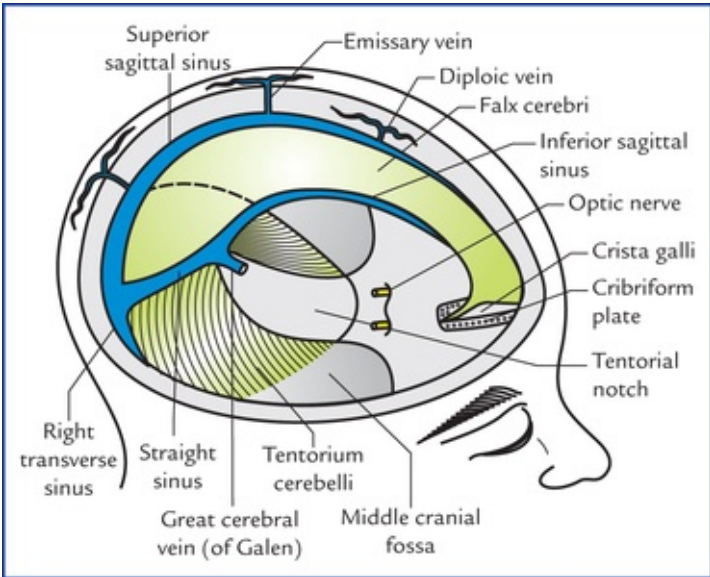


FIG. 16.1 Dural septa and dural venous sinuses viewed from superolateral aspect.

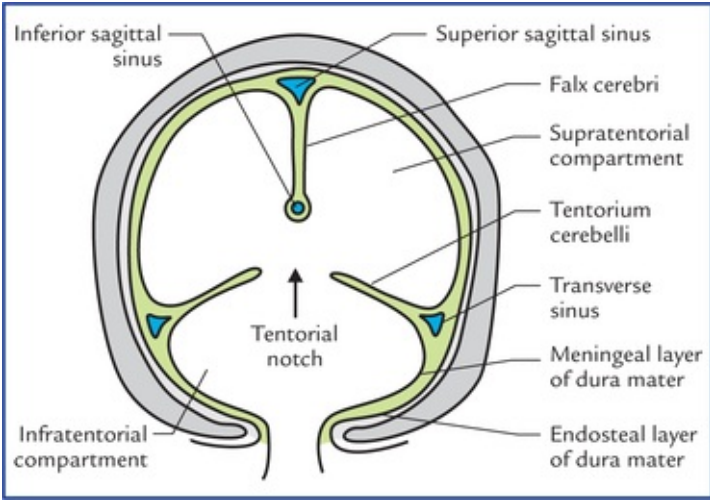


FIG. 16.2 Schematic coronal section of skull showing division of cranial cavity into three compartments by falx cerebri and tentorium cerebelli. Each half of the supratentorial compartment contains the cerebral hemisphere, whereas the infratentorial compartment contains the cerebellum and brainstem.

The four important dural septa are:

1. Falx cerebri
2. Falx cerebelli
3. Tentorium cerebelli

4. Diaphragma sellae.

Functions of dural septa

1. Dural septa divide the cranial cavity into compartments to separate the different parts of the brain and thus restrict their movements within the cranial cavity (Fig. 16.1).
2. They enclose intracranial dural venous sinuses.

Falx Cerebri

Falx cerebri is a large sickle-shaped vertical fold of dura mater which dips into the longitudinal fissure, between the two cerebral hemispheres.

Its narrow anterior end is attached to the crista galli and its broad posterior end to the upper surface of the tentorium cerebelli. Its convex upper border is attached to the vault of skull along the sagittal suture and its lower border is free and concave downwards.

The falx cerebri encloses three dural venous sinuses, viz.

- *Superior sagittal sinus*, along its upper attached border.
- *Inferior sagittal sinus*, along its lower free border.
- *Straight sinus*, along its line of attachment with the tentorium cerebelli.

Tentorium cerebelli

Tentorium cerebelli is tent-like semilunar fold of dura mater which forms the sloping roof of the posterior cranial fossa, between the cerebellum below and the occipital lobes of cerebral hemispheres above. It prevents the cerebellum from being compressed by the heavy cerebrum.

It has two borders: (a) an outer convex attached border, and (b) an inner concave free border. The inner border bounds an oval space, the *tentorial notch* or the *door of tentorium* through which passes the midbrain to connect the hindbrain with the forebrain (Fig. 16.2).

On each side, the anterior half of the outer border is attached anterolaterally to the superior border of the petrous temporal bone and posterior clinoid process, and posterior half is attached posterolaterally to the lips of the transverse sulcus.

The inner free border is 'U'-shaped and its anterior ends are attached to the anterior clinoid processes.

Tentorium cerebelli contains four dural venous sinuses, two on either side:

- *Superior petrosal sinus*, along the anterior half of its attached border.
- *Transverse sinus*, along the posterior half of its attached border.

Falx cerebelli

Falx cerebelli is a small sickle-shaped fold of dura mater which intervenes between the two cerebellar hemispheres posteriorly. It is attached to the internal occipital crest by its outer border, and encloses the *occipital venous sinus*.

Diaphragma sellae (or tentorium hypophysii)

Diaphragma sellae is a small circular fold of dura mater which roofs the pituitary fossa/sella turcica. It has an aperture in its centre to provide passage for the stalk of the pituitary gland.

Arterial supply of dura mater

The dura is supplied by numerous branches of the internal carotid, ascending pharyngeal, maxillary, occipital and vertebral arteries.

N.B. Middle meningeal artery is the largest of the meningeal arteries and from clinical point of view is the most important for it is often damaged in head injuries.

Clinical Correlation

The *middle meningeal artery*, a branch of maxillary artery enters the cranial cavity through the foramen spinosum to lie between the endosteal and meningeal layers of dura mater. Its anterior and posterior branches, along with accompanying meningeal veins (between the arteries and bone) stand out prominently as if in relief on the external surface of the dura mater to groove and supply bones of the cranial vault. The anterior (frontal) branch crosses the *pterion*, on its inner aspect and the posterior (parietal) branch ascends backwards towards the lambda. A fracture of thin squamous temporal bone may cause a *middle meningeal haemorrhage* from the artery or vein, producing an **extradural haematoma**.

Nerve supply of dura mater

The nerve supply of dura mater is derived mainly from three sources:

1. Three divisions of trigeminal nerve
 2. First three cervical spinal nerves
 3. Cervical sympathetic trunk.
- The **supratentorial dura** is supplied by the meningeal branches from the three divisions of the trigeminal nerve:
 1. In the anterior cranial fossa by meningeal branches of the anterior and posterior ethmoidal nerves.
 2. In the middle cranial fossa by meningeal branches of maxillary and mandibular nerves.
 - The **infratentorial dura** is supplied by ascending meningeal branches of upper three cervical nerves.

Clinical Correlation

The stimulation of sensory nerve endings in the dura mater due to stretching causes pain and is the basis of certain forms of headache. Pain arising from supratentorial dura is referred to the forehead while pain arising from infratentorial dura is referred to the back of the neck and occiput. The role of the autonomic supply of the cranial dura mater is uncertain.

N.B. The brain itself, the arachnoid mater, and the pia mater do not have sensory nerve endings. These are restricted only to the dura mater and cerebral vessels.

Dural venous sinuses

The **dural venous sinuses** are formed in following two ways: (a) by separation of the two layers of cerebral dura, and (b) by reduplication of the meningeal layer of dura ([Fig. 16.2](#)).

The dural venous sinuses are lined by endothelium which becomes continuous with the endothelial lining of the veins.

Characteristic features

- Have no valves, hence the blood can flow in either direction in the sinuses,
- Are devoid of smooth muscle fibres in their walls,
- Drain finally into the internal jugular veins,
- Have cerebral, diploic and some meningeal veins as their tributaries,
- Communicate via valveless emissary veins with the extracranial veins through skull foramina.

Classification

The dural venous sinuses are classified into two types, unpaired and paired (Table 16.1).

Table 16.1

Classification of dural venous sinuses

Unpaired	Paired
• Superior sagittal sinus	• Sphenoparietal sinuses
• Inferior sagittal sinus	• Cavernous sinuses
• Straight sinus	• Superior petrosal sinuses
• Occipital sinus	• Inferior petrosal sinuses
• Anterior intercavernous sinus	• Transverse sinuses
• Posterior intercavernous sinus	• Sigmoid sinuses

Unpaired sinuses

Superior sagittal sinus (SSS)

Superior sagittal sinus lies in the attached border of the falx cerebri and extends anteroposteriorly from the foramen caecum where it communicates with the nasal veins to the internal occipital protuberance, where it usually turns to the right side to continue as the *right transverse sinus*.

Large clusters of arachnoid villi (**arachnoid granulations**), concerned with the absorption of CSF project into the venous lacunae of the SSS (the clefts between the two layers of dura mater along side the SSS).

The 8 to 12 superior cerebral veins ascend with slight anterior inclination, and traverse the subdural space to drain into the superior sagittal sinus and its lacunae.

Clinical Correlation

The superior sagittal sinus communicates with the veins of scalp, diploic veins and sometimes with the veins of the nose. As a result the infection from these areas can spread to the sinus producing thrombosis of superior sagittal sinus.

Inferior sagittal sinus

Inferior sagittal sinus lies in the posterior two-third of the lower free border of falx cerebri and receives

the veins from the medial surfaces of the cerebral hemispheres. At the junction of falx cerebri with the tentorium cerebelli, it is joined by the great cerebral vein to form the *straight sinus*.

Straight sinus

Straight sinus runs along the line of attachment of falx cerebri with the tentorium cerebelli. At the external occipital protuberance it usually turns to the left to continue as the *left transverse sinus*.

Occipital sinus

Occipital sinus is the smallest sinus and situated along the attached margin of the falx cerebelli. It extends downwards from the confluence of the sinuses to the foramen magnum, where it communicates with the internal vertebral venous plexus.

N.B. At the external occipital protuberance the superior sagittal sinus communicates with the left transverse, occipital and straight sinuses to form, what is termed **confluence of sinuses**.

The shapes of various dural folds, and sinuses enclosed in them are summarized in [Table 16.2](#).

Table 16.2

Shapes of dural folds and enclosed venous sinuses

Fold	Shape	Venous sinuses enclosed
Falx cerebri	Sickle-shaped	Superior sagittal, inferior sagittal and straight sinuses
Tentorium cerebelli	Tent-shaped (semilunar)	Transverse and superior petrosal sinuses
Falx cerebelli	Sickle-shaped	Occipital sinus
Diaphragma sellae	Horizontal fold	Anterior and posterior intercavernous sinuses

Paired sinuses

Sphenoparietal sinuses (Fig. 16.4)

These small sinuses lie along the lesser wing of sphenoid and drain into the cavernous sinus.

Cavernous sinuses (Figs 16.3, 16.4)

Cavernous sinuses are situated one on either side of the sella turcica and, the body of sphenoid. Each sinus is a short wide venous channel measuring 2 cm anteroposteriorly and 1 cm transversely. It extends from superior orbital fissure anteriorly to the apex of petrous temporal bone posteriorly. The cavernous sinus is so named because it is traversed by a network of trabeculae which subdivide the cavity into numerous communicating caverns lined by endothelium. The two sinuses communicate with each other through anterior and posterior inter-cavernous sinuses which lie in the anterior and posterior margins of the diaphragma sellae, and pass anterior and posterior to the stalk of the pituitary gland respectively.

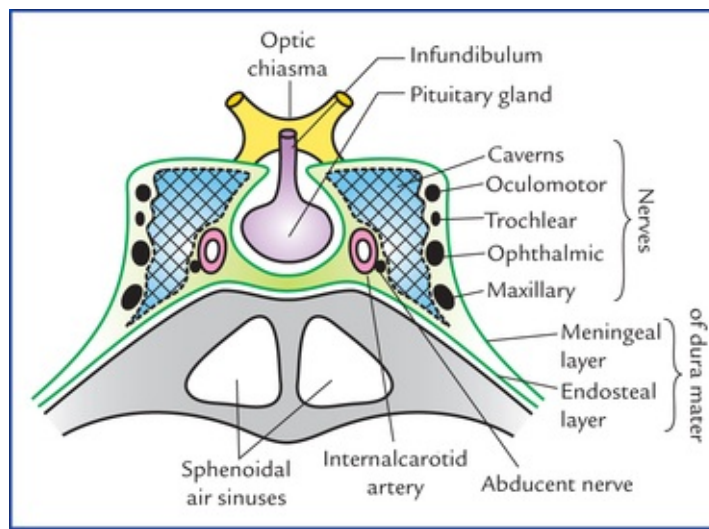


FIG. 16.3 Coronal section of cavernous sinus showing its relations and contents.

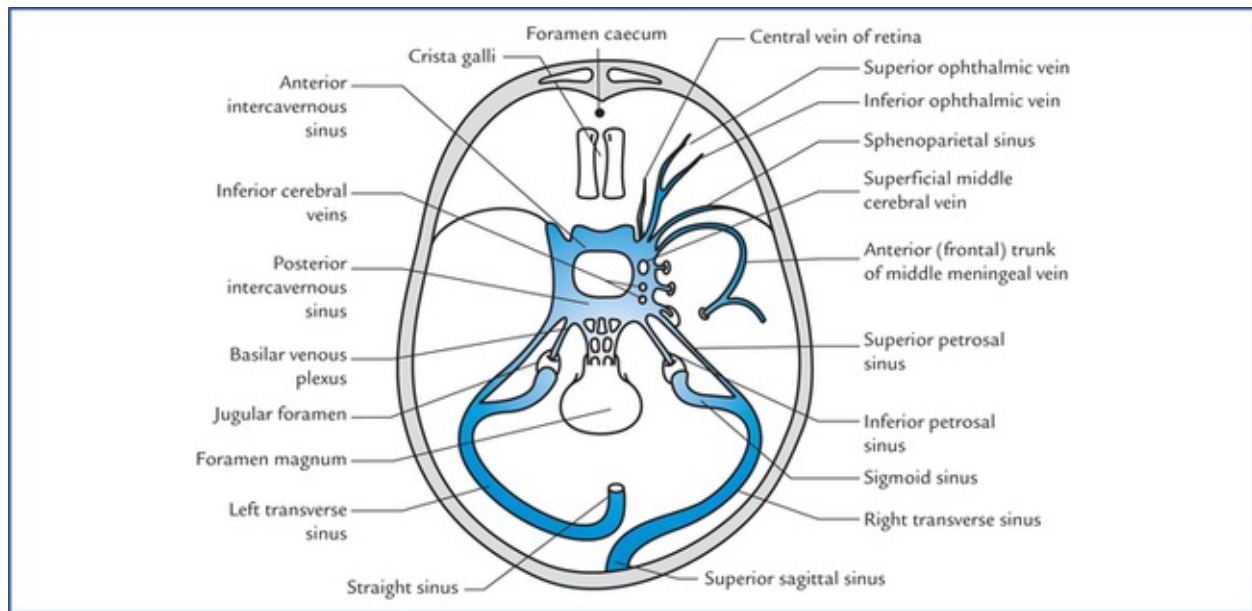


FIG. 16.4 Tributaries and communications of the cavernous sinus. (V = foramen of Vesalius, O = foramen ovale, L = foramen lacerum.)

The cavernous and intercavernous sinuses together constitute the *circulus sinus*.

Formation It is formed by the separation of meningeal and endosteal layers of dura mater so that its roof, lateral and medial walls consists of meningeal layer, and its floor consists of endosteal layer. The sinus is filled with venous blood and is covered with an endothelial lining.

Relations Medially: Pituitary gland and body of sphenoid containing sphenoidal air sinuses.

Laterally: Uncus of temporal lobe of brain and trigeminal ganglion lying within the *cavum trigeminale*.

Superiorly: Upper limb of the U-shaped loop of internal carotid artery forming carotid siphon.

Inferiorly: Greater wing of sphenoid.

Each sinus is traversed by an internal carotid artery with sympathetic plexus around it, and abducent nerve, covered by an endothelium. The abducent nerve is inferolateral in relation to the artery.

Structures present in the lateral wall of cavernous sinus The lateral wall of cavernous sinus (between its endothelium and meningeal layer of dura mater) contains (Fig. 16.3) oculomotor, trochlear, ophthalmic and maxillary nerves from above downwards.

Communications of the cavernous sinus (Fig. 16.4) Each sinus communicates with the:

- *facial vein* through two routes: (a) via superior ophthalmic and angular veins, and (b) via pterygoid venous plexus and deep facial vein,
- *superior sagittal sinus*, through superficial middle cerebral vein and superior anastomotic vein,
- *pterygoid venous plexus*, through emissary veins passing through foramen ovale, foramen spinosum, foramen vesalii and foramen lacerum,
- *transverse sinus*, through superior petrosal sinus,
- *internal jugular vein*, through inferior petrosal sinus,
- *internal vertebral venous plexus*, through basilar venous plexus, and
- *opposite cavernous sinus*, through anterior and posterior intercavernous sinuses.

Tributaries of the cavernous sinus (Fig. 16.4)

- *Superior ophthalmic vein*, which is often joined by inferior ophthalmic vein.
- *Inferior ophthalmic vein*, if it does not end in the superior ophthalmic vein.
- *Sometimes central vein of retina*, when it fails to drain into the superior ophthalmic vein.
- *Superficial middle cerebral vein*.
- *A few inferior cerebral veins*.
- *Sphenoparietal sinus*.
- *Sometimes anterior frontal trunk of middle meningeal vein*, if it does not drain into the pterygoid venous plexus through foramen ovale, or into the sphenoparietal sinus.

Clinical Correlation

• Cavernous sinus thrombosis

The infection reaching the cavernous sinus via emissary veins from face, scalp and paranasal sinuses, etc. may cause cavernous sinus thrombosis which presents with pain in the eye and total ophthalmoplegia due to involvement of IIIrd, IVth and VIth cranial nerves present inside and in the lateral wall of the cavernous sinus. There may be marked oedema of eyelids due to congestion of orbital veins.

• Pulsating exophthalmos

In fracture of the base of the skull, the internal carotid artery may rupture within the cavernous sinus, producing an arteriovenous fistula. Consequently, the arterial blood rushes into the cavernous sinus, enlarging it and forcing its blood into communicating veins. As a result, the eyeball protrudes (exophthalmos) and conjunctiva becomes engorged (chemosis) on the side of injury. Interestingly in these circumstances the bulging eye pulsates in synchrony with the radial pulse, producing a clinical condition called **pulsating exophthalmos**.

Superior petrosal sinus

Superior petrosal sinus lies in the attached border of tentorium cerebelli runs along the superior border of petrous temporal bone and connects the cavernous sinus with the transverse sinus. It drains the cavernous sinus into the transverse sinus.

Inferior petrosal sinus

Inferior petrosal sinus lies in the groove between the petrous temporal bone and clivus of sphenoid and drains the cavernous sinus into the bulb of the internal jugular vein.

Transverse sinuses

Transverse sinuses lie in the posterior attached margins of the tentorium cerebelli, groove the occipital bone. The *right transverse sinus* is usually a continuation of the superior sagittal sinus while the left one is usually a continuation of straight sinus. Both these sinuses become sigmoid sinuses on the inner aspects of mastoid processes of temporal bones.

Sigmoid sinuses

Sigmoid sinuses each sigmoid sinus is a continuation of the transverse sinus beyond a point where it leaves the tentorium cerebelli. It lies between the two layers of dura mater of posterior cranial fossa and takes a S-shaped curve posterior to the base of petrous temporal bone producing a S-shaped groove on the mastoid part of temporal bone and jugular process of occipital bone. It passes out through the jugular foramen to continue as internal jugular vein.

Clinical Correlation

As the sigmoid sinus is closely related to the mastoid antrum and being separated from it only by a thin plate of bone. The infection from middle ear or mastoid antrum can spread through this thin portion (which may be membranous especially in children) to sigmoid sinus and cause its thrombosis.

Arachnoid mater

Arachnoid mater is a thin, transparent membrane lying between the pia mater internally and dura mater externally. It invests the brain loosely and continues as spinal arachnoid at the foramen magnum, which ends at the level of second sacral vertebra. It is closely related to the dura mater. Being closely related to the dura, it bridges over all the fissures on the surface of the brain except two:

1. **Longitudinal cerebral fissure**, into which it is carried by the falx cerebri.
2. **Stem of lateral sulcus**, into which it is pushed by the lesser wing of the sphenoid.

A capillary interval, the **subdural space** between the meningeal layer of dura and arachnoid mater is traversed by cerebral veins in their route to the dural venous sinuses.

Processes of arachnoid

- *Arachnoid villi* are fine finger-like processes which arise from the surface of arachnoid. They push the dura before them and eventually perforate it to project into the venous sinuses. They are covered by specialised mesothelial cells which convey the CSF to blood stream, thus leading to the absorption of CSF. The arachnoid villi are most numerous along the superior sagittal sinus.
- *Arachnoid granulations (Pacchionian bodies)*: With advancing age the arachnoid villi enlarge in size and form pedunculated tufts called arachnoid granulations. Some consider that these are aggregations of arachnoid villi, clumped together, i.e. arachnoid granulations are the large clusters of arachnoid

villi. Arachnoid granulations like arachnoid villi are concerned with the absorption of CSF. They project into the venous lacunae of the superior sagittal sinus (Fig. 16.5).

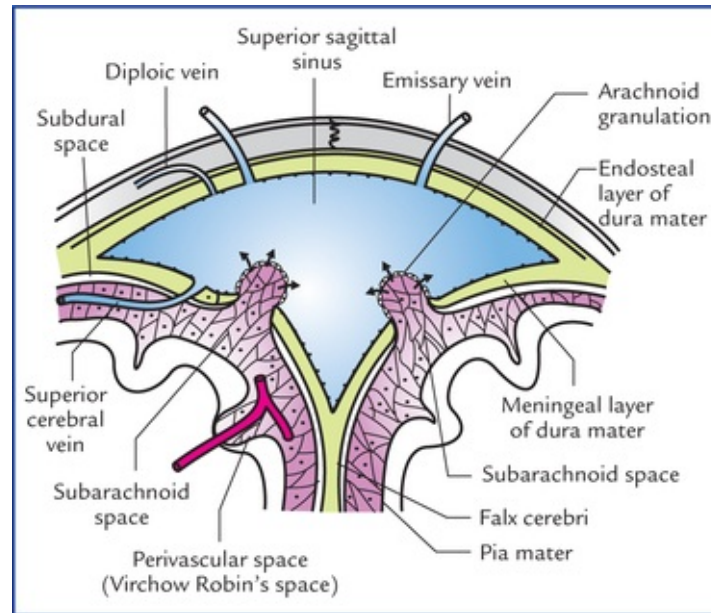


FIG. 16.5 Schematic transverse section through superior sagittal sinus showing arachnoid granulations and absorption of CSF.

As these granulations enlarge with the age, they produce parasagittal depressions on the inner surface of the cranial vault.

Clinical Correlation

The **meningiomas** are tumours arising from arachnoid villi and most commonly occur along the superior sagittal sinus.

Pia mater

Pia mater is thin transparent vascular membrane which closely invests the surface of the brain, i.e. it faithfully follows the surface irregularities of the cerebral hemisphere, and dips in every sulcus forming folds. However, its relationship is not so intimate over the surface of cerebellum where it dips and forms folds only in larger cerebellar fissures.

All the blood vessels to brain run on it before entering the brain.

Processes of pia

- *Perivascular sheaths around the vessels entering or leaving the brain substance.* The large blood vessels of the brain lie in the subarachnoid space. The smaller branches before entering into the substance of brain carry with them the double sleeve of leptomeninges (pia and arachnoid). The outer wall of double sleeve is derived from pia and the inner from the arachnoid (Fig. 16.5). The space between the two layers is called **perivascular space (Virchow-Robin's space)**.
- *Septa/folds dipping into sulci and fissures of the brain.*

- *Tela choroidea of third and fourth ventricles.* These are the folds of vascular pia along with ventricular lining the ependyma carried into the interior of the IIIrd and IVth ventricles by developing tuft of blood capillaries. *The tela choroidea and tuft of blood capillaries together form choroid plexuses of these ventricles.*
- *Sheaths for cranial nerves.*

Subarachnoid space

Subarachnoid space is the space between the arachnoid mater and pia mater. It is filled with cerebrospinal fluid (CSF) which enters it from ventricular system of the brain.

Subarachnoid space is traversed by trabeculae passing from arachnoid to pia, giving it a *spider's web appearance* hence the name arachnoid (arachnoid = like spider's web) and forms a kind of fluid-filled sponge. The arteries and veins of the brain lie in this space.

Subarachnoid space around the brain is continuous with the subarachnoid space around the spinal cord at foramen magnum, and communicates with the ventricular system only through the foramina in the roof of fourth ventricle.

Extensions of the subarachnoid space

- A sleeve of the subarachnoid space extends around the optic nerve to the back of the eyeball. Small extensions of the subarachnoid space also occur around the other cranial nerves.
- The subarachnoid space also extends around the arteries and veins of the CNS at points where they penetrate the nervous tissue.

Subarachnoid cisterns (Fig. 16.6)

The arachnoid mater bridges over the sulci on the surfaces of the brain. In certain situations, for example, at the base of the brain, around the brainstem and cerebellum, around the free margin of tentorium cerebelli, and in association with major blood vessels, the arachnoid and pia are widely separated. Thus subarachnoid space presents dilatations, filled with substantial amount of CSF called *subarachnoid cisterns*. These cisterns are large pools of CSF and act as a water-bed to the brain. The important cisterns are discussed as under:

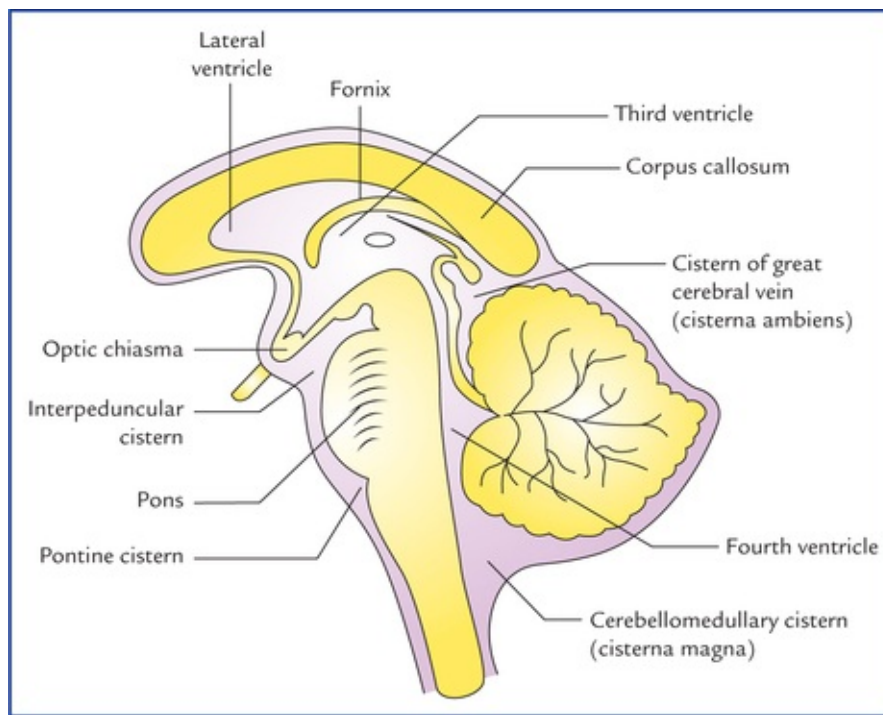


FIG. 16.6 Sagittal section of brain showing location of principal subarachnoid cisterns.

- **Cerebellomedullary cistern (cisterna magna).** It is the largest cistern and formed by the arachnoid, bridging the interval between the medulla oblongata and the inferior surface of the cerebellum. Thus it lies in the angle formed by the cerebellum, the medulla oblongata and the occipital bone. It is directly continuous inferiorly with the posterior part of the spinal subarachnoid space.

Clinical Correlation

The *cerebellomedullary cistern* is easily accessible to a needle introduced anterosuperiorly through the posterior atlanto-occipital membrane, between the posterior arch of atlas and posterior margin of the foramen magnum. Therefore, it is utilized; for **cisternal puncture** if lumbar puncture is not possible to withdraw CSF by clinicians for therapeutic and diagnostic purposes.

This cistern is triangular in sagittal section. It is the only cistern which directly communicates with the ventricular system of the brain through openings (*foramen of Magendie* and *foramina of Luschka*) in the roof of the fourth ventricle.

- **Pontine cistern (cisterna pontis):** This is an extensive subarachnoid space on the ventral surface of the pons and contains the basilar artery and its branches. It is continuous below with the subarachnoid space of the spinal cord, behind with the cerebellomedullary cistern and rostrally with the interpeduncular cistern.
- **Interpeduncular cistern (basal cistern):** It is formed by the arachnoid bridging across the two temporal lobes and contains the *circle of Willis (circulus arteriosus)*. Interpeduncular cistern is continuous laterally with the subarachnoid spaces surrounding the middle and posterior cerebral arteries, and anteriorly with the subarachnoid spaces around the anterior

cerebral arteries.

- **Cistern of lateral sulcus/fossa (sylvian cistern):** It lies in front of each temporal pole and is formed by arachnoid bridging the lateral sulcus. It contains the middle cerebral artery.
- **Cistern of great cerebral vein (cisterna superior or cisterna ambiens):** It occupies the interval between the splenium of corpus callosum and the superior surface of cerebellum. This cistern contains the great cerebral vein of Galen and pineal gland, and is widely used as a **neurosurgical landmark**.

The various cisterns are large pools of CSF and communicate freely with each other. The pulsations of arteries within CSF help to force the CSF from cisterns on to the superolateral surfaces of the cerebral hemispheres and then into arachnoid villi and granulations.

The summary of various cisterns is given in [Table 16.3](#).

Table 16.3

Location and vascular contents of various cisterns of the brain

Cistern	Location	Contents
Cerebellomedullary cistern/cisterna magna	In the interval between medulla oblongata and inferior surface of cerebellum	–
Pontine cistern/cisterna pontis	On the ventral surface of pons	Basilar artery and its branches
Interpeduncular cistern/basal cistern	At the base of brain in the interval between two temporal lobes	Circle of Willis (circulus arteriosus)
Cistern of lateral sulcus/sylvian cistern	In the stem of lateral sulcus in front of temporal pole	Middle cerebral artery
Cistern of great cerebral vein of Galen/ cisterna ambiens	In the interval between splenium of corpus callosum and superior surface of cerebellum	Great cerebral vein of Galen

Cerebrospinal Fluid

Cerebrospinal fluid (CSF) is somewhat similar to that of blood plasma and interstitial fluid. It is present in the ventricular system within the CNS and in the subarachnoid space surrounding the CNS. It bathes both the external and internal surfaces of the brain and spinal cord and provides a protective cushion between the CNS and the surrounding bones.

In an adult, the total volume of CSF is about 150 ml, out of which only 30 ml is in the ventricular system and remainder in the subarachnoid space.

Composition

Cerebrospinal fluid is clear, colourless and slightly alkaline fluid with a specific gravity of 1005-1008. It contains inorganic salts, and traces of protein and glucose similar to that of blood plasma. But, it has much lower protein content than the plasma and the glucose content is about half to that of blood, the chloride content is slightly more in CSF ([Table 16.4](#)).

Table 16.4

Composition of CSF and blood plasma

Substance	CSF	Plasma

Protein	25 mg/100 ml	600 mg/100 ml
Glucose	50 mg/100 ml	100 mg/100 ml
Chloride	120 mEq/L	100 mEq/L

CSF = cerebrospinal fluid

Clinical Correlation

Normally the CSF is clear and colourless with specific gravity of 1005–1008, and is almost cell-free having only 0–5 lymphocytes/mm³. In **bacterial meningitis**, the fluid is cloudy, with raised protein content and vastly increased number of cells.

Analysis of CSF has diagnostic value in many diseases of CNS.

Production

About 80 to 90% of the CSF is produced by the choroid plexuses within the lateral ventricles, with remaining being produced by the choroid plexuses in the third and fourth ventricles. The process of production whether by secretion, filtration, or dialyzation is uncertain. The average amount of CSF formed per day is about 500 ml.

Circulation and Absorption (Fig. 16.7)

The CSF is produced mainly in the lateral ventricles, from where it passes through the interventricular foramina (of Monro) into the third ventricle, and then via cerebral aqueduct into the fourth ventricle. Here the fluid escapes via the median aperture (foramen of Magendie) and lateral apertures (foramina of Luschka) in the roof of lateral ventricle, into the cerebellomedullary and pontine cisterns respectively. From these sites the fluid flows slowly in the subarachnoid space over the brain and spinal cord.

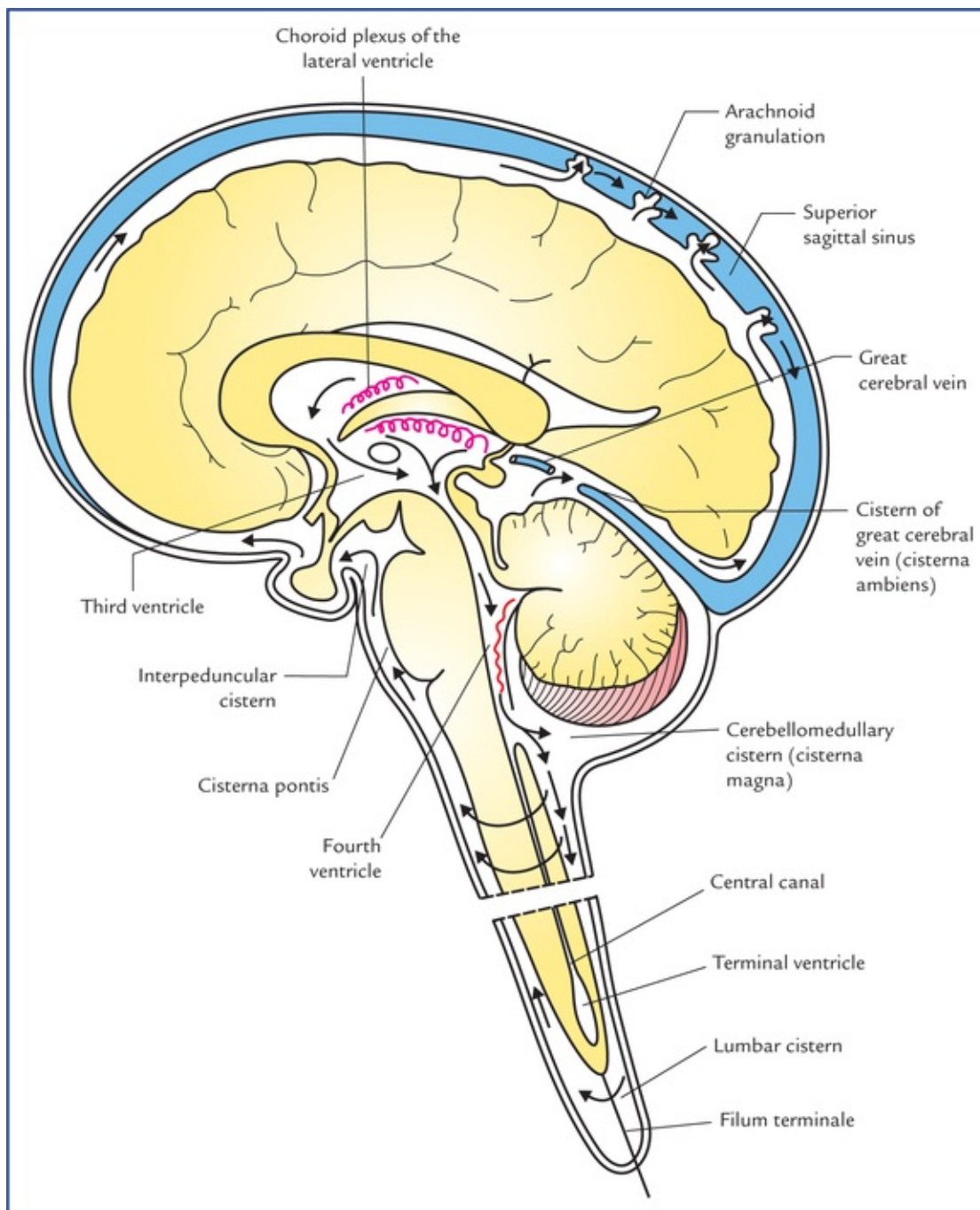


FIG. 16.7 Circulation of cere-brospinal fluid from its sites of formation in the choroid plexuses of lateral ventricle to its sites of absorption into the superior sagittal sinus. Note the location of various cisterns.

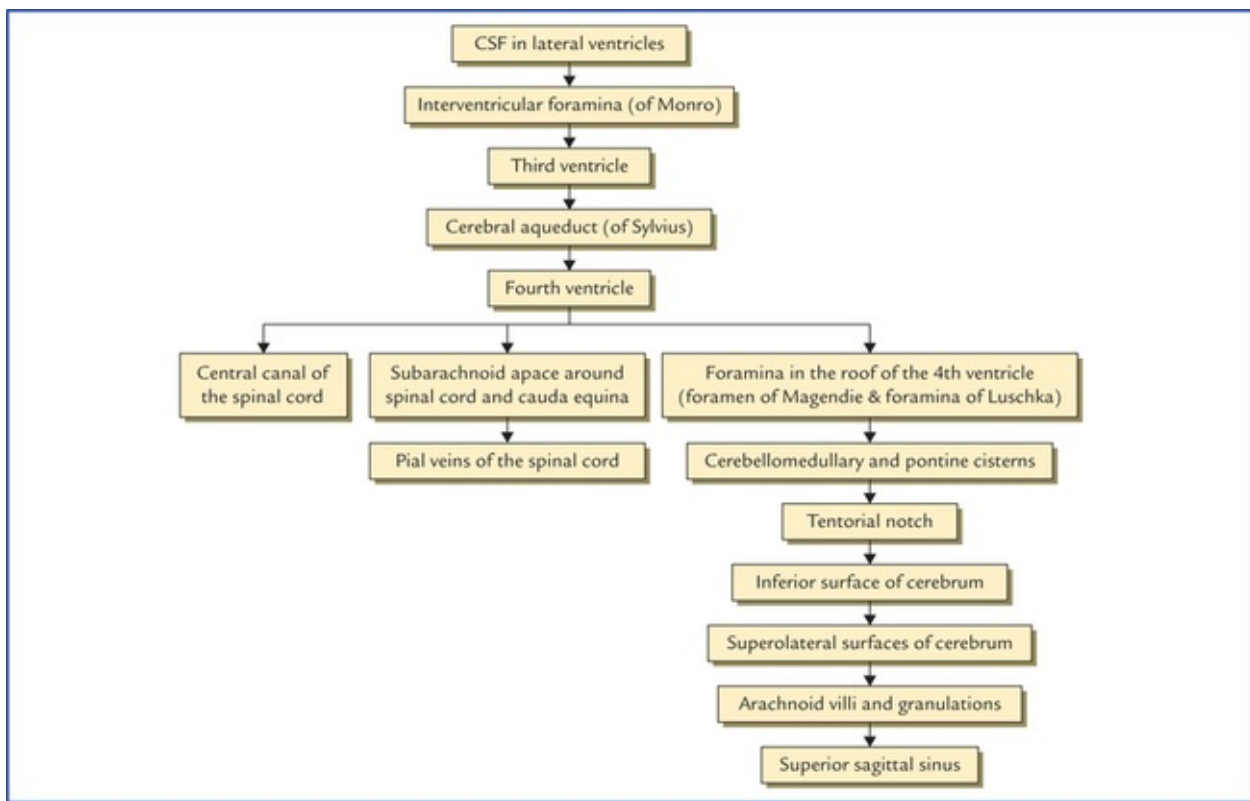
Most of the CSF flows upwards through the gap in the tentorium cerebelli and then forwards and laterally over the inferior surface of the cerebrum. Finally, it ascends on the superolateral aspect of each cerebral hemisphere to reach the arachnoid villi and granulations which penetrate into the superior sagittal sinus. The CSF enters into the blood stream of the sinus through the mesothelial cell lining of these villi and granulations.

Some of the CSF moves inferiorly in the subarachnoid space around the spinal cord and cauda equina.

Small amount of absorption may also occur into the pial veins.

The flow of CSF is facilitated by the pulsations of cerebral and spinal arteries present in the subarachnoid space, and the movements of the head and spine.

The circulation and absorption of CSF is summarized in [Flowchart 16.1](#).



FLOWCHART 16.1 Circulation and absorption of CSF.

Functions of CSF

- It serves as a cushion between the CNS and surrounding bones.
- CSF acts as a shock absorber (i.e. it prevents or diminishes the transmission of jarring or shocking forces to the CNS).
- It supports the brain and spinal cord, and maintains a uniform pressure upon them. *The brain simply floats in the CSF, and it has been stated that a brain weighing 1,500g in air, weighs no more than 50g in cerebrospinal fluid.*
- Change in the intracranial volume is sometimes compensated by the controlled production and absorption of CSF. For example, if blood volume of the brain increases then more CSF drains away. Conversely if brain's blood volume reduces, more CSF is retained.
- It nourishes the CNS.
- CSF removes the metabolites (waste products) from the CNS.
- It serves as a pathway for pineal secretions to reach the pituitary gland.

Special Properties of CSF

1. Due to presence of **blood-CSF barrier**:
 - Antibodies are not found in the CSF hence infections of the CNS are often fatal.
 - Bile is not found in CSF, even in severe jaundice.
 - Most of the drugs cannot reach CSF.
2. There is no **CSF-brain barrier**, hence if drugs are injected into the subarachnoid space (intrathecal injections) they soon enter the extracellular spaces around the neurons and neuroglia.

N.B. It has been shown that inflammation increases the diffusion rate of penicillin into the CSF. The

opinions of paediatricians are, therefore, divided as to whether intrathecal therapy is necessary in the treatment of pyogenic conditions affecting the meninges.

Clinical Correlation

- Cerebrospinal fluid can be obtained by lumbar, cisternal or ventricular puncture. The first method (i.e. lumbar puncture) being the easiest, is commonly used by the clinicians for taking out the CSF for various diagnostic and therapeutic purposes (see [Chapter 7](#)).
- **Froin's syndrome (also called loculation syndrome)** If a block occurs anywhere in the vertebral canal preventing fluid passing the obstruction, the CSF below the obstruction shows following special properties:
 - It coagulates spontaneously as the amount of protein in it is greatly increased.
 - It may be yellow in colour like plasma (xantho-chromia) due to altered blood pigment.
 - Sudden increase of intracranial venous pressure is not transmitted to the CSF below the level of block.
- **Hydrocephalus**

Hydrocephalus is an abnormal increase in the volume of cerebrospinal fluid (CSF) within the skull. It is characterized by excessive accumulation of CSF in the cerebral ventricles or subarachnoid space.

Causes

- Excessive production of CSF.
- Obstruction in some part of the circulatory route of CSF.
- Interference with the absorption of the CSF.

Out of these three factors, the obstruction in some part of the circulatory route of CSF is the common cause. The obstruction may occur at one of the following two sites:

- (a) *Inside the ventricular system:* The common sites of block are: interventricular foramina of Monro, aqueduct of Sylvius, foramina of Magendie and Luschka in the roof of fourth ventricle.
- (b) *Obstruction at the interventricular foramina* leads to distension of one or both lateral ventricles depending upon whether one or both foramina are blocked.

- Obstruction of the aqueduct of Sylvius leads to distension of both lateral ventricles and third ventricle.
- Obstruction at the openings in the roof of fourth ventricle leads to distension of all the ventricles.

At the opening in the tentorium cerebelli: If the sub-arachnoid space surrounding midbrain passing through the tentorial notch is blocked due to adhesions, the CSF from below the tentorium cannot flow upwards through the tentorial notch and spread over the surfaces of the cerebral hemisphere to reach the arachnoid granulations for absorption.

Types of Hydrocephalus

Two varieties of hydrocephalus are described: (a) non-communicating, and (b) communicating.

If the CSF accumulates within the ventricular system the condition is called **internal (non-communicating) hydrocephalus**. It occurs due to blockage at some point between its site of formation at the choroid plexuses and its site of exit through the foramina in the roof of fourth ventricle.

If the CSF accumulates in the subarachnoid space, the condition is called **external (communicating) hydrocephalus** as there is no obstruction within or to the outflow from the ventricular system. It commonly occurs due to blockage of arachnoid villi and granulations (e.g. adhesions after meningitis).

N.B. The hydrocephalus is most commonly caused by the stenosis of the cerebral aqueduct.

Clinical features of hydrocephalus in infants and children (Fig. 16.8)

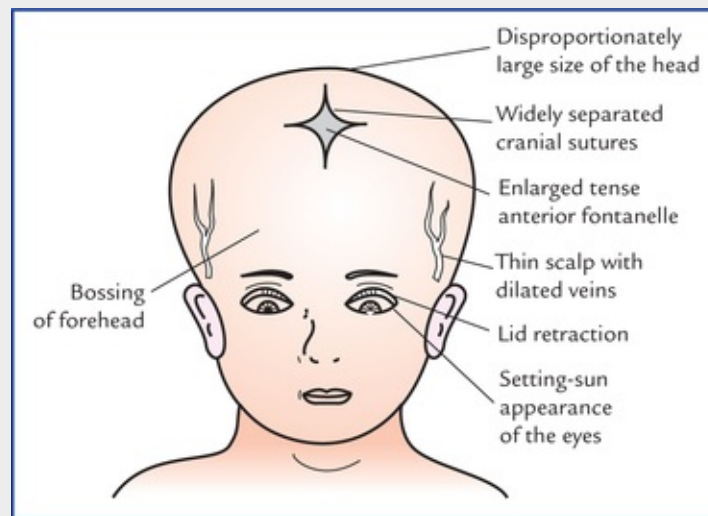


FIG. 16.8 Clinical features of hydrocephalus in infants and young children.

1. Disproportionately large size of the head (increased skull circumference).
2. Bossing of the forehead.
3. Widely separated cranial sutures.
4. Enlarged and tense anterior fontanelle.
5. Thin scalp with dilated scalp veins.
6. Eyes look downwards giving a typical **setting-sun appearance**.
7. **Cracked-pot sound** on skull percussion.
8. Cranial nerve paralyse are common.
9. Progressive loss of motor function.
10. Dementia.

N.B. There is a natural tendency to the arrest of infantile hydrocephalus. **Cuvier** and **Helmholtz** were the cases of arrested hydrocephalus.

Clinical Problems

1. Explain, why the right internal jugular vein is larger than left?
2. Explain, how the blood-clot or thrombus from pelvic veins after child birth can reach the intracranial dural venous sinuses without passing through the heart and lungs.
3. Explain, why CNS infections are usually fatal?
4. Explain, why removal of CSF by lumbar puncture or cisternal puncture may cause severe headache afterwards?
5. What is **Queckenstedt's test**?
6. What are presenting features of a hydrocephalus in infants and children?
7. What are the usual sites of blockage in the circulatory route of CSF.

Clinical Problem Solving

1. This is because, the right internal jugular vein is the continuation of larger superior sagittal sinus (superior sagittal sinus → right transverse sinus → right sigmoid sinus → right internal jugular vein) whereas the left internal jugular vein, is the continuation of smaller inferior sagittal sinus (inferior sagittal sinus → left transverse sinus → left sigmoid sinus → left internal jugular vein).
2. The pelvic veins drain into vertebral venous plexus which communicates with the basilar venous plexus, which in turn communicates with the intracranial dural venous sinuses. All these venous channels are valveless, therefore if intra-abdominal pressure is increased too much (such as during child birth), the clot or thrombus from pelvic veins are directly pushed into the intracranial dural venous sinuses without going through the heart and lung.
3. The CNS infections are usually fatal because there are no antibodies in the CSF. Further, a clinician has a limited choice of antibiotics to give due to presence of blood-brain and blood-CSF barriers.
4. Normally the brain floats freely in CSF but when CSF is removed, the brain sags and hangs on vessels and cranial nerve roots. The traction of these structures stimulate pain fibres producing dragging pain.
5. When the internal jugular veins are compressed in the neck, there is rise in cerebral venous pressure which inhibits the absorption of CSF into the dural venous sinuses. Consequently there occurs a prompt rise in manometric reading of the CSF pressure. If it does not happen, it indicates blockage in the subarachnoid space (**positive Queckenstedt's test**).
6. See [page 197](#).
7. These are: 1. Interventricular foramina, 2. Cerebral aqueduct, 3. Foramina in the roof of fourth ventricle and 4. Subarachnoid space around the midbrain in the tentorial notch.

Somatic Motor and Sensory Pathways

Somatic Motor Pathways

The somatic motor pathways of the brain and spinal cord are divided into pyramidal and extrapyramidal systems. Both these systems control the motor activities of body through lower motor neurons. The **pyramidal system** has a direct route to the lower motor neurons, while the **extrapyramidal system** has an indirect, tortuous route to these neurons. The lesions of somatic motor pathways lead to paralysis.

Clinical Correlation

Paralysis

The term paralysis denotes abolition of function, either motor or sensory, but in common clinical practice, this term is used to denote only loss of motor function.

Types of Paralysis

- **Hemiplegia** is the paralysis of one half of the body and usually involves upper and lower limbs. If the paralysis is partial, the term **hemiparesis** is used.
- **Monoplegia** is the paralysis of one limb only, i.e. the paralysis is restricted to a single limb.
- **Diplegia** is the bilateral paralysis of the corresponding parts, viz. both upper limbs or both lower limbs (**paraplegia**), or bilateral facial paralysis (facial diplegia).
- **Paraplegia** is the paralysis of two upper or two lower limbs but *generally, the term paraplegia is used for the paralysis of the two lower limbs.*
- **Quadriplegia** is the paralysis of all the four limbs.

Pyramidal System

The pyramidal system is the main **voluntary motor pathway**. It consists of two neurons, the upper and lower motor neurons. The **upper motor neurons** arise in the cerebral cortex and descend to relay in the motor nuclei of the cranial nerves (*corticoculomotor fibres*) and anterior horn cells of the spinal cord (*corticospinal fibres*).

The fibres arising from cranial nerve nuclei and anterior horn cells (**lower motor neurons**) pass through cranial and spinal nerves to supply the skeletal muscles (the final common pathway).

Conventionally the term **pyramidal tract** refers specifically to a group of corticospinal fibres (corticospinal tract) which occupies the pyramid of the medulla oblongata. However, clinically it

includes both corticospinal and corticonuclear fibres.

Corticospinal (pyramidal) tract (Fig. 17.1)

The fibres of corticospinal tract arise from pyramidal cells of the cerebral cortex (areas 4, 6 and 8). These fibres descend and converge in the corona radiata, to pass through the internal capsule where they occupy the genu and anterior two-third of its posterior limb. Then they descend through the midbrain occupying the middle three-fifth of the crus cerebri. On entering the pons (basilar part), the tract is dispersed into many smaller longitudinal bundles by pontine nuclei and transverse pontocerebellar fibres. These bundles regroup in the upper part of medulla, near its ventral aspect to produce a pyramid-shaped swelling known as pyramid (hence the name 'pyramidal tract'). In the lower part of the medulla, the majority of these fibres (about 75%) cross to the opposite side and descend in the spinal cord occupying the posterior part of lateral white column as the **crossed pyramidal tract** or **lateral corti-cospinal tract**. The fibres of this tract establish connections with the anterior horn cells of anterior grey column at various levels of spinal cord. The majority of uncrossed fibres (20%) descend into the anterior white column of spinal cord forming what is called **uncrossed pyramidal tract** or **anterior corticospinal tract**. The remaining (5%) fibres continue with the lateral corticospinal tract of the same side. On reaching the appropriate level of spinal cord these fibres along with the fibres of anterior corticospinal tract also cross to the opposite side and establish connections with the anterior horn cells like that of lateral corti-cospinal tract. In this way, all the corticospinal fibres ultimately connect the cerebral cortex of one side with the anterior horn cells in the opposite half of the spinal cord. Therefore, the lesions of corticospinal tract above the pyramidal decussation will give rise to paralysis on the opposite side.

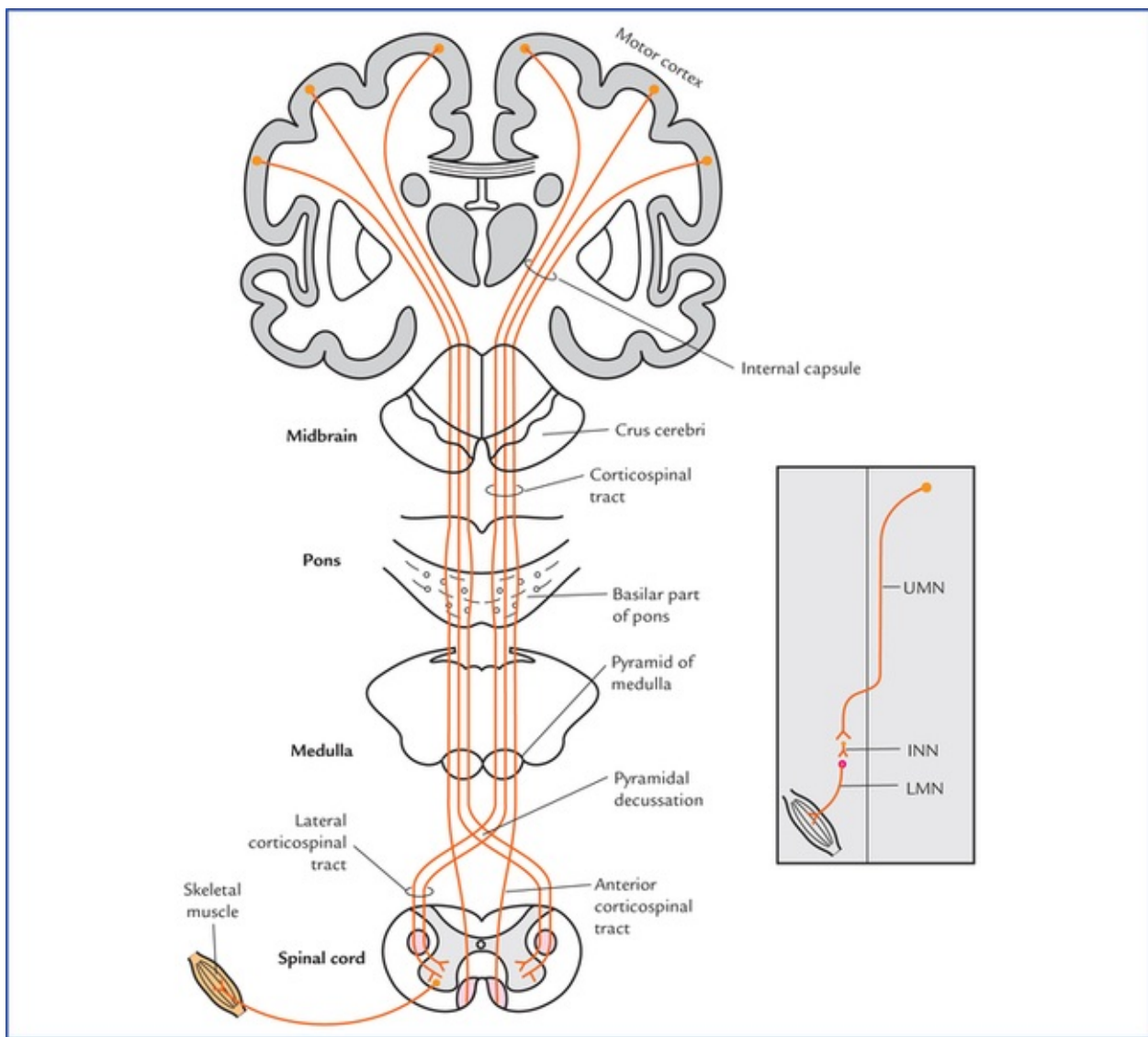


FIG. 17.1 Course and termination of the corticospinal and corticonuclear tracts. The **inset** on the right side shows an abbreviated form of motor pathway. (UMN = upper motor neuron, INN = internuncial neuron, LMN = lower motor neuron.)

N.B. According to Barr, ML (1972) those fibres of corti-cospinal tract, which do not take part in the pyramidal decussation terminate in the ipsilateral grey matter and account in part for the bilateral cortical control of the muscles of the neck and the trunk.

Functions of the corticospinal tract (pyramidal tract)

The corticospinal tract forms a pathway that confers the speed and agility to the voluntary movements by contraction of individual or small group of muscles, particularly those moving the hands, fingers, feet and toes. Thus the integrity of corticospinal tract is essential for performing the rapid skilled voluntary movements.

Corticonuclear tract (Fig. 7.16)

The corticonuclear fibres arise and course in company with the fibres of corticospinal tract. In the internal capsule they occupy the genu. In the midbrain they occupy a small part of crus cerebri, immediately medial to the corticospinal fibres. At various levels of brainstem, most of corticonuclear fibres cross to the opposite side to synapse with the cells of cranial nerve nuclei, either directly or through interneurons. *The cranial nerve nuclei that supply striated muscles are functionally equivalent to the anterior horn cells of spinal cord.* Some of them terminate on the ipsilateral cranial nerve nuclei also.

Points to Note

- The pyramidal tract contains about one million fibres in the human.
- The majority of corticospinal fibres terminate on interneurons/ internuncial neurons which in turn carry the impulses to anterior horn cells. Only 9–10% synapse directly with anterior horn cells.
- Fibres of lateral corticospinal tract extend to the lowest segments of the cord, while that of anterior corticospinal tract extend only up to the midthoracic level.
- The longest fibres of corticospinal tract, viz. those to lower segments of cord lie most superficially, while shortest fibres lie most medially.
- The fibres of corticospinal tract in addition to motor cortex, also arise from sensory cortex (one-third from premotor area and remaining one-third from primary sensory area and superior parietal lobule). The fibres arising from sensory cortex (parietal lobe) end in nucleus gracilis, nucleus cuneatus and substantia gelatinosa. They do not control motor activity but regulate the input of sensory impulses to the brain.
- The representation of the musculature of the body differs at different levels. (In the primary motor cortex the body is represented upside down, in the internal capsule the motor fibres to head lie anteriorly and those for leg lie posteriorly, in the midbrain the fibres for the face lie medially while those for leg lie laterally.)

Arterial supply of areas of brain and spinal cord occupied by pyramidal tract

In view of the frequent involvement of the pyramidal tract in cerebrovascular accidents, the arterial supply of the areas of the brain and the spinal cord occupying this tract is listed in detail in [Table 17.1](#).

Table 17.1

Arterial supply of the different parts of brain and spinal cord containing pyramidal tract

Parts	Arterial supply
Motor cortex	
• Leg area	Anterior cerebral artery
• Face, trunk and arm areas	Middle cerebral artery arm areas
Internal capsule	Branches of middle cerebral artery
Midbrain (cms cerebri)	Posterior cerebral artery
Pons	Pontine branches of basilar artery
Medulla	Medullary branches of vertebral artery
Spinal cord	Segmental branches of anterior spinal artery

N.B. The pyramidal tract is most frequently involved in cerebrovascular accident where it passes through the internal capsule.

Clinical Correlation

Effects of the lesions of corticospinal tracts

The lesions of corticospinal tracts/upper motor neuron lesions result in hemiplegia with or without involvement of cranial nerves. The classical signs are as follows:

- Spastic paralysis, due to involvement of upper motor neurons (UMN). Normally the lower motor neurons (LMNs) are under control of UMNs. Once the UMNs are damaged, they have no control on LMNs. Consequently, LMNs become hyperactive causing hypertonia or spasticity of muscles and exaggerated tendon reflexes.
 - *Babinski's sign is present*, i.e. great toe becomes dorsiflexed and other toes fan outward when the skin along the lateral aspect of the sole of the foot is scratched with a blunt object.
 - *Superficial abdominal reflexes are absent*, i.e. abdominal muscles fail to contract when the skin of the abdomen is scratched,
 - *Cremasteric reflex is absent*, i.e. cremasteric muscle fails to contract when the skin on the medial side of the upper part of thigh is stroked.
 - Loss of performance of fine skilled voluntary movements.
- The signs and symptoms of hemiplegia differ according to the site of lesion ([Table 17.2](#)).

Table 17.2

Clinical features of hemiplegia

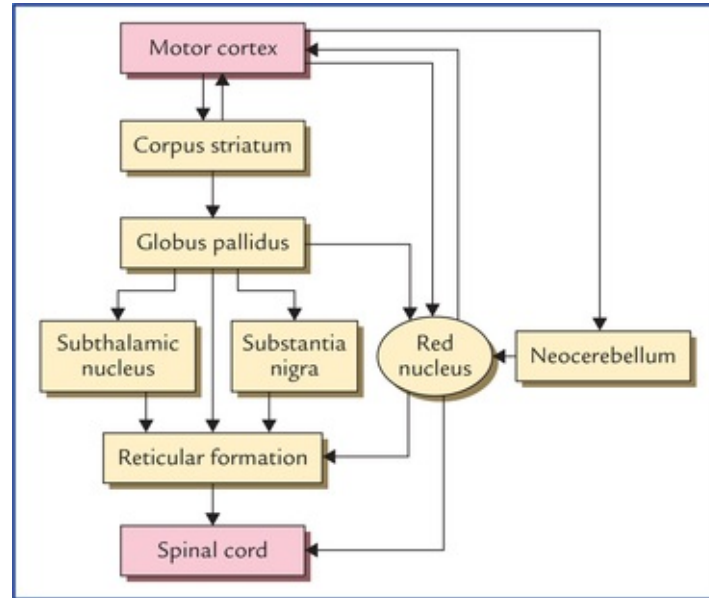
Site of lesion	Clinical features
Cortex (cortical hemiplegia)	<ul style="list-style-type: none"> • Contralateral hemiplegia • Aphasia (if lesion in dominant hemisphere)
Internal capsule (capsular hemiplegia)	<ul style="list-style-type: none"> • Contralateral hemiplegia • Ipsilateral UMN-type of facial palsy
Midbrain/crus cerebri (midbrain hemiplegia)	<ul style="list-style-type: none"> • Contralateral hemiplegia • Ipsilateral LMN type of 3rd nerve palsy
Pons (pontine hemiplegia)	<ul style="list-style-type: none"> • Contralateral hemiplegia • Ipsilateral LMN type of 6th nerve palsy • Ipsilateral LMN type of 7th nerve palsy
Medulla (medullary hemiplegia)	<ul style="list-style-type: none"> • Contralateral hemiplegia • Ipsilateral LMN type of tongue paralysis (12th nerve palsy)
Spinal cord (spinal hemiplegia)	<ul style="list-style-type: none"> • Contralateral hemiplegia • No cranial nerve involvement

N.B. The lesions of corticospinal tract above the pyramids produce contralateral paralysis, whereas lesions below the pyramids cause ipsilateral paralysis.

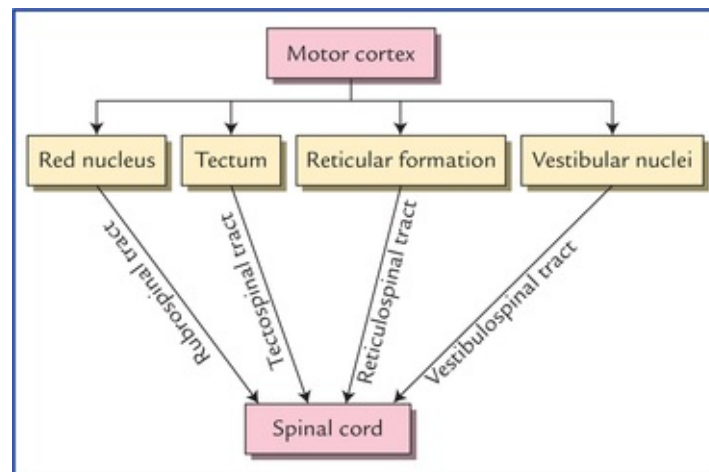
N.B. The most important characteristic feature of unilateral brainstem lesion (haemorrhage, tumour) is ‘**alternating hemiplegia**’ which is characterised by: ipsilateral cranial nerve palsy (at the level of lesion), and contralateral hemiplegia, i.e. loss of motor power and sensations in the limbs (below the level of lesion).

Extrapyramidal System

Phylogenetically, it is an older system than the pyramidal system. It consists of all the motor tracts of the brain and spinal cord which do not pass through the medullary pyramids. The extrapyramidal system works hand in hand with the pyramidal system to perform voluntary movements (Flowcharts 17.1 and 17.2).



FLOWCHART 17.1 Indirect motor pathways through which the corpus striatum influences the spinal cord.



FLOWCHART 17.2 Indirect motor pathways through which the cerebral cortex influences the spinal cord. These are generally described as extrapyramidal tracts.

Components of extrapyramidal system

The extrapyramidal system includes subcortical centres such as corpus striatum, globus pallidus, tectum, red nucleus, reticular formation, vestibular nuclei and neocerebellum.

The corpus striatum influences descending pathways principally by its cortical connections. The other subcortical centres influence the lower motor neurons in the spinal cord directly through rubrospinal,

reticulospinal, tectospinal, vestibulospinal, and olivospinal tracts ([Flowchart 17.2](#)).

Functions of extrapyramidal system

- Postural adjustments of the body to maintain balance.
- Gross synergistic voluntary movements in group of muscles affecting proximal joints of the limbs.
- Movements performed unconsciously, like swinging of arms during walking.
- Regulatory influence over the reflex activities.

The differences between the pyramidal and extrapyramidal systems are given in [Table 17.3](#).

Table 17.3

Differences between the pyramidal and extrapyramidal systems

	Pyramidal system	Extrapyramidal system
Phylogeny	Phylogenetically recent in acquisition, present only in mammals and achieving its greatest development in man	Phylogenetically older than pyramidal system
Function	Responsible for non-postural, precise movements of small muscles involved in skilful activity	Responsible for gross postural (stereotyped) movements involving large groups of muscles
Pathways	Connected directly to the lower motor neurons. Therefore impulses reach the LMNs, through a direct route	Connected indirectly (polysynaptic pathway) to lower motor neurons. Therefore, impulses reach the LMNs through a circuitous route
Effects of lesion	No increase in muscle tone	Muscle tone increased (spasticity)
Cortical fibres	Arise predominantly in primary motor area (Brodmann's area 4)	Arise predominantly in premotor area (Brodmann's area 6)
Subcortical centres and basal ganglia	Play no role in pyramidal system	Play a key role in extrapyramidal system

N.B. Naturally occurring lesions in man rarely, if ever involve pyramidal pathway without simultaneous involvement of extrapyramidal pathways therefore the division of motor pathways into pyramidal and extrapyramidal systems is of little or no clinical relevance.

Points to Note

- The extrapyramidal fibres originating from cerebral cortex, in contrast to pyramidal fibres, make synapse with subcortical centres before establishing contact with the lower motor neurons at the segmental level.
- The cortical sites of origin of extrapyramidal and pyramidal fibres overlap extensively.

Clinical Correlation

Effects of lesions of extrapyramidal tracts

- *Paralysis* with little or no muscular atrophy (except that due to disuse)
- *Spasticity or hypertonicity of the muscles*
- *Exaggerated deep reflexes, viz. knee jerk, ankle jerk, etc.*
- *Clasp-knife rigidity.*

Upper and lower motor neuron lesions

Any lesion that destroys any part of the pyramidal tract is termed **upper motor neuron (UMN) lesion**.

The classical example of upper motor neuron paralysis is *hemiplegia*.

In UMN lesion, the muscles are not paralyzed because UMNs do not supply muscles directly. Actually what happens is that the control of UMNs on LMNs which supply the muscles is lost. As a result LMNs become hyperactive. Consequently, the muscles of the limbs may become spastic and involuntary movements may occur which are uncontrollable and often lead to severe rigidity or spasm. Reflexes are exaggerated. There is no loss of muscle tone and no wasting of the affected muscles. A little wasting may occur due to disuse atrophy.

Similarly, any lesion of anterior horn cells or cranial nerve nuclei or motor fibres of peripheral nerves is described as **lower motor neuron (LMN) lesion**. The classical examples of LMN paralysis are *poliomyelitis* due to involvement of anterior horn cells of spinal cord, and *Bell's palsy* due to involvement of facial nerve.

In LMN lesion, the affected muscles are paralyzed. They become limp and flaccid. There is wasting and normal reflexes are lost.

Both types of lesions manifest in the form of paralysis of muscles and loss of motor power. The important differences of upper and lower motor neuron lesions are given in [Table 17.4](#).

Table 17.4

Differences in clinical features of upper and lower motor neuron lesions

Features	Upper motor neuron lesion	Lower motor neuron lesion
Muscle tone	Increased (hypertonia or spasticity)	Decreased (hypotonia or flaccidity)
Muscle wasting	Absent (except due to disuse atrophy)	Present (atrophy)
Extent of paralysis	Widespread	Localized
Babinski's sign*	Present	Absent
Tendon reflexes, viz. knee and ankle jerks	Exaggerated	Diminished or lost
Muscle clonus †	Present	Absent

*When outer border of plantar surface of the foot is scratched with a blunt object in patient with a pyramidal (UMN) lesion it results in slow dorsiflexion of great toe accompanied by fanning of lateral toes. In normal person it results in plantar flexion of toes.

†A quick and continued stretch of a tendon, e.g. by sudden downward pulling of patella in patient with upper motor neuron lesion results in appearance of repetitive, rhythmical contraction and relaxation of quadriceps instead of single contraction as in normal individuals.

General Somatic Sensory Pathways

The general somatic sensory pathways are concerned with sensory modalities of pain, touch, temperature, vibration, tactile discrimination, pressure and proprioception. They transmit these sensations from somatic receptors in skin, muscles, tendons, joints) to the central nervous system.

The general somatic sensory pathways are divided into spi-nothalamocerebral, spinocerebellar, and trigeminothalamic pathways. The sensations carried by the first group of pathways are only perceived consciously.

Spinothalamocerebral Pathways

Spinothalamocerebral pathways consist of a series of three sensory neurons: primary, secondary and tertiary.

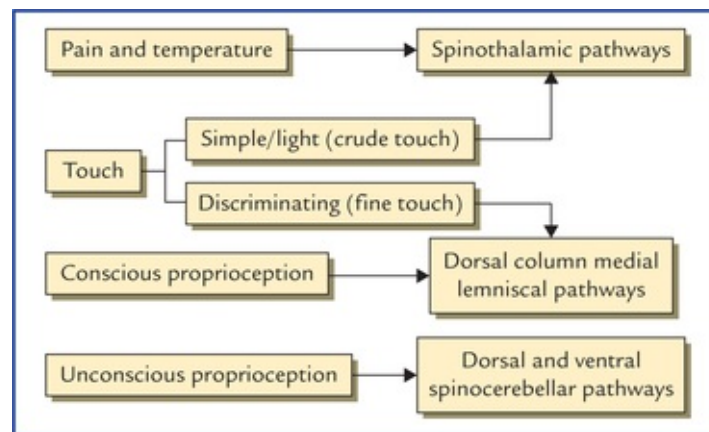
The cell bodies of primary (first order) sensory neurons lie in the dorsal root ganglia of spinal nerves and sensory ganglia of cranial nerves, the cell bodies of secondary (second order) sensory neurons lie in the grey matter of the spinal cord and sensory nuclei within the brainstem, and cell bodies of tertiary (third order) sensory neurons lie in the thalamus.

The primary sensory neurons bring sensations from receptors to the secondary neurons which transmit it to the tertiary neurons; which finally convey it to the primary somatic sensory cortex of the cerebral hemisphere.

Points to Note

- The second order sensory neurons cross to the opposite side, hence sensations from left side of body pass to the right cerebral hemisphere and those from right side of the body to the left cerebral hemisphere.
- All types of sensory modalities are consciously perceived at the level of cerebral cortex except pain and probably temperature which may be consciously perceived in the thalamus.
- Interneurons also called internuncial neurons may be interposed between the main sensory neurons.
- The cell bodies of all the first order sensory neurons lie outside the CNS except those in the mesencephalic nucleus of trigeminal nerve which lie within the CNS (brainstem).

Various types of sensations carried by different somatic sensory pathways are summarized in [Flowchart 17.3](#).



FLOWCHART 17.3 Sensations carried by different somatic sensory pathways.

Spinothalamic pathways (pathways for simple touch, pain and temperature)

Lateral spinothalamic tract (Fig. 17.2)

The lateral spinothalamic tract carries pain and temperature sensations from the opposite side of the body.

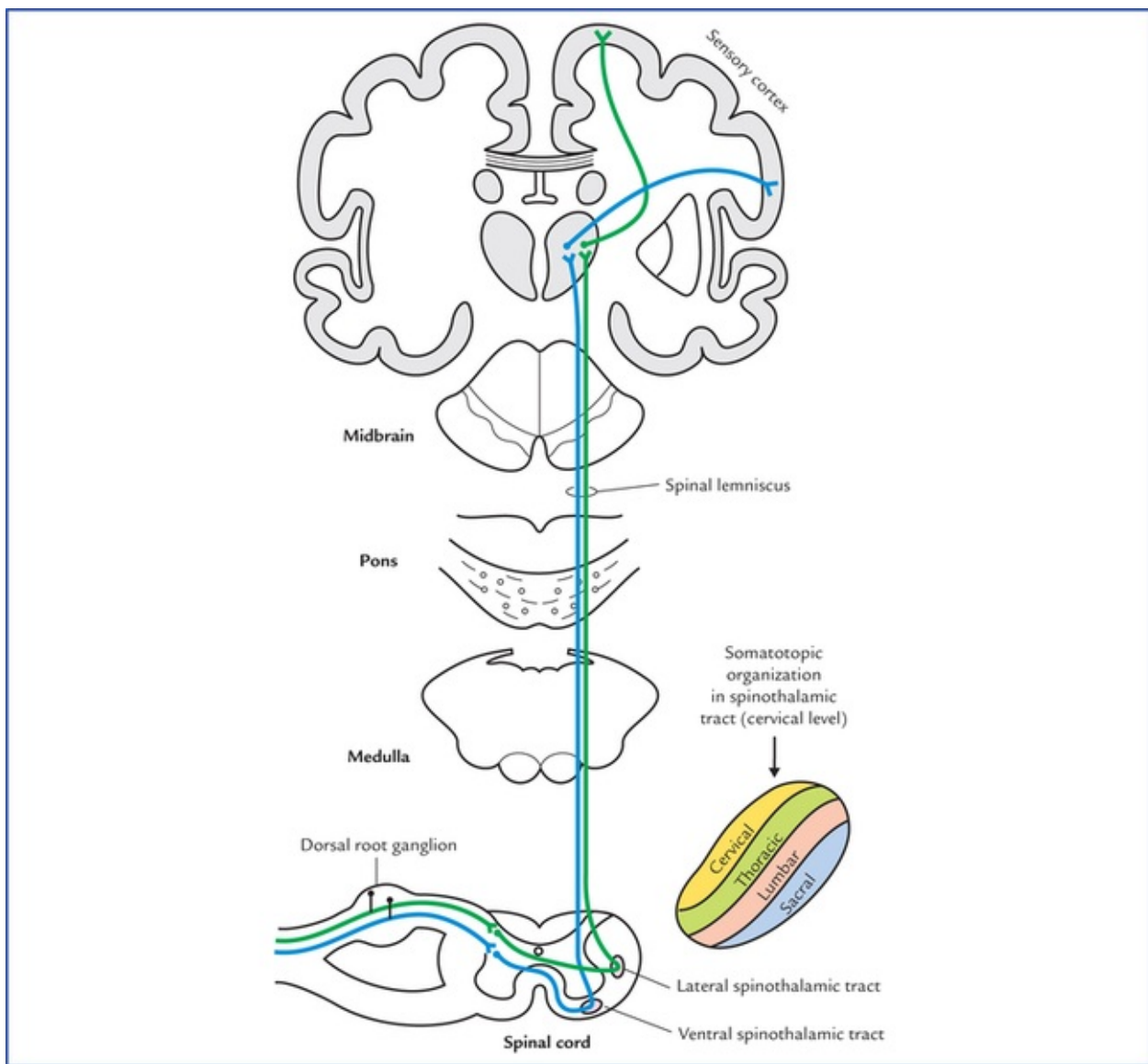


FIG. 17.2 Lateral and ventral spinothalamic tracts.

The *first order sensory neurons* carrying these sensations enter the spinal cord through the lateral division of the dorsal root of the spinal nerve. In the cord these fibres ascend or descend for one or two segments as *dorsolateral tract of Lissauer* at the tip of posterior horn and then relay into the posterior horn cells in the region of substantia gelatinosa.

The axons of *second order sensory neurons* arise from posterior horn cells, cross over to the opposite side in the anterior commissure in front of the spinal canal and reach the opposite lateral white column, where they turn upwards forming the *lateral spinothalamic tract*. The fibres of this tract terminate in the cells of ventral posterolateral (VPL) nucleus of the thalamus.

The axons of *third order sensory neurons* arise from the cells of VPL nucleus of thalamus and project to the primary sensory cortex of the cerebral hemisphere (area 3, 1, 2).

Clinical Correlation

- The damage of lateral spinothalamic tract causes loss of pain and temperature sensation on the opposite side of the body one or two segments below the level of lesion. The patient will not, therefore, respond to pin-prick or recognize hot or cold objects placed in contact with the skin.

- In the spinothalamic tract the pain fibres are lateral to the temperature fibres. In the cervical region the pain fibres become very superficial in the lateral white column, hence **cordotomy** can be performed safely at this level to relieve the pain in the opposite half of the body.

Ventral spinothalamic tract (Fig. 17.2)

The ventral (anterior) spinothalamic tract carries light touch, pressure, tickle, and itch sensations from the opposite side of the body.

The *first order sensory neurons* carrying these sensations enter the spinal cord through the lateral division of dorsal root of the spinal nerve. In the cord these fibres may ascend or descend for 8 to 10 segments in *dorsolateral tract of Lissauer* before terminating into the posterior horn cells in the region of substantia gelatinosa.

The axons of *second order sensory neurons* arise from posterior horn cells, cross over to the opposite side in the anterior white commissure in front of the spinal canal to reach the opposite anterior white column, where they turn upwards to form the *ventral spinothalamic tract*. As it ascends, it merges with the *lateral spinothalamic tract* in the brainstem and relay into the ventral posterolateral (VPL) nucleus of the thalamus.

The axons of *third order sensory neurons* arise from cells of VPL nucleus of thalamus and project to the primary sensory area of cerebral cortex (areas 3, 1, 2).

Clinical Correlation

The damage of anterior spinothalamic tract causes loss of light touch and pressure on the opposite side of the body below the level of the lesion. The patient will not feel the light touch of a cotton wisp or pressure of a blunt object placed against the skin.

N.B. The discriminative touch will still be present, as it is carried by fasciculus gracilis and fasciculus cuneatus.

Points to Note

- The lateral spinothalamic tract carries pain and temperature sensations from whole of the opposite half of body except from the region of the head and neck from where these sensations are carried by Vth, IXth and Xth cranial nerves.
- The transmission of pain and temperature in the posterior horns may be altered (inhibition or facilitation) by nerve impulses coming from the sensory motor strip of the cerebral cortex, especially that from the somesthetic area.
- Throughout the course of spinothalamic tracts the fibres lie in a somatotopic arrangement with sacral fibres being the later almost and fibres from lumbar, thoracic, and cervical segments medially in that order.

Dorsal column medial lemniscal pathways (pathways for conscious

proprioception)

Fasciculus gracilis, fasciculus cuneatus and medial lemniscus

The fasciculus gracilis and fasciculus cuneatus carry the sensations of proprioception, two-point discrimination and vibration (Fig. 17.3).

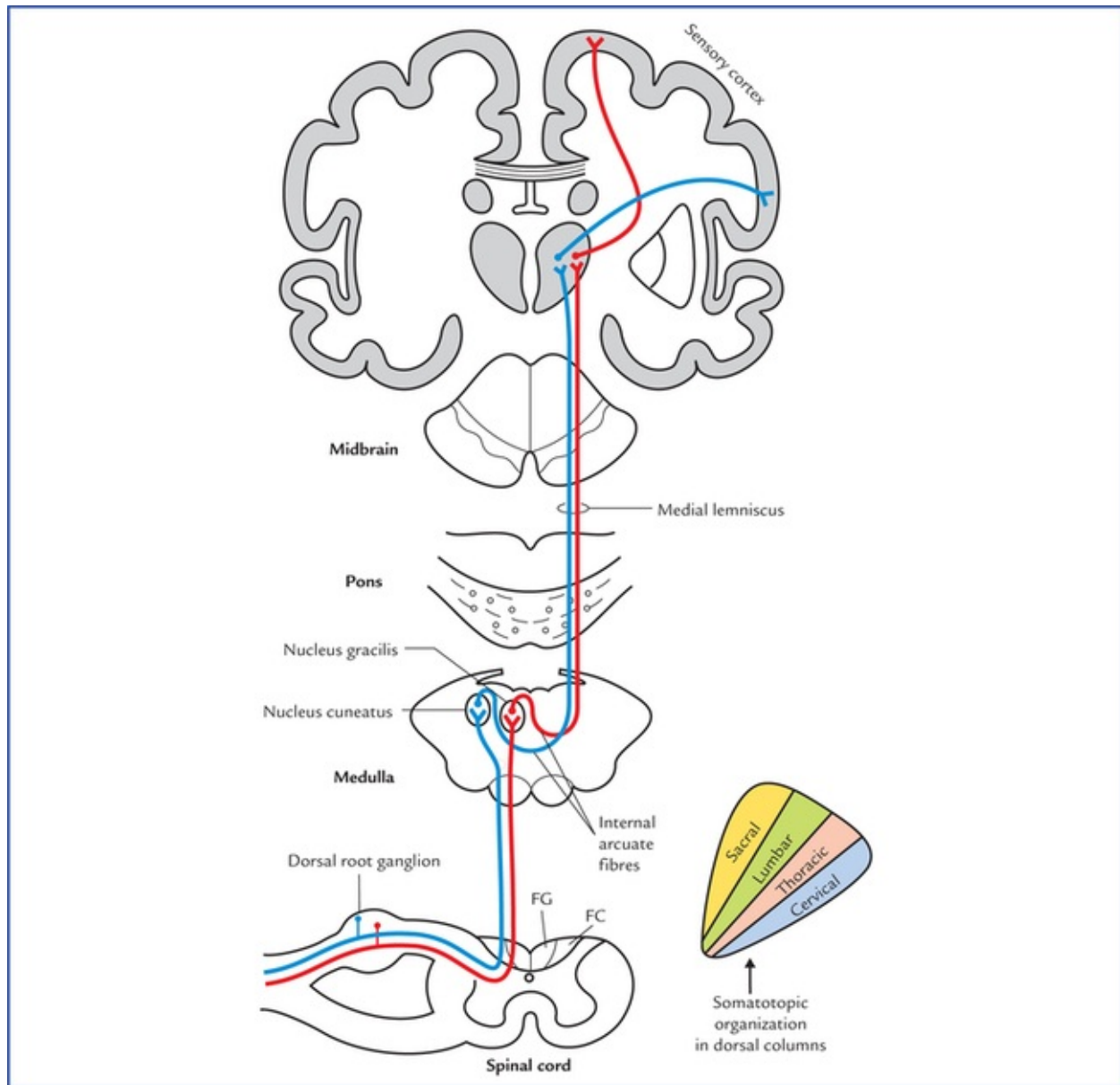


FIG. 17.3. Dorsal column medial lemniscal pathways carrying conscious proprioceptive sensations. (FG = fasciculus gracilis, FC = fasciculus cuneatus.)

The *first order sensory neurons* carrying these sensations enter the spinal cord through the medial division of the posterior spinal nerve root and continue in the posterior white column as fasciculus gracilis and fasciculus cuneatus to the medulla, where they relay in the nucleus gracilis and nucleus cuneatus respectively.

The axons of *second order sensory neurons* arise from cells of the nucleus gracilis and nucleus cuneatus, curve as **internal arcuate fibres**, cross to the opposite side, decussate with those of opposite side in lower medulla (called **sensory decussation**) and then turn upwards forming the **medial lemniscus**. The fibres of medial lemniscus ascend successively through medulla and pons to relay into the ventral

posterolateral (VPL) nucleus of the thalamus.

The axons of *third order sensory neurons* arise from cells of VPL nucleus of thalamus and project to the primary sensory area of the cerebral cortex (area 3, 1, 2).

Clinical Correlation

The **lesions of posterior white columns** (i.e. fasciculus gracilis and fasciculus cuneatus) cause loss of sensations of proprioception, two-point discrimination and vibration on the same side of body below the level of lesion, whereas the **lesions of medial lemniscus** produce contralateral loss of these sensations.

Due to loss of proprioception, the patient fails to get information from the muscles and joints to consciousness, hence he is not able to know the position and movements of the ipsilateral limb. For example if you dorsiflex his big-toe, he cannot tell whether the toe is pointing upwards or downwards if his eyes are closed.

The loss of vibration sense can be easily tested by applying a vibrating tuning fork to the bony prominences, such as lateral malleolus of fibula or styloid process of radius.

The loss of tactile discrimination is tested by putting the compass on the skin and gradually separating the two points of the compass until the patient can appreciate them as two separate points, not as one.

Points to Note

- The characteristics of fine touch or discriminative touch are that, one can recognize the location of stimulated points with precision and is also aware that the two points are touched simultaneously, even though they are close together.
- The touch and pressure sensations carried by the ventral spinothalamic tract are described as **crude touch** in contrast to the same sensations carried by the dorsal column pathways which are described as **fine touch** because the localization and two-point discrimination of sensations carried by ventral spinothalamic tract is poor.
- Fibres conveying sensations from the lower half of the body below the sixth thoracic segment, form the fasciculus gracilis placed medially in the posterior white column while the fibres from the upper half of the body form the fasciculus cuneatus placed laterally.
- The dorsal column pathways should ideally be called **dorsal column-medial lemniscal system or pathways** as it includes dorsal white columns of the spinal cord and the medial lemniscus of the brainstem.

Spinocerebellar Pathways (Pathways for Unconscious Proprioceptive Sensations)

Here it is important to mention that these sensory pathways consist of only two sensory neurons. The fibres of *second order sensory neurons* in spite of going to the thalamus, go to the cerebellar cortex through posterior and anterior spinocerebellar, and cuneocerebellar tracts.

The cell bodies of *primary sensory neurons* lie in the dorsal root ganglia, and those of secondary

sensory neurons in the thoracic nucleus (nucleus dorsalis).

Dorsal (posterior) spinocerebellar tract (Fig. 17.4)

The central processes of *first order sensory neurons* carrying the proprioceptive sensations enter the cord through posterior roots of the spinal nerves and terminate in the cells of **nucleus dorsalis (Clarke's column)** which is situated on the medial side of the base of the posterior horn.

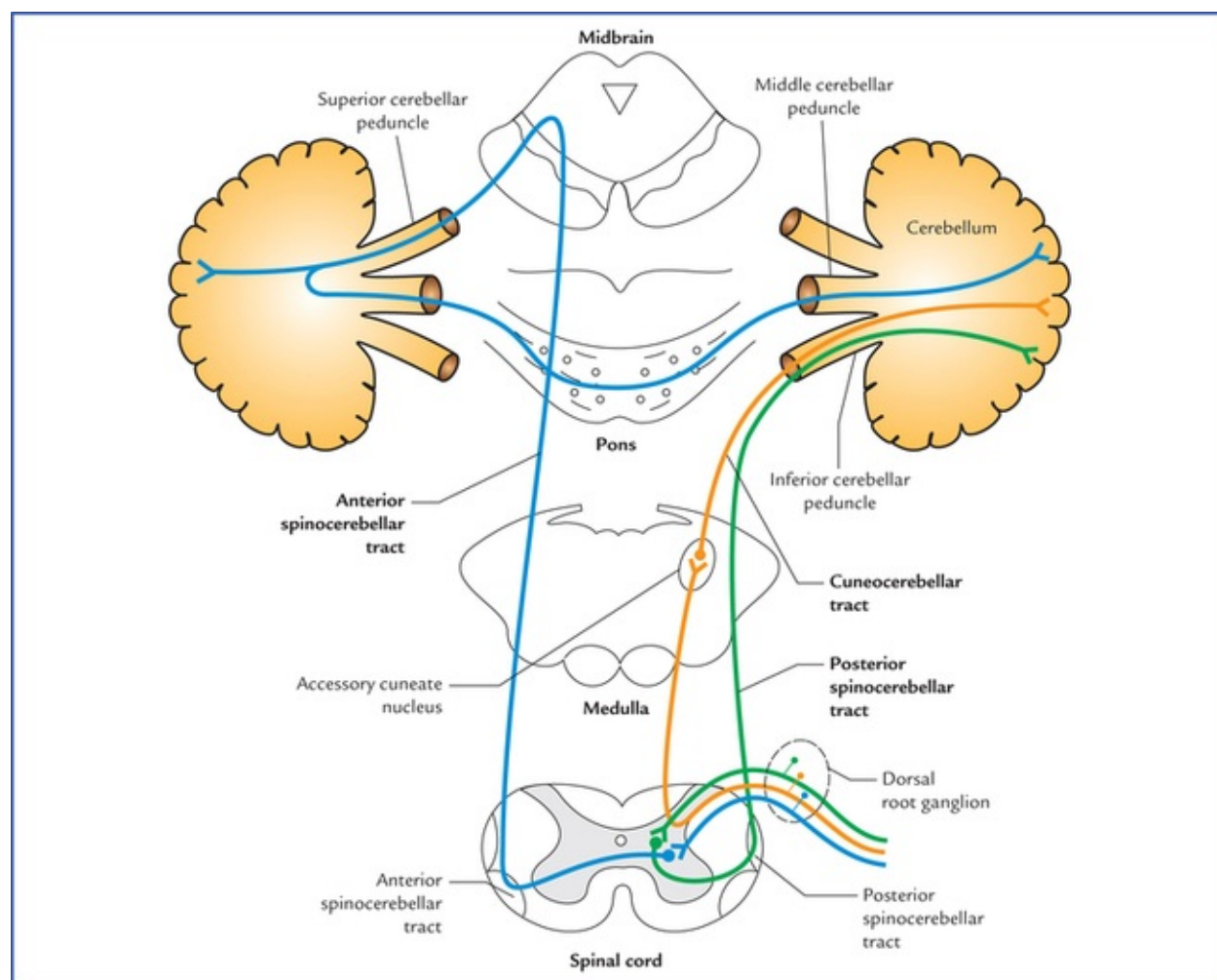


FIG. 17.4 Spinocerebellar pathways (i.e. posterior and anterior spinocerebellar and cuneocerebellar tracts). Note, posterior spinocerebellar and cuneocerebellar tracts enter the cerebellum through inferior cerebellar peduncle.

The axons of *second order sensory neurons* arise from the cells of Clarke's column, and enter the dorsolateral part of the lateral white column on the same side and ascend to form the *dorsal spinocerebellar tract*.

The fibres of this tract enter the cerebellum through the inferior cerebellar peduncle and project (end) in the ipsilateral cerebellar cortex.

Ventral (anterior) spinocerebellar tract (Fig. 17.4)

The central processes of *first order sensory neurons* carrying the proprioceptive sensations enter the cord through the posterior roots of the spinal nerves and terminate in the nucleus dorsalis at the base of the posterior horn. Most of axons of *second order sensory neurons* arising from nucleus dorsalis cross to the opposite side and reach the ventrolateral part of the lateral white column and ascend anterior to the fibres of dorsal spinocerebellar tract as the ventral spinocerebellar tract, however some of them ascend

as anterior spinocerebellar tract in the lateral white column of the same side.

The fibres ascend through the medulla oblongata and pons up to the midbrain then bends downwards to enter the cerebellum through the superior cerebellar peduncle and terminate in the ipsilateral cerebellar cortex.

N.B. The posterior spinocerebellar tract consists of only uncrossed fibres while the anterior spinocerebellar tract consists of both crossed (mainly) and uncrossed fibres.

The fibres of dorsal spinocerebellar tract enter the cerebellum through the inferior cerebellar peduncle and those of anterior spinocerebellar tract through superior cerebellar peduncle.

Cuneocerebellar tract (posterior external arcuate fibres) (Fig. 17.4)

As the Clarke's column is located only from C8 to L3 spinal segments. The axons of *first order sensory neurons* carrying proprioceptive sensations from upper limb and entering the spinal cord above C8 segment, ascend in the ipsilateral dorsal funiculus to terminate by synapsing with the cells of *accessory cuneate nucleus* of the medulla. The axons of *second order sensory neurons* arising from cells of accessory cuneate nucleus enter the ipsilateral cerebellum through the inferior cerebellar peduncle.

N.B. The cuneocerebellar tract is the counterpart of the posterior spinocerebellar tract for the upper limb.

Points to Note

- The dorsal and ventral spinocerebellar tracts carry proprioceptive sensations from lower limb and trunk while the cuneocerebellar tract carries the proprioceptive sensations from the upper limb.
- It is believed that most of the crossed fibres in the anterior spino-cerebellar tract cross again in the cerebellar white matter to reach the ipsilateral cerebellar cortex.
- Recent investigations have shown that some exteroceptive sensations (touch and pressure) may reach the cerebellum through these pathways.

Clinical Correlation

The information carried by dorsal and ventral spino-cerebellar, and cuneocerebellar tracts enable the cerebellum to perform unconscious coordination. The lesions of these tracts result in hypotonia of muscles and ataxia.

Trigeminothalamic Pathways

The trigeminothalamic pathways carry general and proprioceptive sensations from face and oral cavity to the somatosensory cortex.

Ventral trigeminothalamic tract (Fig. 17.5)

The ventral trigeminothalamic tract carries pain and temperature sensations from the face and the oral cavity.

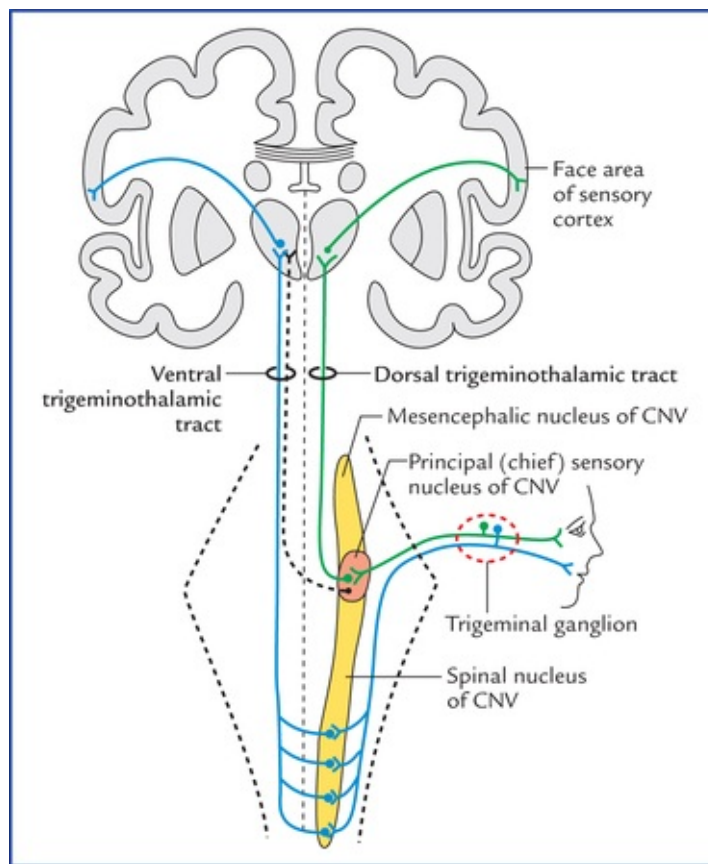


FIG. 17.5 Trigeminothalamic pathways. (CNV=trigeminal nerve.)

The cell bodies of **first order sensory neurons** are located in trigeminal ganglion. The axons of these neurons descend in the spinal tract of trigeminal nerve and synapse with the cell bodies of **second order sensory neurons** located in the spinal nucleus of the trigeminal nerve.

The axons of **second order sensory neurons** cross over to the opposite side ascend up to form the ventral trigemi-nothalamic tract and relay in the contralateral ventral posteromedial (VPM) nucleus of the thalamus.

The axons of **third order sensory neurons** arise from nerve cells of VPM nucleus of thalamus and project through the posterior limb of internal capsule to the face area of the somatosensory area (Brodmann's area 3, 1, and 2) of the cerebral cortex.

Dorsal trigeminothalamic tract (Fig. 17.5)

The dorsal trigeminothalamic tract carries sensations of tactile discrimination and pressure from face and oral cavity.

The **first order sensory neurons** are located in the trigeminal ganglion. The axons of these neurons synapse with the cell bodies of **second order sensory neurons** located in the principal sensory nucleus of the trigeminal nerve.

The axons of **second order sensory neurons** ascend up to form the *dorsal trigeminothalamic tract* and relay in the ipsilateral VPM nucleus of the thalamus.

The axons of **third order sensory neurons** arise from nerve cells VPM nucleus of thalamus and project through the posterior limb of the internal capsule to the face area of mostly ipsilateral of the somatosensory cortex (Brodmann's area 3, 1 and 2).

Clinical Problems

1. Explain, why the **Babinski's sign** is present in adults only if there is a lesion of corticospinal (pyramidal) tract (**upper motor neuron lesions**) but in infants and children up to the age of one it is normally present.
2. Explain, why light touch is very sensitive but not highly discriminative (poorly localized).
3. The lesions of the posterior white column (fasciculus gracilis and fasciculus cuneatus) cause the loss of proprioception, fine touch, and vibration on the same side of the body whereas, the lesions of medial lemniscus cause the loss of these sensations on the opposite side of the body. Explain why it is so.

Clinical Problem Solving

1. When the skin along the lateral aspect of the sole of a foot is scratched with a blunt object the normal response is plantar flexion of all the toes. This is because, normally corticospinal tracts produce plantar flexion of toes in response to sensory stimulation of the skin of the sole of the foot. When corticospinal tracts are damaged (**UMN lesion**), the influence of other descending tracts become apparent in the form of withdrawal reflex, characterised by dorsiflexion of the great toe and fanning of the other toes (**Babinski's sign**).

The **Babinski's sign** is normally present in children during the first year of their life, because the corti-cospinal tract is not myelinated until the end of the first year of life (the myelination of corticospinal tract starts 10 to 14 days after the birth and completed by the end of first year).

N.B. The corticospinal tracts become functional only after their constituent fibres are myelinated.

2. The first order sensory neurons of anterior spinothalamic tract carrying (light touch), after entering the spinal cord, ascend or descend for 8 to 10 segments before synapsing with the second order sensory neurons. While ascending or descending the *first order sensory neurons* give collateral branches that synapse with *second order sensory neurons* of several segments of the cord. Thus collateral branches from number of first order sensory neurons carrying information of light touch from sensory receptors in different patches of skin converge on a single second order neuron and enhance its afferent conduction. As a result, the light touch requires less peripheral stimulation to produce action potentials in the ascending pathway (anterior spinothalamic tract) with consequent increased light touch sensitivity. However it results in less discriminative information because sensory receptors from more than one points of skin have input on to the same second order neuron, which cannot distinguish one small area of skin from another within the zone where its sensory receptors are located.
3. See Clinical correlation on [page 205](#).

Special Senses and their Neural Pathways

There are five types of special senses, viz. (a) sense of smell, (b) sense of vision, (c) sense of sound/hearing, (d) sense of balance, and (e) sense of taste. The special senses have highly specialized receptors which provide specific information about the environment, i.e. they respond to only one type of stimulus. These receptors are located close to the brain and are well protected within the skull. Their responses are more complex but well coordinated within the brain. The special senses: (a) of smell and taste depend on chemoreceptors, (b) of vision on photoreceptors, and (c) of sound and balance on mechanoreceptors.

Olfactory System

In lower vertebrates and many mammals such as dog the sense of smell is highly developed and they are called *macrosmatic*. In humans the sense of smell is less developed, hence they are called *microsmatic*.

The olfactory system transmits sense of smell from olfactory epithelium of nasal mucosa to the olfactory cortex of the brain. The following structures are included in the olfactory system:

- Olfactory epithelium and olfactory nerves
- Olfactory bulb, tract and striae
- Olfactory cortical areas.

Olfactory Epithelium and Olfactory Nerves

The olfactory epithelium is a specialised nasal epithelium which lines the superior one-third of the nasal cavity including the roof (Fig. 18.1). It consists of three types of cells: (a) olfactory receptor cells, (b) supporting cells, and (c) progenitor/basal cells (Fig. 18.2).

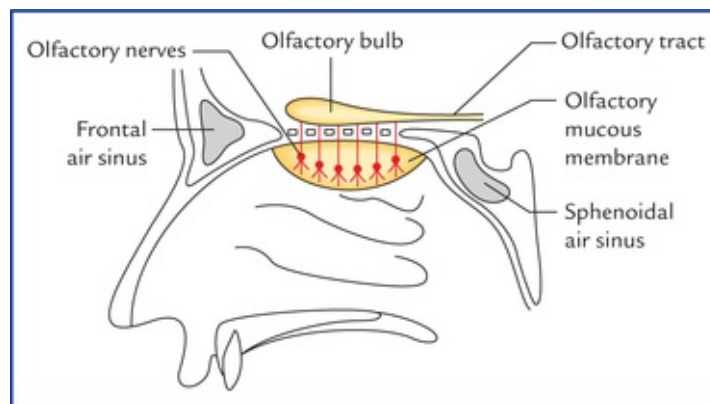


FIG. 18.1 Location of olfactory epithelium in the nasal cavity.

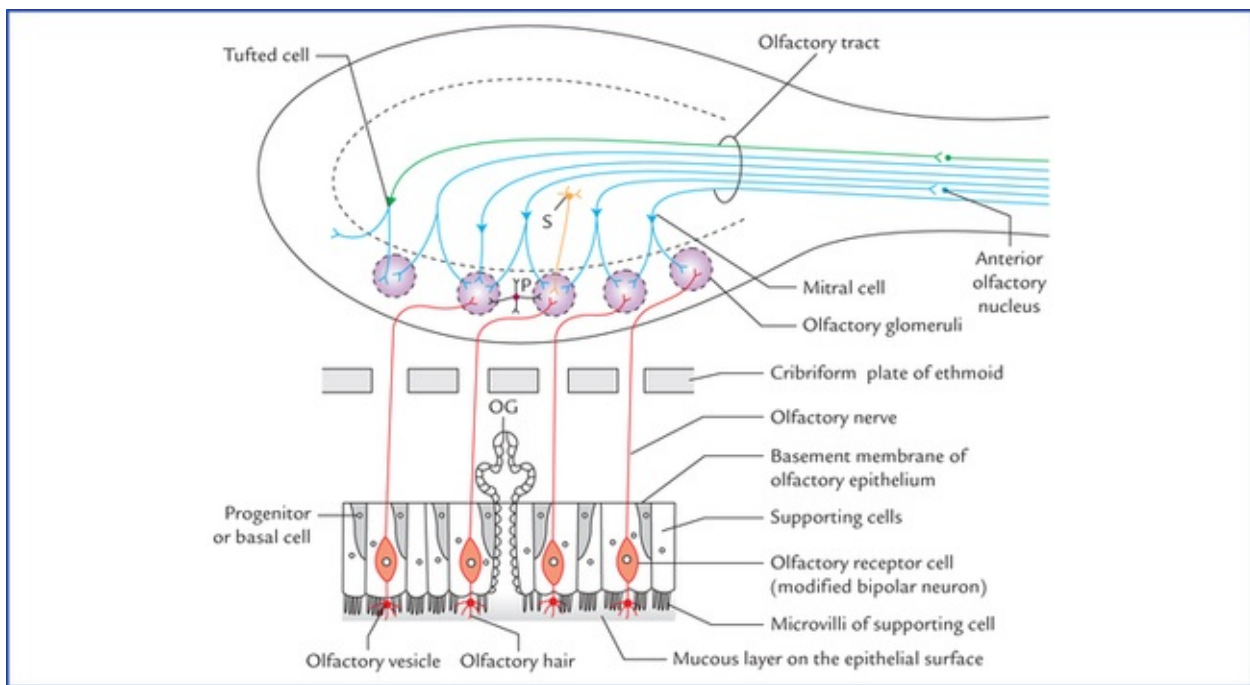


FIG. 18.2 Cellular components of olfactory epithelium and the olfactory bulb. (S = stellate cell, P = periglomerular cell, OG = olfactory glands (of Bowman).)

The **olfactory receptor cells** are, in fact, the modified bipolar neurons and lie vertically between the supporting cells. Their dendrites extend as naked processes towards the free surface of the epithelium, where they end by forming bulbous enlargements called **olfactory vesicles**. These vesicles possess cilia—**olfactory hairs** which lie in a thin mucous film covering the epithelial surface. The **supporting cells** present many microvilli towards the free surface of the epithelium. The mucous film covering the olfactory epithelium is secreted by the **olfactory glands (of Bowman)** and the microvilli of the supporting cells.

The air-borne molecules enter the nasal cavity and are dissolved in this mucous film. The odour producing molecules thus released, bound to the receptor cells. The olfactory cilia react by depolarizing and initiating action potentials in the receptor cells.

As mentioned above, the olfactory receptors of olfactory epithelium are actually neurons. *This is the only site in the body where neurons are exposed to the surface of the body.*

The receptor cells continuously degenerate and are renewed by the **progenitor cells**. *The ability to regenerate primary sensory neurons is unique to mammalian nervous system.*

The axons of receptor cells are fine unmyelinated fibres. They ascend and collect to form about 20 bundles called **olfactory nerves**. The olfactory nerves pass through the foramina of cribriform plate of ethmoid bone to enter the anterior cranial fossa where they terminate in the olfactory bulb.

Olfactory Bulb, Tract and Striae (Figs 18.3–18.5)

The olfactory bulb is a flattened oval mass of grey matter lying just above the cribriform plate. It consists of an outer cortical zone and an inner medullary zone.

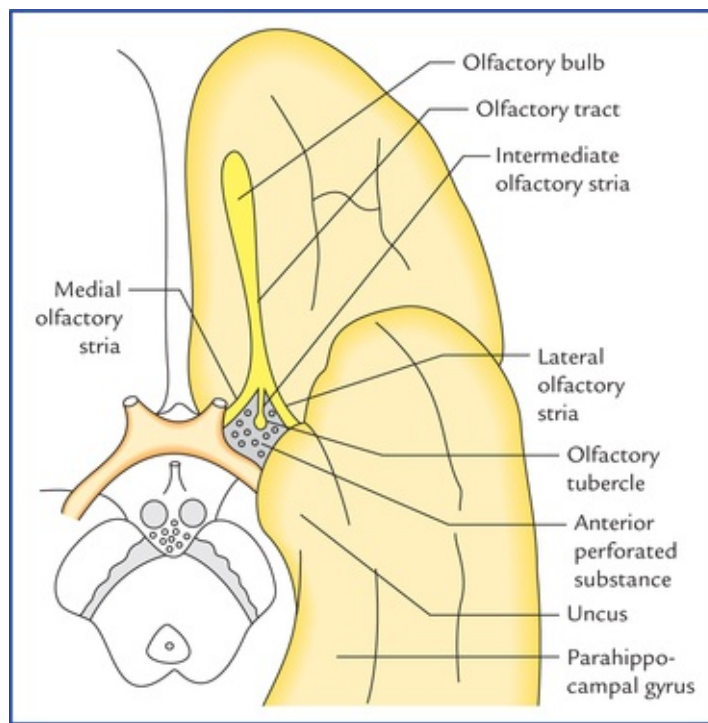


FIG. 18.3 Some of the olfactory structures related to the anterior part of the base of the brain.

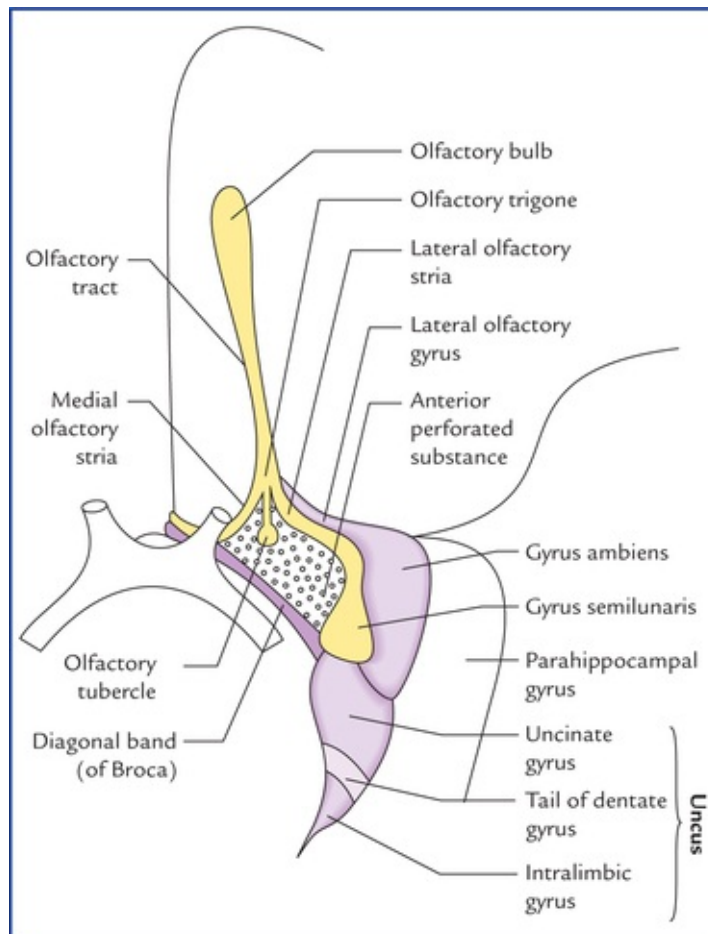


FIG. 18.4 Structures on the inferior aspect of the brain in the area surrounding the optic nerves, chiasma, optic tracts, and interpeduncular fossa. Many of these structures are related to olfactory and limbic system.

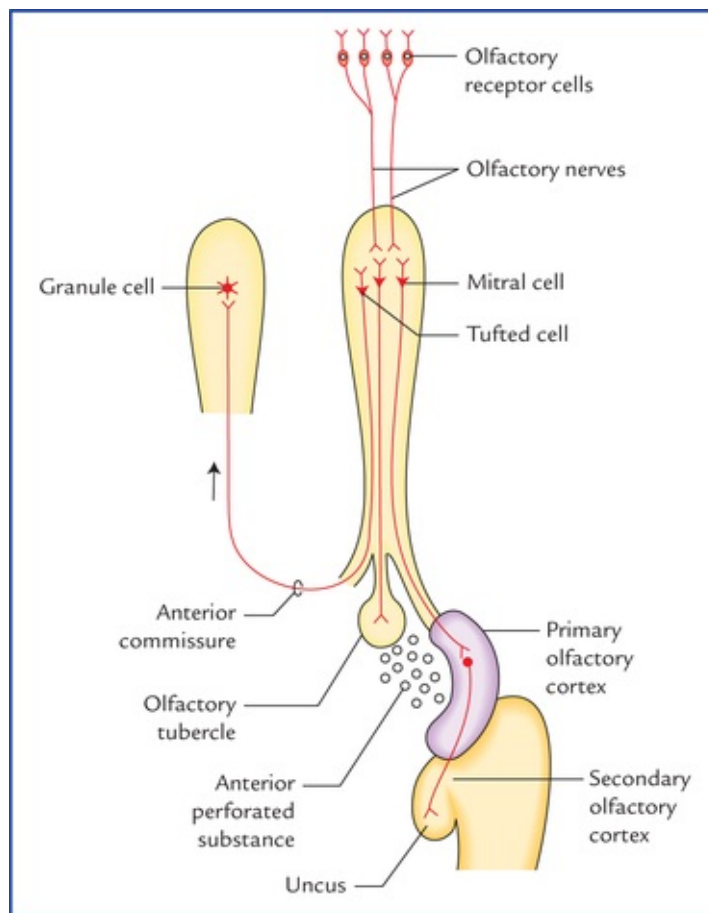


FIG. 18.5 Olfactory pathway.

The *cortical zone* contains olfactory glomeruli and nerve cells which form most of the prominent cellular component of the olfactory bulb. The nerve cells of the olfactory bulb comprise (Fig. 18.2):

- Mitral cells.
- Tufted cells (analogous to but smaller than the mitral cells).
- Stellate (granule) cells, and
- Periglomerular cells.

The *medullary zone* consists of nerve fibres of the olfactory tract. A small group of nerve cells situated at the transitional zone between the olfactory bulb and olfactory tract constitute the **anterior olfactory nucleus**.

Olfactory bulb continues posteriorly as **olfactory tract** (Figs. 18.3 and 18.4). When traced posteriorly the olfactory tract divides into **medial and lateral olfactory striae**. The point of bifurcation is expanded and forms the **olfactory trigone**. The medial and lateral olfactory striae are intimately related to the anterior perforated substance and form its anteromedial and anterolateral boundaries respectively. An **intermediate stria** is sometimes present. It extends from the centre of trigone to anterior perforated substance where it sinks into the base of olfactory **tubercle**, which is a small elevation of anterior perforated substance immediately caudal to the olfactory trigone.

Posterolaterally the anterior perforated substance is related to the uncus while posteromedially it is bounded by a small bundle of fibres called **diagonal band of Broca**.

Olfactory Cortical Areas

The **primary olfactory cortex** lies between the anterior perforated substance and the uncus. The **entorhinal area** comprising uncus and anterior part of the parahippocampal gyrus is often termed

secondary olfactory cortex.

Neural Pathways for Sense of Olfaction (Fig. 18.5)

The axons of the olfactory receptor cells carrying olfactory sensations from olfactory epithelium (**first order sensory neurons**) collect to form small bundles (**olfactory nerves**) which pass through the cribriform plate of the ethmoid bone, to enter the **olfactory bulb** where they terminate in the **olfactory glomeruli**. The glomeruli are formed by the axons of receptor cells and dendrites of mitral and tufted cells (these cells form the **second order sensory neurons** in the olfactory pathway).

Each glomerulus receives impulses from about 26,000 receptor cells and passes this information to the olfactory cortical areas through mitral and tufted cells.

The most of the axons of mitral cells form the **lateral olfactory stria** and run to the **primary olfactory cortex** on the same side which is located between the anterior perforated substance and the uncus on the inferomedial surface of the temporal lobe. The details are shown in [Figure 18.4](#). The others run via **intermediate olfactory stria** to connect with the **olfactory tubercle**, and hence with the limbic system.

The axons of the tufted cells run in the **medial olfactory stria** and cross the midline in the *anterior commissure* to form synapses with the granule cells in the opposite olfactory bulb.

It should be noted that in contrast to all other sensory pathways, the fibres of second order sensory neurons reach the primary olfactory cortex directly without relay in one of the thalamic nuclei or its equivalent nucleus like lateral geniculate body.

The **entorhinal area** (Brodmann's area 28) receives few or no tract fibres directly but receives fibres profusely from primary olfactory cortex, hence it is sometimes called **secondary olfactory cortex**.

Unique features of the olfactory pathway

- The olfactory pathway consists of only two neurons whereas other conscious sensory pathways consist of at least three neurons.
- Olfactory impulses are transmitted directly to the cerebral cortex without relay in the thalamus.

Clinical Correlation

- A tumour (*viz.* meningioma) in the floor of anterior cranial fossa may compress the olfactory bulb and tract and interfere with or cause loss of smell to the same side only. *It is therefore important to test for smell through each nostril.*
- The sectioning of anterior commissure impairs the sense of smell.
- The sense of smell contributes significantly to the sense of taste. The sensation of delicious food is in fact an appreciation of aromas through the olfactory system. Persons who have lost their sense of smell, often complain of loss of taste.

This phenomenon can be demonstrated by pinching one's nose to close the nasal passages, while trying to taste something with olfaction blocked, *it becomes difficult for a person to distinguish between the taste of a piece of apple and a piece of potato.*

- The receptor cells themselves are the first order sensory neurons.

- The receptor cells are exposed to the surface of the body.

Visual System

The vision (sight) is the most important special sense in humans. The visual system transmits sense of vision (sight) from retina of eyeball to the visual cortex. The following structures are included in the visual system:

- Retina
- Optic nerve
- Optic chiasma
- Optic tract
- Lateral geniculate body
- Optic radiation (geniculocalcarine tract), and
- Visual cortex

Retina

The retina forms the inner photosensitive coat of the eyeball. It consists of two layers, an inner **neural layer** and an outer layer of **pigment epithelium** (Fig. 18.6).

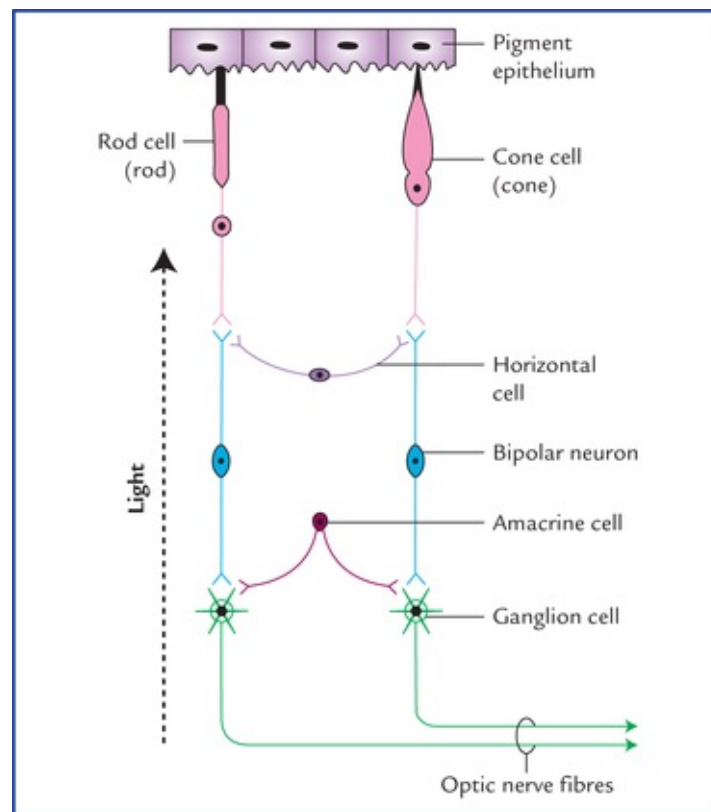


FIG. 18.6 Three basic layers of retina and their constituent cells. The arrow (on the left side) indicates the direction of light falling on the retina. It is important to note that several rods and cones converge on a single bipolar neuron and several bipolar neurons activate one ganglion cell. The one-to-one relationship between rods and cones, bipolar neurons and ganglion cells shown in this figure is only for the sake of simplicity.

Neural layer

The neural layer contains three basic layers of cells:

- An outer layer of **rod and cone cells**
- A middle layer of **bipolar cells**
- An inner layer of **ganglion cells**

The other cells are **association neurons** and **neuroglial cells**.

Rod and cone cells

The rods and cones (around 150 million in number) are modified neurons and serve as *photoreceptors*. Both consist of an outer and inner portion, the former being light sensitive and contains photopigments, **rhodopsin** in case of rods and **iodopsin** in case of cones which convert the stimulus of light into a nerve impulse. The outer portion is rod-shaped in case of rods and cone-shaped in case of cones, hence the names rods and cones. The inner portions of rods and cones are slender and are termed rod and cone fibres respectively. *The cones respond better to the bright light and are responsible for visual acuity and colour vision. They are most numerous in the central region of the retina. Rods on the other hand, predominate in the peripheral part of the retina. They respond to poor light and are important for peripheral vision.*

Bipolar cells

Bipolar cells are bipolar neurons, interposed between the photoreceptor cells and the ganglion cells.

Ganglion cells

Ganglion cells are large multipolar neurons forming the last retinal link in the visual pathway. The axons of ganglion cells form a layer of nerve fibres adjacent to the vitreous humour. These fibres converge towards the rounded area (optic disc) from all directions where they pierce the choroid and sclera, about 3 or 4 mm to the nasal side of the posterior pole of the eyeball and constitute the optic nerve.

The **optic disc**, about 1.5 mm in diameter, is slightly (3 mm) medial to the posterior pole. It is insensitive to light as it has no sensory receptors (**blind spot**). It represents the point of exit of the optic nerve fibres. Its central part is pierced by central artery of retina and tributaries of central vein of retina. **The optic disc may be regarded as a window to the brain and its examination is an important step in the diagnosis and prognosis of diseases with vascular and neurological implications.**

The **macula lutea** is a yellowish oval area of 6 mm in diameter near the centre of the posterior part of the retina. It is in line with the visual axis. The name macula lutea or yellow spot is derived from the presence of yellow pigment (xanthophyll) among the nerve cells in this region.

A small depression in the centre of the macula lutea is called **fovea centralis**. The fovea is about 1.5 mm in diameter and is separated from the edge of optic disc by a distance of 3 mm. The visual acuity is maximum at the fovea (i.e. clearest vision). The fovea is believed to contain only cone receptors.

Clinical Correlation

The retina can be examined directly through an ophthalmoscope and following features are seen in its posterior part (fundus): (a) optic disc/optic papilla/ blind spot, (b) central artery of retina emerging from optic disc, (c) tributaries of central vein of retina converging towards the optic disc, (d) macula lutea, and (e) fovea centralis.

N.B. The optic disc looks pink in colour due to the presence of capillary vessels. In optic

atrophy the disc looks white as the capillary vessels disappear.

Pigment epithelium

Pigment epithelium consists of a single layer of cells containing melanin pigment. Pigment epithelium reinforces the light absorbing proportion of the choroid to reduce the scattering of light within the eye.

Clinical Correlation

While pigment epithelium is firmly attached to the choroid but it is not so firmly attached to the neural layer of retina. The pigment epithelium of retina develops from an outer layer and the neural layer from the inner layer of the optic cup. As a result there remains a potential space between the two layers. Therefore the **detachment of retina** which may follow a blow on the eye, consists of separation of neural layer from pigment epithelium, i.e. at the junction of two layers of optic cup.

The visual field and retinal quadrants

When one looks straight ahead with eyes fixed, that part of external world which can be seen with each eye is called **visual field** of that eye. Thus it is the area within which an object can be seen while the eye fixes on a spot of light or object. Laterally it extends up to 104 degree and on nasal side 65 degree. In front there is a cone-shaped area in which the visual fields of two eyes overlap. Therefore, area seen by one eye and that seen by both the eyes is more or less same except a small area that can be seen only by the eye of that side (Fig. 18.7).

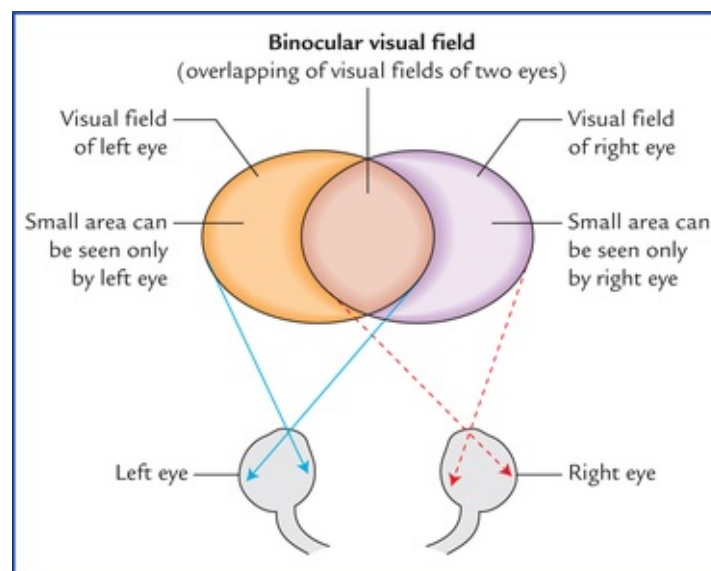


FIG. 18.7 Visual fields of the two eyes and binocular visual field.

For the sake of convenience of description, the visual field is conventionally divided into right and left

halves. Each half is further divided into an upper and a lower half, so that visual field is described to consist of four quadrants (Fig. 18.8).

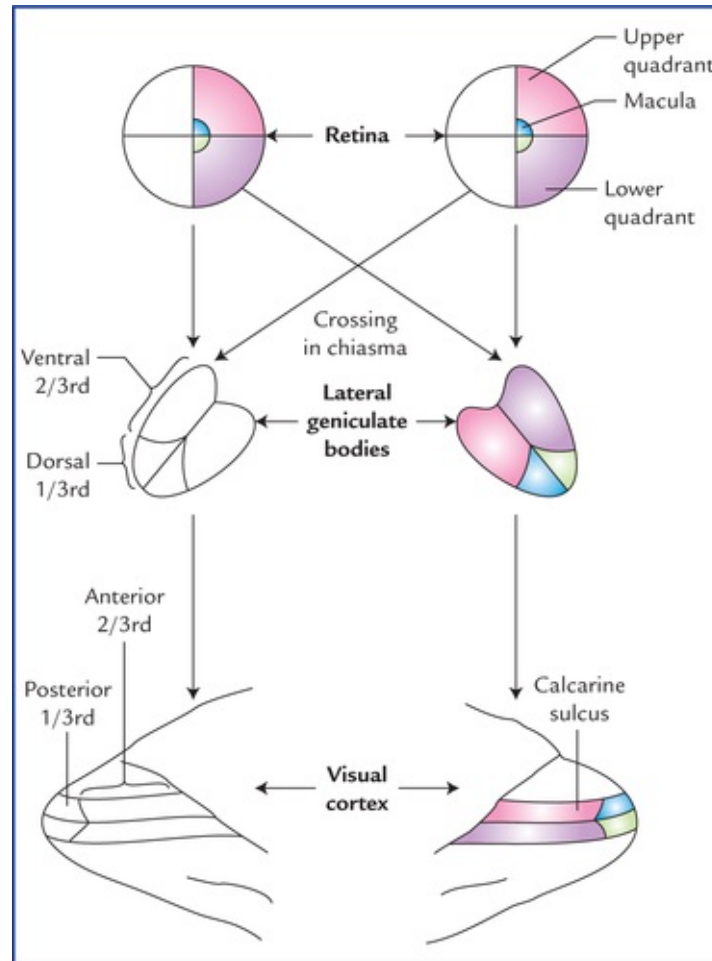


FIG. 18.8 Scheme to show the projection of retina on the lateral geniculate body and the visual cortex. The details are shown only for the right halves of the two retinae.

In a similar manner the retina is also divided into four quadrants (Fig. 18.8). First each retina is divided into nasal and temporal halves by a vertical line passing through the fovea centralis. Then a horizontal line also passing through the fovea, divides each half of retina into upper and lower quadrants. The macular area (responsible for most acute vision) is represented separately from the peripheral parts of the retina. *Light rays can enter the eye only through the pupil and since they travel in straight lines, it is obvious that objects of temporal field of vision are perceived by the nasal half of the retina whereas those in the nasal half are perceived by the temporal half of the retina.*

Central projection of retinal areas

The following **general rules** concerning central projection of retina should be carefully understood before discussing the components of the optic pathway:

- Fibres from right halves of two retinae terminate in the right lateral geniculate body and those from left halves terminate in the left lateral geniculate body. The visual information from lateral geniculate body of each side is relayed into the visual cortex of the corresponding side.
- Fibres from peripheral parts of retina end in the ventral two-thirds of the lateral geniculate body and those from the macula into the dorsal one-third of lateral geniculate body. Fibres from upper quadrants end in the medial half and those from lower quadrants in the lateral half of the geniculate body.

- The fibres from medial half of the lateral geniculate body relay into the upper lip of the calcarine sulcus and those from the lateral half into the lower lip of calcarine sulcus of the occipital lobe. Peripheral and macular quadrants maintain the same relationship as that in the lateral geniculate body, i.e. peripheral quadrants occupy the anterior two-third of visual cortex and macular quadrants occupy the posterior one-third of visual cortex.
- The portion of lateral geniculate body and visual cortex receiving fibres from macula (only 6 mm in diameter) are disproportionately larger.
- Thus specific points on the retina project to the specific points in the lateral geniculate body and similarly specific points in the lateral geniculate body are projected to the specific points in the visual cortex. Therefore, point to point relationship is maintained between the retinae and the visual cortex.

Figure 18.8 represents the above mentioned rules.

Optic Nerve, Optic Chiasma and Optic Tract

The **optic nerve** comes out by piercing the sclera 3 mm medial to the posterior pole of the eyeball. In man it contains about one million fibres, which are the axons of ganglion cells of retina. It passes through the optic canal to reach the middle cranial fossa, where it approaches and joins its counterpart of the other side to form the **optic chiasma** above the roof of pituitary fossa. Posteriorly the chiasma divides into two **optic tracts** which after winding round the cerebral peduncles end in the lateral geniculate body of the corresponding side. The optic nerve is about 4 cm in length. Throughout its course the nerve is surrounded by the extensions of the meninges, i.e. pia, arachnoid and dura mater. The meningeal extensions around the nerve fuse with the scleral coat of the eyeball. The subarachnoid space around the nerve is continuous with that of brain. The fibres arising from macula are numerous and form the **papillomacular bundle**.

The fibres of optic nerve arising in the nasal half of each retina (nasal fibres) enter the optic tract of the opposite side after crossing in the optic chiasma.

It is to be noted that immediately after crossing, these fibres loop forward for a short distance in the optic nerve. Therefore, a lesion affecting optic nerve just in front of optic chiasma leads to temporal field defect in opposite eye and blindness on the side of lesion. Fibres from temporal half of each retina (temporal fibres) enter the optic tract of the same side. Thus due to the decussation of nasal fibres of optic nerves in the optic chiasma, each optic tract contains the temporal fibres of the same side and nasal fibres of the opposite side.

Lateral Geniculate Body

The structure of lateral geniculate body has already been discussed on [page 131](#). This body (or nucleus) is the site of termination of all the optic nerve fibres except the few which reach and relay in the pretectal region and superior colliculus of the midbrain. These fibres form an afferent limb of the pupillary light reflex. Recent studies show that geniculate body receives afferents from the visual cortex also.

Geniculocalcarine Tract

Fibres arising from cells of lateral geniculate body constitute the *geniculocalcarine tract*. First these fibres pass through the retrolentiform part of the internal capsule, then they fan out to form the **optic radiation** which end in the visual cortex (area 17, 18 and 19) of the occipital lobe. Some of the geniculocalcarine fibres loop forward over the temporal (inferior) horn of lateral ventricle before curving

posteriorly towards the occipital lobe and constitute the **temporal loop (Meyer's loop)** of geniculocalcarine tract. Fibres forming this loop arise from the lateral part of the lateral geniculate body.

Visual Cortex

Visual cortex includes primary and secondary visual areas. These are described in detail on [pages 152 and 153](#).

Neural Pathway for Vision (Fig. 18.9)

The neural pathway for vision is a three order neuronal pathway.

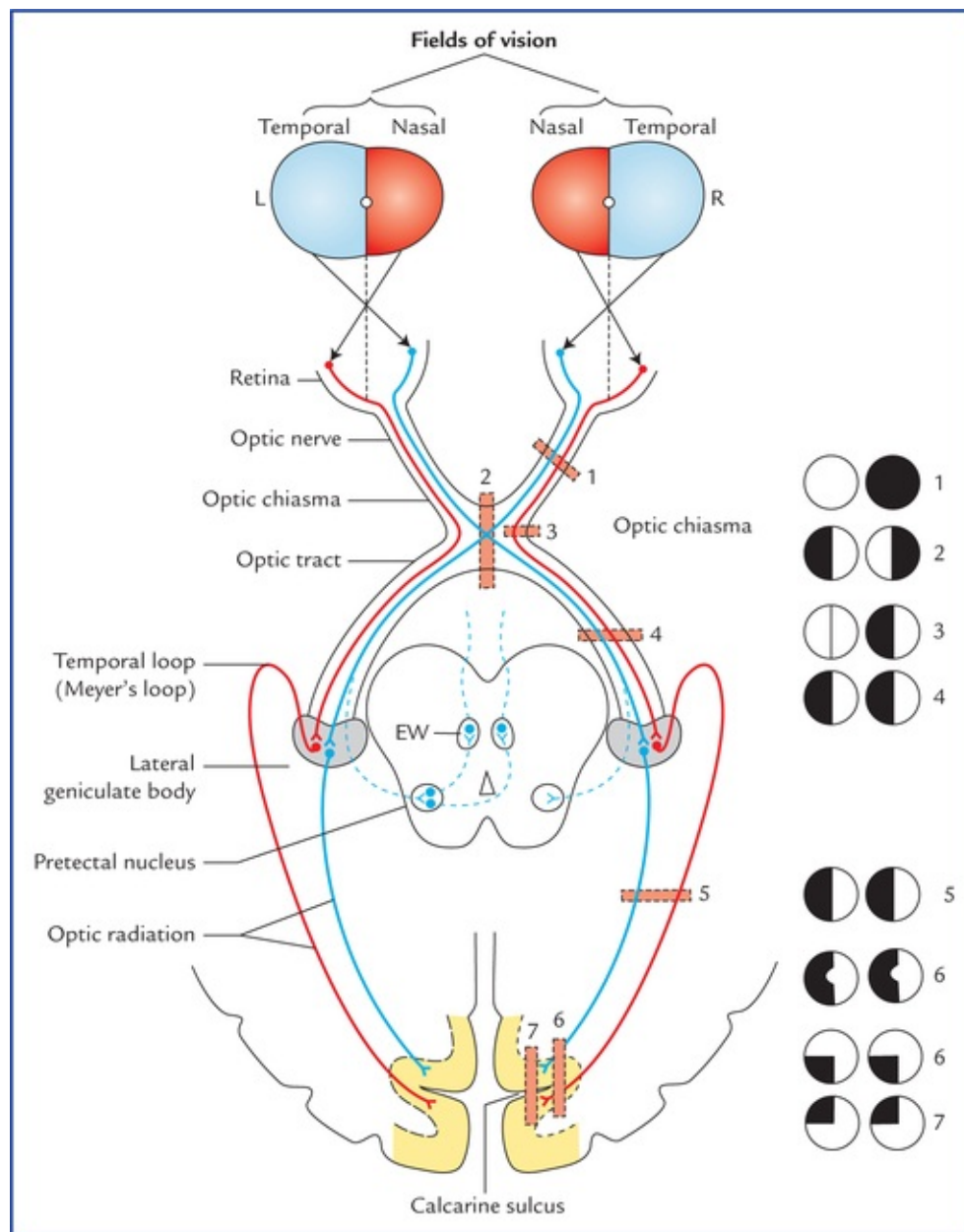


FIG. 18.9 The visual pathway and sites of various lesions affecting it. The black areas of inserts on the right side indicate the visual field defects: 1 = complete blindness of right eye, 2 = bitemporal hemianopia, 3 = right nasal hemianopia, 4&5 = left homonymous hemianopia, 6 = homonymous hemianopia with macular sparing, 7 = contralateral inferior quadrantic hemianopia, 8 = contralateral superior quadrantic hemianopia.

The **first order sensory (primary) neurons** carrying visual sensations are bipolar cells of the retina. Their dendrites synapse with photoreceptors (rods and cones) and axons with the dendrites of ganglion cells.

The **second order sensory (secondary) neurons** are the multipolar neurons (generally referred by most authors as ganglion cells) whose axons run along the optic nerve to the optic chiasma, where fibres from nasal half of retina cross to the opposite side and travel through the opposite optic tract to terminate in the opposite lateral geniculate body. The fibres from temporal half remain uncrossed in the optic chiasma and run in optic tract of the same side to terminate in the ipsilateral geniculate body. The fibres from macula lutea behaves in the exactly same manner.

The cell bodies of **third order sensory (tertiary) neurons** are located in the lateral geniculate body. Their axons form the optic radiations which project to the visual cortex.

Clinical Correlation

The **blindness** is conventionally described with reference to the field of vision rather than with reference to the parts of retina. Loss of vision in one-half of the visual field (right or left) is termed **hemianopia**. If same halves of visual fields are affected in both the eyes, it is called **homonymous hemianopia**. On the other hand if different halves of visual fields are affected, the term **heteronymous hemianopia** is used.

The visual field defects caused by lesions affecting different parts of the visual pathway are described in [Figure 18.9](#).

1. *Injury of optic nerve* of one side will result in **total blindness** in the eye of that side.
2. *Damage of central part of optic chiasma* (as may occur from pituitary tumour) interrupts the crossing fibres from nasal halves of two retinae, and results in **bitemporal heteronymous hemianopia (tunnel vision)**.
3. *Destruction of lateral part of optic chiasma* on one side (as may occur from aneurysm of internal carotid artery) produces a **unilateral nasal hemianopia** on the side of lesion.
- 4 & 5. *Complete destruction of optic tract (4), geniculocalcarine tract (5)* on one side results in blindness in opposite half of field of vision (i.e. nasal field of ipsilateral eye and temporal field of contralateral eye). This type of defect is described as **right or left homonymous hemianopia**, depending upon the side of lesion.
6. Lesions involving visual cortex produce blindness in opposite half of field of vision (**homonymous hemianopia**), **with sparing of macular vision**.
7. *Destruction of upper tip of calcarine sulcus* on one side produces visual loss in lower quadrant of opposite field of vision (**contralateral inferior quadrantic anopia**).
8. *Destruction of lower lip of calcarine sulcus* on one side produces visual loss in superior quadrant of opposite field of vision (**contralateral superior quadrantic anopia**).

N.B.

- A temporal lobe lesion involving temporal loop (also called **Meyer's loop**) of geniculocalcarine tract on one side causes defect in superior quadrant of opposite field of vision (superior quadrantic anopia).
- Lesions anterior to lateral geniculate body also interrupts the fibres responsible for the

Visual Reflexes

Light reflex or pupillary reflex

When light is shown to one eye, normally the pupils of both the eyes constrict. The constriction of pupil upon which the light is shown is termed **direct light reflex** and the constriction of the pupil of the other eye (even though no light fell upon that eye) is termed **indirect or consensual light reflex**.

Pathway of the reflex (Fig. 18.10)

Afferent limb: The visual impulses travel through the optic nerve, optic chiasma and optic tract to terminate in the *pretectal nucleus*. Then the impulses from pretectal nucleus pass to the parasympathetic nuclei (Edinger-Westphal nuclei) of the IIIrd cranial nerve of both sides.

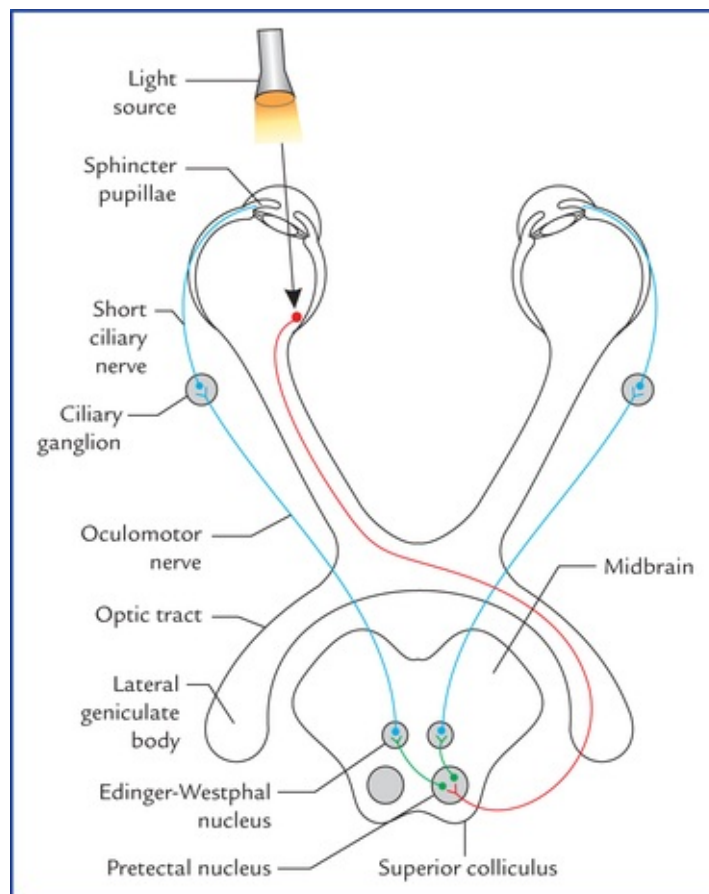
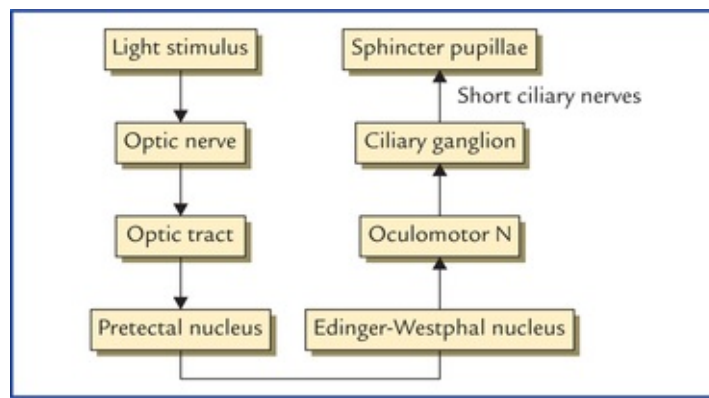


FIG. 18.10 Pathways for light reflex (direct and consensual).

Efferent limb: The impulses from the Edinger-Westphal nucleus pass bilaterally along the oculomotor nerve to the ciliary ganglion. The postganglionic parasympathetic fibres travel along the short ciliary nerves to supply the sphincter pupillae muscle of the iris leading to constriction of pupils of the both eyes. The afferent and efferent limbs of light reflex are depicted in [Flowchart 18.1](#).



FLOWCHART 18.1 Light reflex.

Accommodation reflex

When the eyes are focused from a distant to a near object, *three reactions* take place in the eyes, viz.

- There is **constriction of the pupils** due to action of sphincter pupillae to restrict the light waves to the thickest central part of the lens.
- There is **thickening of the lenses** due to contraction of the ciliary muscles, to increase the refractive index of the lenses.
- There is **convergence of both the eyeballs**, due to the contraction of medial recti, to bring about the convergence of the ocular axes.

These three reactions together constitute the *accommodation* or *near reflex*.

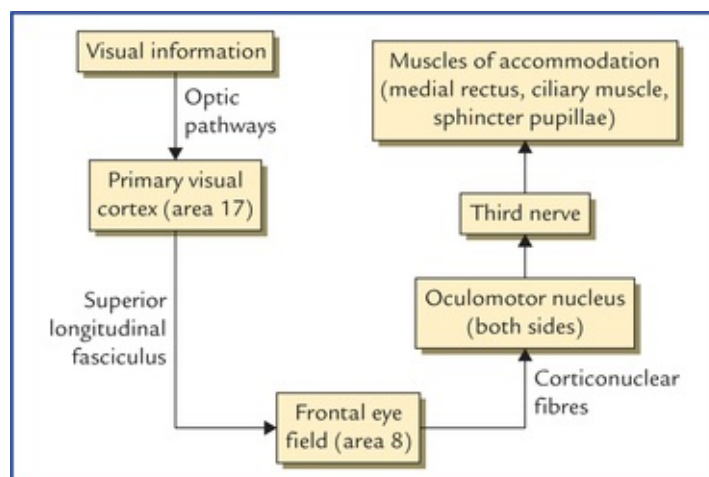
Pathways of the accommodation reflex

Afferent limb: The visual impulses travel through the optic nerve, optic chiasma, optic tract, lateral geniculate body, and the optic radiation to the visual cortex.

From visual cortex the impulses reach the ‘frontal eye field’ through association fasciculus, the *superior longitudinal fasciculus*.

Efferent limb: From ‘frontal eye field’ the corticonuclear fibres project to the oculomotor nerve nuclei of both the sides. From here the impulses travel through the oculomotor nerves to supply, all the three muscles, viz. sphincter pupillae, ciliary muscle and medial rectus of the eyeballs whose active action is needed for accommodation.

The afferent and efferent limbs of accommodation reflex are depicted in [Flowchart 18.2](#).



N.B.

- Since all the muscles responsible for accommodation are supplied of oculomotor nerve, the oculomotor nerve is often termed **nerve of accommodation**.
- Accommodation reflex is bilateral.

Clinical Correlation

Since accommodation is an active process and involves a muscular effort, watching of television or reading for long period may be tiring and may produce headache due to muscular fatigue.

Auditory System

The hearing is second in importance among the special senses in humans after the vision. The auditory system transmits the stimulus responsible for hearing from the **hearing receptor** in the internal ear (also called **spiral organ or organ of Corti**) to the auditory area of the cerebral cortex.

The following structures are included in the auditory system:

- Organ of Corti (hearing receptor).
- Dorsal and ventral cochlear nuclei.
- Trapezoid body and its nuclei.
- Lateral lemniscus.
- Inferior colliculus.
- Medial geniculate body.
- Auditory radiation.
- Auditory cortex.

Organ of Corti (Hearing Receptor) (Fig. 18.11)

Organ of Corti is located in the cochlear duct. The cells inside the cochlear duct are highly modified to form a structure called **organ of Corti**. The organ of Corti consists of:

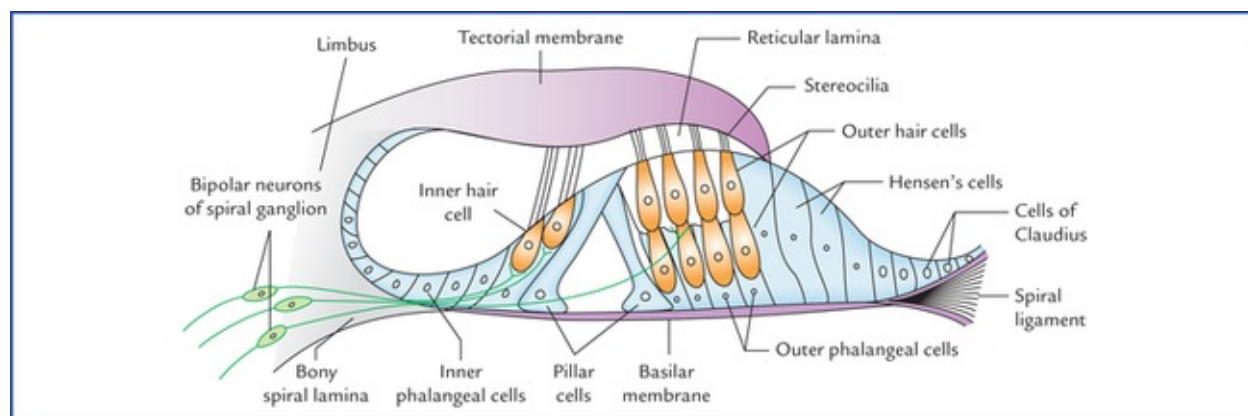


FIG. 18.11 Spiral organ (organ of Corti).

- Two rod (pillar) cells called **rods of Corti** stand on the basilar membrane and project into the scala media. The triangular interval between the two rods the *tunnel of Corti* is filled with perilymph.
- Specialized sensory cells called **hair cells**, are arranged in a single row internal to the inner rod, and in 3 or 4 rows external to the outer rod. From the upper surface of the hair cells project tiny cilia called *stereocilia*. The tips of the cilia are embedded within the gelatinous shelf called *tectorial membrane*, which is attached at one end to the limbus and at the other end to the Hensen's cells. The afferent fibres of cochlear nerve form synaptic contact with the plasma membrane of the hair cells.
- The **phalangeal cells (supporting cells of Deiter)** form cap-like investments around the bases of hair cells. The supporting Hensen's cells are elongated columnar cells and lie outside the external row of outer hair cells, succeeded more laterally by *cubical cells of Claudius*.
- The **reticular lamina** is a tough membrane supported by rods of Corti and presents tiny holes for the passage of stereocilia.

The spaces other than the tunnel of Corti in the organ of Corti are filled with the corticolymph.

Steps Involved In Hearing

- The sound waves are collected by the auricle and are conducted through the external auditory meatus to the tympanic membrane to make it vibrate.
- The vibrating tympanic membrane causes 3 ear ossicles in the middle ear (malleus, incus and stapes) to vibrate.
- The vibrations of the footplate of stapes produces vibrations in the perilymph of the scala vestibuli (here sound waves are converted into fluid waves).
- The vibrations of the perilymph cause simultaneous vibrations of the vestibular membrane and the endolymph in the cochlear duct which causes basilar membrane to vibrate.
- As the basilar membrane vibrates the hair cells of the organ of Corti attached to it move. Consequently the stereocilia of hair cells embedded in the tectorial membrane become bent.
- Bending of the stereocilia causes depolarization of the hair cells.
- The hair cells induce action potentials in the neurons of cochlear nerve.
- The action potential generated in the cochlear nerve neurons is conducted to the cerebral cortex via auditory pathway, where it is interpreted and perceived as sound.

Auditory Neural Pathways (fig. 18.12)

The cell bodies of *first order sensory neurons* of the auditory pathways lie in the **spiral (cochlear) ganglion** which is located within the cochlear modiolus. These neurons are bipolar. Their peripheral processes reach the **organ of Corti** which is the end organ (receptor organ) for hearing, while the central processes constitute the cochlear nerve, which enters the brainstem at the junction of medulla and pons. The fibres bifurcate, one branch ending in the **dorsal cochlear nucleus** and the other in the **ventral cochlear nucleus**.

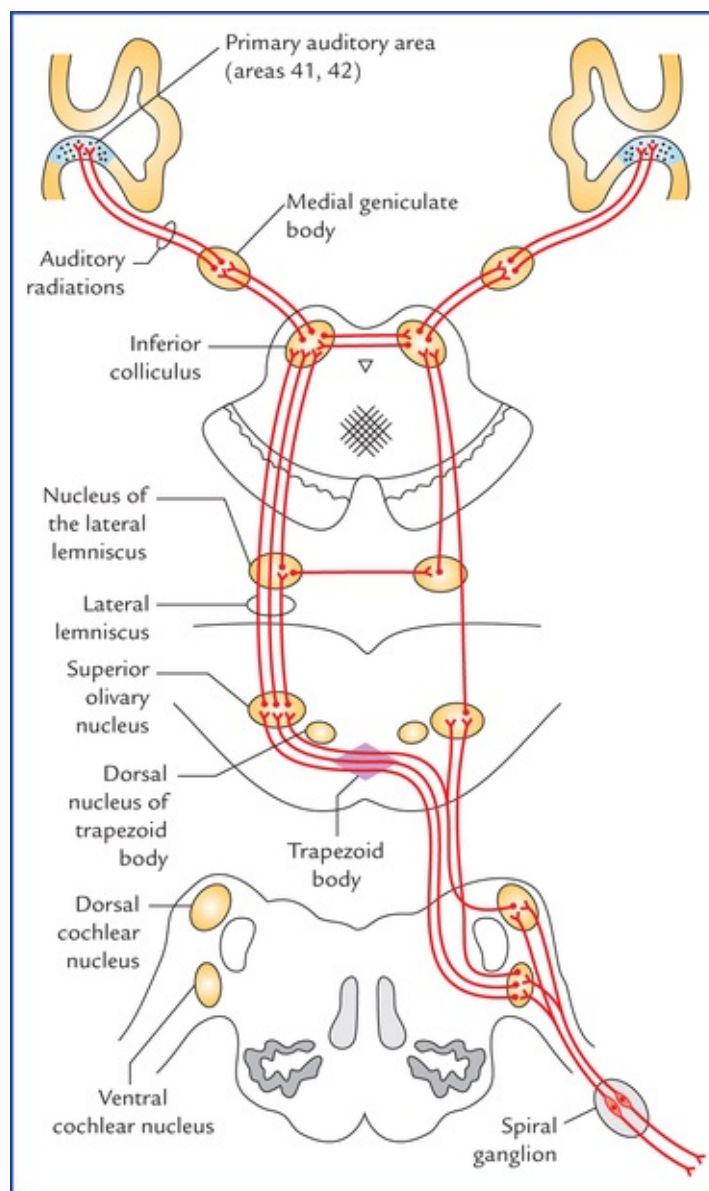


FIG. 18.12 The auditory pathways. The connections are not shown with dorsal nucleus of trapezoid body for the sake of clarity of diagram.

The *second order sensory neurons* arise from the cells of cochlear nuclei, and end in the **dorsal nucleus of corpus trapezoideum** and **superior olivary nucleus** of the same side as well as of the opposite side.

The *third order sensory neurons* arise from the dorsal nucleus of the trapezoid body and superior olivary nucleus of both sides and ascend as the lateral lemnisci. The **lateral lemniscus is the principal ascending auditory tract**. It ascends from the region of superior olivary nucleus, through the lateral part of pontine tegmentum and close to the surface of brainstem. A few of its fibres relay in the nucleus of **inferior colliculus (centre for auditory reflexes)** for reflex activity, which sends new sets of axons to the **medial geniculate body** through the brachium of inferior colliculus. However, most of the fibres of lateral lemniscus pass directly to the medial geniculate body without being relayed in the inferior colliculus. *The medial geniculate bodies are the final relay stations of the hearing pathway*. The fibres arising from medial geniculate bodies (*fourth order sensory neurons*) form the **auditory radiations** which run through the sublenticular part of the internal capsule to project into the **anterior transverse temporal gyrus (or Heschl's gyrus)** located on the upper surface of superior temporal gyrus partly buried in the lateral sulcus. The Heschl's gyrus contains **primary auditory cortex** (areas 41 and 42 of Brodmann).

N.B. There is a bilateral cortical representation from each organ of Corti provided by distribution of

fibres of cochlear nuclei, to the lateral lemnisci of both sides and also interneurons establishing cross-connections between nuclei of lateral lemnisci and between the inferior colliculi.

Points to note

- The **trapezoid body** is a conspicuous mass of fibres in the midline of the tegmentum of pons formed, as a result from decussation of efferent fibres of the cochlear nuclei of two sides. It presents a shape of trapezium in cross-section, hence the name trapezoid body. It has some scattered small nuclear masses within its ventral fibres and a large **dorsal nucleus** which lies lateral to the trapezoid body. The **superior olivary nucleus** lies lateral to the dorsal trapezoid nucleus.
- The **nucleus of lateral lemniscus** is a small aggregation of nerve cells among the fibres of lateral lemniscus. They receive bilateral afferent connections from both cochlear nuclei and their efferent join the lateral lemniscus.

Clinical Correlation

Each ear is represented bilaterally in the auditory pathway from the medulla upwards and projects about equally into the two cerebral hemispheres. Consequently the unilateral lesions of auditory cortex produce only a slight effect on the auditory acuity (i.e. sharpness of hearing) which is difficult to detect by audiometry testing.

Vestibular System

The vestibular pathways transmit impulses from vestibular receptors in the internal ear to the vestibular nuclei in the brainstem, which in turn project to widespread area of the central nervous system. It is responsible for maintenance of body-balance.

Vestibular Receptors

The organs of balance can be divided structurally and functionally into two parts: (a) the **static labyrinth** consisting of utricle and saccule of the vestibule, and (b) the **kinetic labyrinth** consisting of three semicircular ducts. The *static labyrinth* detects the position of head with respect to gravity, although it also responds to linear acceleration or deceleration, viz. a car that slows down or speeds. The *kinetic labyrinth* is involved in evaluating the movements of the head and has a special role in coordination of eye movements with movements of the head.

The *receptors for static balance are maculae* in the wall of utricle and saccule. The macula is a specialized patch of epithelium in the wall of utricle and saccule (Fig. 18.13). It consists of columnar supporting cells and hair cells. The hair of these cells which consists of numerous microvilli, called stereocilia, and cilium (kinocilium) that arises from centriole, are embedded into a gelatinous mass containing irregularly shaped concretions (otoliths) composed of protein and calcium carbonate. The gelatinous mass moves in response to gravity, bending the hair cells and initiating the action potentials in the associated neurons (Fig. 18.14).

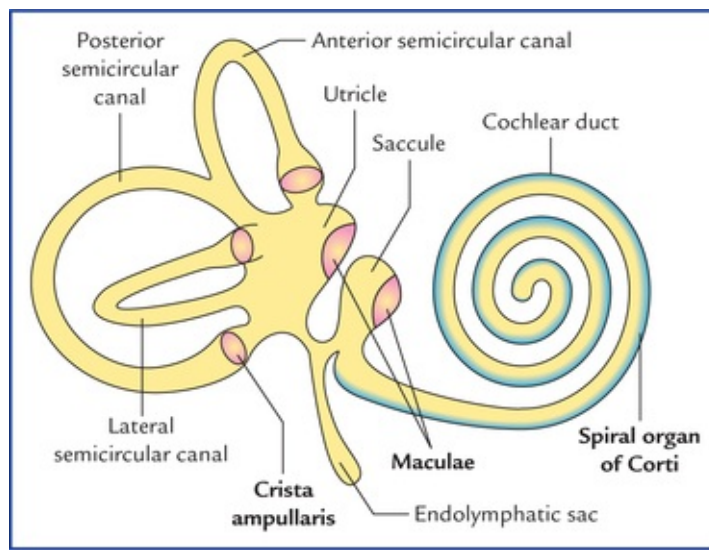


FIG. 18.13 Anterolateral view of right membranous labyrinth showing location of receptors for static balance (maculae in the wall of utricle and saccule) and kinetic balance (cristae ampullaris in the ampullae of semicircular canals).

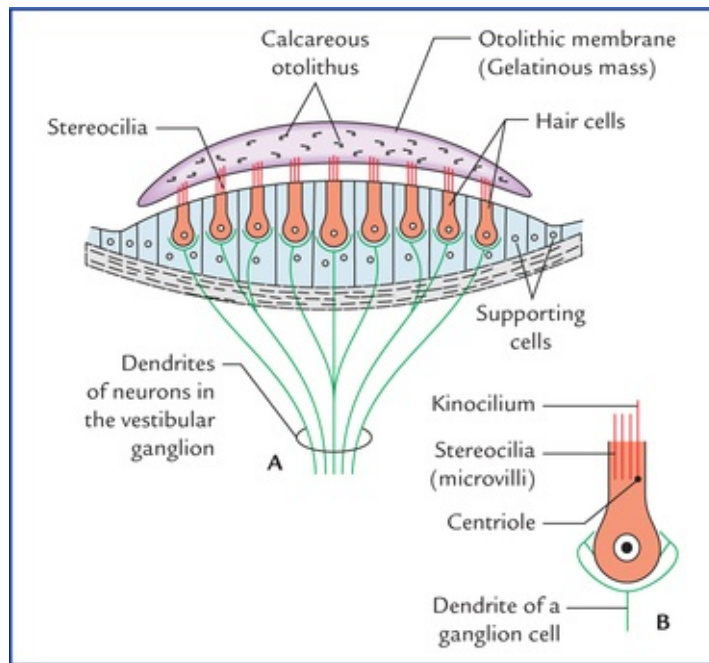


FIG. 18.14 (A) Structure of the macula. (B) An enlarged hair cell showing kinocilium.

The base of each semicircular canal is expanded into an ampulla. Within each ampulla the epithelium is specialized to form **crista ampullaris**, the receptor for kinetic balance (Fig. 18.15). It is structurally and functionally very similar to that of macula. Each crista consists of a ridge or crest of epithelium with curved gelatinous mass, the **cupula** suspended over the crest.

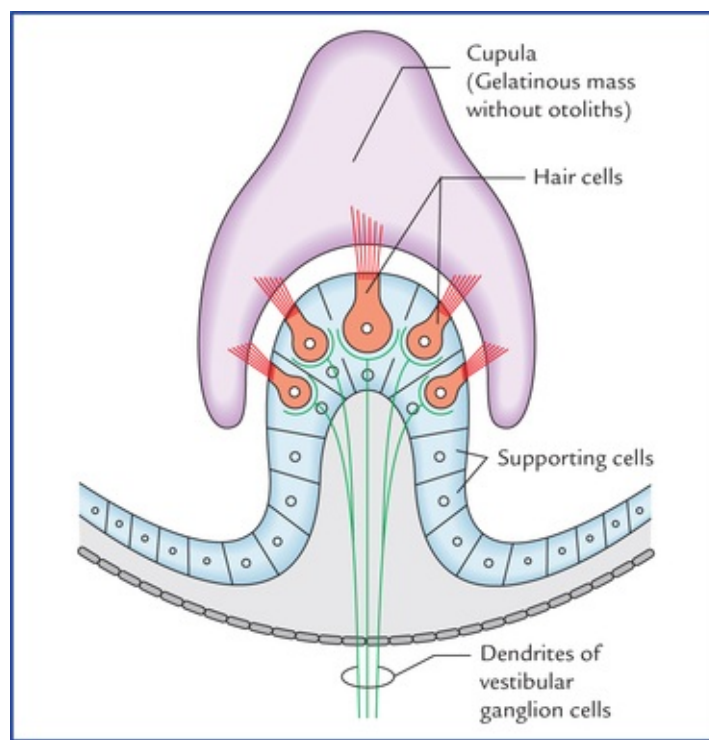


FIG. 18.15 Structure of crista ampullaris.

The hair-like processes of the crista hair cells, similar to those in the maculae are embedded in a gelatinous mass that forms cupula. The cupula does not contain otoliths and therefore cannot respond to the gravitational pull. Instead, the cupula is like a float that is displaced by fluid movements within the semicircular canals. The endolymph movement within each semicircular canal moves the cupula, bends the hairs and initiates the action potentials in the associated neurons of vestibular nerve (Fig. 18.15).

The three semicircular ducts of kinetic labyrinth are placed nearly at right angles to each other, one lying nearly in the transverse plane, one in the coronal plane, and one in the sagittal plane. The arrangement of semicircular canals enables a person to detect movement in any direction.

Neural Pathways for Balance (Figs 18.16 and 18.17)

The cell bodies of **first order (bipolar) sensory neurons** form the vestibular ganglion located at the bottom (fundus) of the internal auditory meatus. The peripheral processes of these cells end on the hair cells of the maculae of the utricle and saccule; and on the hair cells of the cristae of semicircular ducts of the internal ear. The central processes of the bipolar cells of the vestibular ganglion form the vestibular nerve which run in the internal auditory meatus, enters the cranial cavity and traverse the subarachnoid space at cerebellopontine angle to enter the pontomedullary junction superomedial to the cochlear nerve. These fibres relay in the vestibular nuclei (for details see Chapter 8) and flocculonodular lobe of the cerebellum.

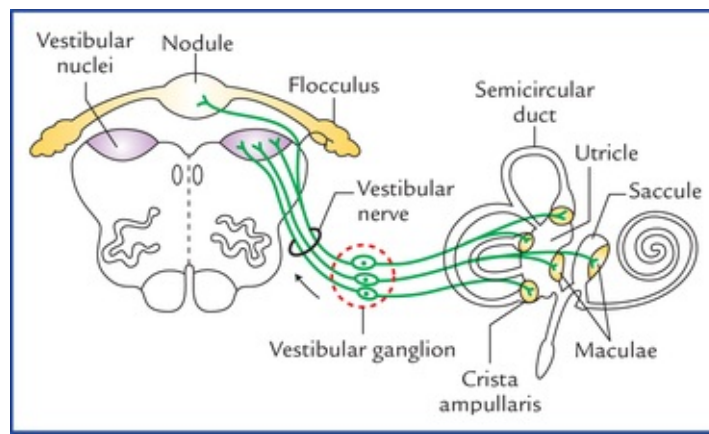


FIG. 18.16 Neural pathways for balance-peripheral connections.

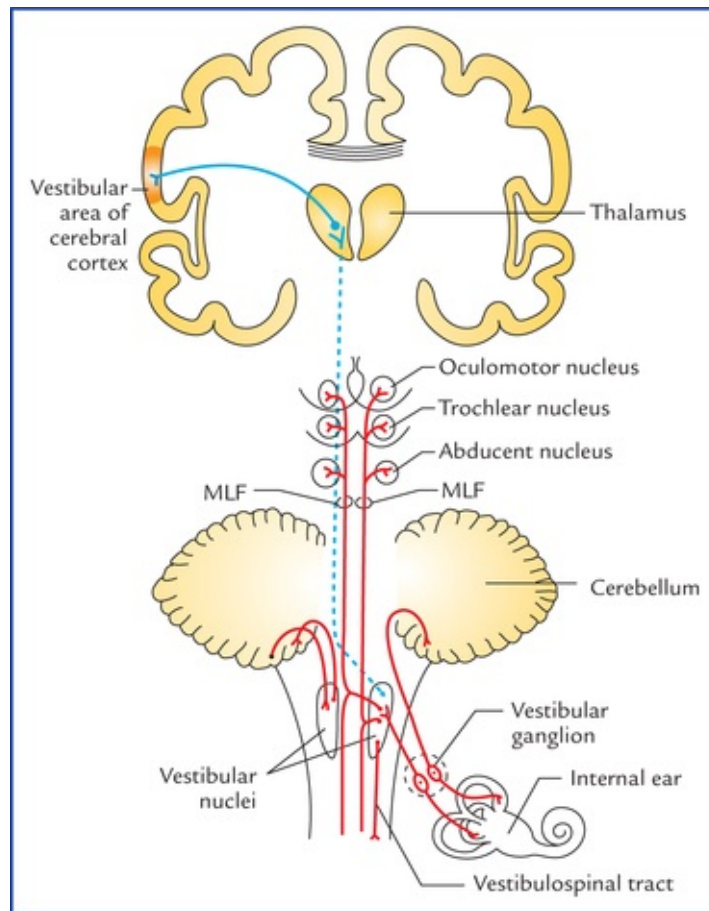


FIG. 18.17 Neural pathways for balance-central connections. (MLF = Medial longitudinal fasciculus).

The **second order sensory neurons** of vestibular nuclei project: (a) to the flocculonodular lobe of the cerebellum (archicerebellum) through inferior cerebellar peduncle (vestibulocerebellar tract), (b) to the motor nuclei of IIIrd, IVth and VIth cranial nerves through medial longitudinal fasciculus (MLF), and (c) to the anterior horn cells of the spinal cord (vestibulospinal tract). The vestibular nuclei also project to the posteroventral nucleus of the thalamus.

The **third order sensory neurons** from thalamus project to the vestibular area of the cerebral cortex in the postcentral gyrus.

The vestibular connections contribute to the coordination of muscle contraction in maintenance of upright posture.

Through connections of the medial longitudinal fasciculus of the same and opposite side, the vestibular system controls some vestibuloocular and postural reflexes, e.g. conjugate eye movements and movements of the neck and trunk in response to vestibular stimulation.

The vestibulothalamocortical connections give a sense of balance and their dysfunction has been associated with the symptoms of **motion sickness**. The motion sickness presents as nausea, vomiting, weakness and incapacitation caused by the stimulation of semicircular canals during motion such as in swing or amusement park ride.

Clinical Correlation

The **balance** of the body is a complex process, dependent on inputs to the vestibular nuclei from vestibular receptors in the internal ear, proprioceptive receptors of the whole body and visual receptors in the eye. The derangement of any of the above components may give rise to clinical manifestations of trunkal ataxia and staggering gait, **nystagmus** (see [Chapter 8](#)), and vertigo.

N.B. The **vertigo** is a feeling of the rotation, either of the patient himself or his environment.

Taste

The taste pathways transmit sense of taste from taste buds located in the mucous membrane of tongue, epiglottis, soft palate and pharynx to the sensory cortex of the brain.

Taste Buds (Fig. 18.18)

The taste buds are the **organs of taste**. There are about 10,000 taste buds in human. Taste buds are oval (egg-shaped) clusters of cells in the epithelial lining of the tongue, palate and pharynx. The cells within the taste buds are of two types: (a) **gustatory cells or receptor cells**, and (b) **supporting or sustentacular cells**.

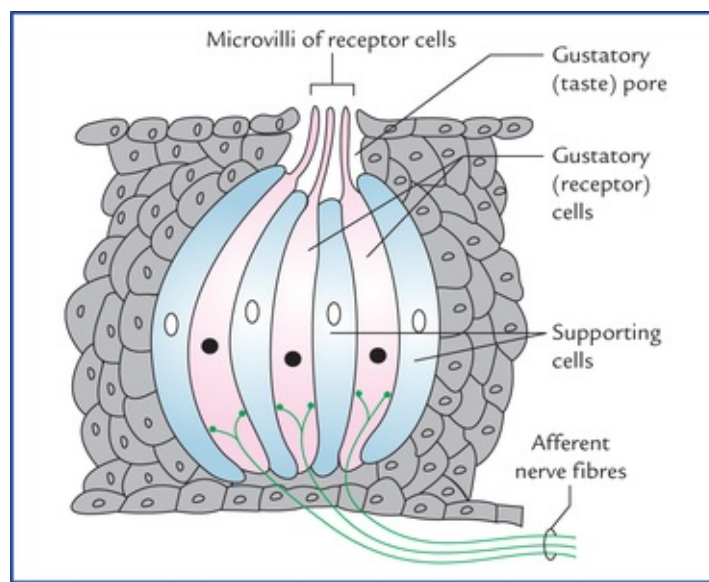


FIG. 18.18 Structure of a taste bud (taste receptor). The gustatory (taste receptor) cells contain synaptic vesicles and are innervated by afferent nerve fibres. The supporting cells are not innervated.

The gustatory cells present microvilli, which project on to the surface through the gustatory pores and are exposed to the fluid in the oral cavity.

The taste producing substances first get dissolved in the oral fluid and then bind with the receptors located on the microvilli of the gustatory cells. The microvilli react by depolarizing the gustatory cells, which lead to the generation of action potentials in the afferent nerve endings.

Neural Pathways for Taste (Fig. 18.19)

The cell bodies of **first order sensory neurons** carrying taste sensations from taste buds are located in the geniculate ganglion, superior petrosal ganglion and inferior ganglion (ganglion nodosum), of facial, glossopharyngeal and vagus nerves respectively.

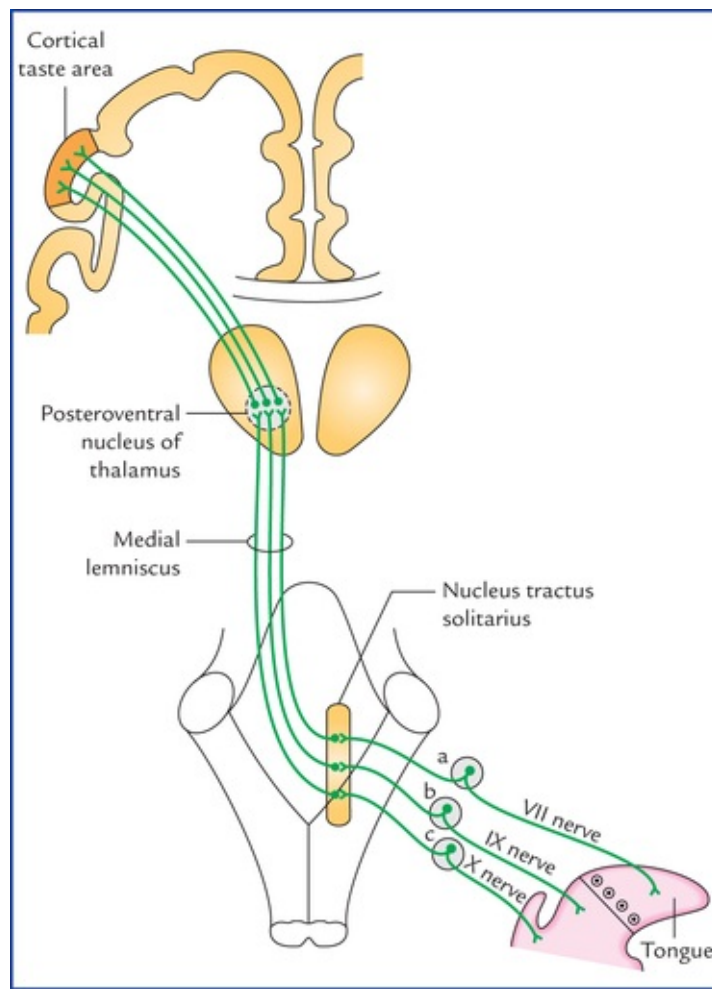


FIG. 18.19 Taste pathways: a = geniculate ganglion of facial nerve, b = superior ganglion of glossopharyngeal nerve, c = inferior ganglion (ganglion nodosum) of vagus nerve. The taste area is located in the inferior part of the postcentral gyrus (primary sensory cortex). According to Barr and Kiemann the taste (gustatory) area is located in the inferior part of the parietal lobe, posterior to the general sensory area for the mouth in the post-central gyrus.

- Taste fibres from anterior two-third of the tongue excluding vallate papillae run in the facial nerve (from tongue successively through lingual, chorda tympani and facial nerves).
- The taste fibres from posterior one-third of the tongue including vallate papillae travel along the glossopharyngeal nerve.
- Taste fibres from posterior most part of tongue, epiglottis and pharynx travel along the vagus nerve (successively through its internal laryngeal, and superior laryngeal branches).

The peripheral processes of these cells connect with the taste buds, while central processes end in the **nucleus tractus solitarius (NTS)**.

The **second order sensory neurons** arise from nucleus tractus solitarius, cross the midline, turn upwards to join the medial lemniscus and terminate in the posteroventral nucleus of the thalamus.

The **third order sensory neurons** arise from posteroventral nucleus of thalamus and project in the inferior part of the postcentral gyrus of the parietal lobe of the brain, the **taste area of the cerebral cortex**.

N.B. All the afferents from tongue, carrying both taste and general sensibility (pain, touch and temperature), travel along the same pathway to the thalamus and sensory cortex.

Clinical Correlation

- There are **four primary taste sensations**, viz. bitter, sour, sweet, and salt. The primary tastes are sensed better in certain areas. The bitter is sensed at the back of the tongue, sour at the sides, the sweet at the tip and the salt on the dorsum.
- The thresholds vary for the four primary tastes. Sensitivity for bitter substances is the highest; sensitivities for sweet and salty tastes are the lowest. Sugars, some carbohydrates, and some proteins produce sweet tastes; acids produce sour tastes; metal ions tend to produce salty tastes; and alkaloids (bases) produce bitter tastes. Many alkaloids are poisonous, thus the high sensitivity for bitter tastes may be protective.
- Electrical stimulation of postcentral gyrus produces hallucinations of taste and its destruction abolishes the taste and tactile sensibility of the tongue.

Clinical Problems

1. Explain the cause of blood-stained watery discharge from the nostril and loss of smell in fracture of anterior cranial fossa.
2. The complete injury of optic nerve leads to permanent blindness. Mention the anatomical basis.
3. The increased intracranial pressure often produces bilateral papilloedema (Swelling of optic discs). Explain.
4. Explain how a pituitary tumour produces a bitemporal loss of vision ('*tunnel vision*').
5. When light is shown to one eye, the pupils of both the eyes constrict. Why?
6. Mention the anatomical basis of **Argyll Robertson pupil** in neurosyphilis.
7. Explain why a sudden brief and extremely loud sound such as due to bomb explosion can result in deafness?

Clinical Problem Solving

1. The blood-stained watery discharge through the nostril occurs due to haemorrhage and leakage of cerebrospinal fluid following fracture of cribriform plate of the ethmoid bone. The loss of smell (*anosmia*) occurs due to lesion of the olfactory nerves, bulbs and tracts.
2. This is because the optic nerve cannot regenerate as it is not a true peripheral nerve. Remember the optic nerve and retina are extensions of the brain, and the nerve itself represents the white matter. Its fibres do not possess neurilemmal sheath and the oligodendrocytes existing as its glial cells form the myelin sheath around the nerve fibres. Due to absence of neurilemmal sheath the optic nerve is incapable of regeneration after the injury.
3. This is because the increased intracranial pressure is transmitted to the subarachnoid space around the optic nerve on both the sides. As a result the venous return through the central vein of the retina, which traverses this space is impeded.
4. The pituitary gland is located in the pituitary fossa (sella turcica) and related superiorly

to the optic chiasma. The loss of vision in both temporal fields (i.e. bitemporal hemianopia) occurs due to the suprasellar extension of pituitary tumour affecting nasal fibres from the both retinae.

5. This is due to direct and indirect consensual light reflexes (see [page 217](#)).
6. The neurosyphilis produces lesions in or near the aqueduct of Sylvius involving superior colliculi which interrupts the pathway of light reflex only. In '**Argyll Robertson pupil**' the pupil does not react to light (loss of light reflex) but does react to accommodation (no loss of accommodation reflex) because pathways for light and accommodation reflexes are different (see pages 217 and 218).
7. Due to excessive displacement of hair cells of the organ of Corti (the auditory receptors).

Reticular Formation and Limbic System

Reticular Formation

The reticular formation is defined as diffuse ill-defined mass of intermingled neurons and nerve fibres occupying the entire core of brainstem (Fig. 19.1). The reticular formation has derived its name from its light microscopic appearance of a vague network of nerve cells and nerve fibres. It has been defined to include all areas within the brainstem (except the named nuclei and tracts) which when stimulated will produce **arousal**.

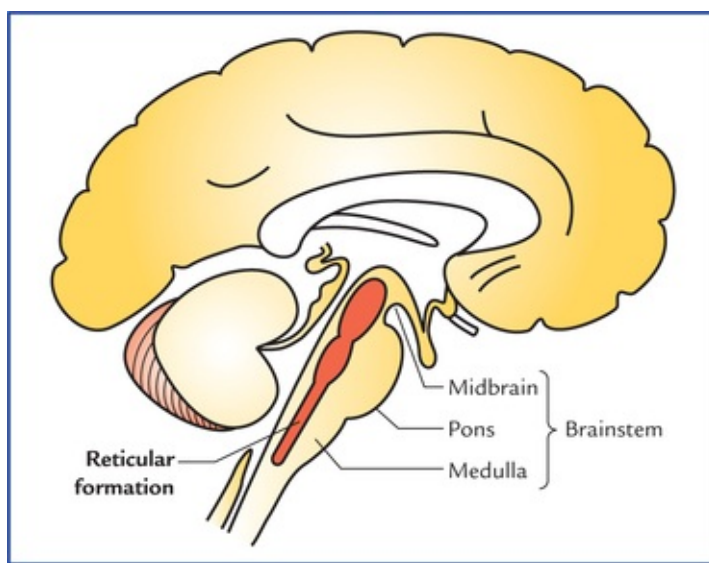


FIG. 19.1 Location of reticular formation in the brainstem.

Phylogenetically it represents the old reticular core of brain and contains within it the vital cardiac and respiratory centres which control respiration, heart rate and blood pressure. In primitive vertebrates, the diffuse arrangement of neurons was named 'reticular'.

The reticular formation receives data from most of the sensory systems and has efferent (direct or indirect) connections with all the levels of neuraxis.

The knowledge of reticular system is important, because:

- it regulates levels of consciousness, and alertness,
- it regulates respiration, blood pressure, heart rate and other vegetative functions,
- it regulates tone of skeletal muscles, and
- it modulates the impulses in the pain pathways.

Clinical Correlation

Damage of the reticular activating system in the core of the brainstem leads to progressive

loss of consciousness, followed by stupor, coma and death.

Anatomical Extension

The reticular formation extends cranially to the diencephalon (subthalamus, hypothalamus and thalamus) and caudally to the spinal cord in the cervical region. These extensions are either actual or projectional. According to some authorities some centres of cerebrum and cerebellum are also closely related functionally to the reticular formation of brainstem.

Although reticular formation is described to be consisting of network of nerve fibres and scattered neurons, among them a number of regions with fairly localized cell groups called **reticular nuclei**, have been recognised.

Reticular nuclei in the brainstem

The reticular nuclei in brainstem are arranged into three longitudinal columns (Fig. 19.2).

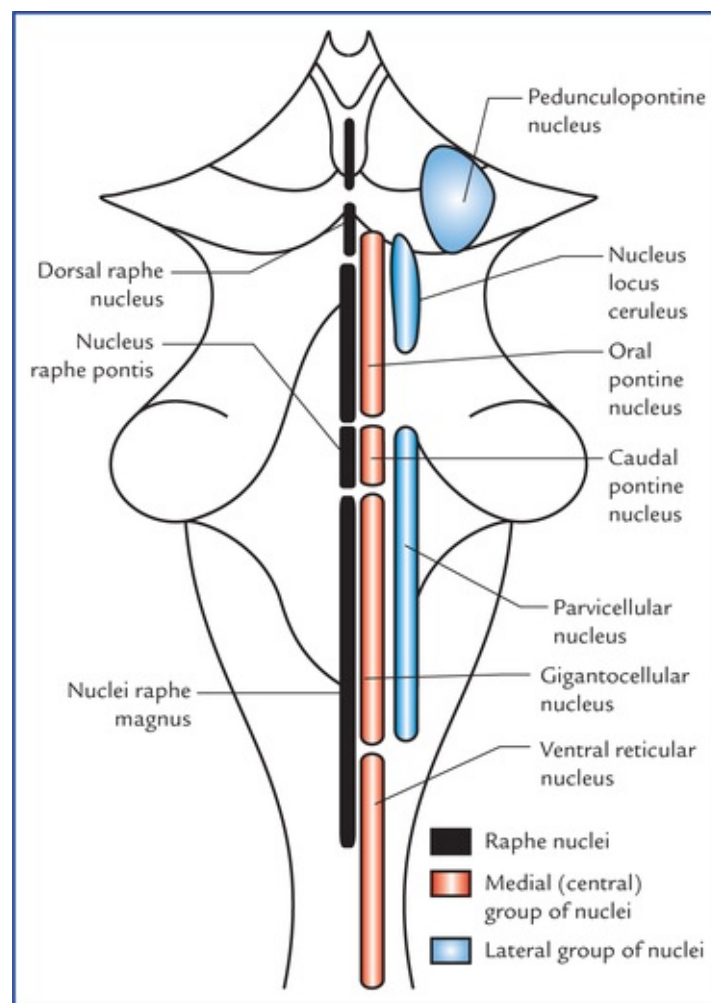


FIG. 19.2 Schematic diagram to show the reticular nuclei in the brainstem.

- *Median column* lies in the midline and consists of intermediate size neurons. The nuclei of this column are termed **raphe nuclei**.
- *Medial column* consists of nuclei which are made up large-size neurons, hence this column is also

termed **magnocellular column**.

- *Lateral column* consists of nuclei which are made up of small neurons, hence this column is also termed **parvo-cellular column** (parvus = little, small).

The nuclei belonging to these columns are shown in [Figure 19.2](#). Since it is not advisable for the student to burden his memory with the names of all the nuclei, only those which have a functional or descriptive value are labelled.

The reticular nuclei as seen in transverse sections of the midbrain, pons and medulla are shown in [Figure 19.3](#).

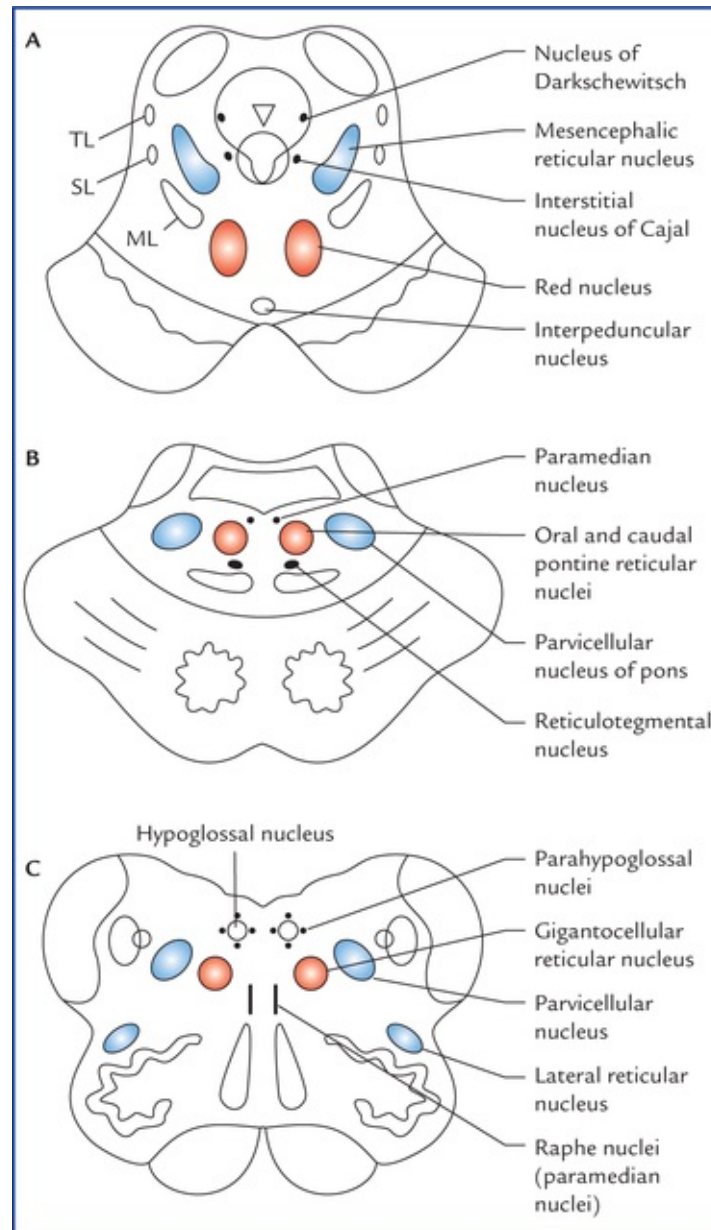


FIG. 19.3 The transverse sections of: midbrain (A), pons (B), and medulla (C) showing the location of reticular nuclei. (ML = medial lemniscus, SL = spinal lemniscus, TL = trigeminal lemniscus.)

Raphe nuclei (median group of nuclei)

The raphe nuclei form a contiguous column in the mid-line. The neurons of raphe nuclei produce **serotonin**, a substance that they use as a neurotransmitter. The *dorsal raphe nucleus* located in the midbrain projects to the spinal cord and forms the **pain controlling pathway**.

The *nucleus raphe magnus* in medulla projects to the caudal part of the spinal nucleus of the trigeminal nerve and influences perception of pain through spinal nucleus.

In fact once the raphe nuclei (vide supra) are activated, the serotonergic neurons inhibit the transmission of pain impulses from dorsal grey horns and spinal nucleus of trigeminal nerve respectively.

Clinical Correlation

The electrical stimulation of either the **dorsal raphe nucleus** (the periaqueductal grey matter) or the **nucleus raphe magnus** results in loss of the ability to experience pain from sites of injury or disease. The former procedure has been used clinically in the management of otherwise intractable pain.

Medial group of nuclei

The medial group of nuclei includes ventral reticular nucleus (in medulla), gigantocellular nucleus (in medulla and pons) and oral and caudal pontine nuclei (in pons). Nuclei of this group receive afferents from nuclei of lateral group and efferents from these nuclei ascend or descend longitudinally in the brainstem and give collaterals to the other reticular cells, thus forming a **polysynaptic pathway**—a characteristic of impulse transmission through the reticular formation.

Lateral group of nuclei

The lateral group of nuclei includes parvicellular nuclei of medulla and pons, nucleus locus ceruleus of pons and pedunculopontine nucleus of the midbrain.

These nuclei receive collaterals from several ascending pathways and project to the medial group of nuclei of the reticular formation. They are regarded as an association region of the reticular formation.

Connections of Reticular Formation

The reticular formation receives information from almost all the principal parts of the nervous system and in turn, projects (directly or indirectly) to all these parts (Fig. 19.4).

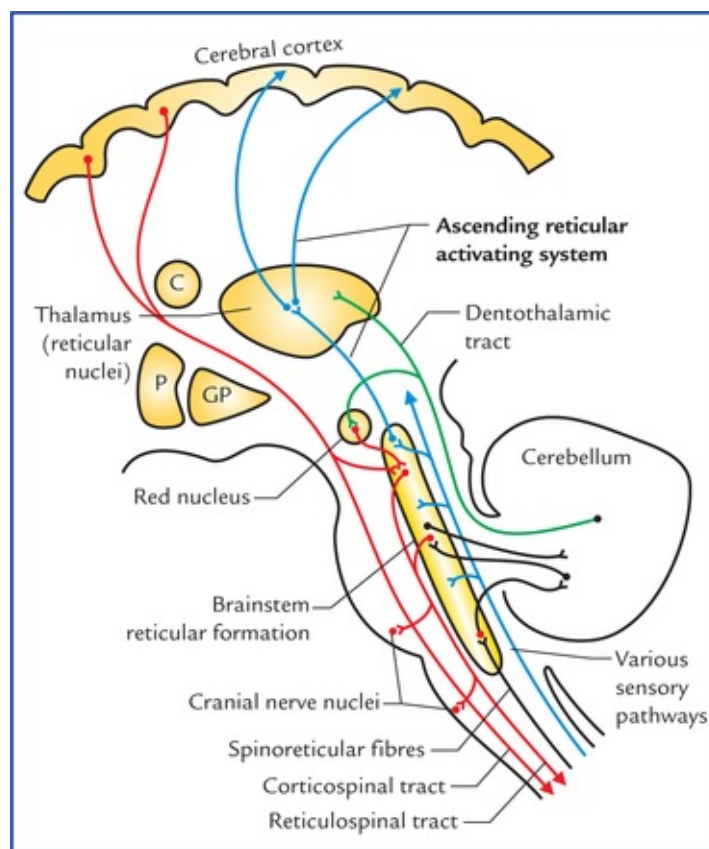


FIG. 19.4 Connections of reticular formation. (P = putamen, and GP = globus pallidus.)

The reticular pathways are polysynaptic, both ascending, descending, and crossed and uncrossed. As a result a unilateral stimulation produces bilateral responses.

Afferent connections

The afferents are classified into three types:

Afferents from various sensory pathways or systems

- *Optic system*—through tectoreticular fibres,
- *Olfactory and limbic systems*—through variety of descending pathways,
- *Auditory system*—through tectoreticular fibres,
- *Gustatory system*,
- *Spinal pathways*—through spinoreticular fibres. A considerable number of fibres of spinothalamic tract terminate in the lateral reticular nucleus of medulla, which in turn project to the cerebellum. Spinoreticulo-cerebellar pathway is an important pathway for carrying exteroceptive sensations to the cerebellum,
- *Trigeminal pathways*.

Afferent fibres from other parts of central nervous system

- *Cerebellum* from both but mainly from contralateral fastigial nucleus.
- *Basal ganglia*, mainly from corpus striatum.
- *Thalamus, hypothalamus and subthalamus*.
- *Limbic system*, mainly from septal areas, amygdaloid nuclei, and hippocampus.
- *Cerebral cortex* mainly from motor and sensory areas of the cerebral cortex.
- *Red nucleus, substantia nigra and habenular nuclei*.

Other factors influencing the activity of reticular formation

- *Hormones and chemical substances*, viz. adrenaline, ace-tylcholine and carbon dioxide.
- *Drugs*, viz. barbiturates, anaesthetics and tranquillizers.

Efferent connections

The efferent connections of reticular formation are to all the parts of CNS from which it receives afferents but mainly to:

- Autonomic and locomotor control centres of brainstem and spinal cord.
- Cranial nerve nuclei, e.g. dorsal nucleus of vagus.
- Cerebral cortex—indirectly through diencephalic nuclei.
- Red nucleus, substantia nigra and tectum of midbrain.

Functional Divisions of Reticular Formation

Functionally the reticular formation is divided into two systems: (a) the ascending reticular activating system (ARAS), and (b) the descending reticular system (DRS). The ascending reticular activating system is commonly termed by the clinicians simply as reticular activating system (RAS).

Ascending reticular activating system (Fig. 19.4)

Most of the ascending tracts, viz. spinothalamic tract, trigeminal lemniscus, lateral lemniscus and central vestibular pathway, while passing through the brainstem give collaterals to the *lateral part of the reticular formation* which projects to the *intralaminar and reticular nuclei of the thalamus*. These nuclei in turn project to the widespread areas of the cerebral cortex.

When this part of reticular formation is stimulated, the individual becomes alert hence it is termed ascending reticular activating system.

The ascending reticular activating system is believed to be responsible for maintaining a state of alertness and consciousness.

Clinical Correlation

- The visual and acoustic stimuli can stimulate the reticular activating system to maintain alertness and attention, therefore the stimuli such as sounds of ringing alarm clock or sudden bright light, can arouse consciousness. Conversely, removal of visual and auditory stimuli may lead to drowsiness and sleep.
- The functions of reticular activating system (RAS) can be affected by certain drugs. For example, general anaesthetics and tranquillizers cause its suppression. On the other hand, ammonia and other irritants stimulate it.
- A **coma** is a state of unconsciousness (due to inactivity of RAS). In coma, even the most powerful external stimuli cannot cause arousal.

The *sleep* is thought to occur because of a decrease in activity within the RAS.

N.B. The nuclei within the reticular formation, generate a continuous flow of impulses unless they are inhibited by other parts of the brain or drugs.

Descending reticular system

Descending reticular system consists of descending pathways from reticular formation to the autonomic centres in the brainstem and, the lateral and anterior horn cells in the spinal cord (see reticulospinal tracts in Chapter 7).

Clinical Correlation

The descending fibres from reticular formation constitute one of the most important motor pathways. The fibres from reticular formation to autonomic centres in the brainstem are critical in controlling respiratory and cardiac rhythms and other vital functions.

Functions of Reticular Formation

- Maintains the normal state of consciousness or wakefulness through its connections with cerebral cortex by way of *ascending reticular activating system*.
- Regulates respiration, heart rate blood pressure and other vegetative functions through autonomic reflex centres present within it in the brainstem.
- Controls muscular activity, directly through reticulospinal projections to lower motor neurons and indirectly by influencing the activities of cerebellum, red nucleus, substantia nigra, corpus striatum, and cerebral cortex.
- Controls receptivity of sensory end organs.
- Controls threshold of central sensory pathways.
- Regulates endocrine, visceral and emotional functions, through its connections with hypothalamus and limbic lobe.

Therefore, reticular formation constitutes the one, if not the most important regulatory mechanisms within the CNS.

Limbic System

The word *limbus* means *ring*, the term **limbic system** is applied to the parts of the cortical and subcortical structures that form a ring around the upper end of the brainstem.

The limbic system was formerly called **rhinencephalon** because of its association to olfaction, but in human beings only a small part of it is actually concerned with smell.

The limbic cortex is phylogenetically oldest part of the cerebral cortex and made up of primitive type of cortical tissue called **allocortex** which consists of only three layers and surrounds the hilum of the cerebral hemisphere. There is second ring of transitional cortex called **juxta-allocortex** between the allocortex and the neocortex. It consists of three to six layers. The cortical tissue of remaining non-limbic portion of the hemisphere is called **neocortex** which is made up of six layers and most highly developed in man.

The limbic system plays a vital role in elaboration of emotional behaviour, drive, and memory.

Functions of the Limbic System

The limbic system is functionally associated with following neural activities:

- **Emotional aspects of behaviour** together with **visceral responses accompanying these emotions**, particularly the reactions of fear and anger and emotions associated with sexual behaviour which are necessary for:
 - survival of an individual including procuring of food and eating behaviour, and
 - survival of the species including the sex behaviour.
- **Brain mechanisms responsible for recent memory.**
- **Integration of olfactory, visceral and somatic impulses reaching the brain.**

N.B. The visceral responses following activities in limbic system are expressed through hypothalamus by way of autonomic nervous system. Because of visceral responses to activities in the limbic system, it is also known as **visceral brain**.

Components of the Limbic System

The structures forming the limbic system are interposed between the superolateral surfaces of the diencephalon and the inferomedial surfaces of the two cerebral hemispheres. Many of these structures have highly arched forms.

A large number of structures of the brain are included in the limbic system. However, a fairly accepted list of these structures is presented here.

Regions of grey matter in limbic system

Cortical structures

- **Limbic lobe**, consisting of cingulate gyrus, isthmus, parahippocampal gyrus and uncus (anterior part of the parahippocampal gyrus) (Fig. 19.5).

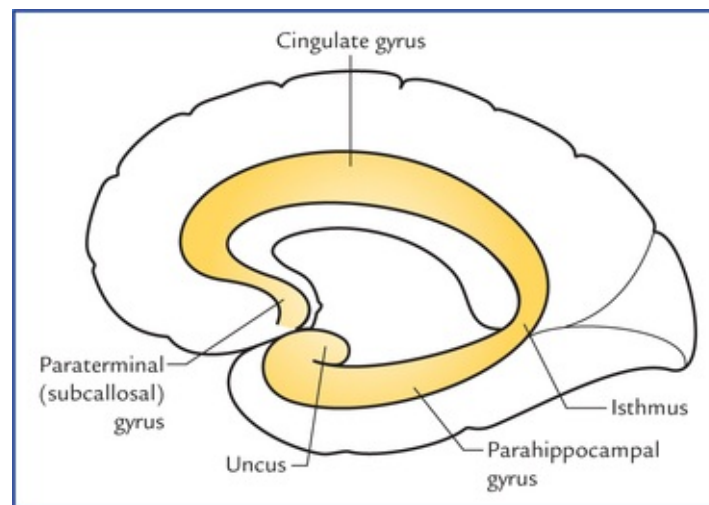


FIG. 19.5 Limbic lobe consisting of cingulate gyrus, isthmus, parahippocampal gyrus, and uncus.

- **Hippocampal formation** (Fig. 19.6) which includes hippocampus (cornu ammonis), dentate gyrus, gyrus fasciolaris and indusium griseum.

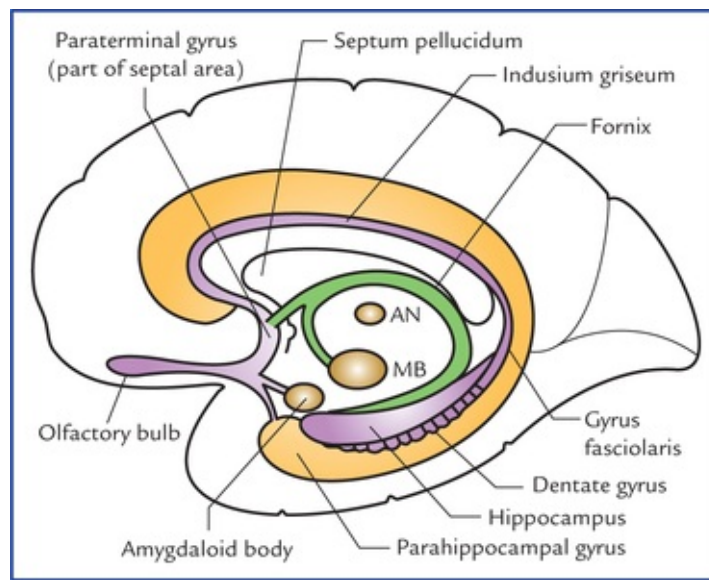


FIG. 19.6 Structures forming hippocampal formation (viz. hippocampus, dentate gyrus, gyrus fasciolaris and indusium griseum) and associated structures. (MB = mammillary body of hypothalamus, AN = anterior nucleus of thalamus.)

N.B. The cingulate gyrus is a ‘**satisfaction centre**’ of brain and associated with the feeling of satisfaction after a meal or after sexual intercourse.

Subcortical nuclei

- Amygdaloid nuclear complex (also called amygdaloid body).
- Septal region and nuclei.
- Olfactory areas (see [Chapter 18](#)).
- Hypothalamus especially the mammillary bodies.
- Anterior nucleus of thalamus.

Amygdaloid Nuclear Complex (Also Called Amygdaloid Body or Amygdala)

Amygdaloid nuclear complex is an almond-shaped mass of grey matter underlying the rostral part of the parahippocampal gyrus on the anteriormost part of the roof of the inferior horn of lateral ventricle.

Posteriorly the amygdaloid body becomes continuous with tail of caudate nucleus and stria terminalis ([Fig. 13.4](#)).

Connections ([Fig. 19.7](#))

Afferents: Main afferents to amygdaloid body are from primary olfactory regions.

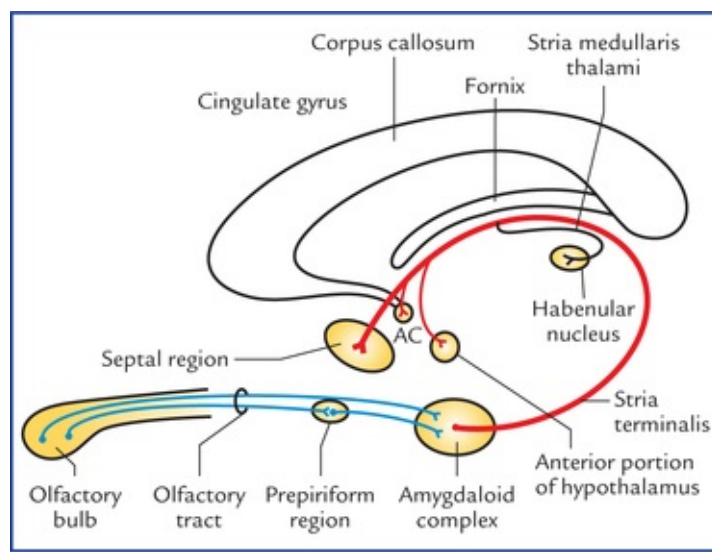


FIG. 19.7 Main afferent and efferent connections of the amygdaloid complex. Note the course of the stria terminalis. (AC = anterior commissure).

Efferents: Stria terminalis forms the main efferent tract of the amygdaloid body. It takes a circuitous route along with (but not functionally related to) the tail of caudate nucleus in close relation to the lateral ventricle until the level of anterior commissure, where majority of its fibres terminate in the septal area and anterior portion of the hypo-thalamus. The others join the anterior commissure and are distributed to the contralateral amygdaloid body. Some fibres run caudally to reach the habenular nucleus through **stria medullaris thalami**.

In general the amygdaloid body plays an important role in controlling the somatic responses to internal needs, drives or instincts. Since part of it receives olfactory input, it is believed that the amygdaloid body plays an important role in smell-mediated sexual behaviour.

Stimulation of amygdaloid body produces excitability, fear and rage. Bilateral damage of amygdaloid body reduces fear and increases sexual activity.

N.B. People in late sixties become pervasive in their sexual behaviour, probably due to atrophy of amygdaloid bodies.

Septal Region

The septal region is on the medial aspect of the frontal lobe beneath the genu and rostrum of corpus callosum and in front of the lamina terminalis. The septal region includes paraterminal and parolfactory gyri. The cerebral cortex in this region is called septal area.

The septal area has been shown to be a **pleasure zone** of brain in rats.

Hippocampal Formation

The hippocampal formation consists of: (a) hippocampus, (b) dentate gyrus, (c) subiculum, (d) indusium griseum, and (e) medial and lateral longitudinal striae.

Hippocampus (also called ram's horn or Ammon's horn)

Hippocampus is an area of cerebral cortex which has rolled into the floor of the inferior horn of the lateral ventricle during fetal life. In adult brain it forms a longitudinal elevation in the floor of inferior horn of the lateral ventricle and is continuous medially with the subiculum and para-hippocampal gyrus.

The name 'hippocampus' meaning 'sea horse', is derived from its appearance in coronal section (Fig. 19.8).

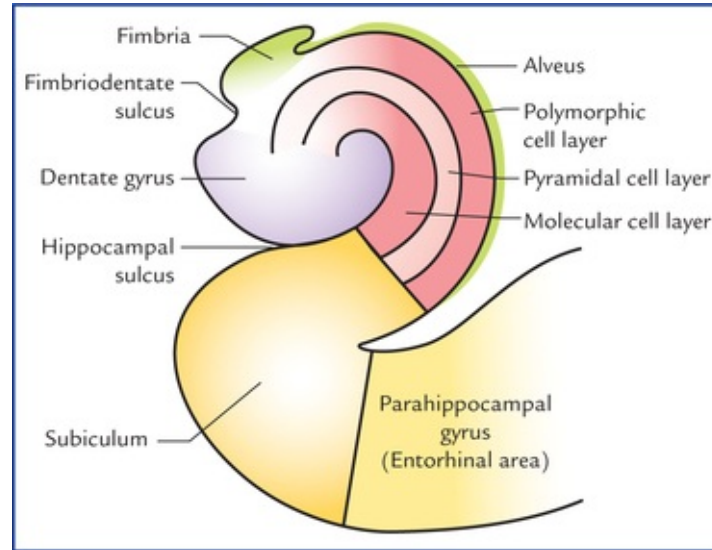


FIG. 19.8 Coronal section of the hippocampus and related structures.

In the frontal section the hippocampus is 'C-shaped' and its outline bears a resemblance to a ram's horn, hence the name **ram's horn**. It is also called **Ammon's horn** after an Egyptian deity with ram's head. Its anterior extremity is expanded and bears few grooves and intervening ridges. Because of its resemblance to an animal's paw it is termed **pes hippocampi** (pes = foot). Traced posteriorly the hippocampus gradually narrows and ultimately ends beneath the splenium of corpus callosum.

The ventricular surface of hippocampus is covered by a thin layer of white fibres called **alveus**. The fibres of alveus originate in the hippocampal cortex, course towards the medial border of hippocampus where they converge to form a narrow strip of white matter, the **fimbria of hippocampus**.

Phylogenetically, hippocampus represents the archicortex and consists of three layers. These are:

- Superficial molecular layer.
- Middle pyramidal cell layer.
- Deep polymorphic cell layer.

N.B. The parahippocampal cortex (neocortex) is made up of **six** layers. In the region known as **subiculum**, there is gradual transition from six-layered neocortex to the three-layered archicortex.

Connections (Fig. 19.9)

Afferents: Hippocampus receives fibres mainly from ento-rhinal area (area 28).

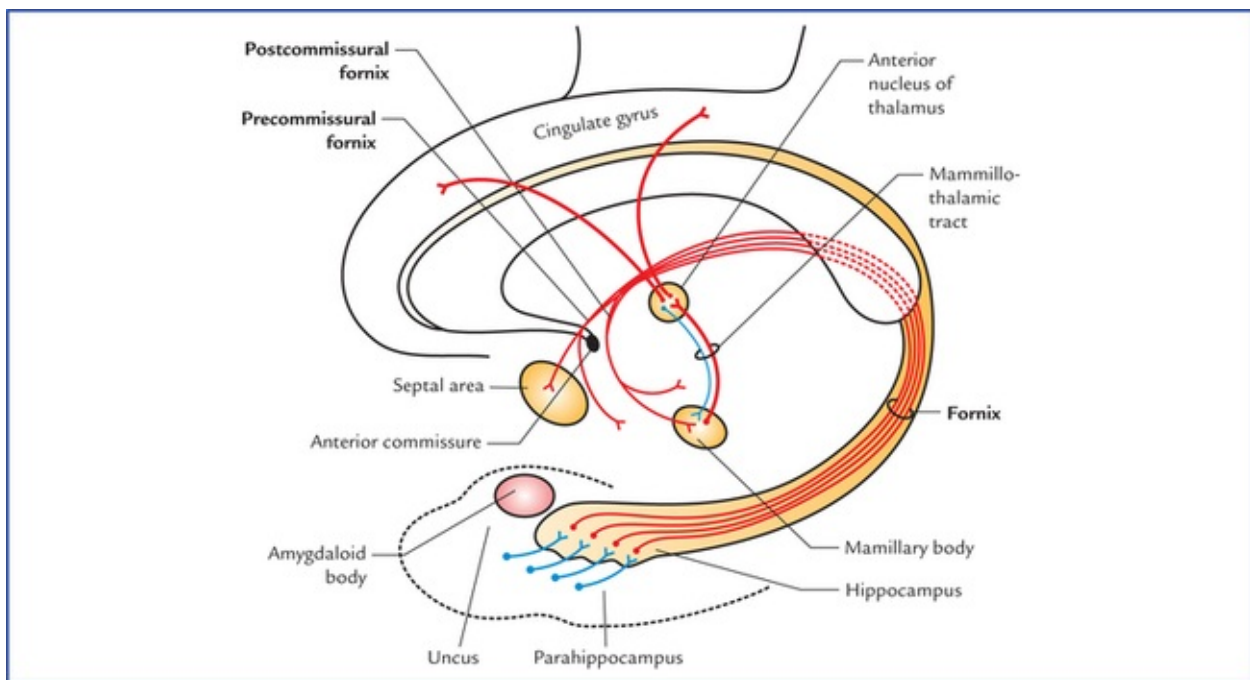


FIG. 19.9 Connections of hippocampus.

Efferents: The fornix is the main efferent tract of the hippocampus.

The fibres leaving the hippocampus pass:

- To the opposite hippocampus through the *commissure of fornix/hippocampal commissure*.
- To the septal and anterior hypothalamic regions.
- To the mammillary body which sends impulses to cingulate gyrus through anterior nucleus of thalamus.

Functions of hippocampus

- Formerly it was regarded as the part of olfactory system but it has no direct connections with the sense of smell in man.
- In man it is an integrative centre which influences endocrine and visceral functions and emotional states through its connections with hypothalamus, septal nuclei, and the cingulate gyrus. It was once considered as the **seat of soul**.
- It plays an important role in **recent memory**.

Clinical Correlation

- The hippocampus categorizes the afferent information related to recent memory and forms the new concepts. Then it correlates the new concepts learned for the first time with the pre-existing memory. The conceived facts then become stored in the cerebral cortex as **memory**. Thus if the hippocampus is damaged or is in a state of shock, the new memory is not formed. As a result the patient cannot tell about the happenings at the time of accident (**loss of recent memory/ amnesia**) but remembers the past happenings for the old memory is already stored in different parts of the cerebral cortex.

Emotionally charged memories are affected more than the non-emotional ones.

- The hippocampus is the most epileptogenic part of the cerebral hemisphere. Its lesions may cause psychomotor epilepsy.

Dentate gyrus, indusium griseum, and medial and lateral longitudinal striae

In the fetal brain, the **dentate gyrus** develops as a further extension of the hippocampus and occupies the interval between the hippocampus and the parahippocampal gyri, lying deep to fimbria. It has a three-layered archicortex. Its surface is toothed hence the name *dentate gyrus*. When traced anteriorly the dentate gyrus runs medially across the inferior surface of uncus. This part is called *tail of dentate gyrus*. The posterior end of dentate gyrus is continuous with the **splenial gyrus or gyrus fasciolaris**, which continues as thin layer of grey matter over the corpus callosum called **indusium griseum**.

The indusium griseum is the vestigial grey matter and contains two delicate longitudinal bands of fibres buried in it, the **medial and lateral longitudinal striae**.

Subiculum

It is a transition zone between three-layered archicortex and six-layered neocortex. It receives input from hippocampus and projects through the fornix to the mammillary nuclei and anterior nucleus of the thalamus.

Fibre bundles of limbic system

- Fornix.
- Mammillothalamic tract.
- Stria medullaris thalami.
- Stria terminalis.
- Medial forebrain bundle.
- Anterior commissure.
- Cingulum.
- Diagonal band (of Broca).

Several of these components of limbic system are already discussed with olfactory system and diencephalon. The remaining ones are described here.

Fornix (Fig. 19.10)

The fornix is a large bundle of mainly **projection fibres** which connects the hippocampus with the mammillary body. It constitutes the sole efferent system of the hippocampus.

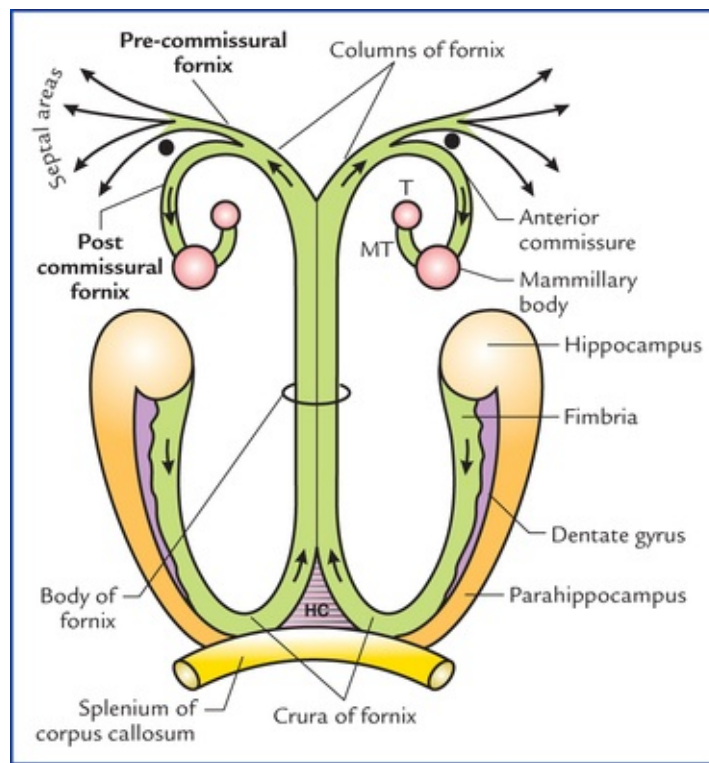


FIG. 19.10 Schematic diagram showing parts of fornix and its connections. (T = anterior nucleus of thalamus, MT = mamillothalamic tract, HC = hippocampal commissure).

On the medial surface of cerebral hemisphere, it is seen as an arched prominent bundle of white fibres below the corpus callosum, along the lower border of septum pellucidum.

There is one fornix in each cerebral hemisphere but two are so closely related/fused beneath the middle of the body of corpus callosum that they are usually described as a single structure.

Origin, course and distribution of its fibres

The fibres of fornix arise mainly from the pyramidal cells of the hippocampus and form a thin layer of white fibres on its ventricular surface called **alveus**.

The fibres of 'alveus' collect on the medial margin of hippocampus to form a narrow strip of white matter, the *fimbria*, lying flat over the *dentate gyrus*. The fimbria becomes a rounded band, the *crus of fornix* as it arches upwards, medially and forwards underneath the splenium of corpus callosum. The two crura, one of each hemisphere, curving over the thalamus, converge and unite in the midline beneath the trunk of corpus callosum to form the *body of fornix*.

Anteriorly, the body of fornix divides into two columns, *the columns of fornix*. Each column of fornix arches downwards towards the anterior commissure, and forms the anterior boundary of interventricular foramen. Then it curves posteriorly through the hypothalamus to end in the mammillary body. These fibres being located posterior to anterior commissure are referred to as *postcommissural fornix*. For some fibres of column pass in front of anterior commissure to end in the septal area and anterior hypo-thalamic region, etc. to constitute the *precommissural fornix*.

N.B.

- *Hippocampal commissure of fornix*. The two crura are interconnected by fibres passing from one to another. These crossing fibres interconnect the two hippocampi and form the *commissure of fornix/hippocampal commissure*.
- Some fibres of fornix pass above the splenium of corpus callosum to end in the cingulate gyrus of the same side and constitute the *dorsal fornix* made up of *association fibres*.

- Most of the fibres of fornix is made up of *projection fibres* connecting hippocampus with the mammillary body

Thus, fornix consists of three types of white fibres: (a) projection fibres, (b) commissural fibres, and association fibres.

Clinical Correlation

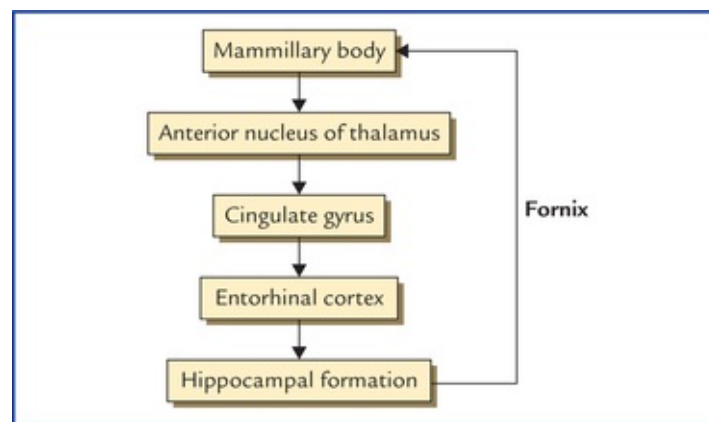
Bilateral transection of the fornix may cause a clinical condition called '**acute amnestic syndrome**' in which an individual is unable to consolidate his short-term memory into long-term memory

Mammillothalamic tract (also called bundle of Vicq d'Azyr)

Mammillothalamic tract is a prominent bundle of fibres which carry impulses from mammillary body to the anterior nucleus of thalamus. It also includes some thalamomammary fibres. Mammillothalamic tract is readily demonstrable by gross dissection. The efferents from anterior nucleus of thalamus are projected mainly to areas 23 and 24 of the cingulate gyrus but some fibres are also shunted to the tegmental nuclei of the midbrain through *mammillo-tegmental tract*.

Papez Circuit

The Papez circuit includes the following limbic structure ([Flowchart 19.1](#)):



FLOWCHART 19.1 Papez circuit.

1. Hippocampal formation.
2. Mammillary body/nucleus.
3. Anterior nucleus of thalamus.
4. Cingulate gyrus.
5. Entorhinal cortex.

The route followed by the circuit of Papez is as under: Hippocampal formation to mammillary nucleus to cingulate gyrus to entorhinal cortex to hippocampal formation.

The structures included in the Papez circuit and their connections constitute a harmonious mechanism

which elaborate **central emotion** and **emotional expressions**.

Clinical Problems

1. A light slapping or tickling of person's face or splashing water on it, is a common and effective technique for arousing him from sleep. Similarly cotton-wisp soaked in liquid ammonia is put near the nostrils to arouse an unconscious patient. Why?
2. What is the neuroanatomical basis of the state of consciousness?
3. A 55-year-old individual met a road-traffic accident and became unconscious thereafter. He was taken to the hospital where he regained consciousness. His CT scan of head did not reveal any brain lesion. When he was enquired—where and how accident took place he could not answer but he could tell the address of his residence and place of work. Provide the anatomical basis.
4. What is the anatomical basis of schizophrenia? Discuss its presenting features.
5. What is **Kluver-Bucy syndrome**?

Clinical Problem Solving

1. This is because these activities stimulate the trigeminal nerve on the face and in the nasal mucosa respectively, which in turn stimulates the reticular activating system (RAS).
2. The **state of consciousness** means that the patient should be oriented to time, place, and person. Further, he should be able to appropriately respond to questions and environmental stimuli.

The consciousness has two facets, namely arousal and awareness, which depend on two brain structures: (a) the brainstem reticular activating system (RAS), and (b) the cerebral cortex.

The **arousal** is the phenomenon of being awake, and it is primary function of the RAS, a nonspecific transmission system for sensory inputs which activate the cerebral cortex. The awareness is more sophisticated function requiring intact cortical activity in order to interpret the sensory input and respond accordingly.

3. The reticular activating system (RAS) is very sensitive part of the brain, as a result, even a blow on head can stop its functioning for sometime leading to unconsciousness. The loss of recent memory occurred due to involvement of hippocampus.
4. The **schizophrenia** is a mental disorder which occurs due to involvement of limbic system. It is characterized by: (a) chronically disordered thinking, (b) blunting of emotional responses, (c) depression and anxiety, and (d) amnesias and phobias.
5. The **Kluver-Bucy syndrome** consists of number of signs and symptoms in monkeys following removal of both temporal lobes, viz. (a) docility, (b) loss of fear and anger, (c) increased appetite, and (d) increased sexual activity which is often perverse.

N.B. This syndrome has also been described in humans following removal of large areas of temporal lobe on both the sides.

Autonomic Nervous System

The autonomic (self-controlling) nervous system is that part of the nervous system which regulates most of the involuntary activities of the body, such as the activities of smooth muscles of bronchial tree, gut, genitourinary system, pupil, arrector pili muscles of the hair, cardiac muscle and secretion of the glands. Thus it represents the visceral component of the nervous system, hence sometimes also called '**visceral nervous system**'.

The autonomic nervous system, like the somatic nervous system is made up of afferent and efferent pathways.

The **visceral afferent pathways** resemble somatic afferent pathways. The cell bodies of first order sensory neurons (pseudo-unipolar) are located in the cranial and dorsal root ganglia. Their peripheral processes are distributed through autonomic ganglia or plexuses or through somatic nerves. The central processes accompany somatic afferent fibres through cranial nerves or dorsal spinal roots into the central nervous system when they establish connections to mediate autonomic reflexes and visceral sensation.

Thus the afferent fibres of the autonomic nervous system are identical to the afferent fibres of the somatic nervous system and form part of general afferent component of the entire nervous system.

Visceral efferent pathways, however, differ from those of somatic efferent pathways (i.e. the efferent fibres, differ in the somatic and autonomic nervous systems).

Somatic efferent fibres pass directly from the CNS to the skeletal muscle, whereas autonomic (visceral) efferent fibres do not pass directly to the visceral effector organs from the CNS, instead they first relay in the autonomic ganglia outside the CNS, and then the postganglionic fibres supply the effector organs. The only exception is the innervation of the adrenal medulla.

Thus the efferent pathway of autonomic nervous system is made up of two neurons, preganglionic and postganglionic.

For all practical purposes, the autonomic nervous system (ANS) is a general visceral efferent motor system which controls and regulates smooth muscle, cardiac muscle and glands. These three divisions of autonomic nervous system differ in their organization and structure but they are closely related functionally.

N.B. All the efferent peripheral nerve fibres belong to the autonomic nervous system except those to the skeletal muscles.

Divisions of the Autonomic Nervous System

The autonomic nervous system is divided into three divisions, the **sympathetic nervous system** and **parasympathetic nervous system**, and **the enteric nervous system**.

1. **Sympathetic nervous system:** The **preganglionic sympathetic fibres** arise from lateral horn cells of the thoracic and upper two lumbar segments (T1 to L2) of the spinal cord, hence sympathetic nervous system constitutes the **thoracolumbar outflow** (Fig. 20.1). The axons of preganglionic neurons project to the autonomic ganglia (the sympathetic ganglia). The ganglia are connected to each other and form a beaded chain.

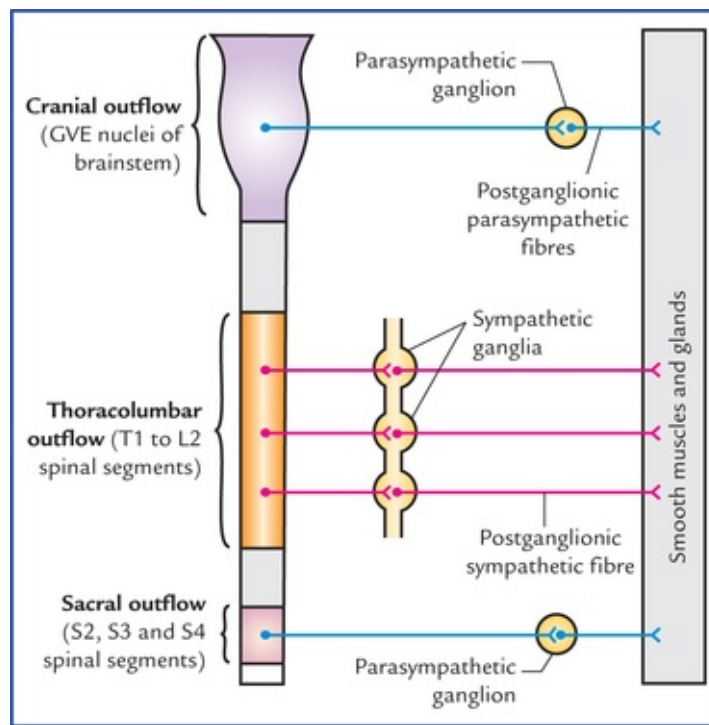


FIG. 20.1 Schematic diagram to show the **craniosacral outflow** (parasympathetic) and **thoracolumbar outflow** (sympathetic). Note that postganglionic parasympathetic fibres are shorter in length as compared to postganglionic sympathetic fibres.

2. **Parasympathetic nervous system:** The **preganglionic parasympathetic fibres** arise from general visceral efferent (GVE) nuclei of brainstem and lateral horn cells of the second, third and fourth sacral segments of the spinal cord, hence parasympathetic nervous system constitutes the **craniosacral outflow** (Fig. 20.1). The axons of preganglionic fibres project to the autonomic ganglia (the parasympathetic ganglia) which are located near or embedded in the wall of viscera/glands. The sympathetic ganglia are located near the CNS along the sympathetic chain in the paravertebral region or in front of vertebral column, hence the postganglionic sympathetic fibres are longer in length, on the other hand the parasympathetic ganglia are located near effector organ, hence the postganglionic fibres are shorter in length (Fig. 20.1).

The effects of sympathetic and parasympathetic control are mainly stimulation or inhibition of glandular secretion and contraction or relaxation of smooth/cardiac muscle.

3. **Enteric nervous system:** It is a network of neurons in the wall of gastrointestinal tract.

N.B. In general the sympathetic and parasympathetic nervous systems produce opposite effects, *viz.* sympathetic stimulation causes dilation of pupil, whereas parasympathetic stimulation causes constriction of the pupil. In tissues or organs innervated by both parasympathetic and sympathetic systems, the two systems function in an integrated reciprocal manner to produce a balanced action.

Sympathetic Nervous System

The activities (functions) of the sympathetic nervous system are such that as if it prepares the body to deal with the emergency (exciting and stressful) situations. The heart rate is increased, arterioles of the skin and intestine are constricted, those of skeletal muscle are dilated, and the blood pressure is raised. There is redistribution of the blood so that it leaves the skin and GIT and pass to the brain, heart and skeletal muscles. In addition there is dilatation of pupils, inhibition of the smooth muscle of the bronchi, intestine, and urinary bladder, and closure of sphincters.

It is generally said that the sympathetic stimulation mobilizes the body energy for **flight or fight**.

Functions of the sympathetic nervous system

- Dilatation of pupil
- Widening of the palpebral fissure
- Secretion of sweat glands
- Motor for arrector pili muscles
- Vasoconstriction of blood vessels all over the body, except those in skeletal muscles
- Stimulation of heart
- Bronchodilatation and inhibition of secretion from bronchial glands
- Inhibition of gastrointestinal motility and secretions
- Sensory for pain from most of the viscera
- Contraction of sphincters of the bladder and bowel
- Motor for ejaculation.

Efferent nerve fibres (thoracolumbar outflow)

The preganglionic sympathetic fibres arise in the lateral grey column of the spinal cord from segments T1 to L2. From each of these segments they emerge as small myelinated axons into the corresponding anterior primary ramus and pass via white ramus communicans into the ganglion of a sympathetic trunk.

Once preganglionic fibres reach the paravertebral ganglia (ganglia in the sympathetic chain) they are distributed as follows (Figs 20.2, 20.3):

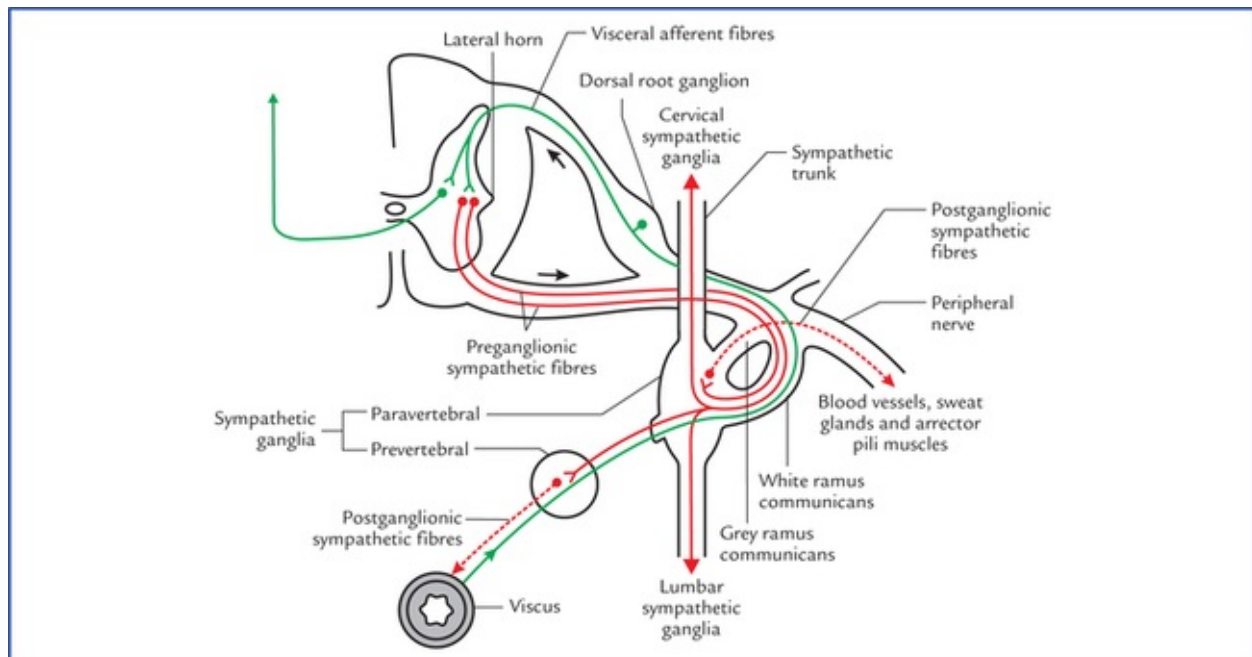


FIG. 20.2 Sympathetic efferent and afferent fibres. The preganglionic sympathetic fibres are shown by solid red lines and postganglionic sympathetic fibres by interrupted red lines. The sympathetic afferent fibres are shown by green lines. Note the fate of preganglionic sympathetic fibres. These may (a) relay in their corresponding ganglion and pass to their corresponding spinal nerve for distribution, (b) ascend or descend in the sympathetic chain and relay in higher or lower ganglia, or (c) pass without synapse to a peripheral (prevertebral) ganglion for relay.

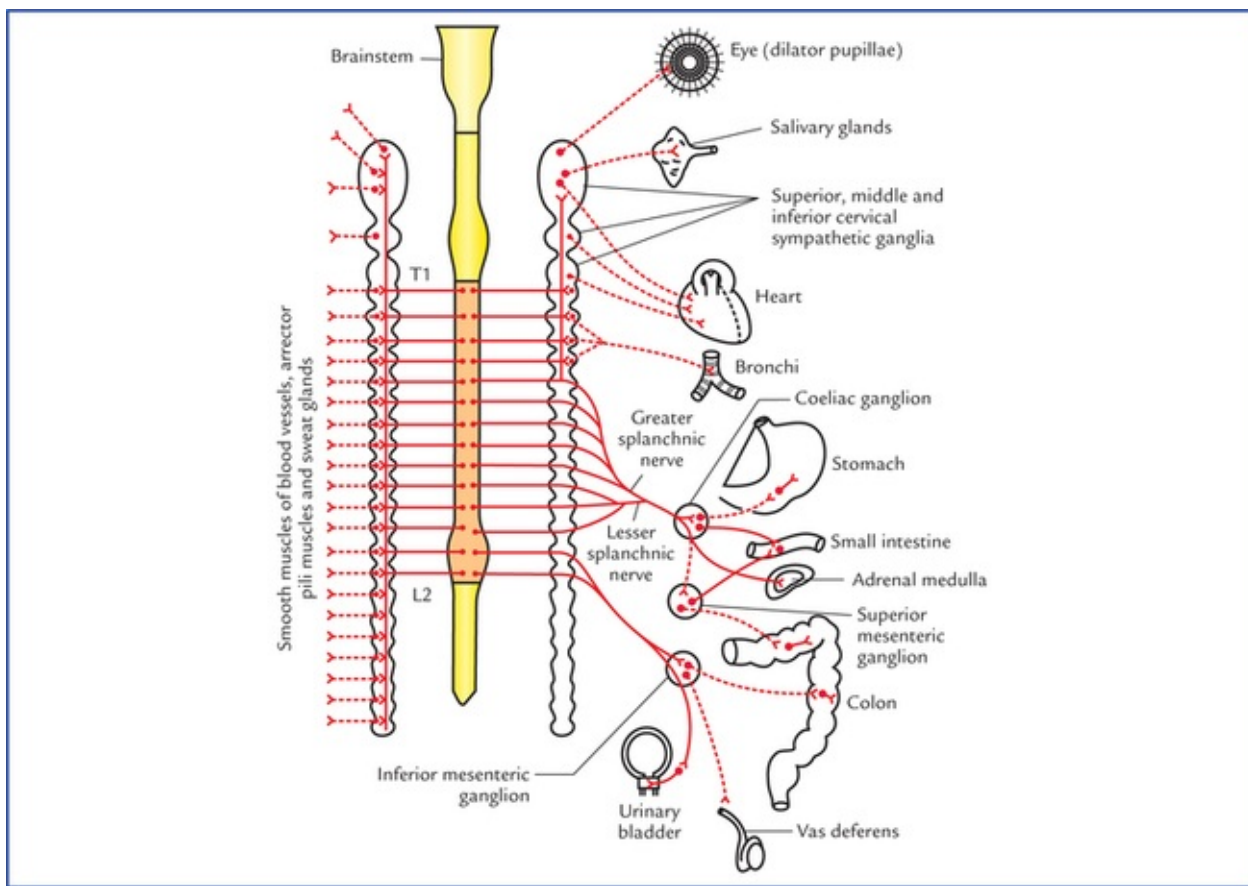


FIG. 20.3 Sympathetic nervous system (*thoracolumbar outflow*). The postganglionic sympathetic fibres are shown by interrupted lines.

- Synapse with the cells in the ganglion. The postganglionic fibres (non-myelinated axons) arising from ganglion cells rejoin the spinal nerves (*grey rami communicantes*) and distributed through its branches to the blood vessels, sweat glands and arrector pili muscles.
- Ascend in the sympathetic trunk to synapse in the cervical sympathetic ganglia.
- Descend in the sympathetic trunk to synapse in lumbar sympathetic ganglia.
- Leave the ganglia without synapsing as **splanchnic nerves** and relay in the prevertebral ganglia. Some of these fibres pass to the suprarenal gland where they synapse with the cells within the medulla. These medullary cells which may be regarded as modified postganglionic sympathetic neurons, secrete **epinephrine** and **norepinephrine**.

Sympathetic trunks

The sympathetic trunks are two ganglionated chains of nerve fibres lying one on either side of the vertebral column, extending along its whole length, i.e. from atlas vertebra above to the coccyx below. Each chain (trunk) bears a number of knot-like enlargements, the **sympathetic ganglia**. The number of ganglia is variable, but generally there are three in the cervical region, 11 in the thoracic region, four in the lumbar region, and four in the sacral region. Thus each sympathetic chain possesses 22 sympathetic ganglia. The ganglia associated with sympathetic chain are termed **paravertebral ganglia**.

N.B. The terminal ganglion, the **ganglion impar** is formed by fusion of two sympathetic trunks as they converge in front of the coccyx.

Cervical sympathetic ganglia

The cervical part of sympathetic trunk extends from base of skull to the neck of first rib. It consists of

three large ganglia, superior, middle and inferior. They are believed to be formed during development by the fusion of smaller segmental ganglia.

- The **superior cervical ganglion** is largest and formed by the fusion of upper 4 cervical ganglia. It is spindle-shaped and lies in front of transverse processes of C2 and C3 vertebra.

Branches

- *Grey rami communicantes* to ventral rami of upper four cervical spinal nerves.
- *Arterial branches* to, both external and internal carotid arteries. These branches form plexuses around these arteries and are distributed along their branches. The fibres carried by external carotid artery are vasomotor, sudomotor, and pilomotor and supply areas of skin mainly supplied by trigeminal nerve.

The fibres carried by internal carotid artery (**internal carotid nerve**) are (motor) to the dilator pupillae and smooth muscle of levator palpebrae superioris (Muller's muscle).

- *Cardiac branch* (superior cervical cardiac branch) to the heart. It is motor (visceral) to cardiac muscle.

- The **middle cervical ganglion** is small and formed by the fusion of 5th and 6th cervical ganglia. It lies in close relationship to inferior thyroid artery at the level of cricoid cartilage (C6).

Branches

- *Grey rami communicantes* to 5th and 6th cervical spinal nerves.
- *Arterial branch* to inferior thyroid artery for distribution to pharynx, larynx, and upper parts of the trachea and oesophagus, thyroid and parathyroid.
- *Cardiac branch* (middle cervical cardiac branch) to the heart.
- The **inferior cervical ganglion** is formed by the fusion of 7th and 8th cervical ganglia. It fuses with the first thoracic ganglion to form the cervicothoracic ganglion (also called **stellate ganglion** because its numerous branches give it a star-shaped appearance).

Branches

- *Grey rami communicantes* to C7 and C8 (in most cases T1 also) spinal nerves.
- *Arterial branches* to both subclavian and vertebral arteries.
- *Cardiac branch* (inferior cardiac branch) to the heart.

N.B. The cervical ganglia receive their preganglionic fibres from first and second thoracic (T1 and T2) spinal segments by the white rami communicantes of first and second thoracic spinal nerves.

Thoracic ganglia

The thoracic part of sympathetic trunk usually consists of 11 ganglia (because first thoracic ganglion gets fused with the inferior cervical ganglion).

- They are connected by grey and white rami communicantes to the thoracic spinal nerves.
- The first five thoracic ganglia (T1-T5) give postganglionic fibres to the heart, lung and oesophagus (through cardiac, pulmonary and oesophageal plexuses).
- The lower eight ganglia give preganglionic fibres, which are grouped to form the **three splanchnic nerves**:
- *Greater splanchnic nerve* arises from 5th to 9th thoracic ganglia.
- *Lesser splanchnic nerve* arises from 10th and 11th thoracic ganglia.
- *Least splanchnic nerve* arises from 12th (or last thoracic) ganglion.

The three splanchnic nerves pierce the crus of diaphragm to end in coeliac and superior mesenteric plexuses and ganglia on abdominal aorta. From there postganglionic fibres arise and supply the abdominal viscera.

Lumbar ganglia

The abdominal part of sympathetic trunk consists of four ganglia:

- Only upper two ganglia receive white rami communicantes from first and second lumbar spinal nerves.
- All ganglia give grey rami communicantes to corresponding lumbar spinal nerves.
- Visceral branches and lumbar splanchnic nerves from ganglia pass downwards, to form a plexus in front of the 5th lumbar and upper sacral vertebrae, called **superior hypogastric plexus**. It lies between the common iliac vessels. It divides into two **inferior hypogastric plexuses**, one on each side of the rectum.

Sacral ganglia

The pelvic part of sympathetic trunk consists of four ganglia. They give grey rami communicantes to sacral and coccygeal nerves to supply lower limbs, buttocks and perineum; and visceral branches to the **pelvic plexuses**.

Prevertebral ganglia

There are three prevertebral ganglia, which are situated in front of vertebral column in the abdominal cavity. They are located close to the origins of superior, middle and inferior mesenteric arteries and are named after them, *viz.*

- *Coeliac ganglion*, at the origin of coeliac artery
- *Superior mesenteric ganglion*, at the origin of superior mesenteric artery
- *Inferior mesenteric ganglion*, at the origin of inferior mesenteric artery.

Parasympathetic Nervous System

The activities of parasympathetic nervous system are directed towards conserving and restoring energy. The heart rate is slowed, the pupils are constricted, the peristalsis and glandular activity is increased, the sphincters are relaxed (opened), and the bladder wall is contracted.

In general the parasympathetic stimulation slows down the body processes except that of GIT and genitourinary system, and allows restoration processes to occur quietly and peacefully.

Functions of the parasympathetic nervous system

- Constriction of pupil.
- Increase in lens curvature (antero-posterior) for accommodation.
- Secretion of respiratory and digestive glands.
- Inhibition of cardiac excitation, conduction and contraction.
- Bronchoconstriction and increased secretion from bronchial glands.
- Increased gastrointestinal motility and inhibition of pyloric and anal sphincters.
- Sensory differentiation of faeces and flatus.
- Contraction of muscular wall of urinary bladder (*detrusor muscle*) and inhibition of the internal urethral sphincter (sphincter vesicae).
- Motor for initiation and maintenance of erection of penis.

The functions of sympathetic and parasympathetic nervous system are compared in [Table 20.1](#).

Comparison of sympathetic and parasympathetic functions

Structure	Sympathetic function	Parasympathetic function
Eye	Dilatation of pupil	Constriction of pupil
Lacrimal gland and Salivary glands	Viscous secretion	Watery secretion
Bronchial smooth muscle	Relaxation	Contraction
Heart	Increases heart rate	Decreases heart rate
GIT	Decreases peristalsis and constricts the sphincters	Increases peristalsis and relaxes sphincters
Genitourinary tract		
• Bladder wall and sphincter	Relaxes bladder wall and constricts the sphincter	Contracts the bladder wall and relaxes the sphincter
• Penis	Ejaculation	Erection
Skin		
• Sweat glands	Produce sweating	No effect
• Arrector pili	Contraction of arrector pili leading erection of hair	No effect
Blood vessels		
• Skin, splanchnic vessels	Contraction	No effect
• Skeletal muscles	Relaxation	No effect

Efferent nerve fibres (Fig. 20.4)

The preganglionic parasympathetic fibres arise from brain-stem and spinal cord.

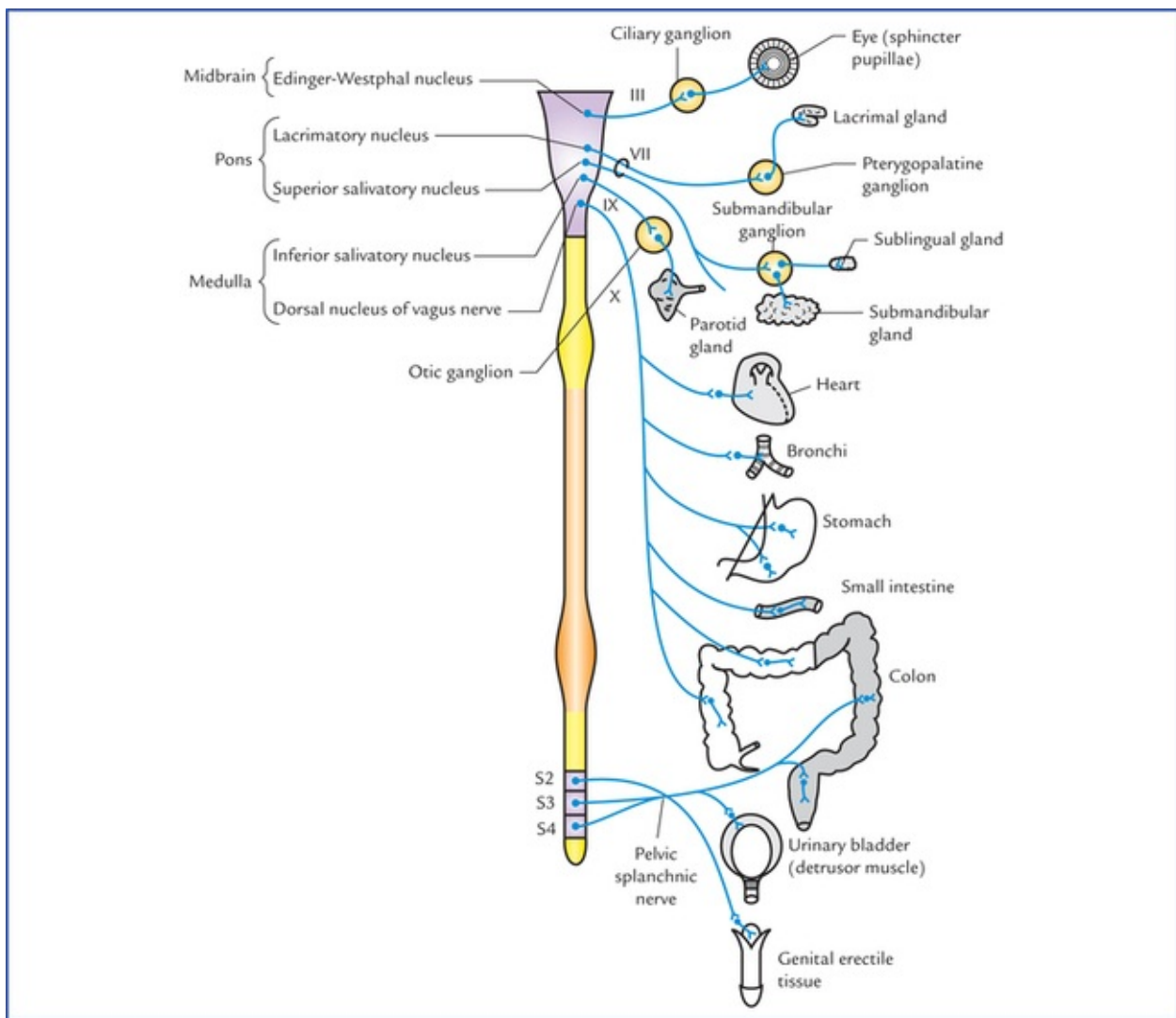


FIG. 20.4 Parasympathetic nervous system (craniosacral outflow).

From the brainstem, they arise from general visceral efferent nuclei (*viz.* Edinger-Westphal nucleus, lacrimatory nucleus and superior salivatory nucleus, inferior salivatory nucleus, and dorsal nucleus of vagus) and run through IIIrd (oculomotor), VIth (facial), IXth (glossopharyngeal) and Xth (vagus) cranial nerves, respectively to terminate in the parasympathetic ganglia in the region of head and neck (*viz.* ciliary, pterygopalatine, submandibular, and otic) and ganglion cells in the autonomic nerve plexuses in the thorax and abdomen. These fibres form what is termed *cranial outflow*. Preganglionic fibres from Edinger-Westphal nucleus relay in the ciliary ganglion, from lacrimatory nucleus in the pterygopalatine ganglion, from superior salivatory nucleus in the submandibular ganglion, from inferior salivatory nucleus in the otic ganglion, and from dorsal nucleus of vagus in the ganglion cells of autonomic nerve plexuses in the thorax and abdomen.

From the spinal cord, the preganglionic parasympathetic fibres arise from the cells in the grey matter of the 2nd, 3rd, and 4th sacral spinal segments, pass through anterior nerve roots of the corresponding sacral spinal nerves (*sacral outflow*), leave the sacral nerves and form the **pelvic splanchnic nerves**, through which they terminate in parasympathetic ganglia located near or within the walls of pelvic organs.

The postganglionic parasympathetic fibres arise from parasympathetic ganglia or autonomic plexuses and supply the viscera.

Autonomic plexuses

The large collections of afferent and efferent autonomic fibres and their associated ganglia form autonomic plexuses in the thorax, abdomen, and pelvis. The branches from these plexuses innervate the viscera.

The autonomic plexuses in different regions of body are listed in [Table 20.2](#).

Table 20.2
Autonomic plexuses and their locations

Region	Autonomic plexuses
Thorax	Cardiac, pulmonary, and oesophageal
Abdomen*	Coeliac, superior mesenteric, inferior mesenteric and aortic
Pelvis	Superior and inferior hypogastric

*In the abdomen the plexuses are associated with aorta and its branches, and named after them.

Autonomic ganglia

Autonomic ganglia are the sites where preganglionic fibres synapse on postganglionic neurons and thus serve as a relay station. The autonomic ganglia are situated along the course of peripheral efferent autonomic pathways.

The sympathetic ganglia form part of sympathetic chain/trunk and are also located in front of vertebral column, away from the viscera.

The parasympathetic ganglia, on the other hand, are situated close to or within the walls of the viscera.

Neurotransmitters involved in autonomic nerve impulse transmission

The autonomic nerve fibres release one of the two transmitter substances, *acetylcholine* (**cholinergic endings**) or *noradrenaline* (**adrenergic endings**).

All the preganglionic autonomic fibres (i.e. both sympathetic as well as parasympathetic) and postganglionic parasympathetic fibres are **cholinergic**, i.e. their terminals liberate **acetylcholine** as their transmitter substance. All the postganglionic sympathetic fibres are **adrenergic**, i.e. their terminals liberate **noradrenaline (norepinephrine)** except for those supplying the sweat glands (i.e. sudomotor fibres), hair muscles (arrector pili) which are cholinergic ([Fig. 20.5](#)).

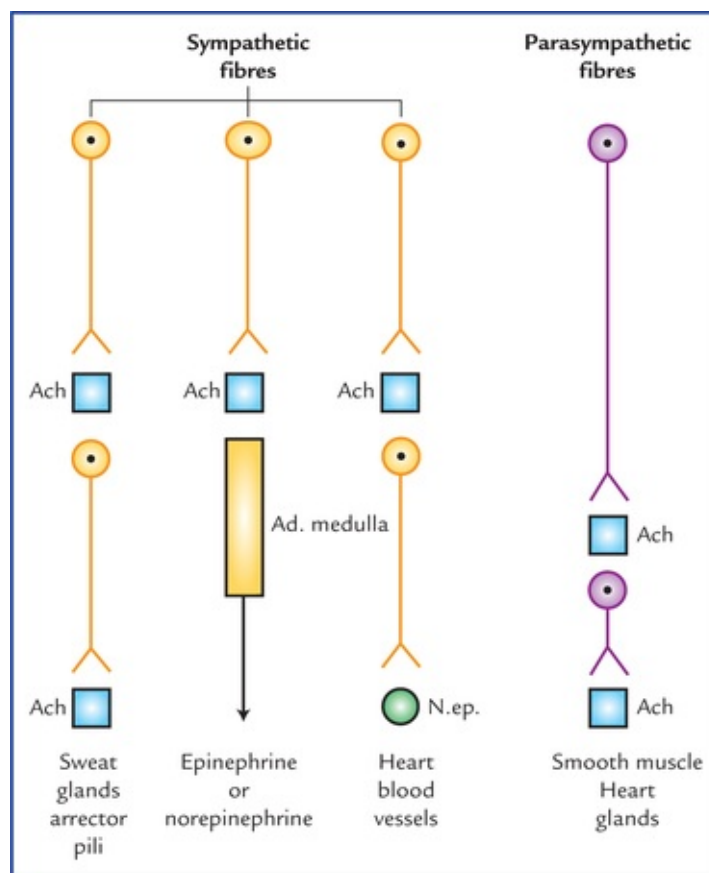


FIG. 20.5 The autonomic efferent fibres and chemical transmitter substances released by their terminals.

Points to Note

- The postganglionic sympathetic transmitter substance, norepinephrine produces both excitatory and inhibitory actions at the postsynaptic sites. This is, due to presence of two types of **adrenergic receptors**, α and β in the target organs. The response depends upon the type of receptors being activated. In general the activation of α **receptors** causes excitation and activation of (β **receptors** causes inhibition.
- The cholinergic receptors are also of two types, muscarinic and nicotinic. The **muscarinic receptors** are activated by muscarine which elicits the same effects as acetylcholine in the target organs. The **nicotinic receptors** are excited by low doses, while blocked by high doses of nicotine.

Clinical Correlation

The classification of autonomic receptors has led to the development of many drugs which can modify autonomic activities. These drugs are commonly used to treat shock, hypertension and cardiac problems.

The anatomical, physiological and pharmacological differences between sympathetic and parasympathetic parts of autonomic nervous system are provided in [Table 20.3](#).

Anatomical, physiological, and pharmacological differences between sympathetic and parasympathetic parts of the autonomic nervous system

	Sympathetic system	Parasympathetic system
Anatomical differences		
• Cells of origin of preganglionic fibres	Are located in the thoracic and upper 2 or 3 lumbar segments (T1-L2/3) of the spinal cord (thoracolumbar outflow)	Are located in the brainstem and second, third, and fourth sacral segments (S2, S3 & S4) of the spinal cord (craniosacral outflow)
• Ganglia	Are located along the sympathetic chain and in front of prevertebral region, hence preganglionic fibres are shorter in length and postganglionic sympathetic fibres are longer in length	Are located near or in the effector organs, hence preganglionic fibres are longer in length and postganglionic are shorter in length
• Outflow from CNS occurs through:	Spinal nerves Sympathetic nerves Splanchnic nerve	Cranial nerves Pelvic nerves
• Distribution of postganglionic fibres	Wide distribution	Limited distribution
Physiological differences	Prepares the body for emergency	Conserves and restores the energy
Pharmacological differences	(Also see page 239)	(Also see page 239)
Neurotransmitter liberated by the postganglionic fibres	All postganglionic sympathetic fibres liberate norepinephrine except for those supplying the sweat glands or blood vessels in the skeletal muscles which liberate acetylcholine	All postganglionic parasympathetic fibres liberate acetylcholine

Afferent nerve fibres of autonomic nervous system (visceral afferents)

The cell bodies of the afferent nerve fibres (first order sensory neurons) of the autonomic nervous system are located either in the dorsal root ganglia of spinal nerves or in the sensory ganglia of the cranial nerves. These neurons are **general visceral afferent neurons** as they carry general sensations from the viscera. The central processes of these neurons enter the central nervous system and either take part in the formation of local reflex arcs, or pass to higher centres of the autonomic nervous system, such as the hypothalamus.

The impulses carried by these fibres are associated with:

- Visceral reflexes, usually at the unconscious level.
- Sensations of hunger, thirst, nausea, sex desire and bladder and bowel distension.
- Visceral pain.

Once the autonomic afferents enter the spinal cord or brain, they travel alongside, or mixed with, the somatic afferent fibres.

N.B. The nerve endings of autonomic afferents (visceral afferents) are not activated by heat, cut or touch but rather by stretch or lack of oxygen.

Visceral Pain

The visceral pain is of great clinical significance, hence needs an elaborate description.

Usually the viscera are insensitive to cutting and such sensations as touch and heat. However, visceral

pain is experienced when it is stretched or suffers from ischaemia (lack of O₂) or if there is accumulation of metabolites.

The visceral pain is dull, boring and poorly localized due to stimulation of large number of fibres, on the other hand the somatic pain is sharp, precise and well localized. The pain of appendicitis is a classical example to put forward these facts. Initially when there is an inflammation of appendix and its covering layer of visceral peritoneum (both innervated by autonomic nerve fibres), the pain is dull and vaguely located in the midline in the periumbilical region. The midgut from which the appendix is derived is a median structure during the development. As the inflammation progresses and involves parietal peritoneum (innervated by somatic nerve fibres), the pain is sharp and clearly located in the right iliac fossa at McBurney's point.

Clinical Correlation

Referred pain

The visceral pain is frequently referred to the skin areas (dermatomes) that are innervated by the same segments of the spinal cord as the diseased viscus. Hence referred pain may be defined as **pain felt at a site remote from its source of origin.**

Anatomical basis of referred pain

The exact basis is not known. However, there are two theories to explain it:

- One theory is that when nerve fibres from the viscus and the skin (dermatome) enter the same segment of spinal cord, they synapse with and stimulate the same (common) second order neurons in the sensory pathway to the cerebral cortex (Fig. 20.6). As a result stimuli from viscus and skin ascend to the central nervous system along a common pathway, consequently the cerebral cortex fails to distinguish between the sites of origin of stimuli.

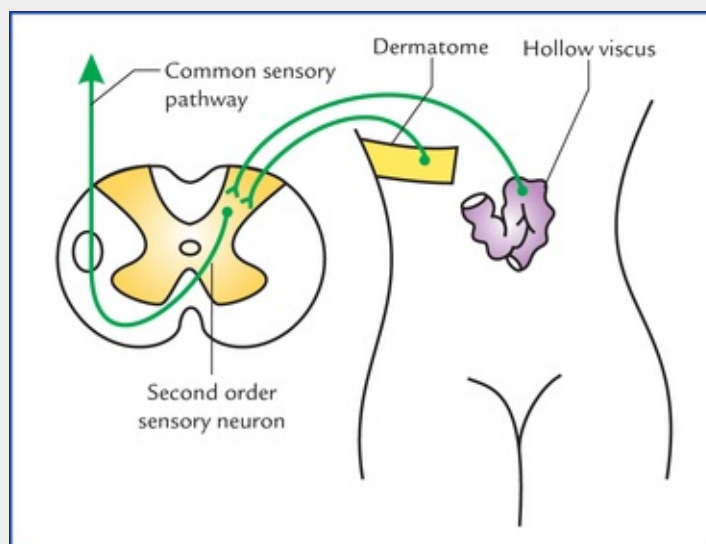


FIG. 20.6 The first order sensory neurons carrying sensations from viscera and dermatome are entering in the same segment of the spinal cord and synapsing with the common second order sensory neuron.

- Another theory is that under normal conditions the viscera do not send painful stimuli to the

brain, whereas the skin repeatedly sends noxious stimuli to the brain. Since afferent fibres from both enter the same segment of the spinal cord, the brain interprets that the information is coming from the skin rather than from the viscus.

Some important examples of referred pain (Fig. 20.7) are listed in Table 20.4.

Table 20.4

The organs and sites of referred pain

Organs (viscera)	Sites of referred pain
Heart	Left precordium, inner aspect of arm and forearm
Gall bladder	Tip of right shoulder
Spleen	Tip of left shoulder (Kehr's sign)
Diaphragm	Tips of shoulders
Appendix	Skin around umbilicus
Testis	
Ovary	
Kidney	Loin, groin, scrotum and inner aspect of the thigh
Ureter	

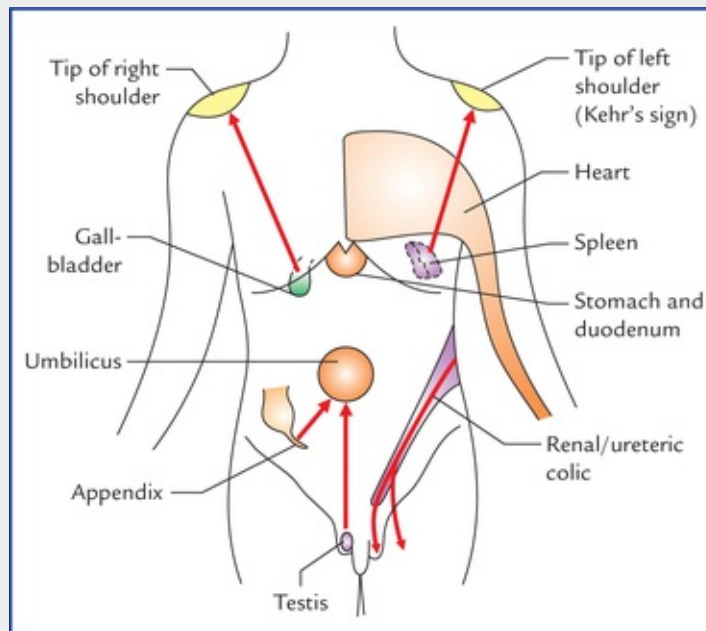


FIG. 20.7 Sites of referred pain from some viscera.

Higher control of the autonomic nervous system

The normal activities of autonomic nervous system are governed by regulatory centres in the brainstem, hypothalamus and cerebral cortex.

The hypothalamus is regarded as the most important higher centre for the control of autonomic nervous system. Its anterior part controls the parasympathetic responses, whereas its posterior part controls the sympathetic responses.

Almost all the autonomic responses can be modified by the activity of same area of the cerebral cortex, presumably through hypothalamus.

Clinical Correlation

Miller et al. (1970) suggested that the autonomic nervous system can be brought under voluntary control to some extent and that the patients with hypertension, for example, possibly can be trained to reduce their blood pressure.

The higher centres of the brain can abnormally influence the functions of autonomic nervous system and induce clinical conditions like **cardiac palpitations** and **myocardial infarction**.

Enteric nervous system

The **enteric nervous system** is a network of intrinsic neurons and ganglia located in the wall of the gastrointestinal tract. These intrinsic neurons are derived from neural crest cells and are independent of sympathetic and parasympathetic nerves. There exists reflex pathway (local reflex mechanisms) in the enteric nervous system through which it controls contraction of muscle coats of the alimentary tract, the secretion of gastric acid, intestinal transport of water and electrolytes, mucosal blood flow, etc.

N.B. Though complex interactions occur between enteric and parasympathetic and sympathetic nervous systems, the enteric nervous system is capable of performing its reflex activities independent of CNS.

Clinical Correlation

Since intrinsic neurons survive following section of extrinsic sympathetic and parasympathetic nerves, the organs/parts of GIT that are transplanted are not truly denervated. Consequently there is no cessation of their activity, i.e. contraction remains unaffected and no structural changes occur.

Important autonomic innervations

The Eyeball

The main structures supplied by autonomic motor fibres in the eyeball are: sphincter pupillae, ciliary muscle and dilator pupillae.

- **Sphincter pupillae and ciliary muscle**, are innervated by parasympathetic fibres (see [Chapter 9](#)).
- **Dilator pupillae**, it is innervated by sympathetic fibres. The preganglionic sympathetic fibres arise from lateral horn cells of first thoracic spinal segment (T1), pass through anterior root of the first

thoracic nerve, to enter the inferior cervical sympathetic ganglion and ascend in the cervical sympathetic chain to relay in its superior cervical sympathetic ganglion. The postganglionic fibres from ganglion, pass successively through internal carotid nerve (or plexus), ophthalmic nerve, nasociliary nerve and long ciliary nerves (occasionally short ciliary nerves) to supply the dilator pupillae (Fig. 20.8).

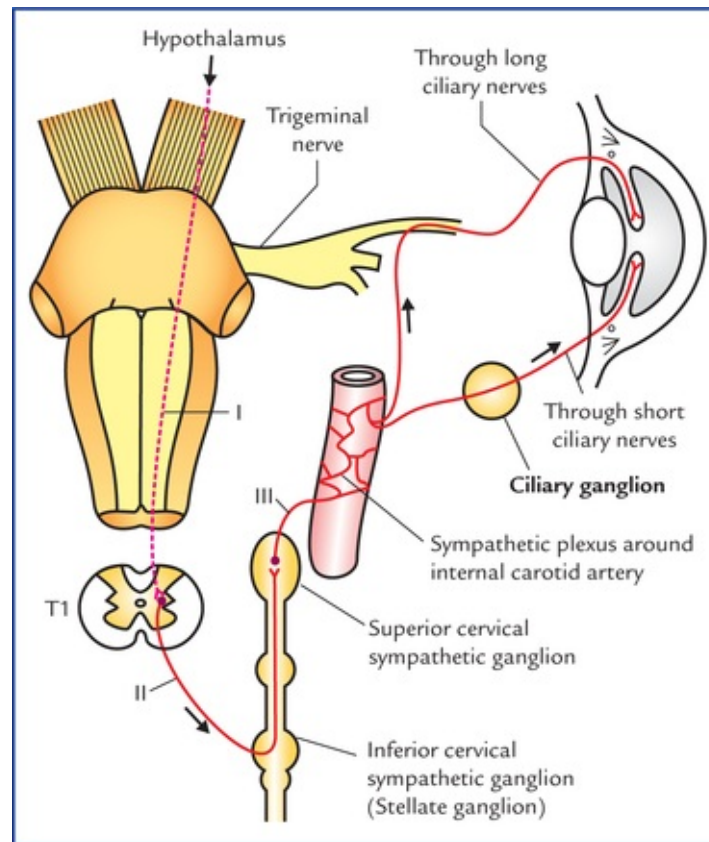


FIG. 20.8 Sympathetic pathway to the eye. I. First order neuron (**hypothalamospinal fibres** project) without interruption from hypothalamus to the *ciliospinal centre* in the intermediolateral cell column of T1 spinal segment, II. Second order neuron (**preganglionic fibres**), arise from T1 spinal segment and relay in the superior cervical sympathetic ganglion, III. Third order neuron (**postganglionic fibres**) arise from superior cervical sympathetic ganglion. The second and third order neurons form the peripheral part of the sympathetic motor pathway.

N.B. Sympathetic fibres also supply the orbitalis muscle in the floor of orbit, smooth muscle fibres of levator palpebrae superioris (Muller's muscle) and sudomotor and vaso-motor fibres to orbit, eyelid and face.

Clinical Correlation

Horner's syndrome

It occurs due to interruption of sympathetic pathway to the head and neck (Fig. 20.8). The common sites of lesion are: brainstem, cervical part of spinal cord, or stellate ganglion.

Characteristic features

• Miosis (i.e. constriction of pupil)	Due to paralysis of dilator pupillae and unopposed action of sphincter pupillae.
• Partial ptosis (i.e. slight drooping of the	Due to paralysis of smooth muscle fibres of levator palpebrae superioris called Muller's

upper eyelid)	muscle.
• Anhidrosis (i.e. loss of sweating)	Due to involvement of sudomotor fibres which are concerned with sweating in the region of head and neck.
• Enophthalmos (sunken eyeball)	It is often apparent but not real and is caused by ptosis. The paralysis of orbitalis muscle may also be responsible.
• Flushing of the face	Due to involvement of vasoconstrictor fibres leading to vasodilation of skin arterioles in the region of head and neck.

The Salivary Glands

Parotid gland

Parasympathetic innervation (secretomotor supply): The preganglionic fibres arise from *inferior salivatory nucleus* in the pons, pass successively through glossopharyngeal nerve and its tympanic branch, the tympanic plexus and the lesser petrosal nerve to terminate in the otic ganglion. The postganglionic fibres from the otic ganglion, pass through the auriculotemporal nerve to supply the parotid gland (Fig. 20.9).

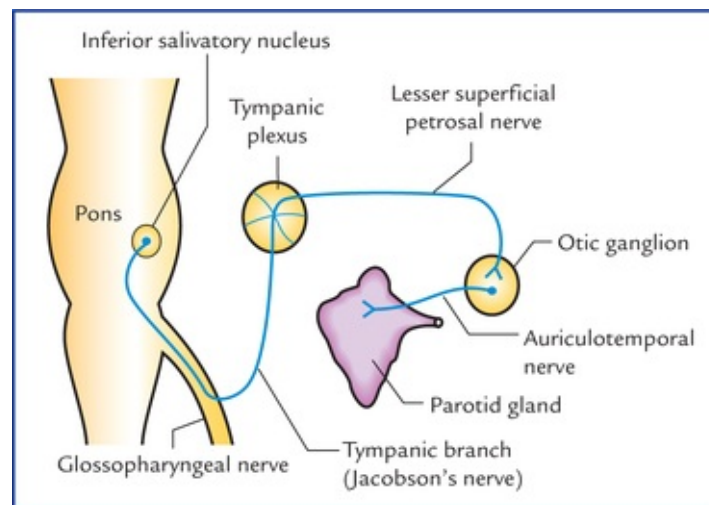


FIG. 20.9 Secretomotor pathway for parotid gland.

Submandibular and sublingual glands

Parasympathetic innervation (secretomotor nerve supply): The preganglionic fibres arise from *superior salivatory nucleus* in the pons, pass successively through facial, chorda tympani and lingual nerves to terminate in the submandibular ganglion. The postganglionic fibres from the submandibular ganglion supply the submandibular gland directly, and sublingual gland through the lingual nerve (Fig. 20.10).

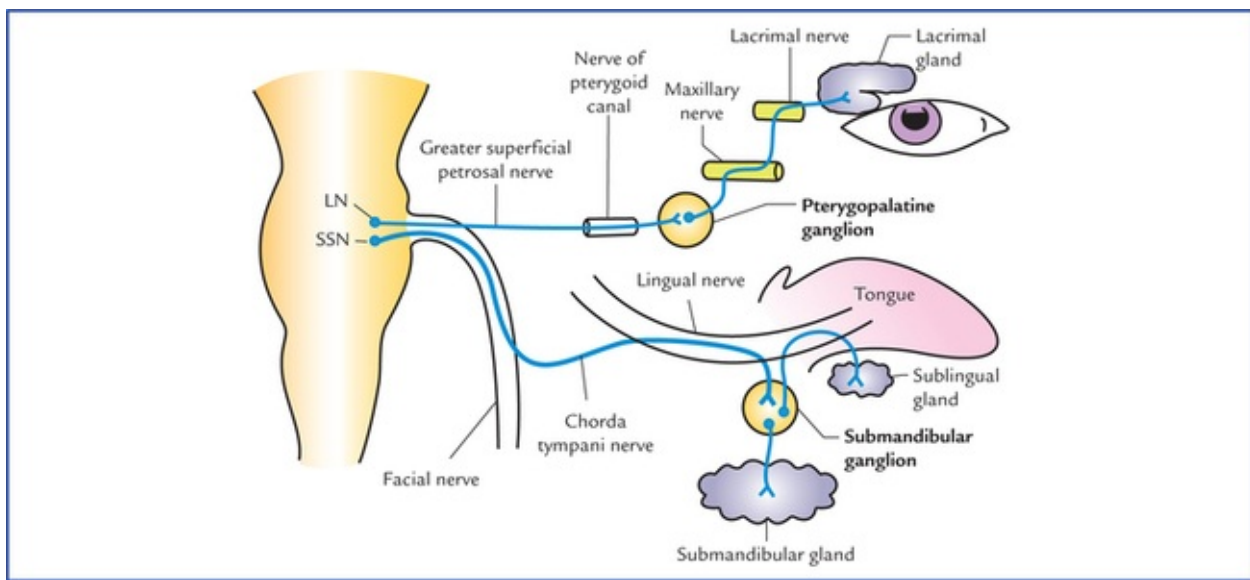


FIG. 20.10 Secretomotor pathways for lacrimal gland, and submandibular and sublingual salivary glands. (LN = lacrimatory nucleus, and SSN = superior salivatory nucleus.)

Lacrimal gland

Parasympathetic innervation (secretomotor nerve supply): The preganglionic parasympathetic fibres arise from lacrimatory nucleus in the pons, and pass successively through nerves intermedius, geniculate ganglion of facial nerve, greater petrosal nerve and nerve of pterygoid canal to terminate in the pterygopalatine ganglion. The postganglionic fibres arise from pterygopalatine ganglion, and pass successively through maxillary nerve, zygomatic nerve and its zygomatico-temporal branch, and lacrimal nerve to supply the lacrimal gland (Fig. 20.10).

Gastrointestinal Tract

Motor supply

Parasympathetic innervation

- The most of GIT, i.e. from oesophagus to the junction of right two-third and left one-third of transverse colon, is supplied by **vagus nerve**. Preganglionic parasympathetic fibres arise from dorsal nucleus of vagus, and pass successively through vagus nerve coeliac, superior and inferior mesenteric plexuses, and then run along the coeliac, superior mesenteric and inferior mesenteric arteries and their branches to enter the GIT, where they relay in the ganglia within myenteric (Auerbach's) and submucosal (Meissner's) plexuses located in the wall of the gut.
- From junction of right two-third and left one-third of transverse colon to the junction of upper and lower halves of the anal canal the GIT is supplied by **sacral parasympathetic outflow**. The preganglionic parasympathetic fibres arise from anterolateral grey columns of S2, S3 and S4 spinal segments, pass successively through the ventral roots of spinal nerves, pelvic splanchnic nerves and superior and inferior hypogastric plexuses to terminate in the ganglia within myenteric (Auerbach's) and submucosal (Meissner's) plexuses located in the gut wall.

The postganglionic fibres arise from parasympathetic ganglia located in the gut wall and supply the muscle and glands of GIT.

Sympathetic innervation: The preganglionic sympathetic fibres arise from T5 to L2 spinal segments, pass through the sympathetic trunks without relay, travel through the splanchnic nerves to terminate in the

ganglia related to the coeliac (*coeliac ganglion*), superior mesenteric (*superior mesenteric ganglion*) and inferior mesenteric (*inferior mes-enteric ganglion*) arteries. The postganglionic fibres arise from these ganglia and travel along these arteries to reach the gut which they supply.

Functional significance

The parasympathetic nerves stimulate peristalsis (gastrointestinal motility) and relax the sphincters. They also stimulate secretion from mucosal glands.

The sympathetic fibres inhibit peristalsis and cause contraction of the sphincters; they also inhibit secretion from mucosal glands.

Clinical Correlation

Congenital megacolon (Hirschsprung disease)

Sometimes, during embryonic period the neural crest cells fail to migrate into the wall of descending colon at its junction with the sigmoid colon, leading to lack of formation of parasympathetic ganglia in the myenteric (Auerbach's) plexus. As a result the part of colon lacking ganglia shows marked decrease in its peristalsis leading to functional obstruction. Consequently the proximal part of descending colon becomes greatly distended due to accumulation of faeces, causing congenital megacolon (Hirschsprung disease).

Sensory supply

The afferent fibres travel along both sympathetic and parasympathetic pathways.

Pain from most of the GIT travel along the sympathetic nerves except from upper part (i.e. pharynx and oesophagus) and lower part (i.e. lower part of pelvic colon, rectum and upper part of anal canal) from where it is carried by parasympathetic fibres through vagus and pelvic splanchnic nerves respectively.

Urinary Bladder

Motor supply (Fig. 20.11)

Parasympathetic innervation: The preganglionic parasympathetic fibres arise from S2, S3 and S4 spinal segments (**spinal micturition centre**), pass through the pelvic splanchnic nerves and inferior hypogastric plexus to terminate in the nerve cells located in the vesical plexus. The postganglionic fibres arise from vesical plexus and supply the urinary bladder.

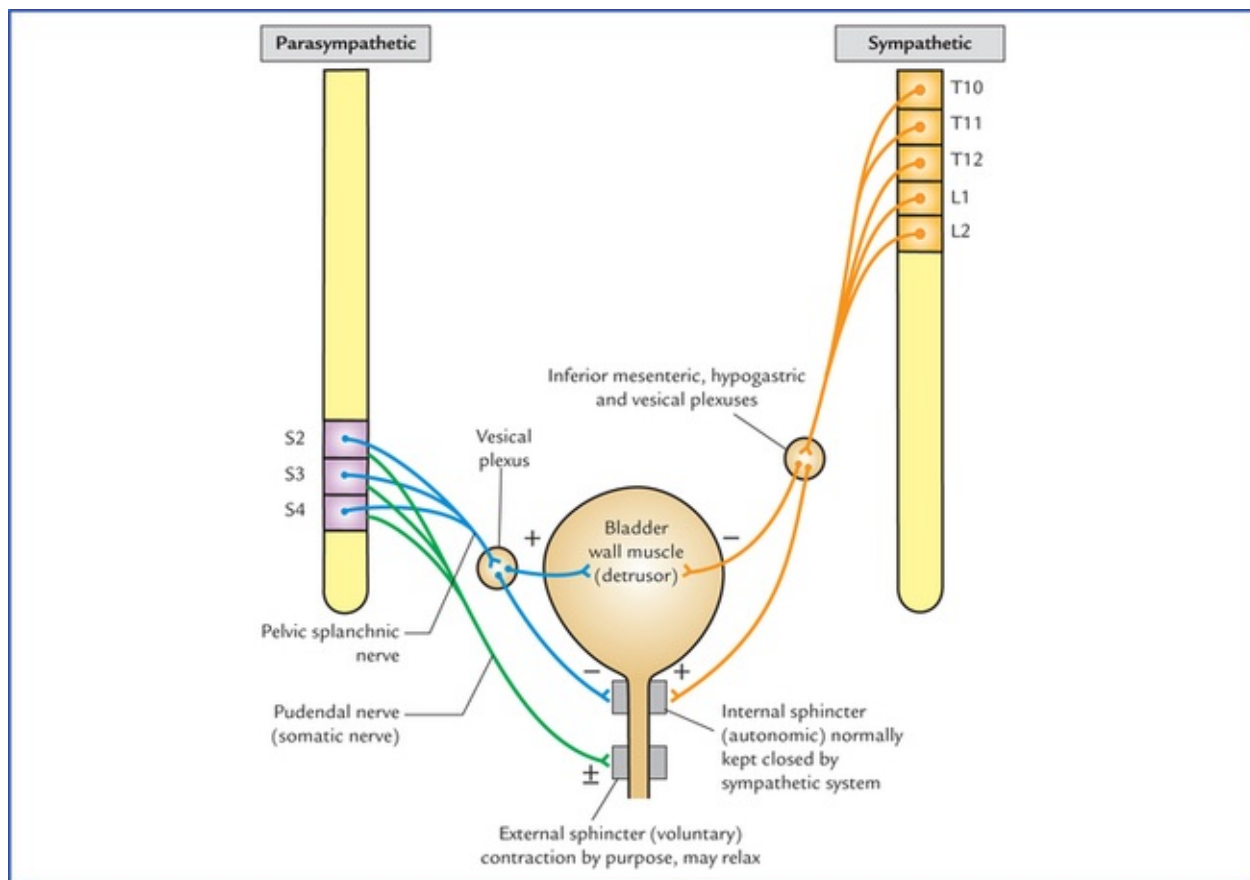


FIG. 20.11 Motor innervation of the urinary bladder, showing physiological and neurological principles of bladder function. (+) = contraction, (-) = relaxation, (±) = contraction and relaxation.

Sympathetic innervation: The preganglionic sympathetic fibres arise from T10 to L2 spinal segments, and terminate in the cells of inferior mesenteric, superior hypogastric, inferior hypogastric and vesical plexuses. The postganglionic fibres arise from the cells within these plexuses and supply the urinary bladder.

The parasympathetic fibres stimulate the contraction of the smooth muscle of the bladder wall (**detrusor muscle**) and relax the internal urethra! sphincter (**sphincter vesicae**).

The sympathetic fibres have little or no action on the detrusor muscle and play only a minor role in maintaining urinary continence by causing contraction of sphincter vesicae. However, in males during ejaculation (brought out by sympathetic action) the sympathetic stimulation causes active contraction of sphincter vesicae and prevents the seminal fluid from entering the bladder.

Sensory supply

Sensory fibres carry impulses of distension and pain from the bladder. They travel through both sympathetic and parasympathetic fibres to the CNS.

Clinical Correlation

- The fibres carrying sensations of distension (filling of the bladder) travel through the posterior white column of the spinal cord, while the fibres carrying pain travel through the anterior and lateral white columns of the spinal cord.

The important point to note here is that sensory pathways carrying sensation of pain and distension take different routes in the spinal cord. Therefore, intractable bladder pain due

to **carcinoma bladder** may be relieved by cutting anterior and lateral white columns of spinal cord on both the sides (**bilateral anterolateral cordotomy**).

- **Effects of spinal cord injuries on the bladder function**

- The **atonic bladder** occurs during the phase of spinal shock (temporary loss/halt of all spinal functions) immediately after the injury. The muscle of bladder wall (detrusor muscle) is relaxed, the internal sphincter (sphincter vesicae) is tightly contracted (due to loss of inhibition from higher centres) and the external sphincter is relaxed. As a result the bladder becomes greatly distended with urine which finally overflows.
- The **automatic reflex bladder** occurs after the patient has recovered from the spinal shock, and if the cord is injured above the level of segments responsible for the parasympathetic outflow, i.e. **spinal micturition centre** (S2, S3 and S4). Due to involvement of descending fibres from paracentral lobule, the **cortical micturition centre**, the voluntary control on bladder is lost. As a result, the bladder fills and empties reflexly. The stretch receptors in the bladder wall are stimulated as the bladder fills and the afferent impulses pass to the spinal cord (S2, S3 and S4). From spinal cord the efferent impulses pass to the bladder, causing detrusor muscle to contract and internal and external sphincter urethrae to relax leading to emptying of the bladder. This spinal reflex for emptying the bladder occurs every 1 to 4 hrs.
- The **autonomous bladder** occurs if the sacral segments (S2, S3 and S4) of the spinal cord are destroyed. In this condition, the bladder has neither reflex control nor voluntary control because both, reflex centre for bladder emptying (S2, S3 and S4) and descending fibres from voluntary cortical centre have become non-functional. As a result the bladder wall becomes flaccid, and the capacity of the bladder is greatly increased. It fills to capacity and overflows, causing continuous dribbling of urine.

Bladder function

The process of micturition requires proper integration of autonomic and voluntary nervous systems. The contraction of smooth muscle of bladder wall (the detrusor muscle) is initiated by parasympathetic activity, while the internal sphincter mechanism (which is normally closed by sympathetic activity) is allowed to relax by decreased sympathetic activity. The external sphincter mechanism, which can be voluntarily relaxed to allow micturition is controlled by pudendal nerves (S2, S3 and S4).

Heart

Motor supply

Parasympathetic innervation: The preganglionic parasympathetic fibres arise from dorsal nucleus of vagus in the medulla oblongata, run through vagus nerve and its cardiac branches to synapse on the cells or ganglia in superficial and deep cardiac plexuses. The postganglionic fibres arise from these cells or ganglia and supply the sinuatrial and atrioventricular nodes and coronary arteries.

Sympathetic innervation: The preganglionic sympathetic fibres arise from T1 to T5 spinal segments and terminate in the cells of upper 3 or 4 thoracic ganglia and cervical sympathetic ganglia.

The postganglionic sympathetic fibres arise from these ganglia, pass first through the cardiac branches of these ganglia and then through cardiac plexuses to supply sinuatrial and atrioventricular nodes, and coronary arteries of the heart.

Functions

The sympathetic stimulation increases whereas the parasympathetic stimulation decreases the heart rate. During normal circumstances, the heart rate is normal because a balance is maintained between the inhibitory and the stimulatory effects of the parasympathetic and sympathetic innervation. The exertion and emotional emergencies tilt the balance towards the sympathetic tone, hence responsible for increased heart rate. The excessive vagal stimulation can bring the activity of the heart standstill.

Further, the sympathetic stimulation causes dilatation, and parasympathetic stimulation causes constriction of the coronary arteries, thus increasing or decreasing blood supply to the heart respectively.

Sensory supply

The afferent fibres from heart travel through both sympathetic and parasympathetic pathways. The *sensations of pain from heart* (due to anoxia, viz. angina) are carried by sympathetic fibres. They travel through cardiac branches of middle and inferior cervical sympathetic ganglia, pass successively through these ganglia, sympathetic trunks and spinal nerves to enter the spinal segments from T1 to T4/5.

Afferent fibres running along the cardiac branches of vagus nerves are concerned with reflexes controlling the activity of the heart.

Arteries of the Upper Limb

The arteries of the upper limb are innervated by sympathetic fibres only.

The preganglionic fibres arise from T2 to T8 thoracic spinal segments, and pass to the sympathetic trunk through white rami communicantes. After entering the trunk they ascend to synapse with the cells within the stellate and middle cervical sympathetic ganglia. The postganglionic fibres arise from these ganglia, join the nerves forming brachial plexus and are distributed to the arteries through the branches of brachial plexus. The stimulation of sympathetic nerves causes vasoconstriction of cutaneous arteries and vasodilatation of arteries supplying the skeletal muscles.

Clinical Correlation

The **Raynaud's disease** occurs due to vasospasm of the digital arteries of the upper limb following exposure to cold. It is common in women. There is pallor or cyanosis of the fingers associated with severe pain. The gangrene of the tips of the fingers may occur. It can be treated by preganglionic sympathectomy.

The symptoms are relieved: (a) by avoiding exposure to cold, and stopping smoking (smoking causes vasoconstriction), and (b) by giving drugs that inhibit sympathetic activity to bring about arterial dilatation.

The removal of stellate (cervicothoracic) ganglion (cervicothoracic preganglionic sympathectomy) has also been used in the past.

Arteries of the Lower Limb

The arteries of the lower limb are supplied by sympathetic nerves. The preganglionic fibres arise from lower three thoracic and upper two or three lumbar segments of the spinal cord (T10-L2), and pass to the lower thoracic and upper lumbar ganglia of the sympathetic chain. These fibres synapse in the lumbar and sacral ganglia. The postganglionic fibres arise from these ganglia and reach the arteries through the branches of lumbar and sacral plexuses.

Clinical Correlation

Buerger's disease is an arterial occlusive disease of the legs causing ischaemia of muscles. It is common in men, particularly those who smoke a lot. These individuals complain of **intermittent claudication**, i.e. appearance of pain on exercise which disappears after rest and reappears on exercise.

They may suffer from ischaemia and dry gangrene of the toes.

The **preganglionic lumbar sympathectomy** (removal of upper three lumbar ganglia and intervening parts of the sympathetic chain) is advocated in order to bring about vasodilatation and increase in the blood flow through the collateral circulation.

Clinical problems

1. What is the embryological basis of **congenital megacolon (Hirschsprung disease)**?
2. What are the effects of spinal cord injury on the bladder function?
3. Explain, why there is **enuresis (bed-wetting)** during infancy.
4. Pain arising from gall bladder is often referred to the tip of right shoulder. Mention the anatomical basis.
5. Explain, why the pain of renal and ureteric colic is referred to loin, groin scrotum/labium majus and inner aspect of the upper thigh.
6. Pain from appendix, testis and ovary is often referred to the skin around umbilicus. Mention the anatomical basis.
7. Explain, why the cardiac pain is felt over the mid-sternum in the precordium and often spreads to the medial side of arm and forearm.

Clinical problem solving

1. See [page 244](#).
2. See [page 245](#).
3. Because there is no cortical (voluntary) control on the **spinal micturition centre** in infants (as the descending corticospinal fibres have yet not myelinated).
N.B. The corticospinal fibres get myelinated and begin to function about the age of 3 to 6 years. Therefore bed-wetting after the age of 6 years attracts the parent's concerns.
4. Irritation of parietal peritoneum lining the diaphragm by diseased gall bladder (*viz.*

cholecystitis) accounts for referred pain to the tip of right shoulder, because parietal diaphragmatic peritoneum and skin over tip of right shoulder are supplied by phrenic and supraclavicular nerves respectively. Both of which arise from same spinal segments, i.e. C3 and C4.

5. The kidney and ureter are supplied by sympathetic fibres (responsible for carrying pain sensations) derived from T10 to L2 spinal segments. Therefore, the pain of **renal** and **ureteric colic** is referred to the regions of skin innervated by T10 to L2 spinal segments. It therefore commences in the back over the lower ribs (loin) and shoots downwards and forwards to the inguinal region (groin), scrotum/labium majus and upper inner aspect of the thigh ([Fig. 20.7](#)).
6. Pain from appendix, testis and ovary is referred to the skin around the umbilicus because all these organs and skin around the umbilicus are supplied by T10 spinal segment.
7. The heart is supplied by upper four thoracic spinal segments (T1–T4). The skin over sternum and precordium is supplied by T4, T3 and T2 spinal segments, the skin on the medial aspect of arm by T2 spinal segment and that on the medial aspect of forearm by T1 spinal segment.

The cardiac pain therefore being visceral in nature, is not felt in the heart, rather it is referred to the skin areas supplied by the same spinal segments which supply the heart.

Index

A

- Abducent nerve, [99](#)
- Accommodation, reflex, [217](#)
- Acetylcholinesterase (AChE), [34](#)
- Adamkiewicz, artery of, [70](#)
- Adiadochokinesis, [119](#)
- Agnosia
 - auditory verbal, [152](#)
 - visual, [153](#)
- Alternating hemiplegia, [202](#)
- Alveus, [230](#)
- Amnion's horn, [230](#)
- Amygdaloid body, [158](#)
- Amygdaloid nuclear complex, [229](#)
- Anencephaly, [2](#)
- Aneurysm, berry, [173](#)
- Angiogram
 - carotid, [179](#), [240](#)
- Angiography, cerebral, [179](#), [240](#)
- Angle, cerebellopontine, [82](#)
- Ankle jerk, [39](#)
- Annulospiral endings, [31](#)
- Anterior commissure, [165](#)
- Anterior spinothalamic tract, [64](#)
- Aphasia
 - global, [152](#)
 - motor, [150](#), [152](#)
 - receptive, [151](#), [152](#)
- Aqueduct, cerebral, [83](#)
- Arachnoid mater, [52](#), [187](#), [191](#)
- Arbor vitae cerebelli, [114](#)
- Archicerebellum, [113](#)
- Area(s)
 - entorhinal, [212](#), [230](#)
 - postrema, [122](#), [124](#)

septal, [230](#)

Argyll Robertson pupil, [88](#), [224](#)

Arnold-Chiari malformation, [89](#)

Artery(ies)

of Adamkiewicz, [70](#)

anterior spinal, [69](#)

arterial radicularis magna, [70](#)

arterial vaso-corona, [69](#)

basilar, [174](#)

central, [177](#)

cerebellar, anterior inferior, [174](#)

cerebellar, posterior inferior, [174](#)

cerebellar, superior, [174](#)

cerebral, anterior, [176](#)

cerebral, middle, [176](#)

cerebral, posterior, [174](#)

Charcot's, [177](#)

choroidal, anterior, [168](#), [176](#), [177](#)

choroidal, posterior, [177](#)

communicating, anterior, [172](#)

communicating, posterior, [172](#)

internal carotid, [175](#)

of cerebral haemorrhage, [168](#), [177](#)

of cerebral thrombosis, [176](#)

of Huebner, [168](#)

ophthalmic, [175](#)

spinal, anterior, [174](#)

spinal, posterior, [69](#), [174](#)

striate, [177](#)

vertebral, [174](#)

Ascending reticular activating system, [227](#)

Astereognosis, [151](#)

Asthenia, [119](#)

Astrocyte, [14](#)

Asynergia, [119](#)

Ataxia, [119](#)

Athetosis, [160](#)

Atrophy, muscular, [35](#)

Automatic reflex bladder, [245](#)

Autonomic innervation

of eyeball, [242](#)

of GIT, [243](#)

- of heart, [246](#)
- of limbs, [246](#)
- of salivary glands, [234](#)
- of urinary bladder, [244](#), [246](#)

Autonomic nervous system, [234](#), [247](#)

- afferent fibres, [23](#)
- divisions of, [234](#)
- higher control, [241](#)
- neurotransmitters, [239](#)

Axolemma, [13](#)

Axon, [10](#)

Axon hillock, [13](#)

Axonotmesis, [28](#)

Axon transport, [13](#)

Axoplasmic flow, [13](#)

B

Babinski's sign, [209](#)

Ballismus, [160](#)

- hemiballismus, [160](#)
- mono ballismus, [160](#)

Barr body, [18](#)

Barrier

- blood-brain, [183](#)
- blood-CSF, [185](#)

Basal nuclei, [156](#), [161](#)

- disorders of, [159](#), [160](#)
- functions of, [155](#), [158](#)

Base of brain, [46](#)

Bed-wetting, [247](#)

Benedikt's syndrome, [87](#)

Bladder, urinary

- atonic, [245](#)
- automatic reflex, [245](#)
- autonomous, [245](#)
- functional disorders, [245](#)
- innervation of, [245](#)

Blind spot, [213](#)

Blood brain barrier, [183](#)

Blood CSF barrier, [185](#)

Blood supply of

- brain, [172](#), [186](#)
- cerebellum, [119](#), [179](#)

cerebral cortex, [177](#)

corpus striatum, [179](#)

internal capsule, [179](#), [240](#)

medulla, [77](#)

midbrain, [87](#)

pons, [81](#)

thalamus, [179](#)

Body

amygdaloid, [229](#)

geniculate, lateral, [131](#), [132](#), [215](#)

geniculate, medial, [131](#), [132](#)

juxta-restiform, [97](#)

mammillary, [46](#), [135](#)

pineal, [132](#), [133](#)

pontobulbar, [79](#)

trapezoid, [80](#)

Bowman, gland of, [210](#)

Brachium

inferior, [131](#)

superior, [131](#)

Brain, [42](#)

base of, [46](#)

Brainstem, [72](#), [88](#)

medulla oblongata, [72](#), [78](#)

midbrain, [82](#), [88](#)

pons, [78](#), [82](#)

Brown-Sequard syndrome, [68](#)

Buerger's disease, [247](#)

Bulb, olfactory, [210](#)

Bundle, papillomacular, [215](#)

C

Calamus scriptorius, [122](#)

Canal, central, [48](#)

Capsule, internal, [165](#), [168](#)

Cauda equina, [55](#)

Caudate nucleus, [156](#)

Cavernous sinus, [189](#), [191](#)

thrombosis, [191](#)

Cell(s)

basket, [114](#)

ependymal, [15](#), [16](#)

Golgi, [115](#)

granule, [115](#)

microglia, [15](#)

neuroglial, [16](#)

oligodendrocytes, [15](#), [16](#)

Renshaw, [67](#)

satellite, [16](#)

Schwann, [16](#)

Stellate, [114](#)

Central nervous system, [42](#)

disorders, [47](#)

Cerebellar nodule, [112](#)

Cerebellum, [46](#), [111](#), [120](#)

arterial supply, [119](#)

comparator function of, [119](#)

connections of, [119](#)

cortex of, [114](#), [115](#)

external features, [111](#), [112](#)

functions of, [111](#)

grey matter, [114](#)

internal structure, [113](#)

intrinsic neuronal circuitry, [116](#)

nuclei intracerebellar, [119](#)

peduncles of, [116](#)

subdivisions of, [112](#), [113](#)

white matter of, [115](#)

Cerebral cortex, [146](#)

association areas, [148](#)

auditory areas, [152](#)

Broca's area, [150](#)

frontal eye field, [150](#)

functional areas, [148](#)

layers of, [147](#)

motor area of, [148](#)

motor speech area, [150](#)

olfactory areas of, [153](#)

parastriate, [153](#)

peristriate, [153](#)

prefrontal area of, [150](#)

premotor area of, [149](#)

primary motor area, [148](#)

primary sensory area, [151](#)

sensory area of, [148](#)

striate, [152](#)

structure, [146](#)

supplementary motor area, [150](#)

taste, [153](#)

types of, [146](#)

vestibular area, [153](#)

visual areas of, [152](#), [153](#)

Cerebral dominance, [153](#)

Cerebral hemisphere(s), [140](#)

borders of, [141](#)

gross anatomy, [140](#)

lobes of, [58](#), [142](#)

poles of, [140](#)

sulci and gyri, [141](#)

surfaces of, [140](#)

white matter of, [162](#)

Cerebrospinal fluid, [193](#)

circulation and absorption, [194](#)

functions of, [194](#)

production of, [194](#)

properties of, [195](#)

Cerebrovascular accidents, [50](#)

Cerebrum, [140](#), [154](#)

white matter, [162](#), [168](#)

Cervical spondylitis, [71](#)

Charcot's artery of cerebral haemorrhage, [177](#)

Chemoreceptor trigger zone (CTZ), [124](#)

Chiasma, optic, [215](#)

Chorea, [160](#)

Huntington, [160](#)

Sydenham's [160](#)

Choroid fissure, [171](#)

Choroid plexus

of third ventricle, [138](#)

of fourth ventricle, [121](#)

Chromatolysis, [26](#)

Cingulum, [162](#)

Circle of Willis, [172](#)

Circulus arteriosus, [172](#)

Cisternal puncture, [193](#)

Cisterns, subarachnoid, [192](#), [193](#)

of ambiens, [193](#)

cerebellomedullary/cisterna magna, [193](#)

interpeduncular, [193](#)

of great cerebral, [193](#)

of lateral sulcus, [193](#)

pontine, [193](#)

Clarke's column, [207](#)

Claudication, intermittent, [247](#)

Clastrum, [158](#)

Cleft, synaptic, [33](#)

Colliculus

facial, [79](#)

inferior, [84](#)

superior, [85](#)

Coma, [228](#)

Commissure(s)

anterior, [165](#)

corpus callosum, [163](#)

habenular, [133](#)

hippocampal, [232](#)

of fornix, [232](#)

posterior, [133](#), [165](#)

Congenital megacolon, [244](#)

Connexus, interthalamic, [126](#)

Contre-coup injury, [50](#)

Conus medullaris, [51](#)

Cord, spinal, [51](#), [71](#)

Cordotomy, [53](#), [68](#)

Corona radiate, [165](#)

Corpus callosum, [163](#), [164](#)

genu of, [164](#)

rostrum of, [164](#)

splenium of, [164](#)

trunk of, [164](#)

Corpus striatum, [155](#)

connections, [156](#)

functions, [157](#)

Corpuscle(s)

bulbous, [30](#)

of Krause, [30](#)

of Meissner, [30](#)

Pacinian, [30](#)

Ruffini's, [30](#)

Cortex

cerebellar, [113](#), [115](#)

cerebral, [146](#)

Corticonuclear tract, [200](#)

Corticospinal tract, [61](#), [199](#)

Cranial nerves

abducent, [99](#)

accessory, [106](#), [107](#)

classification, [90](#)

cortical control, [109](#)

facial, [101](#), [103](#)

functional components, [90](#), [97](#)

glossopharyngeal, [103](#), [104](#)

hypoglossal, [107](#), [109](#)

nuclei, [90](#), [97](#)

oculomotor, [97](#)

olfactory, [97](#)

optic, [97](#)

reflexes mediated by, [109](#)

superficial attachments, [47](#), [48](#)

trigeminal, [99](#)

trochlear, [98](#)

vagus, [104](#), [106](#)

vestibulocochlear, [103](#)

Craniopharyngioma, [136](#)

Crista ampullaris, [220](#)

Crus cerebri, [83](#)

Culmen, [112](#)

Cuneus, [145](#)

Cupula, [220](#)

D

Death

criteria for certification, [88](#), [89](#)

Decussation

of pyramids, [74](#)

of superior cerebellar peduncle, [85](#)

sensory, [76](#)

tegmental, dorsal, [85](#)

tegmental, ventral, [85](#)

Dendrites, [10](#)

Dentate gyrus, [230](#)

Dermatome, [36](#)

Development,
of brain, [3](#)
of functional columns in spinal cord, [3](#)
of spinal cord, [2](#)
of ventricular system, [5](#)

Diabetes
insipidus, [136](#)

Diagonal band
of Broca, [212](#)

Diencephalon, [60](#), [125](#), [139](#)
epithalamus, [132](#)
hypothalamus, [133](#), [137](#)
metathalamus, [131](#)
thalamus, [125](#), [131](#)

Diplegia, [199](#)

Disc, optic, [213](#)

Disease(s)
Buerger's, [247](#)
Raynaud's, [246](#)

Dorsal spinocerebellar tract, [207](#)

Double vision, [110](#)

Dura mater, [188](#)
arterial supply, [188](#)
nerve-supply, [188](#)
septa of, [187](#), [189](#)

Dural venous sinuses, [189](#), [191](#)

Dysmetria, [119](#)

E

Effectors, [32](#)
somatic, [32](#)
visceral, [34](#)

Encephalitis, [49](#)

Endoneurium, [25](#)

Enophthalmos, [243](#)

Entorhinal area, [212](#)

Enuresis, [21](#), [247](#)

Epilepsy, [49](#)

Epineurium, [25](#)

Epithalamus, [132](#)

Eyeball, innervation, [242](#)

F

Facial colliculus, [79](#)

Fasciculus

cuneatus, [205](#)

gracilis, [205](#)

lenticularis, [158](#)

medial longitudinal, [86](#)

subthalamic, [158](#)

thalamic, [158](#)

Fibres

anterior external, arcuate, [73](#), [117](#)

arcuate, internal, [205](#)

association, [162](#)

climbing, [116](#)

commissural, [163](#), [165](#)

mossy, [116](#)

posterior external arcuate, [76](#), [208](#)

projection, [165](#)

Filum terminale, [52](#)

Fimbria of hippocampus, [230](#)

Fissure, choroid, [171](#)

Fluid, cerebrospinal, [193](#)

Folium, of vermis, [112](#)

Foramen

of Luschka, [121](#)

of Magendie, [121](#)

Forceps major, [164](#)

Forceps minor, [164](#)

Forel ventral tegmental decussation of, [86](#)

Fornix, [231](#), [232](#)

postcommissural, [232](#)

precommissural, [232](#)

Fossa, interpeduncular, [46](#)

Fossa, rhomboid, [121](#)

Fovea centralis, [213](#)

Free nerve endings, [29](#)

Frey's syndrome, [26](#)

Froin's syndrome, [196](#)

Funiculus

definition of, [59](#)

of spinal cord, [59](#)

G

Galen, great cerebral vein of, [181](#)

Ganglion(s)

- autonomic, [27](#), [239](#)
- cervical sympathetic, [235](#)
- ciliary, [217](#)
- definition of, [13](#), [27](#)
- dorsal nerve root, [23](#)
- impar, [235](#)
- inferior cervical, [237](#)
- lumbar, [237](#)
- lumbar sympathetic, [235](#)
- middle cervical, [237](#)
- otic, [243](#)
- parasympathetic, [238](#)
- paravertebral, [235](#)
- prevertebral, [237](#)
- pterygopalatine, [244](#)
- sacral, [237](#)
- sacral sympathetic, [237](#)
- sensory, [27](#)
- spinal, [23](#)
- stellate, [237](#)
- submandibular, [244](#)
- superior cervical, [235](#)
- sympathetic, [27](#), [237](#)
- thoracic sympathetic, [237](#)

Geniculate body

- medial, [131](#), [132](#)
- lateral, [131](#), [132](#), [215](#)

Gland

- lacrimal, [243](#)
- parotid, [243](#)
- salivary, [243](#)
- sublingual, [243](#)
- submandibular, [243](#)

Glioblastoma

- multiforme, [15](#)

Globus pallidus, [156](#)

- in cerebellar cortex, [114](#)
- in olfactory bulb, [212](#)

Glomeruli

Gliosis

- replacement, [15](#)

Golgi tendon organ(s), [32](#)

Granule cells, [146](#)

Gyrus

ambiens, [211](#)

angular, [144](#)

cingulate, [145](#)

cuneate, [189](#)

cuneus, [144](#)

dentate, [229](#)

fasciolaris, [231](#)

frontal, inferior, [144](#)

frontal, middle, [144](#)

frontal, superior, [144](#)

Heschl's, [144](#)

medial frontal, [144](#)

occipital, inferior, [144](#)

occipital, superior, [144](#)

occipito-temporal, [146](#)

orbital, [145](#)

paracentral lobule, [145](#)

parahippocampal, [144](#), [145](#)

paraterminal, [144](#)

parolfactory, [144](#)

postcentral, [144](#)

precentral, [144](#)

rectus, [145](#)

supramarginal, [144](#)

temporal, inferior, [144](#)

temporal, middle, [144](#)

temporal, superior, [144](#)

temporal, transverse, [144](#)

H

Habenular commissure, [133](#)

Habenular nucleus, [133](#)

Haematoma

extradural, [188](#)

Haemorrhage

pontine, [82](#)

subarachnoid, [173](#), [186](#)

subdural, [183](#)

Hemianopia, [216](#)

Hemiballismus, [160](#)

Hemiplegia, [199](#)

Herniation

of brain, [49](#)

of intervertebral disc, [71](#)

Herpes zoster

ophthalmicus, [41](#)

Heschl's gyrus, [144](#), [152](#)

Hippocampal formation, [230](#)

Hippocampus, [230](#)

functions of, [231](#)

Hirschsprung disease, [244](#)

Horner's syndrome, [242](#)

Hydrocephalus, [196](#)

internal, [123](#), [197](#)

external, [197](#)

Hypertrophy, muscular, [48](#)

Hypothalamospinal tract, [63](#)

Hypothalamus, [60](#), [133](#)

connections of, [134](#)

control of

adenohypophysis by, [136](#)

neurohypophysis by, [135](#)

functions of, [136](#)

nuclei of, [134](#)

subdivisions of, [133](#)

Hypotonia, [203](#), [208](#)

I, J, K

Indusium griseum, [231](#)

Inferior sagittal sinus, [189](#)

Inhibition

reciprocal, [67](#)

Renshaw cell, [67](#)

Injuries

brain, [50](#)

spinal cord, [50](#)

Insula, [143](#)

Internal capsule, [165](#), [168](#)

arterial supply, [167](#), [168](#)

constituent fibres, [165](#)

parts, [165](#)

Internal carotid nerve, [237](#)

Internal cerebral veins, [181](#)

Interpeduncular fossa, [46](#)

Island of Reil, [143](#)

Jerk(s)

biceps, [39](#)

brachioradialis, [39](#)

knee, [38](#), [39](#)

quadriceps, [39](#)

triceps brachii, [39](#)

triceps surae, [39](#)

Kernicterus, [185](#)

Klüver-Bucy syndrome, [233](#)

Knee jerk, [38](#)

L

Labbe, inferior anastomotic vein of, [180](#)

Lateral geniculate body, [215](#)

Lateral spinothalamic tract, [63](#) Lateral ventricle(s), [168](#)

Lemniscus

medial, [205](#)

trigeminal, [96](#)

Lentiform nucleus, [156](#)

Ligamenta denticulata, [53](#)

Light reflex, [217](#)

Limbic lobe, [43](#)

Limbic system, [228](#), [233](#)

components of, [228](#)

functions of, [228](#)

Limen insulae, [143](#)

Lingula, [112](#)

Lobe, limbic, [228](#)

Lobes,

of cerebellum, [112](#), [113](#)

of cerebral hemisphere, [141](#)

frontal, [142](#), [143](#)

occipital, [143](#), [144](#)

parietal, [142](#), [144](#)

temporal, [143](#), [144](#)

Lobule, paracentral, [145](#)

Locus ceruleus, [121](#)

Lumbar puncture, [52](#)

Luschka, foramen of, [121](#)

M

Macula lutea, [213](#)

Maculae, [220](#)

Macular

area, [153](#)

sparing, [153](#)

Mammillothalamic tract, [232](#)

Medial geniculate body, [131](#)

Medial longitudinal fasciculus, [221](#)

Medulla oblongata, [72](#)

blood supply, [77](#)

external features, [72](#)

internal structure, [74](#)

Medulloblastoma, [124](#)

Megacolon, congenital, [244](#)

Melatonin, [132](#), [139](#)

Meninges, [187](#)

of brain, [187](#)

of spinal cord, [51](#)

Meningitis, [49](#)

Meningocele, [7](#), [8](#)

Meningoencephalocele, [7](#), [8](#)

Meningoencephalocele, [7](#), [8](#)

Metathalamus, [45](#), [131](#)

Meyer's loop, [215](#)

Meynert, dorsal tegmental decussation of, [85](#)

Microglia, [15](#)

Micturition centres, [245](#), [247](#)

Midbrain, [45](#), [82](#), [86](#)

external features, [82](#)

internal structure, [83](#), [86](#)

Monoplegia, [199](#)

Motor-end-plate, [33](#)

Motor speech area, [150](#)

Motor unit, [33](#)

Multiple sclerosis, [49](#)

Muscle power, [39](#)

grading, [40](#)

Muscle tone

abnormalities of, [37](#)

Muscular

atrophy, [35](#)

contracture, [40](#)

fasciculations, [40](#)

hypertrophy, [35](#)

rigidity, [37](#)

wasting, [40](#)

Myasthenia gravis, [34](#)

Myelination, [19](#)

Myelin sheath, [19](#)

N

Neocerebellum, [113](#)

Neostigmine, [34](#)

Nerve fibre(s), [19](#)

alpha (α), [32](#)

gamma (γ), [33](#)

myelinated, [19](#)

non-myelinated, [19](#)

peripheral, [22](#)

projection, [165](#)

somatic afferent, [22](#)

somatic efferent, [22](#)

visceral afferent, [22](#)

visceral efferent, [22](#)

Nerve(s)

abducent, [99](#)

accessory, [106](#)

cranial, [22](#)

facial, [101](#), [103](#)

glossopharyngeal, [103](#)

hypoglossal, [107](#)

oculomotor, [98](#)

olfactory, [97](#), [210](#)

optic, [97](#), [215](#)

peripheral, [22](#)

spinal, [23](#)

trigeminal, [99](#), [101](#)

trochlear, [98](#)

vagus, [104](#), [106](#)

vestibulocochlear, [103](#)

Nerve supply of

dilator pupillae, [242](#)

eyeball, [242](#)

gastrointestinal tract, [243](#)

heart, [246](#)

lacrimal gland, [243](#)

limbs, [246](#), [247](#)

parotid gland, [243](#)

salivary glands, [243](#)

sublingual gland, [243](#)

submandibular, [243](#)

urinary bladder, [244](#)

Nervi terminalis, [90](#)

Nervous system

autonomic, [9](#), [234](#), [247](#)

central, [42](#), [49](#)

development, [1](#), [7](#)

divisions of, [9](#)

organization, [10](#)

peripheral, [9](#)

somatic, [9](#)

Neural crest, [1](#)

Neural pathways

for balance, [221](#)

for hearing, [219](#)

for sense of smell, [212](#)

for taste, [223](#)

for vision, [215](#)

Neural tube, [1](#)

Neurites, [10](#)

Neuritis

ischaemic, [25](#)

Neurobiotaxis, [80](#)

Neuroglia, [14](#), [15](#)

functions of, [16](#)

Neuroma, [27](#)

Neuromuscular junction, [33](#), [34](#)

Neuromuscular spindles, [30](#), [31](#)

Neuron(s), [10](#), [14](#)

bipolar, [11](#)

Golgi type, [11](#)

lower motor (LMM), [12](#)

motor, [12](#)

multipolar, [11](#)

postganglionic, [12](#)

preganglionic, [12](#)

pseudounipolar, [11](#)

reserve cerebral, [50](#)

sensory, [12](#)

unipolar, [11](#)

upper motor (UMN), [12](#)

Neuropathy, peripheral, [27](#)

Neurotmesis, [25](#), [28](#)

Neurotransmitter(s), [17](#)

Node, of Ranvier, [19](#)

Nodule, of vermis, [121](#)

Nucleus/nuclei

abducent, [93](#)

ambiguus, [94](#)

arcuate, [79](#)

caudate, [156](#)

cerebellar, [119](#)

cochlear, [96](#)

commissural of vagus, [94](#)

cuneate, accessory, [76](#)

dentate, [115](#)

dorsal vagal, [94](#)

dorsalis, [59](#)

Edinger-Westphal, [94](#)

emboliform, [115](#)

facial, [93](#)

fastigial, [115](#)

general and special visceral afferent, [94](#)

general somatic afferent, [95](#)

general somatic efferent, [93](#)

general visceral efferent, [94](#)

globose, [115](#)

gracile, [76](#)

gustatory, [94](#)

habenular, [133](#)

hypoglossal, [93](#)

inferior salivatory, [94](#)

intracerebellar, [119](#)

lacrimatory, [94](#)

lentiform, [156](#)

mesencephalic, [96](#)

oculomotor, [85](#), [93](#), [97](#)

of facial nerve, [93](#)

of solitary tract, [94](#)

of trigeminal, main/chief sensory, [95](#)

of trigeminal, mesencephalic, [96](#)

of trigeminal, motor, [93](#)

of trigeminal, spinal, [95](#)

pretectal, [86](#)

proprius, [59](#)

red, [86](#)

somatic efferent, [93](#)

special somatic afferent, [96](#)

special visceral afferent, [93](#)

special visceral efferent, [93](#)

superior salivatory, [94](#)

trochlear, [85](#), [93](#)

vestibular, [96](#)

visceral afferent, [59](#)

Nystagmus, [124](#)

O

Obex, [122](#)

Olfactory

areas, cortical, [212](#)

bulb, [210](#)

epithelium, [210](#)

nerve, [97](#)

nerves, [210](#)

neural pathways, [212](#)

receptor cells, [210](#)

striae, [210](#)

tract, [210](#)

trigone, [212](#)

Olfactory system, [210](#), [213](#)

Ophthalmoplegias

external, [110](#)

internal, [110](#)

Optic

chiasma, [215](#)

nerve, [7](#), [215](#)

tract, [215](#)

P

Pacinian corpuscles, [30](#)

Pain

referred, [241](#)

visceral, [240](#)

Paleocerebellum, [113](#)

Papez circuit, [232](#)

Paracentral lobule, [145](#)

Paralysis, [199](#)

diplegia, [199](#)

flaccid, [203](#)

hemiplegia, [199](#)

lower motor, [203](#)

monoplegia, [199](#)

paraplegia, [199](#)

quadriplegia, [199](#)

Saturday night, [28](#)

spastic, [201](#)

upper motor, [201](#), [203](#)

Paraplegia, [199](#)

Parasympathetic nervous system, [237](#)

efferent fibres, [238](#)

functions of, [237](#)

Parasympathetic outflow

cranial, [238](#)

sacral, [238](#)

Parinaud's syndrome, [88](#)

Parkinsonism, [159](#)

Pathway(s)

auditory, [219](#)

dorsal column, [205](#)

lateral, [203](#)

lateral spinothalamic, [203](#)

of hearing, [219](#)

olfactory, [212](#)

pyramidal, [199](#)

somatic motor, [199](#)

somatic sensory, [203](#)

spinocerebellar, [207](#)

spinothalamic, [203](#), [206](#)

spinothalamocerebral, [203](#)

taste [298](#)

trigeminothalamic, [208](#)

dorsal, [208](#)

ventral, [208](#)

Peduncle

cerebellar, inferior, [117](#), [118](#)

cerebellar, middle, [118](#)

cerebellar, superior, [118](#)

cerebral, [83](#)

Perineurium, [25](#)

Peripheral nerves, [19](#), [27](#)

degeneration, [25](#)

nerve fibres, [24](#)

regeneration, [24](#)

structure, [24](#)

Pia mater, [52](#), [192](#)

Pineal gland, [132](#), [133](#)

calcification, [133](#)

Placodes, ectodermal, [2](#)

Pleasure zone, [230](#)

Plexus

autonomic, [239](#)

brachial, [23](#), [24](#)

cervical, [23](#), [24](#)

lumbosacral, [23](#), [24](#)

Pneumoencephalography, [171](#)

Poisoning, organophosphorous, [34](#), [35](#)

Poliomyelitis, [18](#)

Pons, [46](#), [78](#), [82](#)

blood supply, [81](#)

external features, [79](#)

internal structure, [79](#), [81](#)

tumours of, [82](#)

Posture, [40](#)

Ptosis, [243](#)

Puncture

cisternal, [193](#)

lumbar, [52](#)

Pupillary light reflex, [215](#)

Pupillary reflex, [217](#)

Pyramid

decussation of, [74](#)

Q, R

Quadrants, retinal, [214](#)

Quadriplegia, [199](#)

Queckenstedt's test, [198](#)

Rachischisis, [2](#)

Radiation

acoustic, [167](#)

optic, [167](#)

thalamic, [167](#)

Raphe nuclei, [225](#)

Raynaud's disease, [246](#)

Rebound phenomenon, [199](#)

Recent memory

loss of, [128](#)

Receptor(s), [29](#), [32](#)

adrenergic, [239](#)

classification, [29](#)

cutaneous, [30](#)

encapsulated, [30](#)

in joints, [32](#)

muscarinic, [239](#)

muscle, [30](#)

nicotinic, [239](#)

non-encapsulated, [29](#)

of static balance [294](#)

Red nucleus, [86](#)

Referred pain, [241](#)

sites, [241](#)

Reflex/Reflexes

accommodation, [217](#), [218](#)

Achilles tendon, [39](#)

biceps tendon, [39](#)

brachioradialis, [39](#)

carotid, [109](#)

carotid sinus, [109](#)

conjunctival, [109](#)

corneal, [109](#)

gag, [109](#), [140](#)

gamma reflex loop, [31](#)

Jaw Jerk, [109](#)

lacrimation, [109](#)

light [290](#)

oculocardiac, [109](#)

patellar tendon, [39](#)

plantar, [39](#)

pupillary, [217](#)

sneezing, [109](#)

spinal, [65](#)

stretch, [31](#)

triceps tendon, [39](#)

Reflex arc, [67](#)

Reil, Island of, [143](#)

Releasing hormones, [136](#)

Renshaw cells, [67](#)

Reticular formation, [225](#), [233](#)

connections, [227](#)

functions of, [228](#)

nuclei of, [225](#)

Reticulospinal tracts, [63](#)

lateral, [63](#)

medial, [63](#)

Retina, [213](#)

detachment, [214](#)

layers of, [213](#)

quadrants, [214](#)

Retinal quadrants, [214](#)

Rexed laminae, [59](#)

Rhinencephalon, [228](#)

Rhomberg's sign, [119](#)

Rigidity, muscular

clasp-knife type, [37](#), [41](#)

cogwheel type, [37](#), [41](#)

lead-pipetype, [37](#), [41](#)

Rosenthal, basal vein of, [181](#)

Rubrospinal tract, [61](#), [63](#)

Ruffini's corpuscles, [30](#)

S

Saturday night paralysis, [28](#)

Schizophrenia, [233](#)

Segmental innervation

of muscles, [38](#)

of skin, [36](#)

Seizure, [49](#)

Sensory perception abnormalities, [38](#)

Septal region, [229](#)

Sinuses, dural venous, [189](#), [191](#)

cavernous sinus, [190](#), [191](#)

confluence of sinuses, [189](#)

inferior petrosal, [191](#)

inferior sagittal, [189](#)

occipital, [189](#)

sigmoid, [191](#)

straight, [189](#)

superior petrosal, [191](#)

superior sagittal, [189](#)

sphenoparietal, [189](#)

transverse, [191](#)

Siphon, carotid, [175](#)

Space occupying lesions, [49](#), [50](#)

Spastic paralysis, [61](#)

Spina bifida, [7](#), [8](#)

Spinal cord, [51](#), [71](#)

blood supply, [69](#), [71](#)

development, [2](#)

enlargements of, [55](#), [56](#)

external features, [53](#)

grey matter, [57](#), [60](#)

internal structure, [55](#)

laminae of, [59](#)

lesions of, [67](#), [71](#)

meninges, [51](#)

positional changes, [51](#)

tracts, [60](#), [69](#)

white matter, [60](#)

Spinal nerves, [52](#)

Spinal segments, [54](#), [55](#)

Spinal shock, [50](#)

Spinocerebellar pathways, [207](#)

Spinothalamic pathways, [203](#)

Spinothalamic tracts

lateral, [203](#)

ventral, [203](#)

Spinocerebellar tracts, [207](#)

dorsal, [207](#)

ventral, [207](#)

Squint

lateral, [98](#)

medial, [99](#)

Strabismus

lateral, [98](#)

medial, [98](#)

Stretch reflex, [31](#)

Stria

longitudinal, [231](#)

medullaris, [121](#)

medullaris thalami, [229](#)

olfactory, [212](#)

terminalis, [156](#)

Striatum, [156](#)

Stroke, [50](#)

cerebral, [186](#)

Subiculum, [231](#)

Substantia gelatinosa, [59](#)

Substantia nigra, [84](#), [158](#)

Subthalamus, [45](#), [133](#), [158](#)

Sulcus

calcarine, [142](#)

callosal, [145](#)

central, [142](#)

cingulate, [145](#)

circular, [143](#)

collateral, [145](#)

frontal, inferior, [144](#)

frontal, superior, [144](#)

lateral, [142](#)

limitans, [121](#)

lunate, [144](#)

occipital, lateral, [144](#)

occipital, transverse, [144](#)

occipito-temporal, [145](#)

olfactory, [145](#)

orbital, [145](#)

parieto-occipital, [142](#)

postcalcarine, [145](#)

postcentral, [144](#)

precentral, [143](#)

rhinal, [143](#)

suprasplenic, [145](#)

temporal, inferior, [144](#)

temporal, superior, [144](#)

Superior sagittal sinus, [189](#)

Supinator jerk, [39](#)

Sylvius, cerebral aqueduct of, [83](#)

Sympathetic nervous system, [234](#)

efferent fibres, [235](#)

functions of, [235](#)

ganglia of, [235](#), [237](#)

outflow, [235](#)

trunk of, [235](#)

Sympathetic trunks, [235](#)

Synapse, [15](#), [17](#)

classification, [16](#)

properties, [17](#)

structure, [16](#)

Synaptic transmission, [15](#)

Syndrome

acute amnesic, [232](#)

anterior spinal artery, [69](#)

Benedikt's, [87](#)

Brown-Sequard, [68](#)

cerebellar, [119](#)

Frey's, [26](#)

Froin's, [196](#)

Horner's, [242](#)

Klüver-Bucy, [233](#)

lateral medullary, [78](#)

loculation, [196](#)

medial medullary, [78](#)

Millard-Gubler, [81](#)

Parinaud's, [88](#)

pontocerebellar angle, [82](#)

split-brain, [164](#)

thalamic, [130](#), [139](#)

vermis, [124](#)

Weber's, [87](#)

Syringomyelia, [67](#)

System(s)

auditory, [218](#), [220](#)

enteric nervous, [234](#)

extrapyramidal, [201](#)

limbic, [228](#), [232](#)

olfactory, [210](#), [213](#)

parasympathetic, nervous, [237](#), [239](#)

pyramidal, [200](#)

sympathetic nervous [234-237](#)

vestibular, [220](#), [222](#)

visual, [213](#), [218](#)

T

Tabes dorsalis, [65](#)

Tactile corpuscles, [30](#)

Tactile discs (of Merkel), [30](#)

Tapetum, [164](#)

Taste, [222](#)

area, [223](#)

buds, [222](#)

neural pathways, [223](#)

types, [223](#)

Taste buds, [222](#)

Tetanus toxin, [28](#)

Thalamus, [125](#), [130](#)

connections of, [127](#)

external features, [126](#)

functions, [129](#)

internal structure, [126](#)

nuclei, [127](#)

Third ventricle, [137](#), [138](#)

Tract

anterior spinocerebellar, [65](#)

anterior spinothalamic, [64](#)

corticonuclear, [200](#)

corticospinal, [199](#)

anterior, [64](#), [199](#)

lateral, [199](#)

cuneocerebellar, [66](#), [208](#)

dorsal spinocerebellar, [65](#)

dorsal trigeminothalami, [208](#)

dorsolateral tract of Lissauer, [64](#)

geniculocalcarine, [212](#)

hypothalamohypophyseal, [135](#)

intersegmental, [65](#)

mammillothalamic, [232](#)

of Burdach, [64](#)

of Goll, [64](#)

of trigeminal nerve, spinal, [208](#)

olfactory, [212](#)

optic, [211](#)

posterior column, [65](#)

pyramidal, 199

reticulospinal, 63

lateral, 63

medial, 63

rubrospinal, 61, 63

solitariohypothalamic, 95

solitariothalamic, 223

spinal tract of trigeminal nerve, 95

supraopticohypophyseal, 135

tectospinal, 84

tubero-infundibular, 136

ventral trigeminothalamic, 208

Trapezoid body, 79, 81

Tremor

intention, 120

resting, 120

Trochlear nerve, 98

Trolard, superior anastomotic vein of, 180

Tuber cinereum, 46, 47

Tubercle

cuneate, 75

gracile, 75

Typical spinal nerve, 23

U, V

Uncus, 148, 228

Urinary bladder, 244

atonic, 245

automatic reflex, 245

autonomous, 245

motor supply, 245

sensory supply, 245

Vasa-corona, 69

Vasopressin, 135

Vein(s)

anastomotic, inferior, 180

anastomotic, superior, 180

basal, 181

bridging, 183

cerebral, 180

cerebral, anterior, 181

cerebral, deep middle, 180

cerebral, great, 181

cerebral, inferior, [180](#)

cerebral, internal, [181](#)

cerebral, superficial middle, [180](#)

cerebral, superior, [180](#)

striate, [181](#)

thalamostriate, [181](#)

Velum

inferior medullary, [121](#)

superior medullary, [121](#)

Venous drainage, of brain, [179](#), [183](#)

Ventral spinocerebellar tract, [65](#), [207](#)

Ventral spinothalamic tract, [64](#), [205](#)

Ventricles of CNS, [49](#)

fourth, [120](#), [124](#)

lateral, [168](#), [171](#)

boundaries [169-170](#)

parts, [169](#)

third, [137](#), [138](#)

Ventriculography, [171](#)

Vermis

of cerebellum, [111](#)

Vesicles of brain, [3](#), [4](#)

primary, [3](#), [4](#)

secondary, [3](#), [4](#)

Vestibular system, [220](#), [222](#)

neural pathways, [221](#), [222](#)

receptors, [220](#)

Vicq d'Azyr bundle of, [232](#)

Virchow-Robin's space, [192](#)

Visceral pain, [240](#), [241](#)

Vision, binocular, [214](#)

Visual reflexes, [217](#)

Visual field, [214](#)

Visual system, [213](#), [218](#)

neural pathway, [215](#)

Vital centres, [72](#)

W, X, Z

Waldeyer, neuron theory of, [16](#)

Wallerian degeneration, [26](#)

Web, synaptic, [17](#)

Weber's syndrome, [87](#)

Wernicke's sensory speech area, [151](#)

White matter

of cerebellum, [115](#)

of cerebrum, [162](#), [168](#)

of spinal cord, [60](#), [68](#)

Willis, circle of, [172](#)

Withdrawal reflex, [65](#)

Zona inserta, [158](#)